

Patient Name: RAJENDRA THITE

Date and Time: 26th Mar 22 11:13 AM

Patient ID: 2208525351

Age **43** **9** **2**
 years months days

Gender **Male**

Heart Rate **80bpm**

Patient Vitals

BP: NA

Weight: NA

Height: NA

Pulse: NA

Spo2: NA

Resp: NA

Others: _____

Measurements

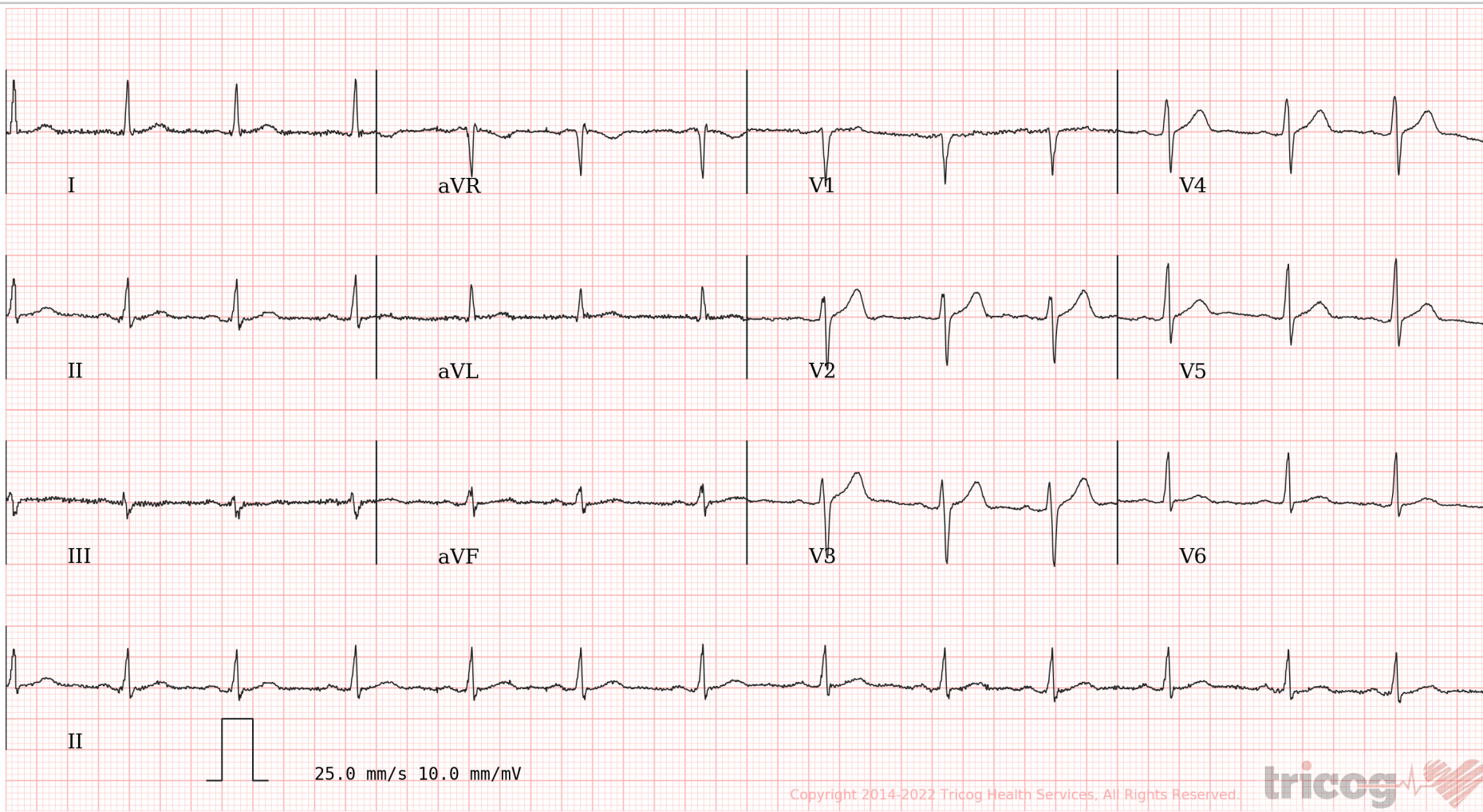
QSRD: 82ms

QT: 342ms


QTc: 394ms

PR: 158ms

P-R-T: 91° 19° 33°



Copyright 2014-2022 Tricog Health Services, All Rights Reserved.



ECG Within Normal Limits: Sinus Rhythm, Normal Axis. Please correlate clinically.

REPORTED BY

Dr. Milind Shinde
 MBBS, DNB Medicine
 2011/05/1544



Use a QR Code Scanner
Application To Scan the Code

CID : 2208525351
Name : MR.RAJENDRA THITE
Age / Gender : 43 Years / Male
Consulting Dr. : -
Reg. Location : Lulla Nagar, Pune (Main Centre)

Collected : 26-Mar-2022 / 12:26
Reported : 26-Mar-2022 / 19:43

AERFOCAMI HEALTHCARE BELOW 40 MALE/FEMALE

<u>PARAMETER</u>	<u>RESULTS</u>	<u>BIOLOGICAL REF RANGE</u>	<u>METHOD</u>
Urine Sugar (Fasting)	Present (+++)	Absent	
Urine Ketones (Fasting)	Absent	Absent	
Urine Sugar (PP)	Present (++++)	Absent	
Urine Ketones (PP)	Absent	Absent	

*Sample processed at SUBURBAN DIAGNOSTICS (INDIA) PVT. LTD Pune Lab, Pune Swargate
*** End Of Report ***



MC-2463



Dr.GOURAV AGRAWAL
DCP, DNB (Path)
Pathologist

ADDRESS: 2nd Floor, Aston, Sundervan Complex, Above Mercedes Showroom, Andheri West - 400053

Page 1 of 1

HEALTHLINE - MUMBAI: 022-6170-0000 | OTHER CITIES: 1800-266-4343

For Feedback - customerservice@suburbandiagnosics.com | www.suburbandiagnosics.com

CID#	: 2208525351	SID#	: 177803097089
Name	: MR.RAJENDRA THITE	Registered	: 26-Mar-2022 / 09:32
Age / Gender	: 43 Years/Male	Collected	: 26-Mar-2022 / 09:32
Consulting Dr.	: -	Reported	: 26-Mar-2022 / 12:34
Reg.Location	: Lulla Nagar, Pune (Main Centre)	Printed	: 26-Mar-2022 / 12:40

USG WHOLE ABDOMEN

LIVER : The liver is enlarged in size and measures 18.5 cm. It shows raised parenchymal echo pattern. The intra hepatic biliary and portal radical appear normal. No evidence of any intra hepatic cystic or solid lesion seen. The main portal vein and CBD appears normal.

GALL BLADDER : The gall bladder is physiologically distended. The visualized gall bladder appears normal. No evidence of pericholecystic fluid is seen.

PANCREAS : The pancreas is well visualised and appears normal. No evidence of solid or cystic mass lesion is noted.

KIDNEYS : Both the kidneys are normal in size, shape and echotexture. No evidence of any calculus, hydronephrosis or mass lesion seen.

SPLEEN : The spleen is normal in size, shape and echotexture. No evidence of focal lesion is noted.

URINARY BLADDER : The urinary bladder is well distended. It shows thin walls and sharp mucosa. No evidence of calculus is noted. No mass or diverticulum is seen.

PROSTATE : The prostate is normal in size and echotexture.

Visualized small bowel loops appear non-dilated. Gaseous distension of large bowel loops. There is no evidence of any lymphadenopathy or ascitis.

CID#	: 2208525351	SID#	: 177803097089
Name	: MR.RAJENDRA THITE	Registered	: 26-Mar-2022 / 09:32
Age / Gender	: 43 Years/Male	Collected	: 26-Mar-2022 / 09:32
Consulting Dr.	: -	Reported	: 26-Mar-2022 / 12:34
Reg.Location	: Lulla Nagar, Pune (Main Centre)	Printed	: 26-Mar-2022 / 12:40

IMPRESSION :

Ø Hepatomegaly with fatty liver.

Advice - Clinical and lab correlation.

*** End Of Report ***



Dr.Navid Shattari
MD, DNB, Radio-Diagnosis Reg No.
2015/05/2742

CID#	: 2208525351	SID#	: 177803097089
Name	: MR.RAJENDRA THITE	Registered	: 26-Mar-2022 / 09:32
Age / Gender	: 43 Years/Male	Collected	: 26-Mar-2022 / 09:32
Consulting Dr.	: -	Reported	: 26-Mar-2022 / 12:43
Reg.Location	: Lulla Nagar, Pune (Main Centre)	Printed	: 26-Mar-2022 / 12:59

X-RAY CHEST PA VIEW

Prominent bronchovascular markings are noted.

No obvious consolidation/cavitation.

The cardiothoracic ratio is maintained.

The domes of the diaphragm are normal.

The cardio and costophrenic angles are clear.

Bony thorax is normal.

Advice - Clinical and lab correlation.

*** End Of Report ***



Dr. Navid Shattari
MD, DNB, Radio-Diagnosis Reg No.
2015/05/2742

CID#	: 2208525351	SID#	: 177803097089
Name	: MR.RAJENDRA THITE	Registered	: 26-Mar-2022 / 09:32
Age / Gender	: 43 Years/Male	Collected	: 26-Mar-2022 / 09:32
Consulting Dr.	: -	Reported	: 26-Mar-2022 / 14:48
Reg.Location	: Lulla Nagar, Pune (Main Centre)	Printed	: 26-Mar-2022 / 14:54

PHYSICAL EXAMINATION REPORT

a) Diet : Veg

b)Addiction : No (HTN & DM-2 Since 5 Years)

GENERAL EXAMINATION :

a)Height (cms) : 168

b)Weight (kgs) : 81

c)Lymph Nodes : Not Palpable

3) SYSTEMIC EXAMINATION

A) RESPIRATORY SYSTEM

a) Lungs : Clear

b) Trachea : Central

c) Air Entry : Equal

d) Rales : No

d) Others : NAD

B) CARDIOVASCULAR SYSTEM (CVS)

a) Heart Sounds : S1 S2 Normal

b) Murmurs : No

c) Pulse/min : 82

d) B/P (mm of Hg) : 130/80

e) Miscellenous : NAD

CENTRAL PROCESSING LAB: 2nd Floor, Aston, Sundervan Complex, Above Mercedes Showroom, Andheri West - 400053

HEALTHLINE - MUMBAI: 022-6170-0000 | **OTHER CITIES:** 1800-266-4343

For Feedback - customerservice@suburbandiagnosics.com | **www.suburbandiagnosics.com**

CID#	: 2208525351	SID#	: 177803097089
Name	: MR.RAJENDRA THITE	Registered	: 26-Mar-2022 / 09:32
Age / Gender	: 43 Years/Male	Collected	: 26-Mar-2022 / 09:32
Consulting Dr.	: -	Reported	: 26-Mar-2022 / 14:48
Reg.Location	: Lulla Nagar, Pune (Main Centre)	Printed	: 26-Mar-2022 / 14:54

C) ABDOMEN

- a) Liver : Not Palpable
- b) Spleen : Not Palpable
- c) Any other Swelling : No

D) NERVOUS SYSTEM

- a) Ankle Reflex : Normal
- b) Plantars : Flexor

DOCTOR REMARKS :

*** End Of Report ***



Dr.Milind Shinde
MBBS, DNB, Consuling Physician,
Diabetologist & Echocardiologist

CENTRAL PROCESSING LAB: 2nd Floor, Aston, Sundervan Complex, Above Mercedes Showroom, Andheri West - 400053

HEALTHLINE - MUMBAI: 022-6170-0000 | **OTHER CITIES:** 1800-266-4343

For Feedback - customerservice@suburbandiagnosics.com | **www.suburbandiagnosics.com**