

Customer Name	MR.A MANJUNATHA C	Customer ID	MED120491726
Age & Gender	30Y/MALE	Visit Date	22/11/2021
Ref Doctor	MediWheel		

2D ECHOCARDIOGRAPHIC STUDY

M-mode measurement:

AORTA	:	2.65	cms.
LEFT ATRIUM	:	3.28	cms.
AVS	:	1.45	cms.
LEFT VENTRICLE			
(DIASTOLE)	:	5.31	cms.
(SYSTOLE)	:	3.04	cms.
VENTRICULAR SEPTUM	:		
(DIASTOLE)	:	1.01	cms.
(SYSTOLE)	:	1.11	cms.
POSTERIOR WALL	:		
(DIASTOLE)	:	1.06	cms.
(SYSTOLE)	:	1.45	cms.
EDV	:	135	ml.
ESV	:	36	ml.
FRACTIONAL SHORTENING	:	30	%
EJECTION FRACTION	:	60	%
EPSS	:	---	cms.
RVID	:	1.85	cms.

DOPPLER MEASUREMENTS:

MITRAL VALVE:	E - 0.6 m/s	A - 0.5 m/s	NO MR.
AORTIC VALVE:	1.1 m/s		NO AR.
TRICUSPID VALVE:	E - 0.3 m/s	A - 0.2 m/s	TRACE TR.
PULMONARY VALVE:	0.6 m/s		NO PR.




Customer Name	MR.A MANJUNATHA C	Customer ID	MED120491726
Age & Gender	30Y/MALE	Visit Date	22/11/2021
Ref Doctor	MediWheel		

2D ECHOCARDIOGRAPHY FINDINGS:

Left Ventricle	:	Normal size, Normal systolic function. No regional wall motion abnormalities.
Left Atrium	:	Normal.
Right Ventricle	:	Normal.
Right Atrium	:	Normal.
Mitral Valve	:	Normal. No mitral valve prolapsed.
Aortic Valve	:	Normal. Trileaflet.
Tricuspid Valve	:	Normal.
Pulmonary Valve	:	Normal.
IAS	:	Intact.
IVS	:	Intact.
Pericardium	:	No pericardial effusion.

IMPRESSION:

- NORMAL SIZED CARDIAC CHAMBERS.
- NORMAL LV SYSTOLIC FUNCTION. EF: 60%.
- NO REGIONAL WALL MOTION ABNORMALITIES.
- GRADE I DIASTOLIC DYSFUNCTION.
- TRACE TR, PASP 25mmHg.
- NORMAL VALVES.
- NO CLOTS / PERICARDIAL EFFUSION / VEGETATION.

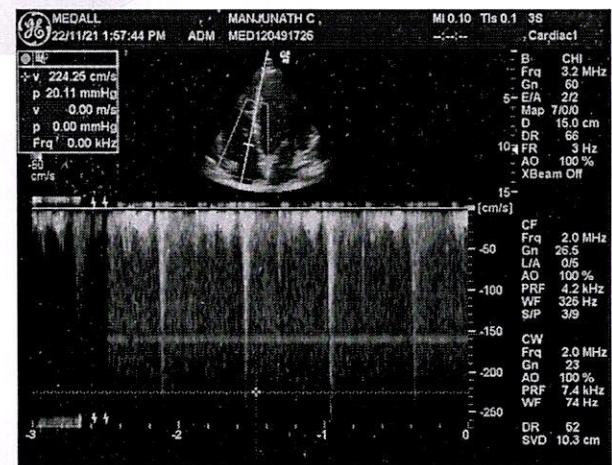
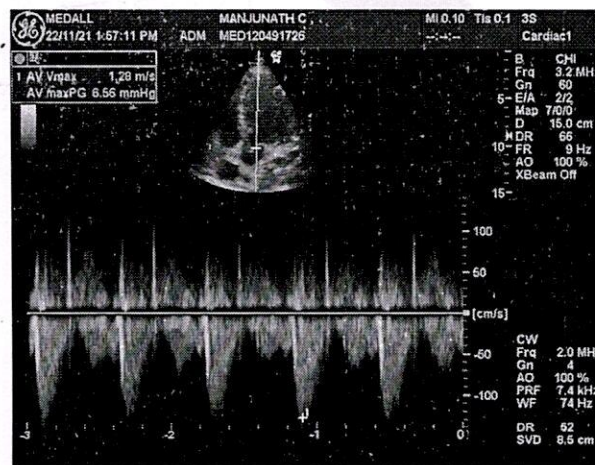
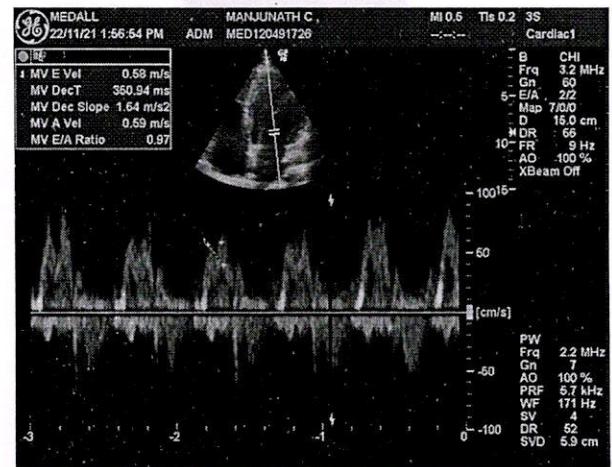
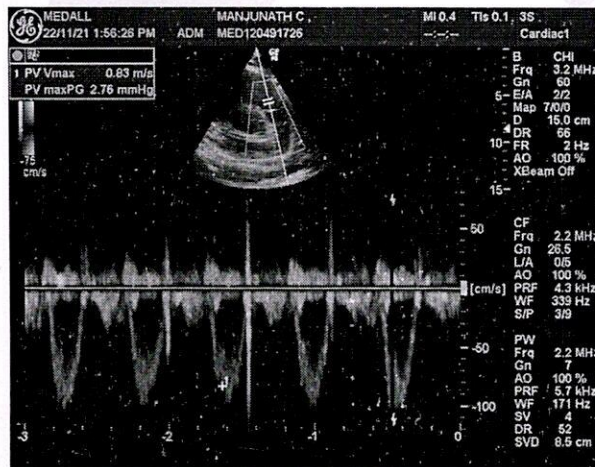
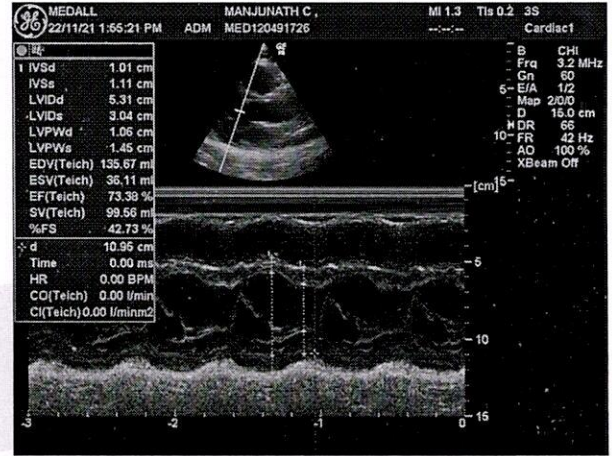
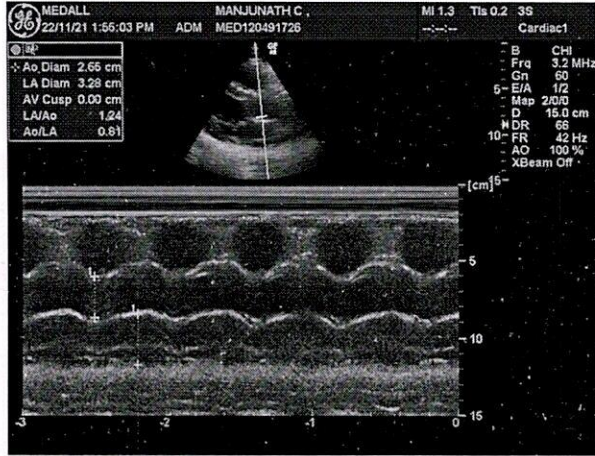


DR. YASHODHA RAVI
CONSULTANT CARDIOLOGIST



CLUMAX DIAGNOSTICS
2nd Main, Basyam Circle, Vyalikaval, Bangalore-560003

Customer Name	MR.A MANJUNATHA C	Customer ID	MED120491726
Age & Gender	30Y/MALE	Visit Date	22/11/2021
Ref Doctor	MediWheel		



You can also conveniently view the reports and trends through our App. Scan QR code to download the App.



Please produce bill copy at the time of collecting the reports. Request you to provide your mobile number or customer id during your subsequent visits.

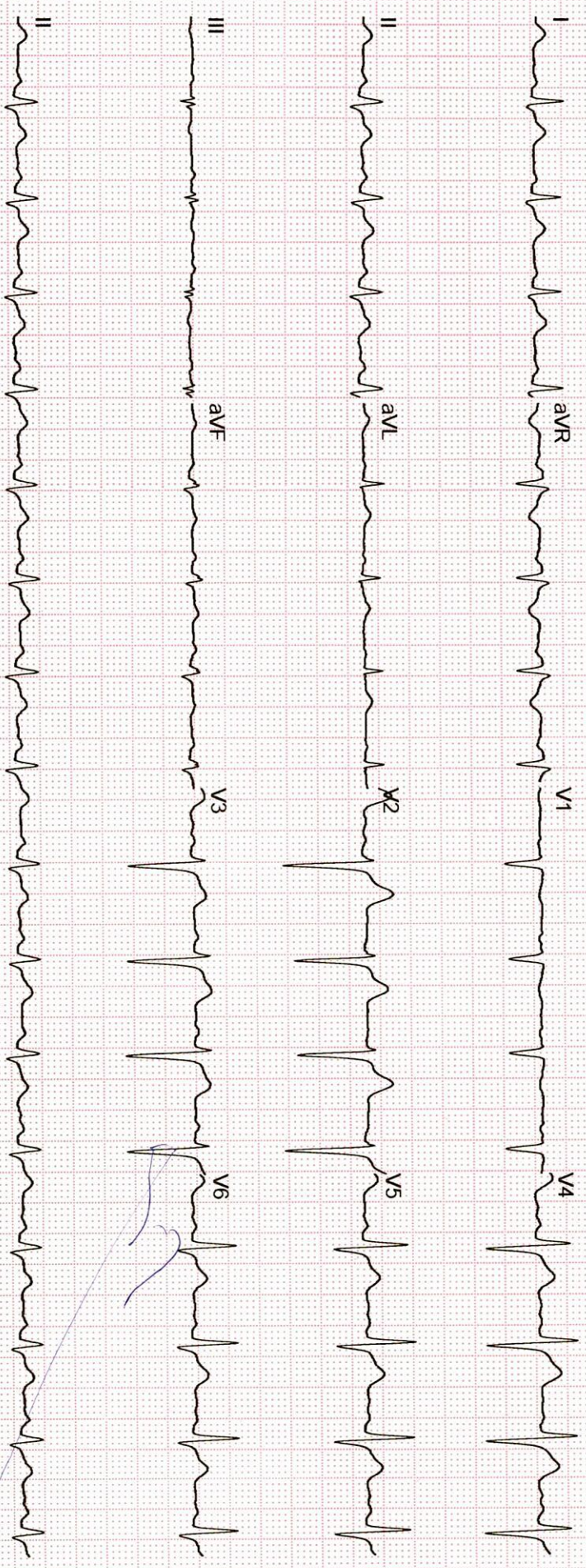
30 Years
Male

QRS : 100 ms
QT / QTcBaz : 342 / 434 ms
PR : 146 ms
P : 100 ms
RR / PP : 618 / 618 ms
P / QRS / T : 44 / 25 / 29 degrees

Normal sinus rhythm
Normal ECG

SR
@Ravi

Technician:
Ordering Ph:
Referring Ph:
Attending Ph:



GE MAC2000 1 1 12SL™ V241

25 mm/s 10 mm/mV

ADS 0.56-20 Hz 50 Hz 4x2.5x3_25_R1

Unconfirmed

1/1

Name	A MANJUNATHA C	ID	MED120491726
Age & Gender	30Y/M	Visit Date	Nov 22 2021 12:00AM
Ref Doctor	MediWheel		

X - RAY CHEST PA VIEW

Bilateral lung fields appear normal.

Cardiac size is within normal limits.

Bilateral hilar regions appear normal.

Bilateral domes of diaphragm and costophrenic angles are normal.

Visualised bones and soft tissues appear normal.

IMPRESSION:

- **No significant abnormality detected.**

DR. H.K. ANAND

DR. C.R. RAMACHANDRA

DR. VARSHA KALE

DR. LOHITH H.P

CONSULTANT RADIOLOGISTS



Dr.SHYLESH REDDY

M.B.B.S.,Dip. DIAB, (A.U)

KMC # 66843

Cons.Physician & Diabetologist

e-mail: drshyleshreddy@yahoo.com



Mangunatha. C.

B.P: 130/80mm of Hg

30/M

Imp:- Normal

Shyleshreddy

