



OnePLUS Ultrasound Lab

— QUALITY FIRST... ALWAYS! —

Dr. Nitin Agarwal
Pathologist & Director
Ex. Sr. Res. MAMC
& Lok Nayak Hospital
Ex. Chief of Lab Dr. Lal Path Labs.

Dr. Pooja (Garg) Agarwal
Radiologist & Director
MAMC & Lok Nayak Hospital



NAME	:Mr. JATIN GURI	Barcode No	:10140825
AGE/GENDER	:31 YRS/Male	SPECIMEN DATE	:25/Mar/2023 08:30AM
PATIENT ID	:111315	SPECIMEN RECEIVED	:25/Mar/2023 02:45PM
REFERRED BY	:Dr. MEDIWHEEL	REPORT DATE	:25/Mar/2023 03:39PM
CENTRE NAME	:ONEPLUS ULTRASOUND LAB	LAB NO.	:012303250008

Test Name	Result	Unit	Ref. Range
BIOCHEMISTRY			
Medi Wheel Health checkup < 40 Male			
Blood sugar pp	97	mg/dL	70.0-140.0

*** End Of Report ***

Checked By.

Dr NITIN AGARWAL
MBBS, MD (Path)
DMC/R/01436
DR. NITIN AGARWAL
MBBS,MD(PATHOLOGIST)

47, Harsh Vihar, Pitampura, New Delhi-110034 | Ph.: 011-42480101, 9599913051
E-mail: oneplusul@gmail.com | Web.: www.oneplusul.in

Page 1 of 1

Clinical correlation is essential for final diagnosis. • If test results are unsatisfactory please contact personally or on phone. • This report is for perusal of doctors only.
• All disputes Subject to Delhi Jurisdiction only. • Not for medicolegal purposes. • All congenital anomalies in a foetus may not be diagnosed in routine obstetric ultrasound.

भारत सरकार

जतिन गुरी
Jatin Guri
जन्म तिथि / DOB : 21/05/1992
पुरुष / MALE

8478 3221 4063

आधार - आम आदमी का अधिकार



Jatin Guri

[Signature]

Dr. NITIN AGARWAL
MBBS, MD
Regn. No. DMC-R-1436

भारतीय विशिष्ट पहचान प्राधिकरण
UNIQUE IDENTIFICATION AUTHORITY OF INDIA


पता: S/O अनिल कुमार,
सी-७/१९५, सेक्टर-७, रोहिणी, नोर्थ
वेस्ट दिल्ली, दिल्ली, 110085

Address: S/O Anil Kumar,
C-7/195, SECTOR-7, Rohini,
North West Delhi, Delhi, 110085

1947 1800 300 1947 help@uidai.gov.in www.uidai.gov.in P.O. Box No. 1947 Bengaluru-560 001

ONEPLUS ULTRASOUND LAB
47, Harsh Vihar, Pitam Pura,
Delhi-110034
Ph. 011-42480101, 959991305
E-mail: oneplusul@gmail.com





Dr. NITIN AGARWAL
MBBS, MD
Regn. No. DMC-R-1436

ONEPLUS ULTRASOUND LAB
47, Harsh Vihar, Pitam Pura,
Delhi-110034
Ph. 011-42480101, 9599913051
E-mail: oneplusul@gmail.com





OnePLUS
Ultrasound Lab
— QUALITY FIRST... ALWAYS! —

Dr. Nitin Agarwal

Pathologist & Director
Ex. Sr. Res. MAMC
& Lok Nayak Hospital
Ex. Chief of Lab Dr. Lal Path Labs.

Dr. Pooja (Garg) Agarwal

Radiologist & Director
MAMC & Lok Nayak Hospital

To
Oneplus lab
Harsh Vihar

25/3/23

I would like to inform you that I am not
willing to undergo stool test.

Jatin Garg
Jatin Garg


Dr. NITIN AGARWAL
MBBS, MD
Regn. No. DMC-R-1436

47, Harsh Vihar, Pitampura, New Delhi-110034 | Ph.: 011-42480101, 9599913051
E-mail: oneplusul@gmail.com | Web.: www.oneplusul.in

Clinical correlation is essential for final diagnosis. • If test results are unsatisfactory please contact personally or on phone. • This report is for perusal of doctors only.
• All disputes Subject to Delhi Jurisdiction only. • Not for medicolegal purposes. • All congenital anomalies in a foetus may not be diagnosed in routine obstetric ultrasound.

ONEPLUS ULTRASOUND LAB

47, HARSH VIHAR, PITAMPURA, DELHI- 110034

Mr. JATIN GURI

Age : 31/M

Ref. by : MEDIWHEEL

Indication1 :

Indication2 :

Indication3 :

COMMENTS : Normal ECG.

ID : 2166

HUWI : 177/105

Recorded : 25-3-2023 10:41

Medication1 :

Medication2 :

Medication3 :

BPM : 77

BP : 134/82

P Axis : 76 deg

QRS Axis : 68 deg

T Axis : 60 deg

P duration : 96 msec

PR duration : 136 msec

QRS duration : 700 msec

QT interval : 320 msec

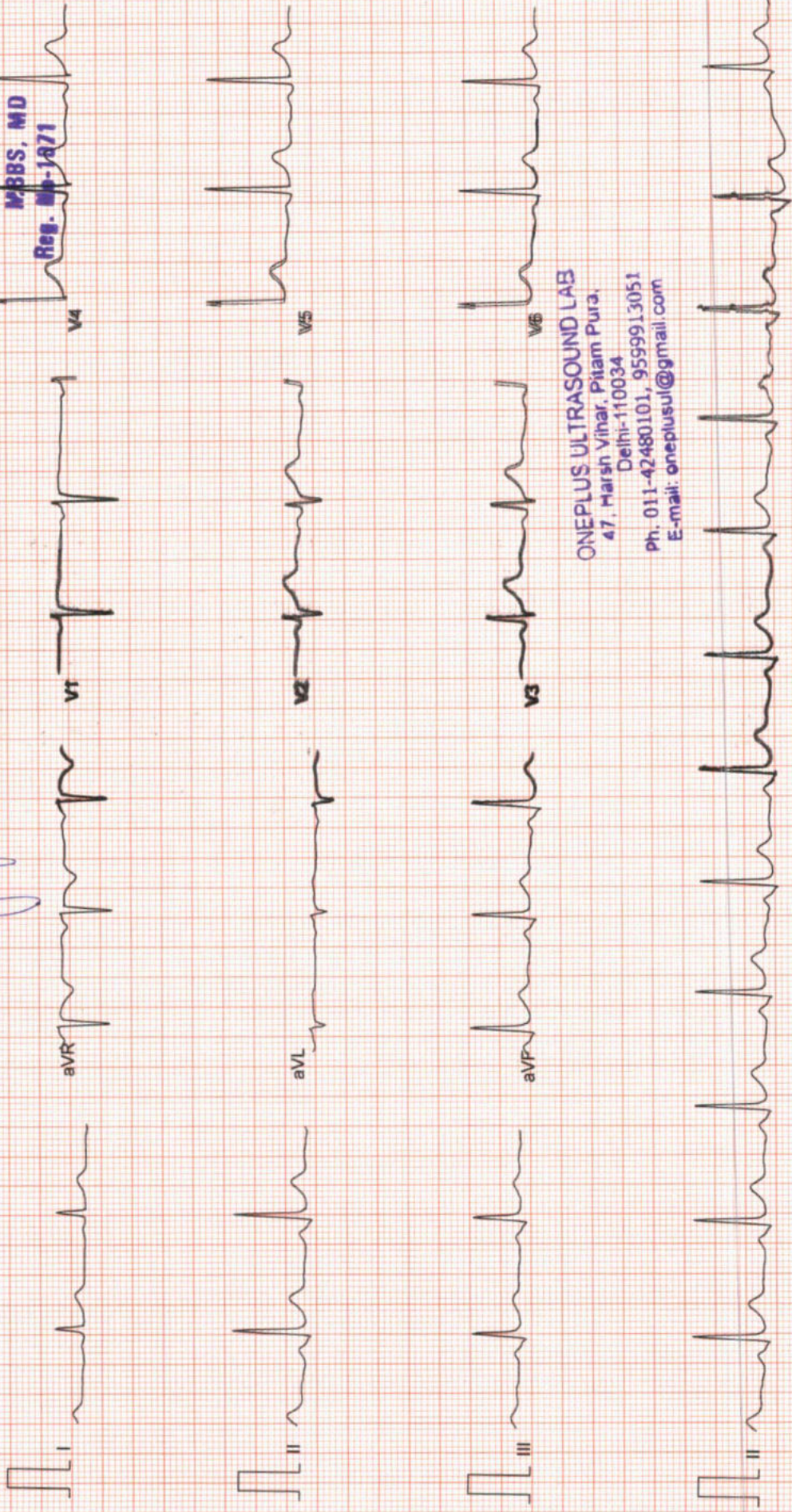
QTc interval : 349 msec

Raw E.C.G. (Seq)

Unconfirmed Report Reviewed By:

Cardiologist

[Signature]
Dr. P.K. GUPTA
M.B.B.S, MD
Reg. No. 1271



ONEPLUS ULTRASOUND LAB
47, Harsh Vihar, Pitam Pura,
Delhi-110034
ph. 011-42480101, 9599913051
E-mail: oneplusul@gmail.com

Filtered

25mm/sec 10mm/mV

CardiCom, INDIA

ONEPLUS ULTRASOUND LAB

47, HARSH VIHAR PITAMPURA DELHI 110034

Mr. JATIN GURI
 Age/Sex : 31/M
 Ref. by : MED/WHEEL
 Indication1 :
 Indication2 :
 Indication3 :

ID : 994
 Ht/Wt : 177/105
 Recorded : 25-3-2023 10:44

TREADMILL TEST SUMMARY REPORT

Protocol: BRUCE

History:

Medication1 :

Medication2 :

Medication3 :

PHASE	PHASE TIME	STAGE TIME	SPEED (Km./Hr.)	GRADE (%)	HR (BPM)	B.P. (mmHg)	RPP X100	II	ST LEVEL (mm) V2	V5	METS
SUPINE STANDING					87	134/82	116	1.0	1.3	1.0	
					75	134/82	100	0.9	1.6	1.0	
STAGE 1	2:59	2:59	2.70	10.00	97	134/82	129	0.6	0.8	0.7	4.80
STAGE 2	5:59	2:59	4.00	12.00	118	150/86	177	0.4	1.1	0.7	7.10
STAGE 3	8:59	2:59	5.40	14.00	140	160/90	224	0.2	1.1	0.6	10.00
STAGE 4	9:59	0:59	6.70	16.00	181	170/94	273	-0.5	0.7	0.0	11.32
PEAK EXER	10:03	1:03			163	170/94	277	-0.6	0.9	0.3	11.41
RECOVERY	2:59	2:59	0.00	0.00	71	134/84	95	0.3	1.0	0.3	

RESULTS

Exercise Duration : 10:03 Minutes
 Max Heart Rate : 163 bpm 86 % of target heart rate 189 bpm
 Max Blood Pressure : 170/94 mmHg
 Max Work Load : 11.41 METS

IMPRESSIONS

Negative for ischemic ECG

[Signature]

ONEPLUS ULTRASOUND LAB
 47, Harsh Vihar, Pitam Pura
 Delhi-110034
 Ph. 011-42480101, 955391303
 E-mail: oneplusul@gmail.com

[Signature]
DR. V. K. GUPTA
MBBS, MD
Cardiologist
Reg. No-10771

ONEPLUS ULTRASOUND LAB

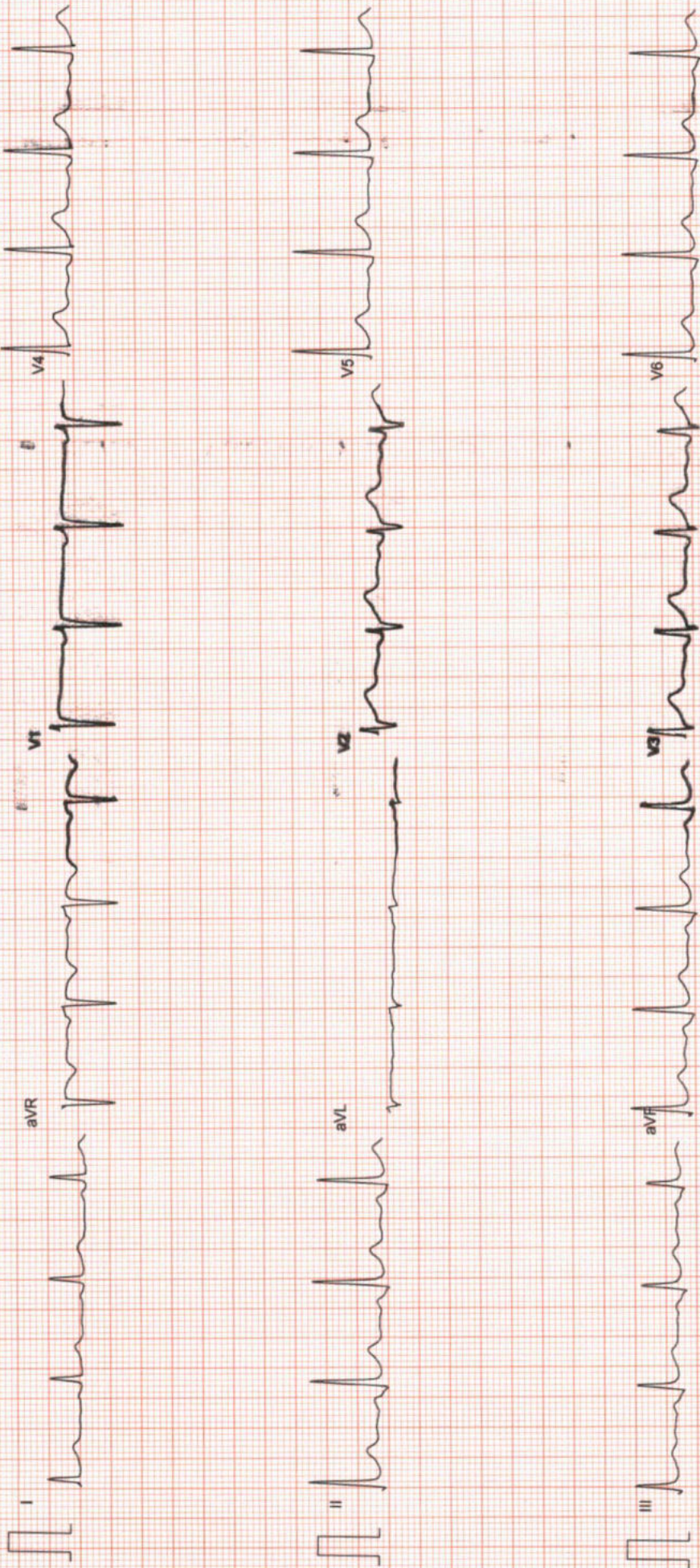
Mr. JATIN GURI
I.D. : 994
AGE/SEX : 31/M
RECORDED : 25-3-2023 10:44

SUPINE
PRETEST

RATE : 87 BPM
B.P. : 134/82 mmHg

ST @ 10mm/mV
80ms PostJ

RAW E.C.G.



ONEPLUS ULTRASOUND LAB
47, Marsh Vihar, Pitam Pura
Delhi-110034
Ph. 011-42480101, 9599913051
E-mail: oneplusul@gmail.com

ONEPLUS ULTRASOUND LAB

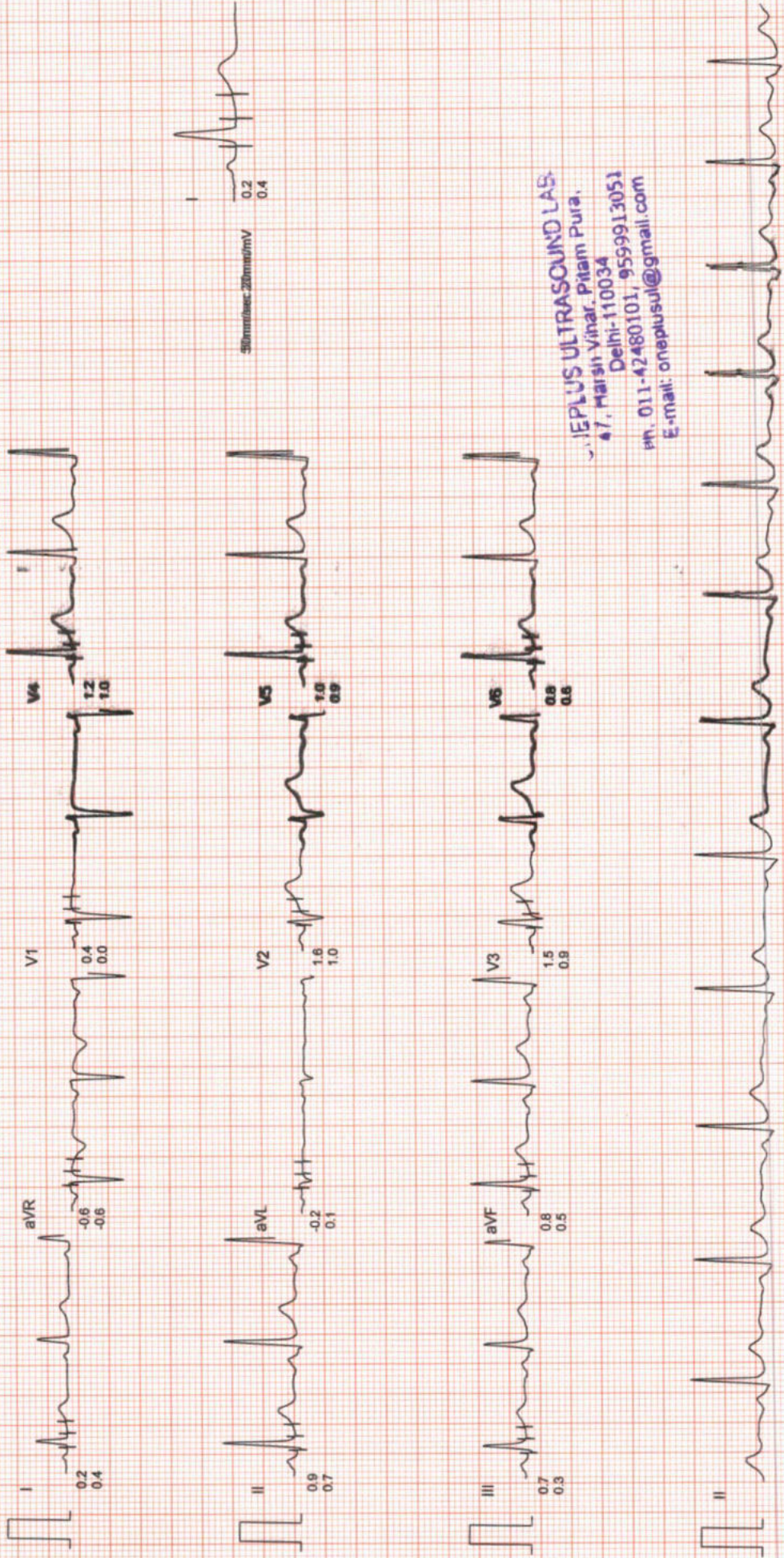
ST @ 10mm/mV
80ms PostJ

Mr. JATIN GURI
I.D. : 994
AGE/SEX : 31/M
RECORDED : 25-3-2023 10:44

RATE : 75 BPM
B.P. : 134/82 mmHg

STANDING
PRETEST

LINKED MEDIAN



ONEPLUS ULTRASOUND LAB.
47, Marshi Vihar, Pitam Pura,
Delhi-110034
Ph. 011-42480101, 9599913051
E-mail: oneplusul@gmail.com

ONEPLUS ULTRASOUND LAB

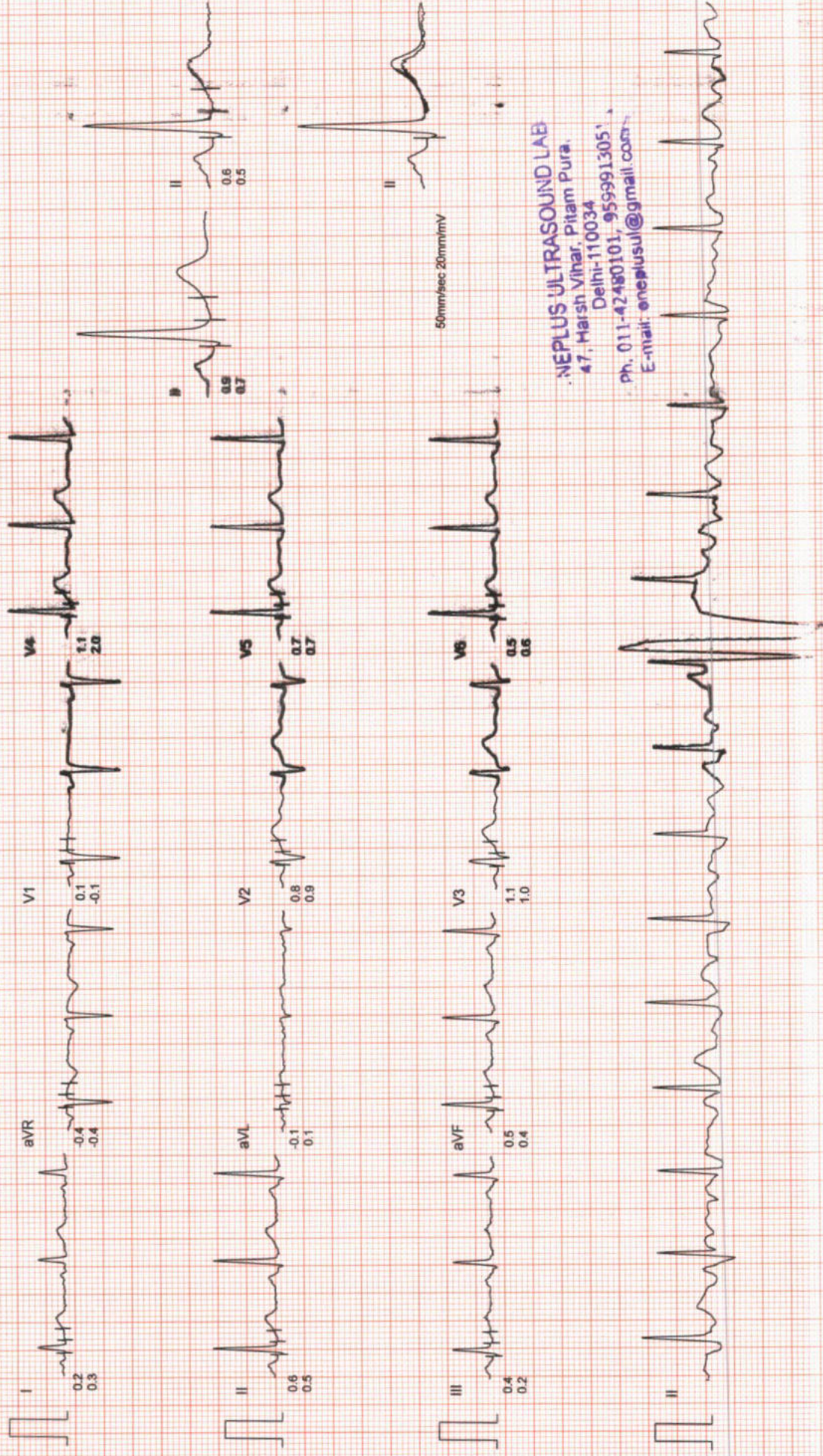
Mr. JATIN GURI
I.D. : 994
AGE/SEX : 31/M
RECORDED : 25-3-2023 10:44

BRUCE
EXERCISE 1
PHASE TIME : 2:59
STAGE TIME : 2:59

RATE : 97 BPM
B.P. : 134/82 mmHg

ST @ 10mm/mV
80ms PostJ
SPEED : 2.7 Km.Hr.
GRADE : 10.0 %

LINKED MEDIAN



NEPLUS ULTRASOUND LAB
47, Harsh Vihar, Pitam Pura,
Delhi-110034
Ph. 011-42480101, 9599913051
E-mail: oneplusul@gmail.com

ONEPLUS ULTRASOUND LAB

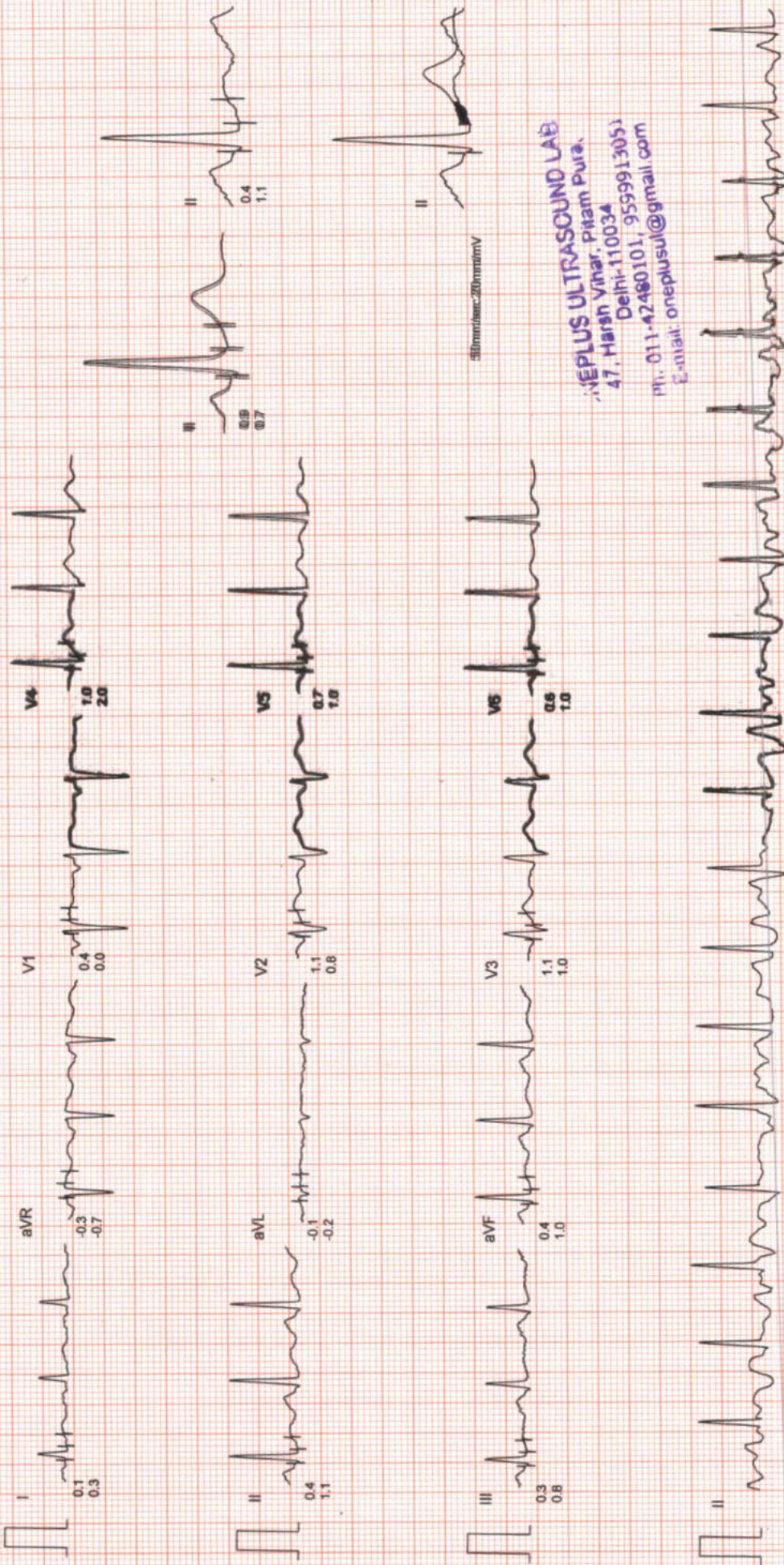
Mr. JATIN GURI
I.D. : 994
AGE/SEX : 31/M
RECORDED : 25-3-2023 10:44

BRUCE
EXERCISE 2
PHASE TIME : 5:59
STAGE TIME : 2:59

RATE : 118 BPM
B.P. : 150/86 mmHg

ST @ 10mm/mV
50ms PostJ
SPEED : 4.0 Km./Hr.
GRADE : 12.0 %

LINKED MEDIAN



ONEPLUS ULTRASOUND LAB
Dr. Harsh Vihar, Pitam Pura,
Delhi-110034
Ph: 011-42480101, 9599913051
E-mail: oneplusul@gmail.com

ONEPLUS ULTRASOUND LAB

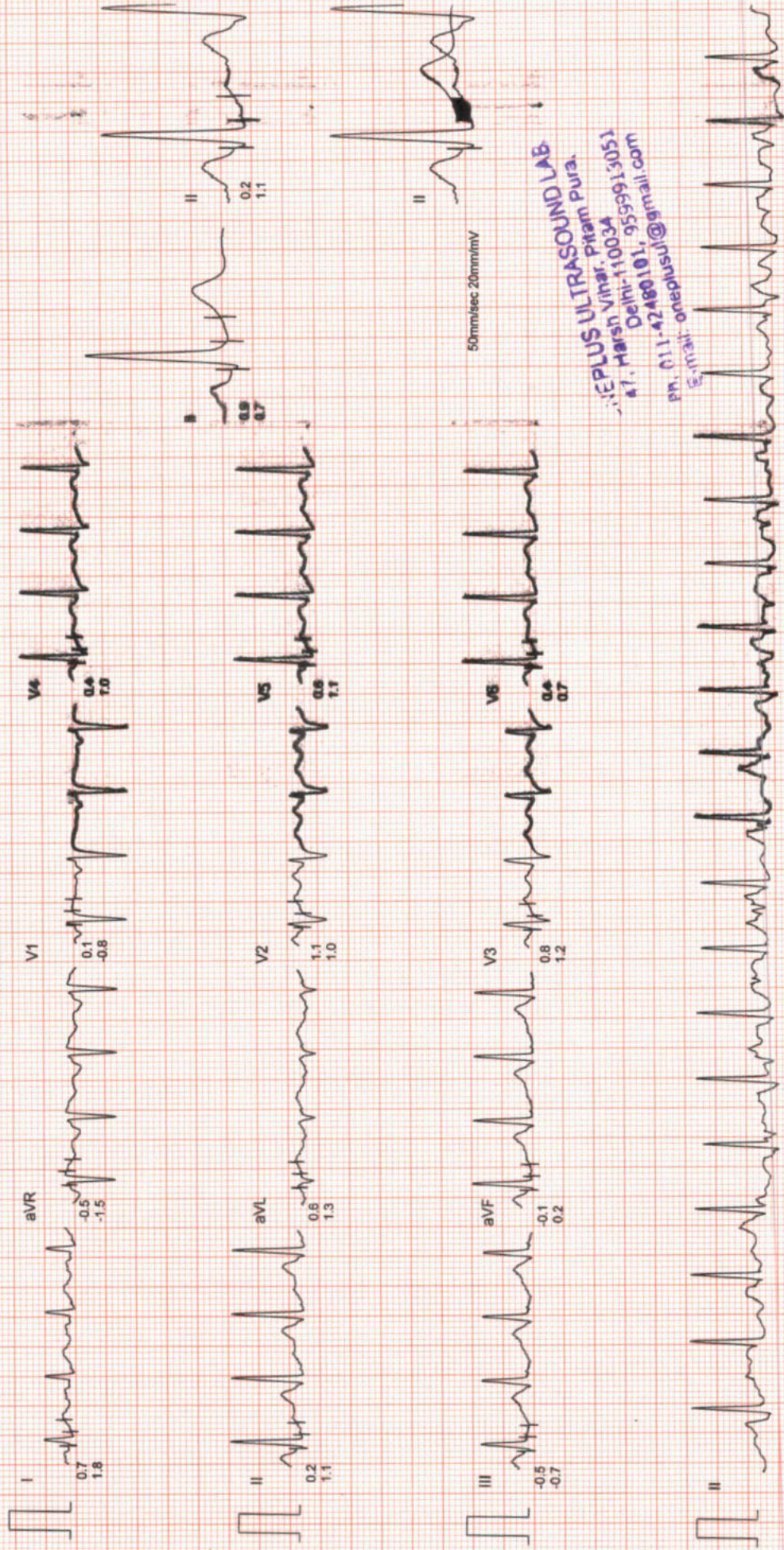
Mr. JATIN GURI
I.D. : 994
AGE/SEX : 31/M
RECORDED : 25-3-2023 10:44

BRUCE
EXERCISE 3
PHASE TIME : 8:59
STAGE TIME : 2:59

RATE : 140 BPM
B.P. : 160/90 mmHg

ST @ 10mm/mV
80ms PostJ
SPEED : 5.4 Km./hr.
GRADE : 14.0 %

LINKED MEDIAN



50mm/sec 20mm/mV

ONEPLUS ULTRASOUND LAB
Dr. Harsh Vihar, Pitam Pura
Delhi-110034
Ph. 011-42480101, 9559913051
Email: oneplusul@gmail.com

ONEPLUS ULTRASOUND LAB

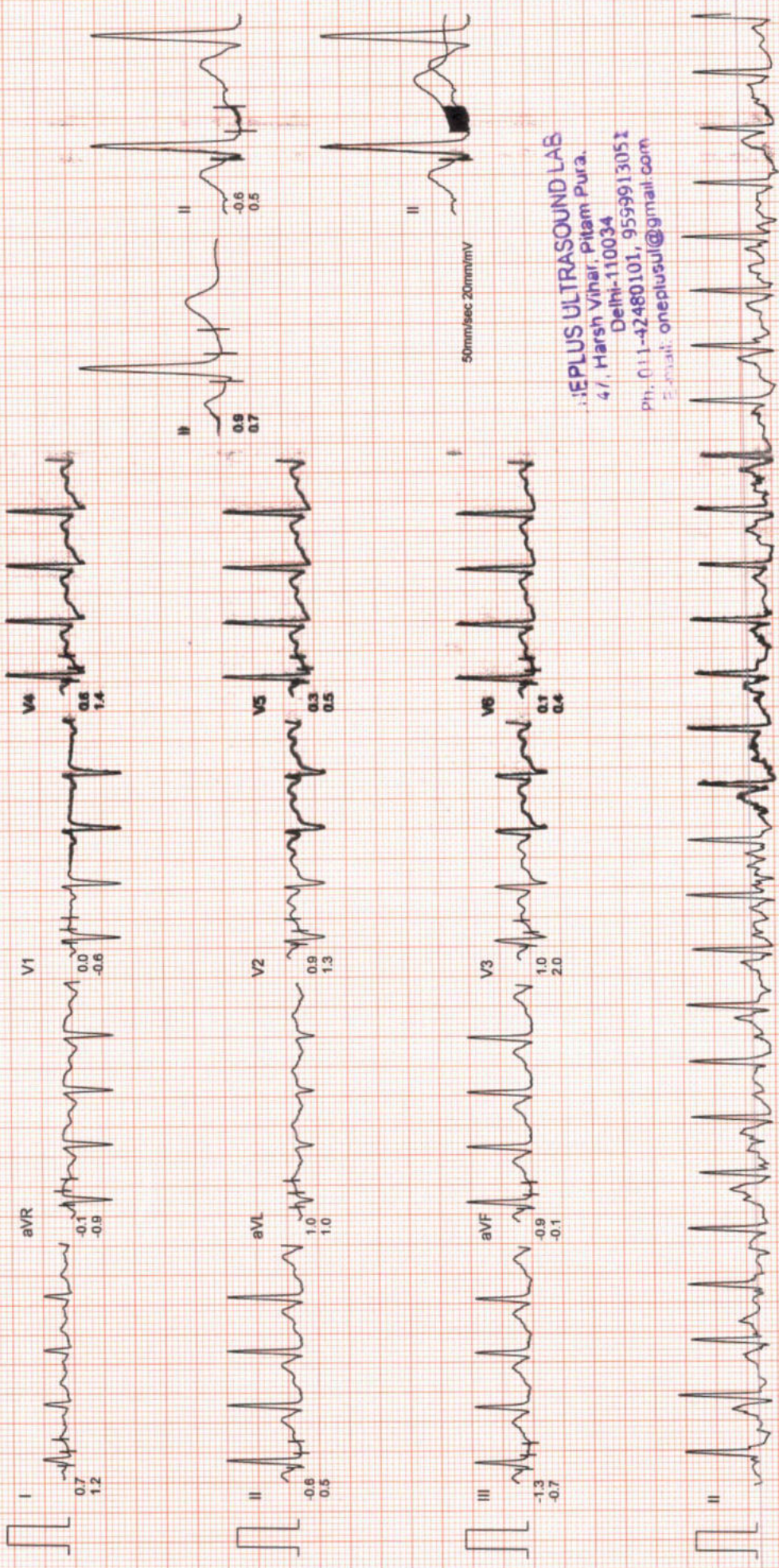
Mr. JATIN GURI
I.D. : 994
AGE/SEX : 31/M
RECORDED : 25-3-2023 10:44

BRUCE
PEAK EXER
PHASE TIME : 10:03
STAGE TIME : T:03

RATE : 163 BPM
B.P. : 170/94 mmHg

ST @ 10mm/mV
80ms PostJ
SPEED : 6.7 Km./Hr.
GRADE : 16.0 %

LINKED MEDIAN



ONEPLUS ULTRASOUND LAB
47, Harsh Vihar, Pitam Pura,
Delhi-110034
Ph: 011-42480101, 9599913052
E-mail: oneplusul@gmail.com

ONEPLUS ULTRASOUND LAB

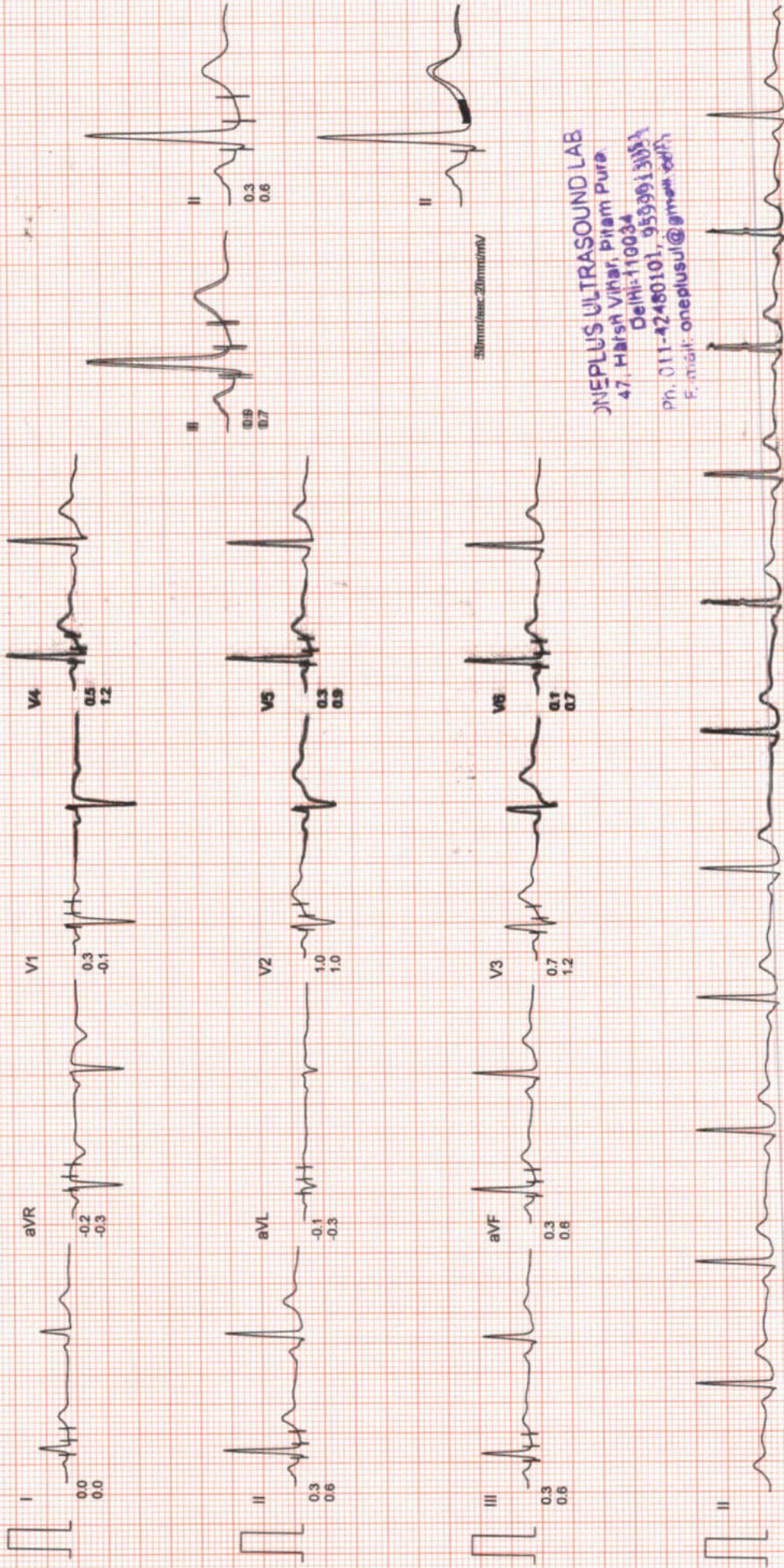
Mr. JATIN GURI
I.D. : 994
AGE/SEX : 31/M
RECORDED : 25-3-2023 10:44

BRUCE
RECOVERY
PHASE TIME: 2:59

RATE : 71 BPM
B.P. : 134/84 mmHg

ST @ 10mm/mV
80ms PostJ
SPEED : 0.0 Km./Hr.
GRADE : 0.0 %

LINKED MEDIAN



ONEPLUS ULTRASOUND LAB
47, Harsh Vihar, Pitam Pura
Delhi-110034
Ph. 011-42460101, 9599913053
E-mail: oneplusul@oneplus.com

ONEPLUS ULTRASOUND LAB

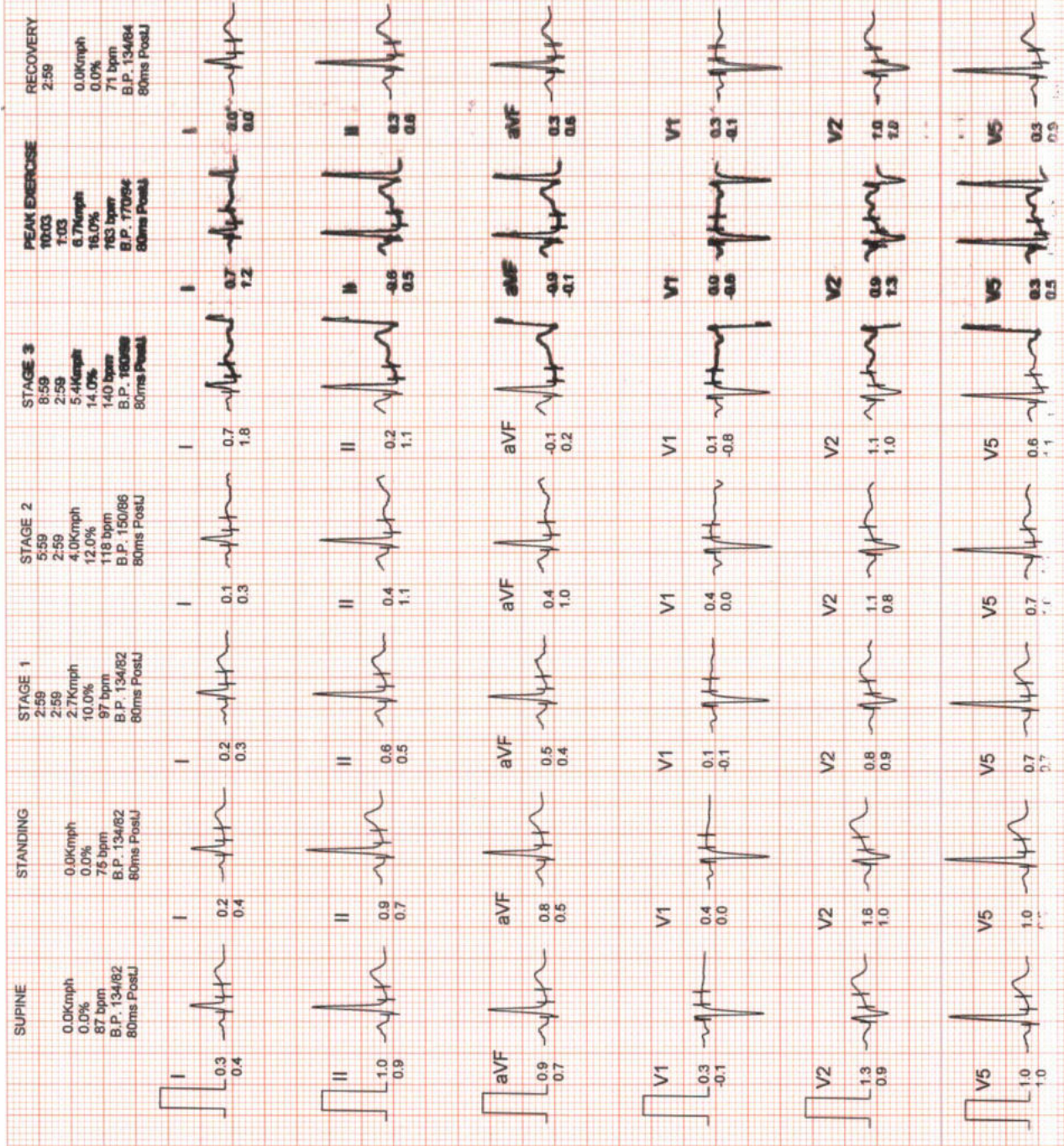
I.D. : 994

AGE/SEX : 31/M

RECORDED : 25-3-2023 10:44

AVG E.C.G.

Mr. JATIN GURI



ONEPLUS ULTRASOUND LAB
47, Harsh Vihar, Pitam Pura,
Delhi-110034
Ph. 011-42480101, 9599913052
E-mail: oneplusul@gmail.com

ONEPLUS ULTRASOUND LAB

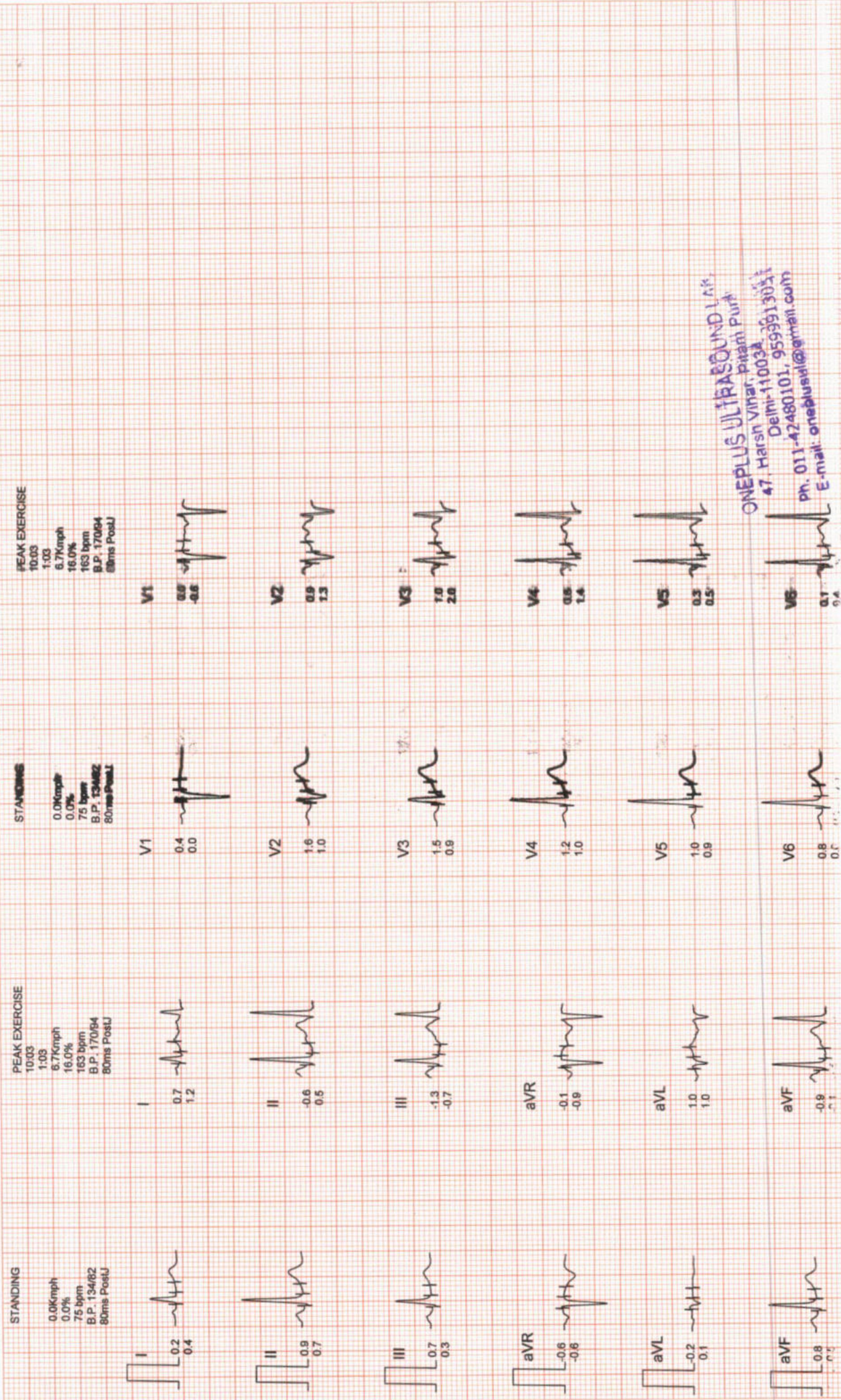
AGESEX : 31/M

I.D. : 994

Mr. JATIN GURI

RECORDED : 25-3-2023 10:44

COMPARISON REPORT



ONEPLUS ULTRASOUND LAB
47, Harsh Vihar, Pitamhi Puri
Delhi-110034
Ph. 011-42480101, 9599913051
E-mail: oneplusid@gmail.com



OnePLUS Ultrasound Lab

QUALITY FIRST... ALWAYS!

Dr. Nitin Agarwal
Pathologist & Director
Ex. Sr. Res. MAMC
& Lok Nayak Hospital
Ex. Chief of Lab Dr. Lal Path Labs.

Dr. Pooja (Garg) Agarwal
Radiologist & Director
MAMC & Lok Nayak Hospital



NAME	:Mr. JATIN GURI	Barcode No	:10140825
AGE/GENDER	:31 YRS/Male	SPECIMEN DATE	:25/Mar/2023 08:30AM
PATIENT ID	:111315	SPECIMEN RECEIVED	:25/Mar/2023 11:55AM
REFERRED BY	:Dr. MEDIWHEEL	REPORT DATE	:25/Mar/2023 01:15PM
CENTRE NAME	:ONEPLUS ULTRASOUND LAB	LAB NO.	:012303250008

Test Name	Result	Unit	Ref. Range
-----------	--------	------	------------

HAEMATOLOGY

Medi Wheel Health checkup < 40 Male

Glycosylated Hemoglobin (HbA1c)	5.3	%	Non Diabetic adults <5.7 Prediabetic (at risk) 5.7-6.4 Diabetes >6.4
----------------------------------------	-----	---	----------------------------------------------------------------------------

Estimated average blood glucose (eag) 105

Reference range (mg/dl):

90 - 120:Excellent control, 121 - 150:Good Control, 151 - 180:Average Control, 181 - 210:Action Suggested

>211:Panic value

BLOOD GROUP (ABO)	B
Rh typing	POSITIVE

NOTE :

- * Apart from major A,B,H antigens which are used for ABO grouping and Rh typing, many minor blood group antigens exist. Agglutination may also vary according to titre of antigen and antibody.
- * So before transfusion, reconfirmation of blood group as well as cross-matching is needed.
- * Presence of maternal antibodies in newborns, may interfere with blood grouping.
- * Auto agglutination (due to cold antibody, falciparum malaria, sepsis, internal malignancy etc.) may also cause erroneous result.

CBC

Haemoglobin	13.5	g/dl	13.0-17.0
Total Leucocyte Count	5900	/cumm	4000-10000
Differential leucocyte count			
Neutrophils	77.3	%	40-80
Lymphocyte	18.10	%	20-40
Monocytes	2.60	%	2-10
Eosinophils	1.6	%	1-6
Basophils	0.4	%	0-2
RBC count	4.90	million/cumm	4.5 - 5.5

Checked By.

Dr NITIN AGARWAL
M B B S . MD (Path)
DMC/R/01436

DR. NITIN AGARWAL
MBBS,MD(PATHOLOGIST)

47, Harsh Vihar, Pitampura, New Delhi-110034 | Ph.: 011-42480101, 9599913051

E-mail: oneplusul@gmail.com | Web.: www.oneplusul.in

Page 1 of 5



OnePLUS

Ultrasound Lab

QUALITY FIRST... ALWAYS!

Dr. Nitin Agarwal

Pathologist & Director
Ex. Sr. Res. MAMC
& Lok Nayak Hospital
Ex. Chief of Lab Dr. Lal Path Labs.

Dr. Pooja (Garg) Agarwal

Radiologist & Director
MAMC & Lok Nayak Hospital



NAME	:Mr. JATIN GURI	Barcode No	:10140825
AGE/GENDER	:31 YRS/Male	SPECIMEN DATE	:25/Mar/2023 08:30AM
PATIENT ID	:111315	SPECIMEN RECEIVED	:25/Mar/2023 11:55AM
REFERRED BY	:Dr. MEDIWHEEL	REPORT DATE	:25/Mar/2023 01:15PM
CENTRE NAME	:ONEPLUS ULTRASOUND LAB	LAB NO.	:012303250008

Test Name	Result	Unit	Ref. Range
PCV(Hematocrit)	44.4	%	40-50
MCV	90.9	fL	83-101
MCH	27.6	Pg	27-32
MCHC	30.4	G/dL	32-35
Platelet count	187000	/cumm	150000-450000
RDW-CV	13.6	%	11.4-14.0
ESR(WESTGRENs METHOD)	10	mm in 1st hr	0-20

BIOCHEMISTRY

<u>Blood sugar fasting</u>	88	mg/dL	70-110
<u>Bun (blood urea nitrogen)</u>	15.30	mg/dl	8.9-21.6
<u>Uric acid, serum</u>	4.2	mg/dl	3.5-7.2
<u>Creatinine, serum</u>	0.6	mg/dl	0.60-1.2

LFT(LIVER FUNCTION TEST)

Bilirubin Total	0.62	mg/dl	0.1-1.2
Bilirubin Conjugated	0.35	mg/dl	0-0.4
Bilirubin Unconjugated	0.27	mg/dl	up to 0.7
SGOT (AST)	41	U/L	0-46
SGPT (ALT)	44	U/L	0-49
Alkaline phosphatase	95	U/L	40-129
Gamma glutamyl transpeptidase	28	U/L	10-45
Total Protein	7.5	gm/dl	6.60 - 8.70
Albumin serum	4.2	g/dL	3.0-5.2
Globulin	3.30	gm/dl	1.8-3.4
Albumin/Globulin Ratio	1.27		1.10 - 2.50

LIPID PROFILE

Cholesterol	211	mg/dl	50-200
Triglycerides	58	mg/dL	25-150
HDL Cholesterol	47	mg/dL	40 - 60

Checked By.

Dr NITIN AGARWAL
M B B S , MD (Path)
DMC/R/01436 MBBS,MD(PATHOLOGIST)

47, Harsh Vihar, Pitampura, New Delhi-110034 | Ph.: 011-42480101, 9599913051

E-mail: oneplusul@gmail.com | Web.: www.oneplusul.in

Page 2 of 5

Clinical correlation is essential for final diagnosis. • If test results are unsatisfactory please contact personally or on phone. • This report is for perusal of doctors only.
• All disputes Subject to Delhi Jurisdiction only. • Not for medicolegal purposes. • All congenital anomalies in a foetus may not be diagnosed in routine obstetric ultrasound.



OnePLUS Ultrasound Lab

Dr. Nitin Agarwal
Pathologist & Director
Ex. Sr. Res. MAMC
& Lok Nayak Hospital
Ex. Chief of Lab Dr. Lal Path Labs.

Dr. Pooja (Garg) Agarwal
Radiologist & Director
MAMC & Lok Nayak Hospital



QUALITY FIRST... ALWAYS!

NAME	:Mr. JATIN GURI	Barcode No	:10140825
AGE/GENDER	:31 YRS/Male	SPECIMEN DATE	:25/Mar/2023 08:30AM
PATIENT ID	:111315	SPECIMEN RECEIVED	:25/Mar/2023 11:55AM
REFERRED BY	:Dr. MEDIWHEEL	REPORT DATE	:25/Mar/2023 01:15PM
CENTRE NAME	:ONEPLUS ULTRASOUND LAB	LAB NO.	:012303250008

Test Name	Result	Unit	Ref. Range
LDL cholesterol	152	mg/dL	<130
VLDL cholesterol	11.6	mg/dL	5-40
Cholesterol/HDL Ratio	4.5		Low Risk 3.3-4.97 Average Risk 4.4-7.1 Moderate Risk 7.1-11.0 High Risk >11.0
LDL/HDL Ratio	3.2		0 - 3.55

According to ATP III and NCEP guidelines

Parameter	Normal	Desirable	Borderline	High
Total cholesterol	<200		200-239	240
Triglycerides	<150	150-199	200-499	500
LDL	Optimal <100 Near Optimal 100-129	130-159	160-180	190
HDL	<40 : LOW 60 : HIGH			

BUN/Creatinine ratio

Bun (blood urea nitrogen)	15.20	mg/dl	8.9-21.6
CREATININE	0.50	mg/dl	0.30-1.10
BUN/Creatinine ratio	30.40		10.0 - 20.0

ENDOCRINOLOGY

THYROID PROFILE(T3,T4,TSH)

Triiodothyronine total [t3]	0.94	ng/dl	0.52-1.9
Thyroxine total [t4]	4.90	µg/dl	4.4 - 10.8
TSH (Thyroid Stimulating Hormone)	1.90	µIU/ml	0.25-5.0

AGE WISE VARIATION IN TSH

AGE	TSH(µIU/ml)	AGE	TSH(µIU/ml)
-----	-------------	-----	-------------

Checked By.

Dr. NITIN AGARWAL
M B B S, MD (P)
DMC/R/01436
DR. NITIN AGARWAL
MBBS, MD (PATHOLOGIST)

47, Harsh Vihar, Pitampura, New Delhi-110034 | Ph.: 011-42480101, 9599913051

E-mail: oneplusul@gmail.com | Web.: www.oneplusul.in

Page 3 of 5



OnePLUS

Ultrasound Lab

QUALITY FIRST... ALWAYS!

Dr. Nitin Agarwal
Pathologist & Director
Ex. Sr. Res. MAMC
& Lok Nayak Hospital
Ex. Chief of Lab Dr. Lal Path Labs.

Dr. Pooja (Garg) Agarwal
Radiologist & Director
MAMC & Lok Nayak Hospital



NAME	:Mr. JATIN GURI	Barcode No	:10140825
AGE/GENDER	:31 YRS/Male	SPECIMEN DATE	:25/Mar/2023 08:30AM
PATIENT ID	:111315	SPECIMEN RECEIVED	:25/Mar/2023 11:55AM
REFERRED BY	:Dr. MEDIWHEEL	REPORT DATE	:25/Mar/2023 01:15PM
CENTRE NAME	:ONEPLUS ULTRASOUND LAB	LAB NO.	:012303250008

Test Name	Result	Unit	Ref. Range
1-4 weeks	1.00 - 19.0	16-20 yrs	0.25 - 5.0
1-12 mths	1.70 - 9.1	21 - 80 yrs	0.25 - 5.0
1-5 yrs	0.80 - 8.2	I st trimester	0.25 - 5.0
6-10 yrs	0.25 - 5.0	II nd trimester	0.50 - 5.0
11-15 yrs	0.25 - 5.0	II rd trimester	0.4 - 6.0

Reference ranges - Interpretation of Diagnostic tests - (Jacques Wallach)

1. Primary hypothyroidism is accompanied by depressed serum T3 and T4 values and elevated serum TSH level.
2. Primary hyperthyroidism is accompanied by elevated serum T3 and T4 levels along with depressed TSH values.
3. Slightly elevated T3 levels may be found in pregnancy and estrogen therapy, while depressed levels may be encountered in severe illness, renal failure and during therapy with drugs like propranolol and propyl thiouracil.
4. Although elevated TSH levels are nearly always indicative of primary hypothyroidism, and may be seen in secondary thyrotoxicosis

CLINICAL PATHOLOGY

URINE ROUTINE

Physical examination

Quantity	30	ML
Colour	PALE YELLOW	
Transparency	CLEAR	CLEAR
Sp.gravity	1.015	1.010-1.030
pH	6.00	
Reaction	ACIDIC	ACIDIC

Chemical examination

Urine protein	NIL	NIL
Urine sugar	NIL	NIL
Bilirubin, urine	NEGATIVE	NEGATIVE
Urobilinogen	NORMAL	NORMAL
Ketones	NEGATIVE	NEGATIVE

Microscopic examination

WBCs cells.	1-2	/HPF	0-2
-------------	-----	------	-----

Checked By.

Dr. NITIN AGARWAL
MBBS, MD (Path)
DMC/R/01436
DR. NITIN AGARWAL
MBBS, MD (PATHOLOGIST)

47, Harsh Vihar, Pitampura, New Delhi-110034 | Ph.: 011-42480101, 9599913051

E-mail: oneplusul@gmail.com | Web.: www.oneplusul.in

Page 4 of 5

Clinical correlation is essential for final diagnosis. • If test results are unsatisfactory please contact personally or on phone. • This report is for perusal of doctors only. • All disputes Subject to Delhi Jurisdiction only. • Not for medicolegal purposes. • All congenital anomalies in a foetus may not be diagnosed in routine obstetric ultrasound.



OnePLUS Ultrasound Lab

Dr. Nitin Agarwal
Pathologist & Director
Ex. Sr. Res. MAMC
& Lok Nayak Hospital
Ex. Chief of Lab Dr. Lal Path Labs.

Dr. Pooja (Garg) Agarwal
Radiologist & Director
MAMC & Lok Nayak Hospital



QUALITY FIRST... ALWAYS!			
NAME	:Mr. JATIN GURI	Barcode No	:10140825
AGE/GENDER	:31 YRS/Male	SPECIMEN DATE	:25/Mar/2023 08:30AM
PATIENT ID	:111315	SPECIMEN RECEIVED	:25/Mar/2023 11:55AM
REFERRED BY	:Dr. MEDIWHEEL	REPORT DATE	:25/Mar/2023 01:15PM
CENTRE NAME	:ONEPLUS ULTRASOUND LAB	LAB NO.	:012303250008

Test Name	Result	Unit	Ref. Range
Epithelial cells	1-2	/HPF	NIL
R.B.C.	NIL	/HPF	NIL
Casts	NIL	/HPF	NIL
Crystals	NIL	/HPF	NIL
Bacteria	NIL	/HPF	NIL
Others.	NIL	NIL	NIL

*** End Of Report ***

Checked By.

Dr NITIN AGARWAL
M B B S , MD (Path)
DMC/R/01436

DR. NITIN AGARWAL
MBBS,MD(PATHOLOGIST)

47, Harsh Vihar, Pitampura, New Delhi-110034 | Ph.: 011-42480101, 9599913051

E-mail: oneplusul@gmail.com | Web.: www.oneplusul.in

Page 5 of 5

Clinical correlation is essential for final diagnosis. • If test results are unsatisfactory please contact personally or on phone. • This report is for perusal of doctors only.
• All disputes Subject to Delhi Jurisdiction only. • Not for medicolegal purposes. • All congenital anomalies in a foetus may not be diagnosed in routine obstetric ultrasound.



OnePLUS
Ultrasound Lab
— QUALITY FIRST... ALWAYS! —

Dr. Nitin Agarwal
Pathologist & Director
Ex. Sr. Res. MAMC
& Lok Nayak Hospital
Ex. Chief of Lab Dr. Lal Path Labs.

Dr. Pooja (Garg) Agarwal
Radiologist & Director
MAMC & Lok Nayak Hospital

Name	: Mr. JATIN GURI	Age/Sex	: 31 YRS/Male
Ref. By	: Dr. MEDIWHEEL	Lab No	: 012303250008
Date	: 25-Mar-2023	Patient ID	: LSHHI111315

ULTRASOUND EXAMINATION----WHOLE ABDOMEN

Liver is normal in size (14.3 cm) and outline with normal echopattern. No abscess or mass lesion seen. Hepatic veins, portal vein, IVC and aorta are normal. Intrahepatic biliary radicles are not dilated. CBD is normal in caliber.

Gall bladder is well distended with anechoic lumen. Wall thickness is normal.

Both kidneys are normal in size, shape, position, outline and echopattern. Corticomedullary differentiation is maintained. No pelvicalyceal dilation or calculus or mass lesion is seen.

Spleen is normal in size and echotexture. No mass lesion seen.

Pancreas is normal in size, outline and echotexture.

Urinary bladder is normal in shape and position. No evidence of intravesical stone or mass seen.

Prostate is normal in size, shape and echopattern.

Prostate measures 3.3 x 2.5 x 1.8 cm. **Weight of prostate is 7.9 grams.**

No abnormal bowel wall thickening seen in right iliac fossa.

No free fluid seen anywhere in abdomen.

IMPRESSION: Normal Study.

Dr. POOJA GARG
M.B.B.S., D.M.R.D.
Reg No. DMC/R/03398
Radiologist
DR. POOJA GARG
RADIOLOGIST
REG. NO. DMC/R/03398

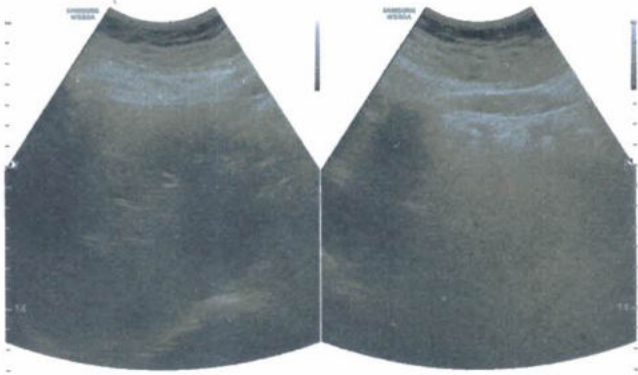Type By : darshita

47, Harsh Vihar, Pitampura, New Delhi-110034 | Ph.: 011-42480101, 9599913051

E-mail: oneplusul@gmail.com | Web.: www.oneplusul.in

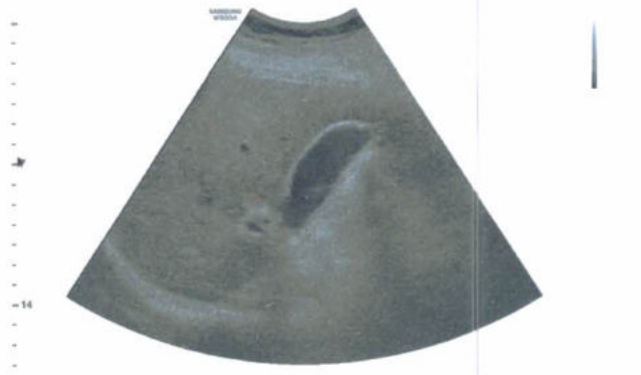WSSDA MR JATIN 30/M OnePlus Ultrasound Lab MI 1.4 25-03-2023
CA1-7A / Abdomen / FR 24Hz Tls 0.1 10:32:05 AM

20 G66 DR135-FAB-P90 Frq Gen. 17.0cm



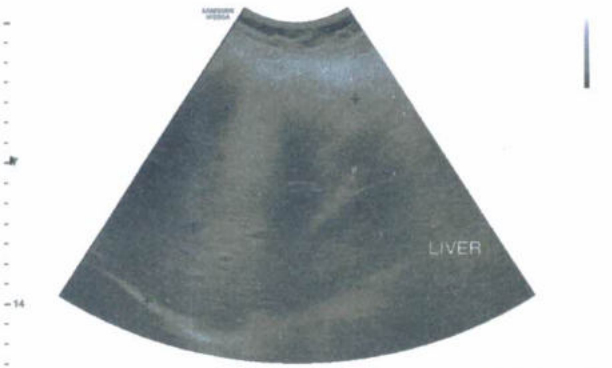WSSDA MR JATIN 30/M OnePlus Ultrasound Lab MI 1.4 25-03-2023
CA1-7A / Abdomen / FR 24Hz Tls 0.1 10:32:13 AM

20 G66 DR135-FAB-P90 Frq Gen. 17.0cm



WSSDA MR JATIN 30/M OnePlus Ultrasound Lab MI 1.4 25-03-2023
CA1-7A / Abdomen / FR 24Hz Tls 0.1 10:32:22 AM

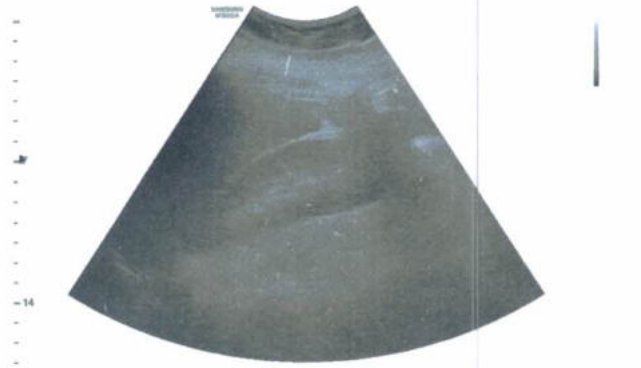
20 G66 DR135-FAB-P90 Frq Gen. 17.0cm



D1 14.30 cm

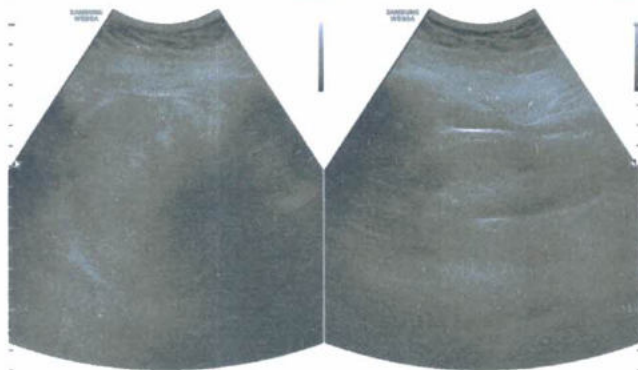WSSDA MR JATIN 30/M OnePlus Ultrasound Lab MI 1.4 25-03-2023
CA1-7A / Abdomen / FR 24Hz Tls 0.1 10:32:43 AM

20 G66 DR135-FAB-P90 Frq Gen. 17.0cm



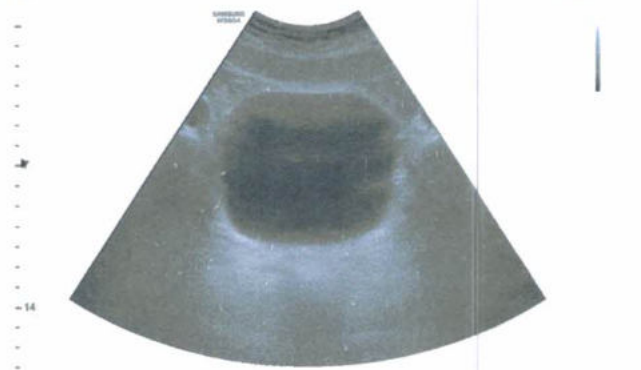
WSSDA MR JATIN 30/M OnePlus Ultrasound Lab MI 1.4 25-03-2023
CA1-7A / Abdomen / FR 24Hz Tls 0.1 10:33:07 AM

20 G68 DR135-FAB-P90 Frq Gen. 17.0cm



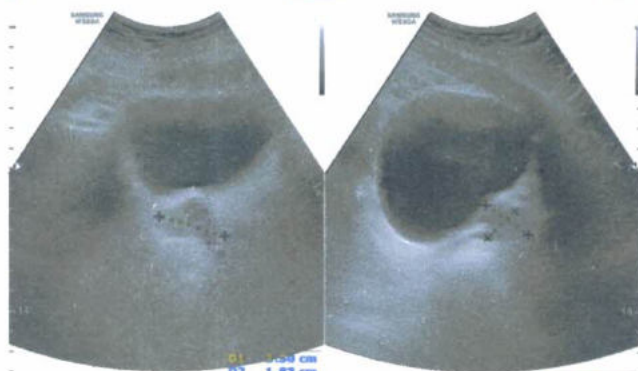
WSSDA MR JATIN 30/M OnePlus Ultrasound Lab MI 1.4 25-03-2023
CA1-7A / Abdomen / FR 24Hz Tls 0.1 10:33:23 AM

20 G66 DR135-FAB-P90 Frq Gen. 17.0cm



WSSDA MR JATIN 30/M OnePlus Ultrasound Lab MI 1.4 25-03-2023
CA1-7A / Abdomen / FR 24Hz Tls 0.1 10:33:36 AM

20 G68 DR135-FAB-P90 Frq Gen. 17.0cm

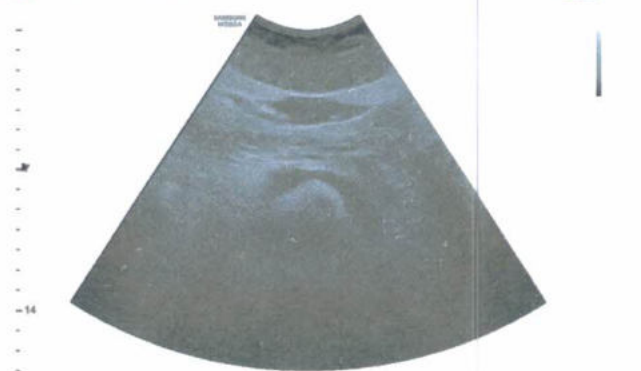


D1 10.25 cm
D2 1.83 cm
D3 3.32 cm
Vol. 7.96 ml

D1 2.90 cm
D2 1.83 cm

WSSDA MR JATIN 30/M OnePlus Ultrasound Lab MI 1.4 25-03-2023
CA1-7A / Abdomen / FR 24Hz Tls 0.1 10:33:43 AM

20 G66 DR135-FAB-P90 Frq Gen. 17.0cm



Name	: Mr. JATIN GURI	Age/Sex	: 31 YRS/Male
Ref. By	: Dr. MEDIWHEEL	Lab No	: 012303250008
Date	: 25-Mar-2023	Patient ID	: LSHHI111315

X-ray-Chest PA view

Bony cage and soft tissues are normal.
Cardiothoracic ratio is normal.
Mediastinum is normal.
Both hila are normal.
Both costophrenic angles are clear.
Both domes of diaphragm are normal.
Lung fields are clear. No parenchymal lesion seen.

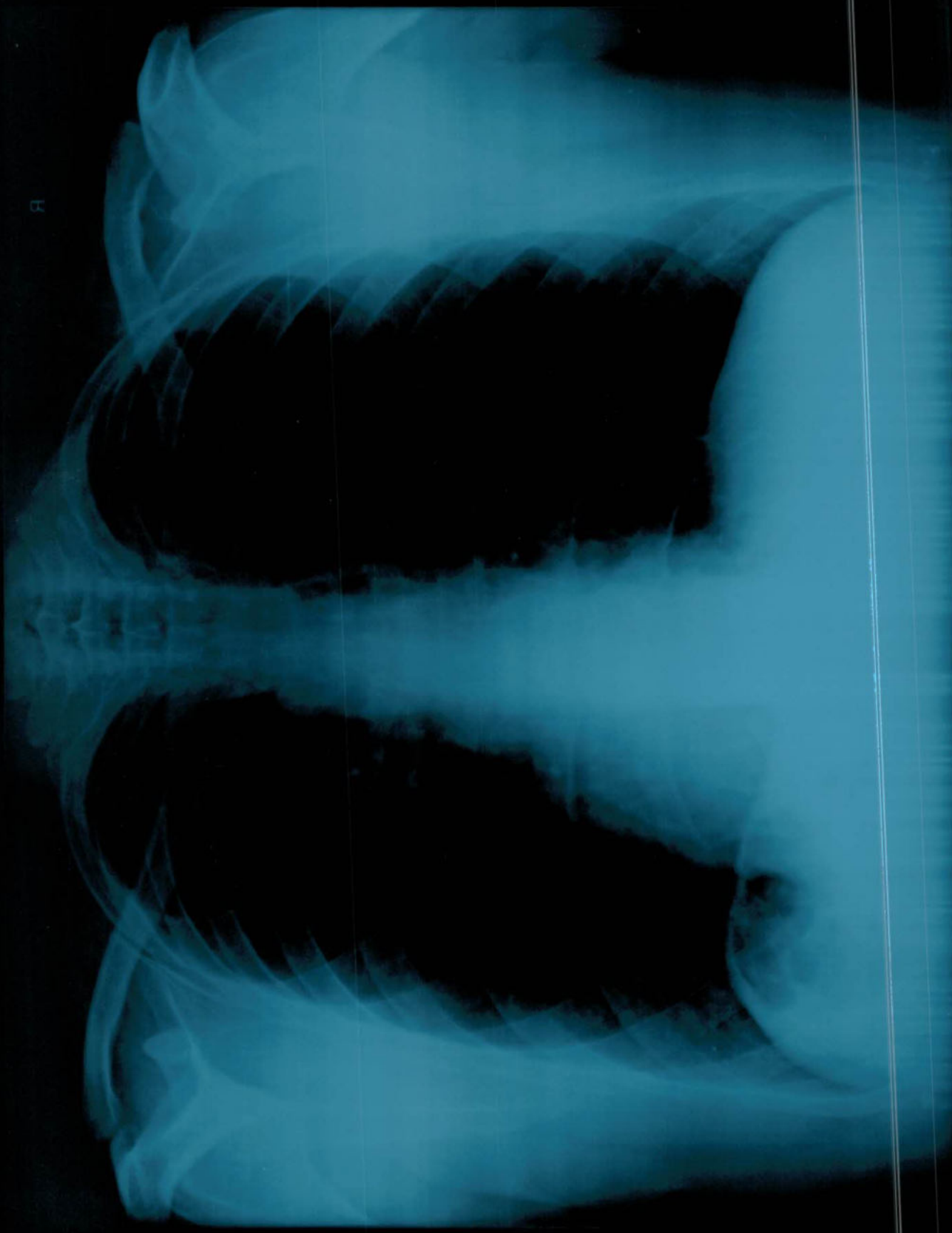
IMPRESSION: Normal Study.

DR. POOJA GARG
RADIOLOGIST
M.B.B.S., REG NO- DMC/R/03398
Reg No. DMC/R/03398
Radiologist

Type By : darshita

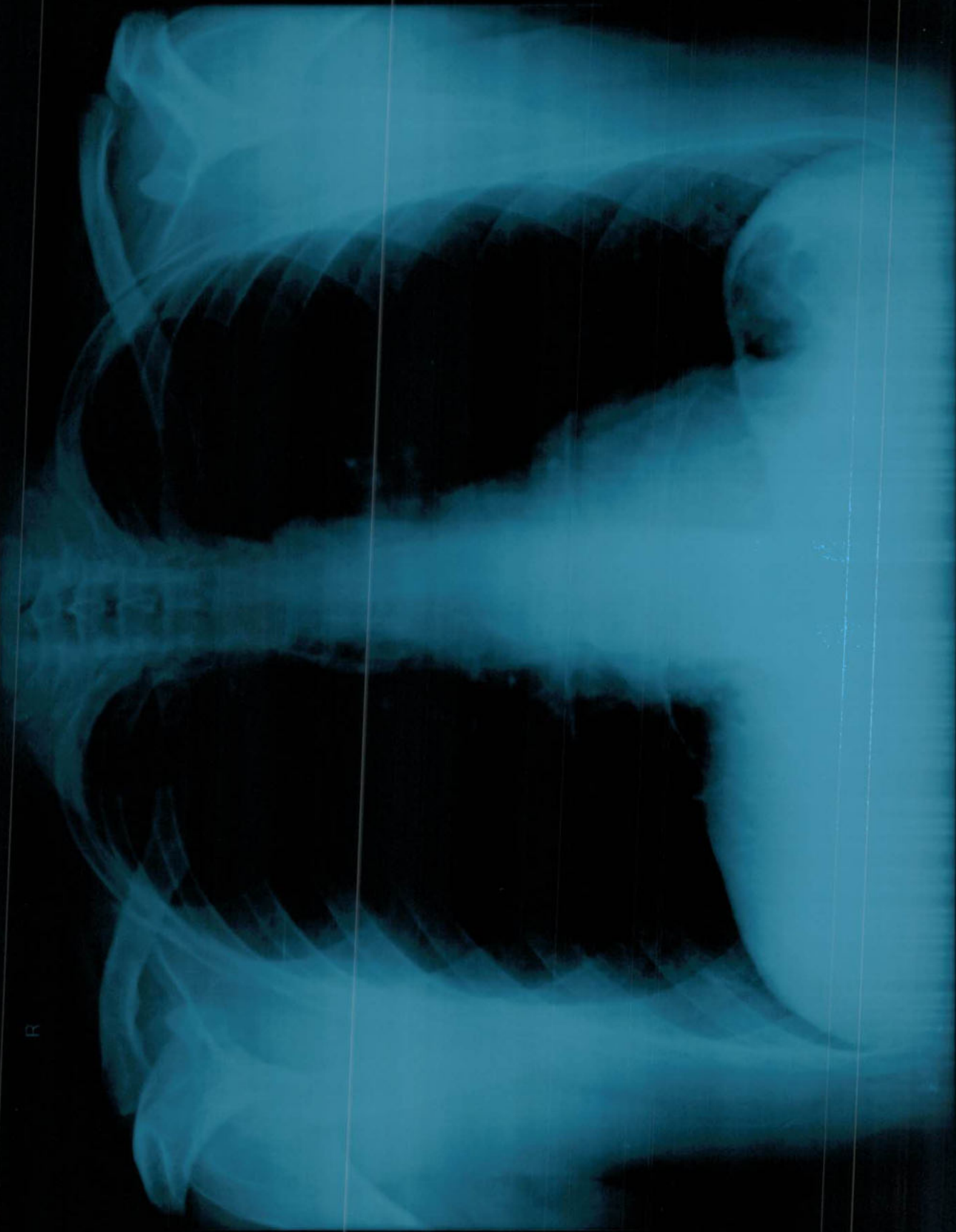
47, Harsh Vihar, Pitampura, New Delhi-110034 | Ph.: 011-42480101, 9599913051
E-mail: oneplusul@gmail.com | Web.: www.oneplusul.in

ONEPLUS MTRASOUND LAB 41 HARSH AHWAR PILLAMPILVA
MR JALIN GURI 31 YRS 52/03/5053 M CHEST PA VIEW 3/52/5053



R

R



MR JATIN GURI 31 YRS 25/03/2023 M CHEST PA VIEW 3/25/2023
ONEPLUS UI-TRASOUND LAB 47 HARSH VIHAR PITAMPURA