

Package Details

Patient Name : Mr Saksham Singh, 2010000023977, male, 30y 11m
Package Name : EHP Mediwheel Full Body Health checkup Below 40 Male
Start Date : 25/02/2023 09:49 End Date : 26/02/2023 09:49
Generated By: Hemanth Kumar
Generated On : 25-02-2023 09:51

Service Name	Ordered Date	Service Center	Consultant	Qty	Explicit
USG ABDOMEN	25/02/2023 09:49 AM	ULTRA SOUND-2F	Dr. Sharma Vasant Kumar	1	No
XRAY CHEST PA	25/02/2023 09:49 AM	X-RAY	Dr. Sharma Vasant Kumar	1	No
ECHO COLOR DOPPLER	25/02/2023 09:49 AM	ECHO-2F	Dr. Sharma Vasant Kumar	1	No
TREADMILL TEST	25/02/2023 09:49 AM	OPD-2F	Dr. Sharma Vasant Kumar	1	No
ECG	25/02/2023 09:49 AM	OPD-2F	Dr. Sharma Vasant Kumar	1	No
BLOOD UREA NITROGEN (BUN)	25/02/2023 09:49 AM	BIOCHEMISTRY	Dr. Sharma Vasant Kumar	1	No
URIC ACID	25/02/2023 09:49 AM	BIOCHEMISTRY	Dr. Sharma Vasant Kumar	1	No
THYROID PROFILE (T3, T4, TSH)	25/02/2023 09:49 AM	BIOCHEMISTRY	Dr. Sharma Vasant Kumar	1	No
LIVER FUNCTION TEST (LFT)	25/02/2023 09:49 AM	BIOCHEMISTRY	Dr. Sharma Vasant Kumar	1	No
SERUM CREATININE	25/02/2023 09:49 AM	BIOCHEMISTRY	Dr. Sharma Vasant Kumar	1	No
LIPID PROFILE (CHOL, TRIG, HDL, LDL, VLDL)	25/02/2023 09:49 AM	BIOCHEMISTRY	Dr. Sharma Vasant Kumar	1	No
HBA1C	25/02/2023 09:49 AM	BIOCHEMISTRY	Dr. Sharma Vasant Kumar	1	No
URINE FOR SUGAR (FASTING)	25/02/2023 09:49 AM	CLINICAL PATHOLOGY	Dr. Sharma Vasant Kumar	1	No
URINE FOR SUGAR (POST PRANDIAL)	25/02/2023 09:49 AM	CLINICAL PATHOLOGY	Dr. Sharma Vasant Kumar	1	No
POST PRANDIAL BLOOD SUGAR (PPBS)	25/02/2023 09:49 AM	BIOCHEMISTRY	Dr. Sharma Vasant Kumar	1	No
FASTING BLOOD SUGAR (FBS)	25/02/2023 09:49 AM	BIOCHEMISTRY	Dr. Sharma Vasant Kumar	1	No
BLOOD GROUP & RH TYPING	25/02/2023 09:49 AM	NARAYANA HRUDAYALAYA BLOOD CENTRE	Dr. Sharma Vasant Kumar	1	No
STOOL ROUTINE EXAMINATION	25/02/2023 09:49 AM	CLINICAL PATHOLOGY	Dr. Sharma Vasant Kumar	1	No
URINE ROUTINE & MICROSCOPY	25/02/2023 09:49 AM	CLINICAL PATHOLOGY	Dr. Sharma Vasant Kumar	1	No
ERYTHROCYTE SEDIMENTATION RATE (ESR)	25/02/2023 09:49 AM	HEMATOLOGY	Dr. Sharma Vasant Kumar	1	No
COMPLETE BLOOD COUNT (CBC)	25/02/2023 09:49 AM	HEMATOLOGY	Dr. Sharma Vasant Kumar	1	No

WT - 71.9
BP - 100/60
HT - 174
PR - 68/mr



Service Name	Ordered Date	Service Center	Consultant	Qty	Explicit
CONSULTATION - FIRST VISIT	25/02/2023 09:49 AM	OPD-2F	Dr. Sharma Vasant Kumar	1	No



25-02-2023 09:51

Health Check up Booking Request(bobS30258), Beneficiary Code-63198

Mediwheel <wellness@mediwheel.in>

Mon 2/20/2023 4:49 AM

To: Info Sarjapur <info.sarjapur@narayanahealth.org>

Cc: mediwheelwellness@gmail.com <mediwheelwellness@gmail.com>

Attention: This email originated outside of Narayana Health domain. Links and attachments cannot be verified as authentic. Do not share personal/organisational data including passwords or act based on the content of the email, unless you have verified the authenticity of the sender and email address thoroughly.

011-41195959

Email:wellness@mediwheel.in

Dear **Narayana Multispeciality Clinic**,

City : Bangalore . **Address** : 83/3 Doddakanneli,Sarjapur,Main Road , Near Wipro Gate-560035,

We have received the confirmation for the following booking .

Name : Saksham singh
Age : 30
Gender : Female
Package Name : Mediwheel Metro Full Body Health Checkup Male Below 40
Contact Details : 9759798693
Booking Date : 20-02-2023
Appointment Date : 25-02-2023

Member Information			
Booked Member Name	Age	Gender	Cost(In INR)
Saksham singh	29	Male	Cashless
Total amount to be paid			Cashless

We will get back to you with confirmation update shortly. Please find the package details as attached for your reference.

Package Name : Mediwheel Metro Full Body Health Checkup Male Below 40 - Includes (37)Tests

Tests included in this Package : Ecg, TSH, X-ray Chest, Stress Test (tmt)/ 2d Echo, Blood Sugar Postprandial, A:g Ratio, Blood Group, Total Cholesterol, Triglycerides, Fasting Blood Sugar, Ultrasound Whole Abdomen , Glycosylated Haemoglobin (hba1c), Hdl, Vldl, Urine Analysis, LDL, Total Protine, General Consultation, HDL/ LDL ratio, GGT(Gamma-glutamyl Transferase), Eye Check-up consultation, ALP (ALKALINE PHOSPHATASE), Uric Acid, AST/ALT Ratio, Serum Protein, CBC with ESR, Stool Analysis, Urine Sugar Fasting, Urine Sugar PP, T3, T4, Cholesterol Total / HDL Ratio, BUN, BUN/Creatinine Ratio, Bilirubin Total & Direct and Indirect, Albumin, Globulin

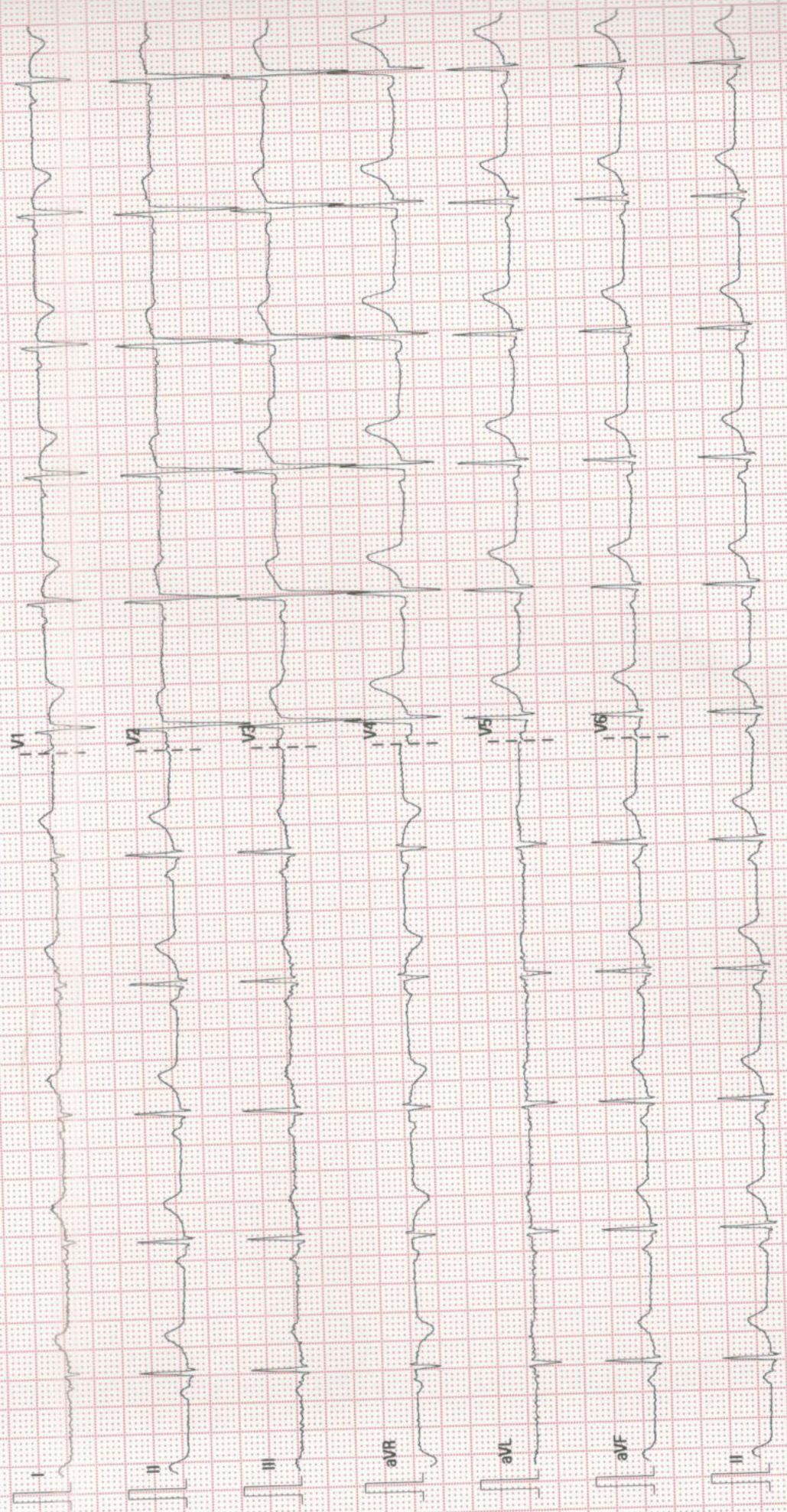
ID: 201-23917
Name: MR. SAKSHAM SINGH
Age: 30 Years
Gender: Male

25-02-2023 12:05:52

Vent. Rate	67 bpm
PR Interval	148 ms
QRS Duration	76 ms
QT/QTc Interval	394/406 ms
P/QRS/T Axes	69/94/50 deg
RV5/SV1	1.224/0.873 mV
RV5 + SV1	2.097 mV
QTc/Hodges	

Sinus rhythm
Rightward axis
Borderline ECG

Unconfirmed Diagnosis



Patient Name : Mr.SAKSHAM SINGH
Age : 30 Years
Referring Doctor : PKG

Patient ID : 201- 23977
Sex : male
Date : 25 .02.2023

ULTRASOUND ABDOMEN AND PELVIS

FINDINGS:

Liver is normal in size (13.4cm), and echopattern. No intra or extra hepatic biliary duct dilatation. No focal lesions.

Portal vein is normal in size, course and caliber. **CBD** is not dilated.

Gall bladder is normal without evidence of calculi, wall thickening or pericholecystic fluid.

Pancreas to the extent visualized, appears normal in size, contour and echogenicity.

Spleen is normal in size (9.7cm), shape, contour and echopattern. No evidence of mass or focal lesions.

Right Kidney is normal in size (measures 9.1 cm in length & 1.1cm in parenchymal thickness), position, shape and echopattern. Corticomedullary differentiation is maintained. No evidence of calculi or hydronephrosis.

Left Kidney is normal in size (measures 9.3 cm in length & 1.3 cm in parenchymal thickness), position, shape and echopattern. Corticomedullary differentiation is maintained. No evidence of calculi or hydronephrosis.

Retroperitoneum – Obscured by bowel gas.


Urinary Bladder is well distended. Wall thickness is normal. No evidence of calculi, mass or mural lesion.

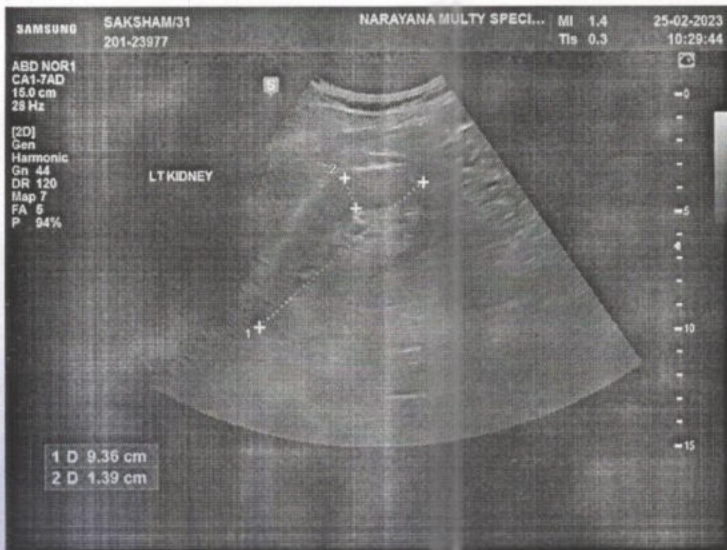
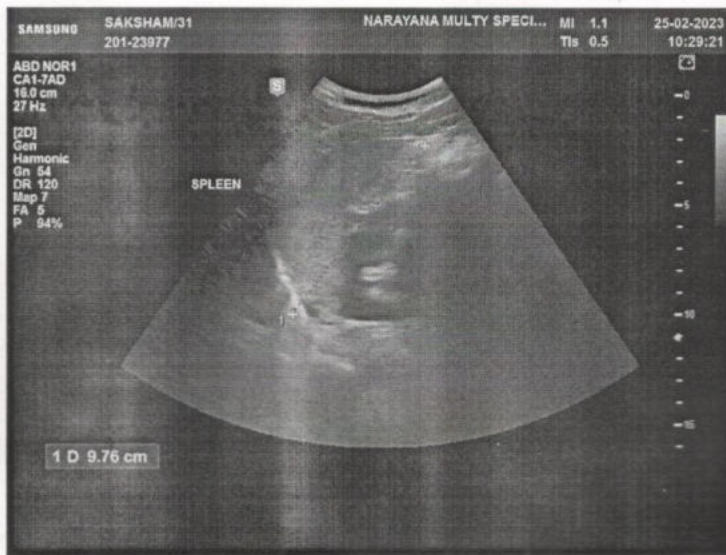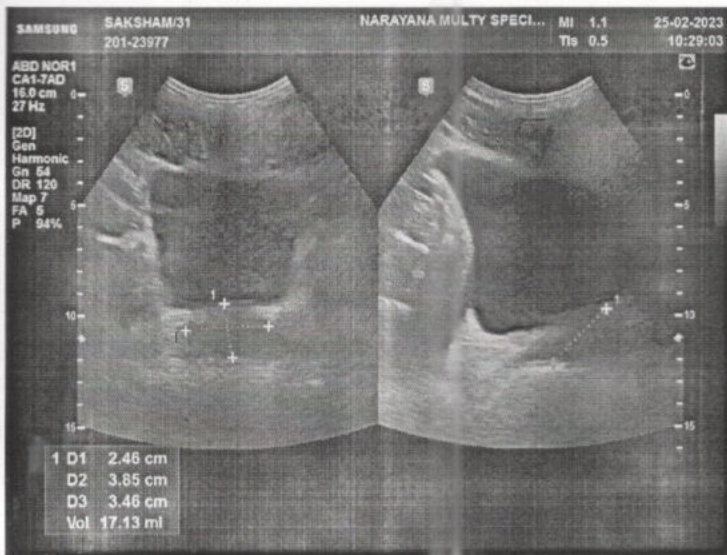
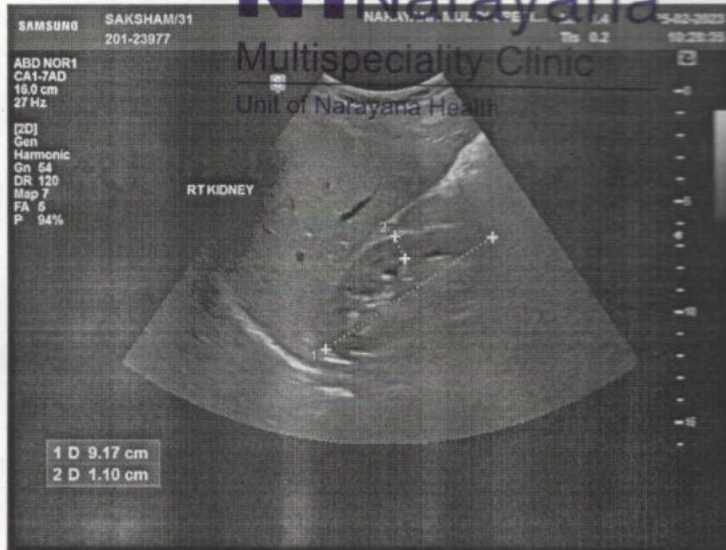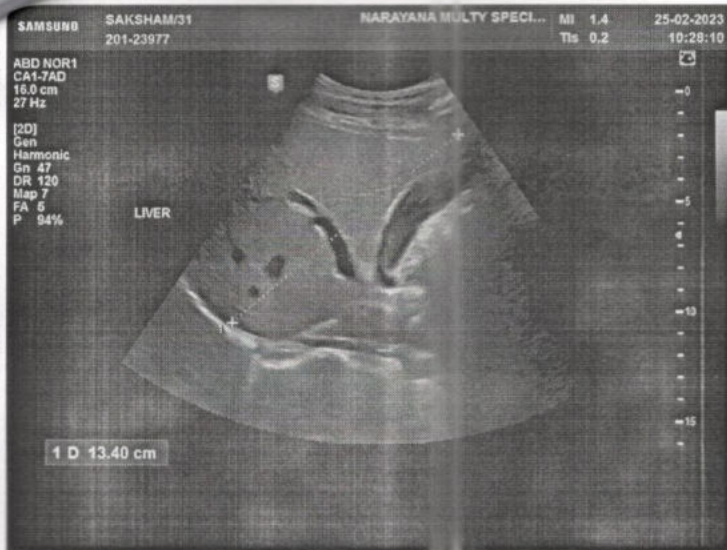Prostate is normal in echopattern and size, (Volume =17.1cc).

Fluid - There is no ascites or pleural effusion.

IMPRESSION:

- **UNREMARKABLE STUDY OF ABDOMEN AND PELVIS**


Dr. Ananthalakshmi.S
Sonologist



TRANS-THORACIC ECHO REPORT

Patient MRN : 201-23977

Date : 25.02.2023

Patient Name : Mr.SAKSHAM SINGH

Age/Gender : 30 yrs/male

M-MODE / 2D MEASUREMENTS

LVEF (>55)% : 60%	LVID(d) (40-56)mm : 44mm	LVID (s) mm : 30mm
TAPSE (>16) mm : 20mm	IVS (d) (6-10)mm : 10mm	LV-EDV ml : --
LA (<39) mm : 26mm	PWD (d) (6-10)mm : 9mm	LV-ESV ml : --
RA (<44)mm : 30mm	RV (<35) mm : 27mm	BSA m ² : --

DOPPLER MEASUREMENTS

MITRAL VALVE : E/A - 0.7/0.5 M/S, NORMAL LV DIASTOLIC FUNCTION, MR-TRIVIAL

AORTIC VALVE : PG - 4 MMHG /AR-TRIVIAL

TRICUSPID VALVE : TR -TRIVIAL

PULMONARY VALVE : PG - 4 MMHG

PA PRESSURE : PASP- 20 MMHG/ NORMAL PA PRESSURE.

FINDINGS

SITUS SOLITUS, LEVOCARDIA, AV AND VA CONCORDANT, NORMAL GREAT ARTERY RELATIONSHIP

VALVES

MITRAL : NORMAL

AORTIC : NORMAL

TRICUSPID : NORMAL

PULMONARY : NORMAL

CHAMBERS

LV : NORMAL SIZED, NORMAL LV SYSTOLIC FUNCTION.

RV : NORMAL SIZED, NORMAL RV FUNCTION.

RWMA : NO RWMA

LVOT : SITUS SOLITUS, LEVOCARDIA, AV AND VA CONCORDANT, NORMAL GREAT ARTERY RELATIONSHIP

LEFT ATRIUM : NORMAL SIZED

RIGHT ATRIUM : NORMAL SIZED



SEPTAE

IVS : INTACT

IAS : INTACT

ARTERIES & VEINS

AORTA : AORTIC ANNULUS - 19MM, ASCENDING AORTA- 28 MM,
NORMAL ARCH NORMAL SIZED.

PULMONARY ARTERY : NORMAL

IVC, SVC & CS : IVC - 13 MM, NORMAL SIZED, COLLAPSING, NORMAL RA PRESSURE.

PULMONARY VEINS : NORMAL

PERICARDIUM : NORMAL


VEGETATION / THROMBUS / TUMOR: NIL

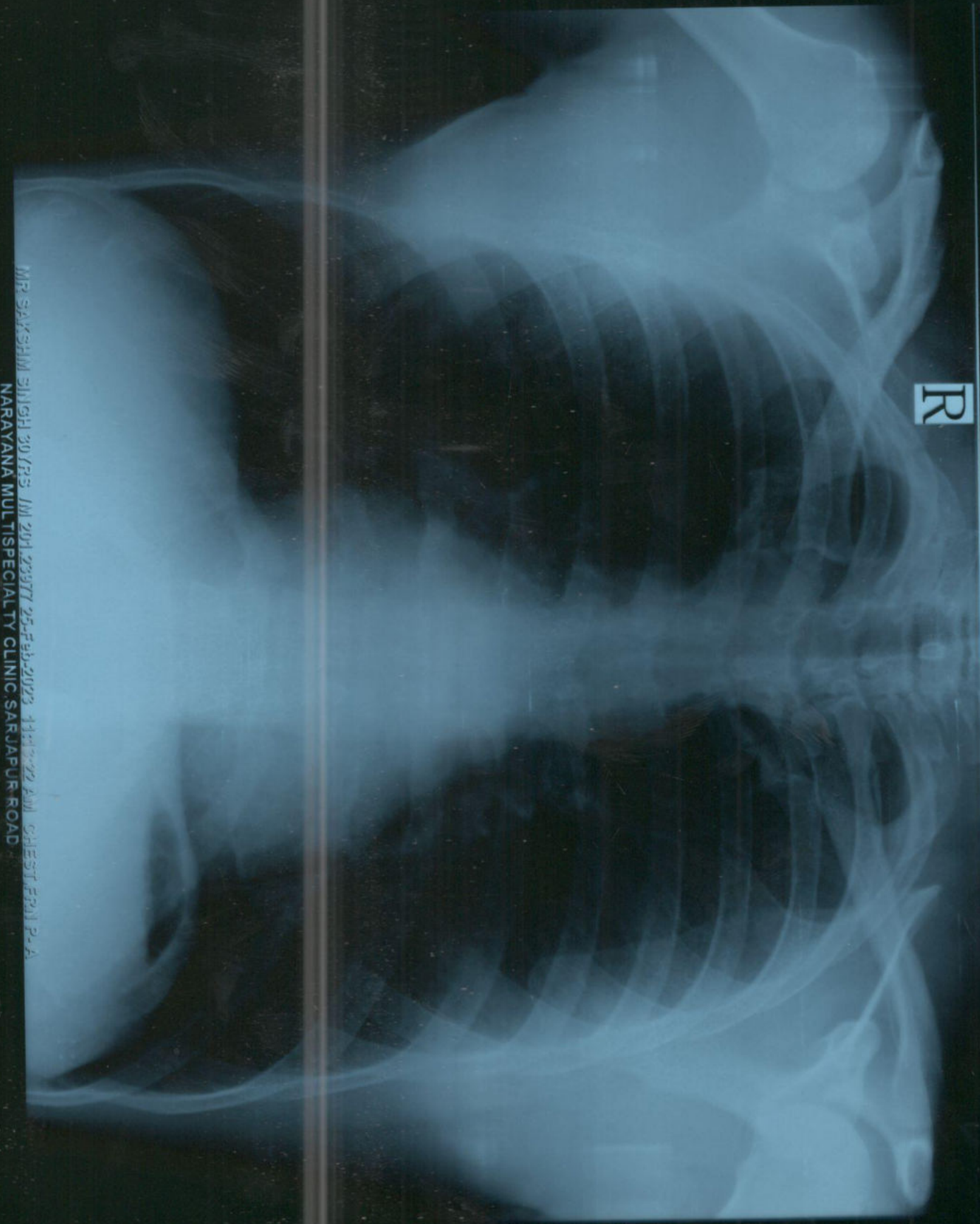
OTHER FINDINGS:

SINUS RHYTHM- 70 BPM
NO PREVIOUS ECHO REPORT

CONCLUSION

NORMAL CHAMBER DIMENSIONS
NORMAL PA PRESSURE
NO RWMA
NORMAL LV SYSTOLIC FUNCTION
LVEF:- 55-60%


CHANDANA V
CARDIAC SONOGRAPHER



MR. SAKSHI SHIRI 30/RS. JM 204 23977 25-55-2023 11:42:22 AM CHEST PA-P

NARAYANA MULTISPECIALTY CLINIC, SARJAPUR ROAD