



SHARANYA
Multispeciality Hospital
BURDWAN



ADVANCED BIOCHEMISTRY

NAME : Pushpa Jaiswal
AGE/SEX : 35 Yr(s) FEMALE
REQ. NO. : 01-DIRQ-PL-21-040686
REF. BY : DR.BANK OF BORODA
TAT : 53 Hrs 44 Mins

REG. NO. : 01-21-050742
REG. DATE : 13/03/2022
REQ. DATE : 13/03/2022
COLLECTION DT. : 13/03/2022
REP. DATE : 15/03/2022

<u>INVESTIGATION</u>	<u>RESULT</u>	<u>UNIT</u>	<u>BIOLOGICAL REFERENCE RANGE</u>
<u>T3, T4, TSH</u>			
T3, Serum	2.0	ng/ml	0.69-2.15
T4, Serum	9.0	ug/dl	5.2-12.7
TSH, Serum	2.0	μIU/ml	0.3-4.5

"Note: Please correlate clinically"

End of Report

Method -CLIA (Snibe Maglumi-800)

Dr. Deb Kumar Ray
MBBS, MD
Consultant
Biochemistry

P.B. : JOYDIP ADITYA

Dr. Anup Kumar Boler
MBBS, MD, Pathology
Consultant Pathologist

Dr. S.G Mukhopadhyay
MD, Pathologist.
Consultant Pathologist

Dr. Purbasha Ghosh
MBBS, M.D.
(Microbiology)
Consultant
Microbiologist

BIOCHEMISTRY


NAME : Pushpa Jaiswal
AGE/SEX : 35 Yr(s) FEMALE
REQ. NO. : 01-DIRQ-PL-21-040683
REF. BY : DR. BANK OF BORODA
TAT : 3 Hrs 38 Mins

REG. NO. : 01-21-050737
REG. DATE : 13/03/2022
REQ. DATE : 13/03/2022
COLLECTION DT.: 13/03/2022
REP. DATE : 13/03/2022

<u>INVESTIGATION</u>	<u>RESULT</u>	<u>UNIT</u>	<u>BIOLOGICAL REFERENCE</u>
Blood Glucose (PP)	152.9	mg/dl	80-140

"Note: Please correlate clinically"

End of Report


Dr. Debkumar Ray
MBBS, MD
Consultant Biochemistry

Dr. Anup Kumar Boler
MBBS, MD, Pathology
Consultant Pathologist

Dr. S.G Mukhopadhyay
MD, Pathologist.
Consultant Pathologist

Dr. Purbasha Ghosh
MBBS, M.D.
(Microbiology)
Consultant
Microbiologist

P.B. : JOYDIP ADITYA

HAEMATOLOGY

NAME : Pushpa Jaiswal
AGE/SEX : 35 Yr(s) FEMALE
REQ. NO. : 01-DIRQ-PL-21-040686
REF. BY : DR.BANK OF BORODA
TAT : 1 Hrs 47 Mins

REG. NO. : 01-21-050742
REG. DATE : 13/03/2022
REQ. DATE : 13/03/2022
COLLECTION DT.: 13/03/2022
REP. DATE : 13/03/2022

<u>INVESTIGATION</u>	<u>RESULT</u>	<u>UNIT</u>	<u>BIOLOGICAL REFERENCE</u>
<u>C B C Complete Haemogram</u>			
Haemoglobin, Blood	11.5	gm/dl	11-16
Total Red Blood Corpuscles	4.04	million/cum	3.8-4.8
Total White Blood Corpuscles	6400	/cumm	4000-11000
<u>Differential Leucocyte Count</u>			
Neutrophils	70	%	45-75
Lymphocytes	26	%	25-45
Monocytes	02	%	2-5
Eosinophils	02	%	2-6
Basophils	00	%	<1
Platelet Count	0.60	Lakh/cumm	1.5-4.5
ESR 1st Hr	35	mm/1st hr.	5-35
Haematocrit/PCV, Blood	36.2	%	36-46
MCV	89.5	fl	83-101
MCH	28.4	Picogram	27-32
MCHC	31.7	%	30-35

Note :- Thrombocytopenia on smear.

Adv :- Repeat CBC after management.

Dr. Debkumar Ray
MBBS,MD
Consultant Biochemistry

Dr. Anup Kumar Boler
MBBS,MD, Pathology
Consultant Pathologist

Dr. S.G Mukhopadhyay
MD, Pathologist.
Consultant Pathologist

Dr. Purbasha Ghosh
MBBS, M.D.
(Microbiology)
Consultant
Microbiologist

P.B. : SANTANU PATRA



SHARANYA
Multispeciality Hospital
BURDWAN



HAEMATOLOGY

NAME : Pushpa Jaiswal
AGE/SEX : 35 Yr(s) FEMALE
REQ. NO. : 01-DIRQ-PL-21-040686
REF. BY : DR.BANK OF BORODA
TAT : 3 Hrs 2 Mins

REG. NO. : 01-21-050742
REG. DATE : 13/03/2022
REQ. DATE : 13/03/2022
COLLECTION DT. : 13/03/2022
REP. DATE : 13/03/2022

INVESTIGATION

RESULT

Blood Grouping (ABO, Rh)

Blood Group (ABO)

" O "

Rh (D) Factor

POSITIVE

"Note: Please correlate clinically"

End of Report

Dr. Debkumar Ray
MBBS,MD
Consultant
Biochemistry

Dr. Anup Kumar Boler
MBBS,MD, Pathology
Consultant Pathologist

Dr. S.G Mukhopadhyay
MD, Pathologist.
Consultant Pathologist

Dr. Purbasha Ghosh
MBBS, M.D.
(Microbiology)
Consultant
Microbiologist

P.B. : PATHOLOGY STUDEN

CLINICAL PATHOLOGY

Patient Name : Pushpa Jaiswal
Age / Sex : 35 Years / Female
Ref. By : DR.BANK OF BORODA
Lab No :
TAT : 1 Hrs 22 Mins

Reg No / Visit No : 01-21-050742/1
Requisition No : 01-DIRQ-PL-21-040686
Requisition Date : 13-Mar-2022
Collection Date : 13-Mar-2022 11:19 AM
Report Date : 13-Mar-2022

URINE ROUTINE EXAMINATION			
TEST PARAMETERS	RESULT	TEST PARAMETER	RESULT
PHYSICAL EXAMINATION		MICROSCOPICAL EXAMINATION	
VOLUME	20 ml	PUS CELLS	1-2 /HPF
COLOUR	Straw	RBC	Nil
APPEARANCE	Slightly Hazy	EPITHELIAL CELLS	1-2 /HPF
SPECIFIC GRAVITY	1.015	CASTS	NOT SEEN
		MICRO ORGANISM	Nil
CHEMICAL EXAMINATION			
REACTION	ACIDIC	CRYSTALS	NOT SEEN
PROTEIN	Nil		
GLUCOSE	ABSENT	PHOSPHATES	ABSENT
BLOOD	Nil	NITRITE	ABSENT
BILE PIGMENTS	ABSENT	KETONE	ABSENT
		BILE SALT	ABSENT

Dr. Anup Kumar Boier
MBBS,MD, (path)

Dr. S. G. Mukhopadhyay
MBBS,MD(Path)

Dr. Debkumar Ray
MBBS,MD(Biochemistry)

Dr. Purbasha Ghosh
MBBS, MD(Microbiology)



SHARANYA
Multispeciality Hospital
BURDWAN



BIOCHEMISTRY

NAME : Pushpa Jaiswal
AGE/SEX : 35 Yr(s) FEMALE
REQ. NO. : 01-DIRQ-PL-21-040686
REF. BY : DR.BANK OF BORODA
TAT : 2 Hrs 45 Mins

REG. NO. : 01-21-050742
REG. DATE : 13/03/2022
REQ. DATE : 13/03/2022
COLLECTION DT. : 13/03/2022
REP. DATE : 13/03/2022

<u>INVESTIGATION</u>	<u>RESULT</u>	<u>UNIT</u>	<u>BIOLOGICAL REFERENCE RANGE</u>
Urea, Serum	25.6	mg/dl	13-50
Creatinine, Serum	0.78	mg/dl	0.5-1.3
Uric Acid	5.5	mg/dl	2.4-5.7
<u>Lipid Profile, Serum</u>			
Total Cholesterol	103.4	mg/dl	<250
Triglycerides	97.5	mg/dl	<170
HDL Cholesterol	48.9	mg/dl	<55
LDL Cholesterol	35.0	mg/dl	0-160
VLDL Cholesterol	19.5	mg/dl	10-35
Blood Glucose (Fasting)	109.2	mg/dl	70-110
<u>LIVER FUNCTION TEST</u>			
Total Billirubin	0.68	mg/dl	0.1-1.2
Direct Billirubin	0.52	mg/dl	<0.3
Indirect Billirubin	0.16	mg/dl	
SGPT/ALT	23.7	U/L	<40
SGOT/AST	22.4	U/L	<40
Alkaline Phosphatase .	150.4	U/L	108-306
Total Protein	6.18	gm/dl	6.3-8.4
Albumin	4.01	gm/dl	3.5-5

Dr. Debkumar Ray
MBBS, MD
Consultant
Biochemistry

Dr. Anup Kumar Boler
MBBS, MD, Pathology
Consultant Pathologist

Dr. S.G Mukhopadhyay
MD, Pathologist.
Consultant Pathologist

Dr. Purbasha Ghosh
MBBS, M.D.
(Microbiology)
Consultant
Microbiologist

P.B. : JOYDIP ADITYA

Bamchandsipur, N.H. 2, Purba Burdhaman-713104, West Bengal, India
Phone : +91 9475641904, +91 9233333583
E-mail : info.sharanyahospital@gmail.com, Web : www.sharanyahospital.com





SHARANYA
Multispeciality Hospital
BURDWAN



BIOCHEMISTRY

NAME : Pushpa Jaiswal
AGE/SEX : 35 Yr(s) FEMALE
REQ. NO. : 01-DIRQ-PL-21-040686
REF. BY : DR.BANK OF BORODA
TAT : 2 Hrs 45 Mins

REG. NO. : 01-21-050742
REG. DATE : 13/03/2022
REQ. DATE : 13/03/2022
COLLECTION DT. : 13/03/2022
REP. DATE : 13/03/2022

<u>INVESTIGATION</u>	<u>RESULT</u>	<u>UNIT</u>	<u>BIOLOGICAL REFERENCE RANGE</u>
Globulin	2.17	gm/dl	>2.5

"Note: Please correlate clinically"

End of Report

Dr. Debkumar Ray
MBBS,MD
Consultant
Biochemistry

Dr. Anup Kumar Boler
MBBS,MD, Pathology
Consultant Pathologist

Dr. S.G Mukhopadhyay
MD, Pathologist.
Consultant Pathologist

Dr. Purbasha Ghosh
MBBS, M.D.
(Microbiology)
Consultant
Microbiologist

P.B. I JOYDIP ADITYA

BIOCHEMISTRY

Patient Name : Pushpa Jaiswal
 Age / Sex : 35 Years / Female
 Ref. By : DR.BANK OF BORODA
 Lab No :
 TAT : 2 Hrs 42 Mins

Reg No / Visit No : 01-21-050742/1
 Requisition No : 01-DIRQ-PL-21-040686
 Requisition Date : 13-Mar-2022
 Collection Date : 13-Mar-2022 11:00 AM
 Report Date : 13-Mar-2022

Sample : Blood

<u>Test Parameters</u>	<u>Result</u>	<u>Unit</u>	<u>Normal Range</u>
HbA1C (Glycosylated Hb)	5.5	%	Non Diabetics 4-6 % Target of therapy < 7% Change of therapy > 8%

Comment : Kindly Correlate Clinically.

END OF REPORT



Dr. Deb Kumar Ray
 MBBS,MD
 Consultant
 Biochemistry

Dr. Anup Kumar Boler
 MBBS,MD, Pathology
 Consultant Pathologist

Dr. S.G Mukhopadhyay
 MD, Pathologist.
 Consultant Pathologist

Dr. Purbasha Ghosh
 MBBS, M.D.
 (Microbiology)
 Consultant
 Microbiologist

Dr. Binlta Kongsabanik
 MBBS,MD(Microbiology)
 Consultant
 Microbiologist



SHARANYA
Multispeciality Hospital
BURDWAN



Name: Pushpa Jaiswal. AGE: 35 Yrs. Sex F

Ref By Dr. Bank of baroda. Date : 13.03.2022.

X-RAY CHEST PA VIEW.

Bronchovascular marking are normal

Domes of diaphragms are smooth and regular.

Costophrenic angles are clear.

Mediastinum is central.

Hila shadow are normal.

Cardiac shadow is normal.

IMP: 1. Normal study.

Clinical correlation suggested.

Dr. Anoop Sastry
Consultant Radiologist



SHARANYA
Multispeciality Hospital
BURDWAN



DEPARTMENT OF USG

Patient Name : Pushpa Jaiswal
Age / Sex : 35 Years / Female
Ref. By : DR.BANK OF BORODA

Reg No / Visit No : 01-21-050742/1
Requisition No : 01-DIRQ-US-21-004193
Report Date : 14-Mar-2022

USG- WHOLE ABDOMEN

Liver: Enlarged in size with raised echotexture. I H B R are not dilated. No focal S O L is seen.

Portal Vein: Normal in size, measures 0.81cm in diameter at porta .

Common Bile Duct: Measures 0.36cm in diameter at porta normal Its lumen appears clear.(visualized part)

Gall Bladder: : Normal in size, shape and position with regular wall .
No luminal calculus or sludge or mass lesion is visualized at present

Pancreas: Normal in size, with normal echo texture. No focal S O L is seen.
Main Pancreatic duct is not dilated.

Spleen: : Length is 10.8cm. Normal in size and echotexture. No focal S O L is seen.

Kidneys: Right kidney 9.9cm Left kidney 9.8cm
Both kidneys are normal in size, shape and position. Both kidney have regular outlines and show normal cortico medullary differentiation. No evidence of any hydronephrosis, renal calculus or mass lesion is visualized.

Both Ureters: Both ureters are not seen; hence not dilated.

Urinary bladder: Walls are smooth and regular .Lumen is free,

Uterus : Normal in size & measuring (7.5 x 4.1 x 3.7) cm. It shows normal myometrium and endometrial echoes. No focal S O L is seen. Cervix appears normal.

Both ovaries: Both ovaries are normal in size and echotexture. No focal S O L is seen.

Both Adnexae :: No obvious mass lesion (solid or cystic) is seen

P O D: Clear.

IMPRESSION :: Hepatomegaly with grade-I fatty liver.

Please correlate clinically.

Dr. S.Z. AHAMED.
MD (Radiologist)
(Reg-No-68381)

Patient

Exam

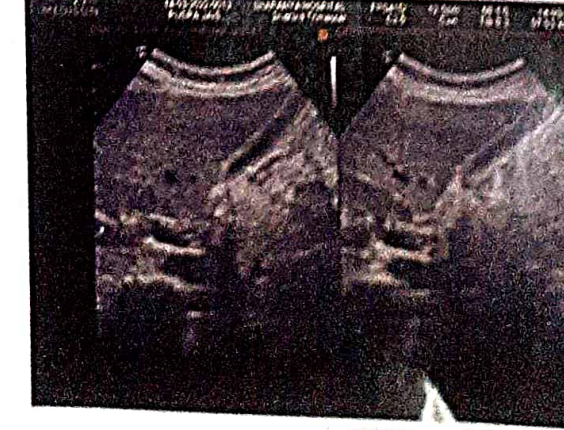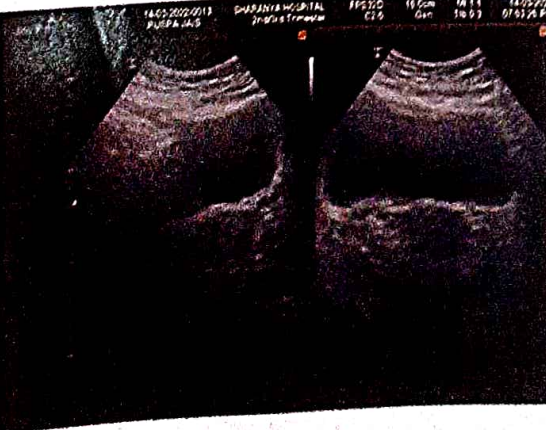
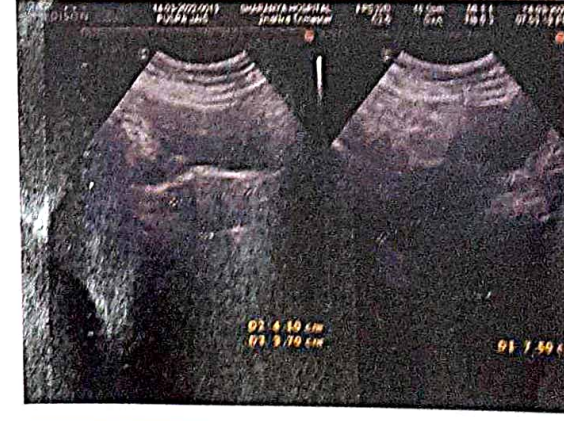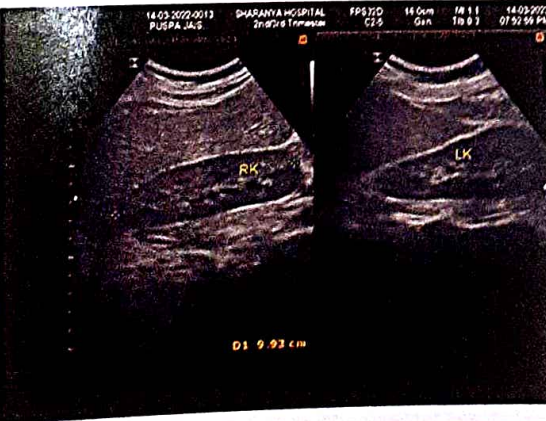
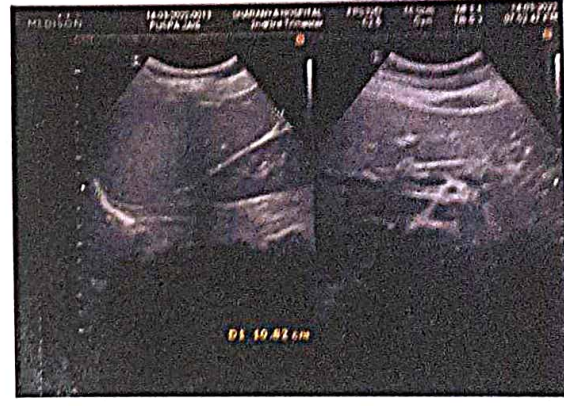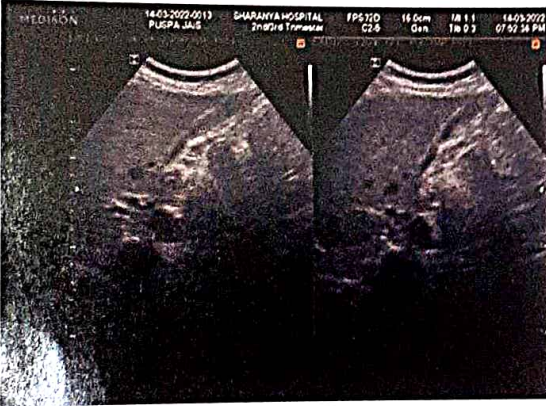
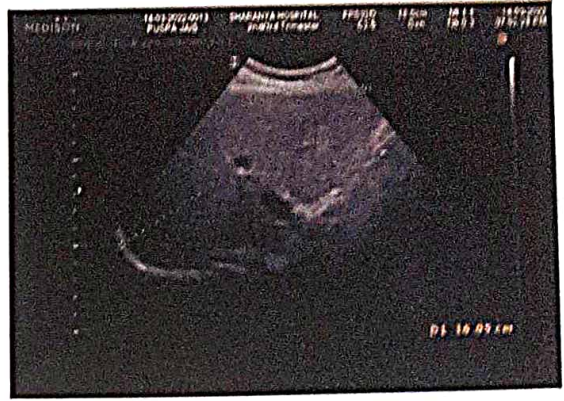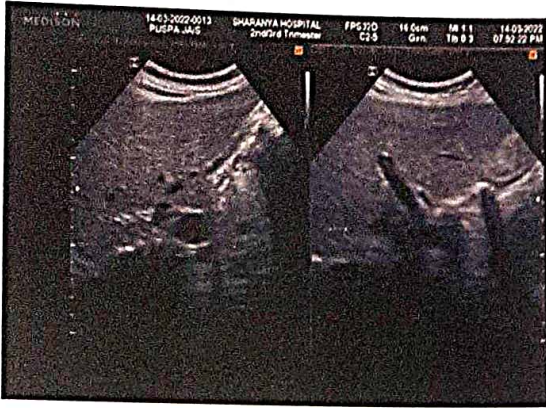
ID
Name
Birth Date
Gender

14-03-2022-0013
PUSPA JAISWAL
Other

Accession #
Exam Date
Description
Sonographer

14032022

SARANYA HOSPITAL





SHARANYA
Multispeciality Hospital
BURDWAN



Name : Pushpa Jaiswal. AGE:35 yrs. Sex :F.

Ref.by : Dr.Bank of Baroda. Date : 14.03.2022.

ECHO CARDIOGRAPHY

2D& M-MODE

LA : 26 mm.
ACS : 15 mm.
AO : 23 mm.
IVSD : 10 mm.
LVPW : 09 mm.
LVIDD : 42 mm.
LVIDS : 29 mm.
EJECTION FRACTION:58 %
FS : %.
EPSS : 10 mm.
DE : 09 mm.
E.F.SLOPE : 112 m/Sec.

Comment,s

LV cavity size and wall thickened normal

- Good LV systolic function.
- No RWMA.
- Normal LA,RA & RV size.
- No pericardial effusion.

No mass, clot, vegetation noted .

IMPRESSION Normal study.


Dr.S.K.Baral (MBBS. DIP CARDIO)
Consultant Cardiologist



ELECTROCARDIOGRAM

Name..... *Puspa Jaiswal*

Ref. by Dr. *Doak of Bopoda*

Age..... *35/35* Sex () M F Date..... *13/03/22*



Barnchandaipur, N.H.2, Purba Burdhaman - 703103, West Bengal, India

Phone : +91 9475641904, + 91 923333

E-mail: info.sharanyahospital@gmail.com

Web-site: www.sharanyahospital.com