



PARKLINE DIAGNOSTICS PVT. LTD.

L.G. 3, 4 & 5, Bhuvana Towers, S.D. Road, Secunderabad - 500 003.

Tel : +91 40-2784 5852, 6649 1787, 7995421787, 7093445852, Fax : +91 40 2784 7864

Email parklinediagnostics@gmail.com www.parklinediagnostics.com



NABL Accredited
Certificate No.MC-2566

MEDICAL EXAMINATION REPORT

Name	Mr. Prasad Rao JV Durga		Date :	07/08/2021		
Company	C/o: Medi wheel		Reg. No. :	UUUS72		
Contact No.	9030133315		Sex	<input checked="" type="checkbox"/> M	Age :	<input type="checkbox"/> 49
Type	Pre-Emp		Emp. No.:	162434		
	Overseas		Height	172 cms.		
	Annual	<input checked="" type="checkbox"/>	Weight	78 kgs.		
Remarks	- Clinical & Lab. Parameters are WNL.					
Fitness Status	Medically Fit / Unfit		Dr. K. VIKRAM Physician's Signature Reg.No. 8603			

COMPREHENSIVE MEDICAL EXAMINATION REPORT

NAME Mr. Prasad Rao JV Durga.

AGE 49 yrs.

MARITAL STATUS Married CHILDREN : M 1 F

IDENTIFICATION (IF ANY) _____

PAST HISTORY

Any family H/o : High Blood Pressure, Heart Disease, Tuberculosis, Diabetes, Asthma, Cancer

Any personal H/o Major illness like : Typhoid.....Jaundice.....Etc. *Father*

Any H/o STD.....Skin infection..... *NIL*

H/o Blood Transfusion.....Recent Vaccination Covid 19 - Both doses - July

H/o Epilepsy.....Giddiness.....

H/o Surgery Haemorrhoidectomy 1990 Fracture in the past (L) Tibia & Fibula - 30 yrs ago

Any Personal H/O.

High Blood Pressure, Heart Disease Tuberculosis, Diabetes, Asthma, Cancer

Drug Abuse, Drug Allergy, Micturition, Bowels, Alcohol, Smoking, Sleep, MC, Wt. Loss/Wt. Gain
 oc.

Present illness / Medication Anti histamines

GENERAL EXAMINATION

Conjunctiva :	<i>NAD</i>	Bone, Joints :	<i>NAD</i>
Skin :		Nutritional Status :	<i>well nourished</i>
Ears :		Lymph Nodes :	<i>N.P.</i>
Nose :		Edema Feet :	<i>NIL</i>
Throat & Oral Cavity :		Varicose Veins :	<i>NIL</i>

Distant Vision : Near Vision :

Right Eye: 6/6

With glasses / Without glasses

left Eye: 6/6

with glasses / without glasses

Colour Vision: BE normal

Right Eye: NG + 2.00 sph NG

With glasses / Without glasses

left Eye: NG + 2.00 sph NG

with glasses / without glasses

Ophthalmologist's Signature

Dr. KATTA
M.B.B.S., D.O.
Regd: 1981 (AMC)

Right Ear

Left Ear

Hearing :

Rinee's Test ;

Weber Test :

Discharge :

SYSTEMIC EXAMINATION

Pulse : 72 / min.

B.P. : 130 / 80 w Kg.

Lungs : A. Shape of Chest
B. Breath Sounds +
C. Adventitious Sounds

Bi-l. symmetrical.

NIL.

Heart : A. Sounds S₁ S₂
B. Murmurs NIL

Nervous System

Abdomen : A. Liver N.P.
B. Spleen
C. Piles NIL
D. Any Lump

A. Higher Function :
B. Cranial Nerves :
C. Sensory System :
D. Motor System :
E. Jerks : (i)

General : A. Hernia
B. Hydrocele NIL
C. Varicocele

Breast : Rt _____ Lt. _____

CANDIDATE'S DECLARATION

I hereby solemnly declare that I am not suffering from Asthma, Hypertension, Diabetes, Occult Psychological disorders or any other ailment which can be suppressed without my voluntary declaration.

Date :

Signature

A handwritten signature in blue ink is written over a horizontal line. The signature is stylized, featuring a large loop on the left side and a long, sweeping stroke extending to the right.

Place :

Note : General Physical Examination and Investigation included in the health check-up Have certain limitations and may not be able to detect all latent and asymptomatic diseases. Any new symptoms developing after the health check-up or persisting thereafter should be brought to the attention of the treating physician.



PARKLINE DIAGNOSTICS PVT. LTD.

L.G. 3, 4 & 5, Bhuvana Towers, S.D. Road, Secunderabad - 500 003. Tel : +91 40-2784 5852, 6649 1787, 7995421787,
7093445852, Fax : +91 40 2784 7864 Email parklinediagnostics@gmail.com www.parklinediagnostics.com



NABL Accredited
Certificate No.MC-2566

ENT CONSULTATION

S.No. 444 577

Emp.No.

Date 7/8/2021

Name Mr. Prasad Rao J.V. Durga

Age

Yrs 49

Sex M/F

EARS :

Right

Left

EAC

: Patent, no Cerumen

- ob.

TM

: Intact, pearly white,
Cone of light (+)

- ob.

TFT

: Rinne's +ve

Rinne's +ve

Weber's - centralised

NOSE

: Septum (+). Bil. T's & meatus (+). Pass (+) - no tenderness

THROAT

: Oropharynx (+). B.I.V. c/s (+) moving
Anteriorly } bil.

NECK

: (+)

IMPRESSION:

ENT clinically NAD

Dr. D. Hari Krishna Reddy
MS (ENT)
Head & Neck Surgeon
Reg. No: 88379



Phone: 27844043
66339096

SECUNDERABAD DENTAL HOSPITAL

CENTRE FOR ADVANCED DENTAL CARE

7/8/2021

ORAL & MAXILLOFACIAL SURGEONS

Dr. Kazim Himathi M.D.S.

Dr. Gautam Dendukuri

FDRCES (Eng), FFDRCS (Ire),
FFDRCS (OMFS), (Ire)

PROSTHODONTIST

Dr. Chandrakanth Reddy M.D.S.

ENDODONTIST

Dr. Ram Narayan Reddy M.D.S.

ORTHODONTIST

Dr. Rajesh Reddy M.D.S., M.Orth RCS.

Dr. Sudeep Bhalerao M.D.S.

PEDIODONTIST

Dr. Veerendranath Reddy M.D.S.

PEDODONTIST

Dr. Mounika M.D.S.

DENTAL SURGEONS

Dr. N. Jagadish Rao B.D.S.

Dr. Baisakhi Saha B.D.S.

Mr. Prasad Rao

o/c :- Patient came for regular dental
checkup

O/F :-
- Stains⁺
- calculus⁺
- missing $\frac{61}{61}$

adv Sealing
fixed prosthesis $\frac{61}{61}$





PARKLINE DIAGNOSTICS PVT. LTD.


L.G. 3, 4 & 5, Bhuvana Towers, S.D. Road, Secunderabad - 500 003 Tel :+91 40-2784 5852, 6649 1787

Fax : +91 40 2784 7864 Email parklinediagnostics@gmail.com www.parklinediagnostics.com



NABL Accredited
Certificate No.MC-2566

TEST REPORT

Req No. : 444577	Referred By : -
Name : Mr.PRASAD RAO JV DURGA [162434]	Registration Date/Time : 07/08/2021/08:40
R/o : ---	Sampling Date/Time : 07/08/2021/
Age/Sex : 49 Years/Male	Sample : -
Barcode : 	Center : MEDIWHEEL

ULTRA SONOGRAPHY

ULTRA SOUND SCAN OF ABDOMEN*

LIVER : Normal in size and echotexture. No focal lesions.

No IHBD /CBD dilatation. Portal vein is normal in size.

SPLEEN: Normal in size and echotexture. No focal lesion seen.

GALL BLADDER: Well distended. No sludge / gall stones / sol.

Gall bladder -Wall thickness is normal.

No pericholecystic oedema.

PANCREAS : Normal in size and echotexture.No calcification / sol.

Pancreatic duct is normal. No peripancreatic fluid collection.

RIGHT KIDNEY : 10.59 x 4.35 cms

Normal in size and echotexture.

Cortical thickness is normal.

No evidence of calculi / sol.

Pelvi calyceal system is normal.

LEFT KIDNEY : 10.30 x 5.16 cms

Normal in size and echotexture.

Cortical thickness is normal.

No evidence of calculi / sol.

Pelvi calyceal system is normal.

URINARY BLADDER : Well distended. Normal in contour.

Wall thickness is normal. No calculus / sol.


PROSTATE : Normal in size and echotexture.

No calcification / sol.

No pre or para aortic adenopathy / ascites noted.

IMPRESSION : Normal Study.

Clinical correlation.


Dr. D.J. MOHAN
MD DMRD
(Reg No. 8995)
Consultant Radiologist

****End of Report****

Printed on : 07/08/2021 / 11.59

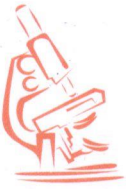The Test marked with *are not accredited by NABL

Lab Timings (Weekdays) : 7.00 am to 8.30 pm

Sundays & Holidays : 7.00 am to 1.00 pm

Radiologists Timings(Weekdays) : 7.30 am to 1.30 pm

& 5.30 pm to 7.30 pm
Sundays & Holidays : 7.30 am to 9.30 am




PARKLINE DIAGNOSTICS PVT. LTD.

L.G. 3, 4 & 5, Bhuvana Towers, S.D. Road, Secunderabad - 500 003 Tel :+91 40-2784 5852, 6649 1787
Fax : +91 40 2784 7864 Email parklinediagnostics@gmail.com www.parklinediagnostics.com



NABL Accredited
Certificate No.MC-2566

TEST REPORT

Req No. : 444577	Referred By : -
Name : Mr.PRASAD RAO JV DURGA [162434]	Registration Date/Time: 07/08/2021/08:40
R/o : - -	Sampling Date/Time : 07/08/2021/
Age/Sex : 49 Years/Male	Sample : -
Barcode : 	Center : MEDIWHEEL

RADIOLOGY

X-RAY CHEST PA VIEW*

Lung fields are clear.

Cardia is normal.

Hila are normal.

C P angles are free.

Bony cage is normal.

Soft tissues are normal.

IMPRESSION : NORMAL CHEST X-RAY.

12

Dr. D.J. MOHAN
MD DMRD
(Reg No. 8995)
Consultant Radiologist

****End of Report****

Printed on : 07/08/2021 / 09.53

The Test marked with *are not accredited by NABL

Lab Timings (Weekdays) : 7.00 am to 8.30 pm

Sundays & Holidays : 7.00 am to 1.00 pm

Radiologists Timings(Weekdays) : 7.30 am to 1.30 pm
& 5.30 pm to 7.30 pm

Sundays & Holidays : 7.30 am to 9.30 am

Page No. 1

ID: 444546

07-08-2021 08:38:55 AM

CARDIART

MR.PRASAD RAO J V DURGA

Male 49Years

HR : 54 bpm
P : 92 ms
PR : 124 ms
QRS : 92 ms
QT/QTc : 430/408 ms
P/QRS/T : 39/66/60 °
RV5/SV1 : 1.891/0.856 mV

Sinus Bradycardia
Correlate Clinically



Dr. NAVEEN KUMAR .C
M.D., D.M.
Consultant Cardiologist
Reg. No. 52291

Diagnosis Information:
Sinus Bradycardia

Report Confirmed by:

PATIENT SUMMARY REPORT

PARKLINE DIAGNOSTICS PVT.LTD

D : 444577
NAME : MR PRASAD RAO JV DURGA
AGE / SEX : 49 / MALE

HEIGHT (cm) : 172
WEIGHT (kg) : 78
PROTOCOL : BRUCE

REF. BY : MEDIWHEEL
DONE BY : DR NAVEEN KUMAR C
TECHNICIAN : G.M.SURESH

021, 09:42:

CASE HISTORY

MEDICATION

OBJECT OF TEST : Routine Check Up.

RISK FACTOR : None.

ACTIVITY : Very Active.

OTHER INVESTIGATION : E C G

REASON FOR TERMINATION : THR ACHIEVED

EXERCISE TOLERANCE : Good (> 10 METS).

EXERCISE INDUCED ARRHYTHMIAS : No.

HAEMO RESPONSE : Normal.

CHRONO RESPONSE : Normal.

FINAL IMPRESSION :

negative for inducible ischemia

EXTRA COMMENTS



Confirmed By :

[Signature]
Dr. NAVEEN KUMAR .C
M.D., D.M.
Consultant Cardiologist

Signature

Reg. No. 52291