

CID# : 2207126389  
Name : MRS.DIPALI RAHUL RAMTEKE  
Age / Gender : 31 Years/Female  
Consulting Dr. : -  
Reg.Location : Lulla Nagar, Pune (Main Centre)

SID# : 177804960452  
Registered : 12-Mar-2022 / 09:12  
Collected : 12-Mar-2022 / 09:12  
Reported : 12-Mar-2022 / 13:56  
Printed : 14-Mar-2022 / 09:45

## PHYSICAL EXAMINATION REPORT

- a) Diet : Mixed  
b)Addiction : No ( Thyroid Since 1 Years. )

### GENERAL EXAMINATION :

- a)Height (cms) : 156  
b)Weight (kgs) : 55  
c)Lymph Nodes : Not Palpable

### 3) SYSTEMIC EXAMINATION

#### A) RESPIRATORY SYSTEM

- a) Lungs : Clear  
b) Trachea : Central  
c ) Air Entry : Equal  
d) Rales : No  
d) Others : NAD

#### B) CARDIOVASCULAR SYSTEM ( CVS )

- a) Heart Sounds : S1 S2 Normal  
b) Murmurs : No  
c ) Pulse/min : 68  
d ) B/P ( mm of Hg ) : 100/70  
e ) Miscellenous : NAD

**PUNE LAB ADDRESS:** Seraph Centre, Opp. BSNL Exchange, Shahu College Road, Off Pune-Satara Road, Behind Panchami Hotel, Pune - 411009

**CENTRAL PROCESSING LAB:** 2<sup>nd</sup> Floor, Aston, Sundervan Complex, Above Mercedes Showroom, Andheri West, Mumbai - 400053

**HEALTHLINE - MUMBAI:** 022-6170-0000 | **OTHER CITIES:** 1800-266-4343 | **For Feedback** - customerservice@suburbandiagnosics.com | [www.suburbandiagnosics.com](http://www.suburbandiagnosics.com)

**Brief Disclaimer:** (1)Suburban Diagnostics ensures that the tests are conducted with utmost care and safety and are performed on samples received as per the sample collection guide of Suburban Diagnostics.(2)Sample may be rejected if unacceptable for the requested tests. (3)Test results may vary from laboratory to laboratory and also in some parameters from time to time for the same patient.(4)Report must not be copied in part, only in full. (5)This report is not valid for medico-legal purposes.(6)Patient information or data will not be communicated to a third party except in the case of a notifiable disease to a Public Care Unit.(7)Suburban Diagnostics reserves the right to subcontract samples to other laboratories as required.(8)Suburban Diagnostics is not liable for any penalties or liabilities arising out of or relating in any way to these services and/or content or information provided herein.(9) For the elaborated disclaimer, please turn over the page or visit our website.

CID#	: 2207126389	SID#	: 177804960452
Name	: MRS.DIPALI RAHUL RAMTEKE	Registered	: 12-Mar-2022 / 09:12
Age / Gender	: 31 Years/Female	Collected	: 12-Mar-2022 / 09:12
Consulting Dr.	: -	Reported	: 12-Mar-2022 / 13:56
Reg.Location	: Lulla Nagar, Pune (Main Centre)	Printed	: 14-Mar-2022 / 09:45

C) ABDOMEN

- a) Liver : Not Palpable
- b) Spleen : Not Palpable
- c) Any other Swelling : No


D) NERVOUS SYSTEM

- a) Ankle Reflex : Normal
- b) Plantars : Flexor

**DOCTOR REMARKS :**

All performed reports are within range

\*\*\* End Of Report \*\*\*



**Dr.Milind Shinde**  
MBBS, DNB, Consuling Physician,  
Diabetologist & Echocardiologist

**PUNE LAB ADDRESS:** Seraph Centre, Opp. BSNL Exchange, Shahu College Road, Off Pune-Satara Road, Behind Panchami Hotel, Pune - 411009

**CENTRAL PROCESSING LAB:** 2<sup>nd</sup> Floor, Aston, Sundervan Complex, Above Mercedes Showroom, Andheri West, Mumbai - 400053

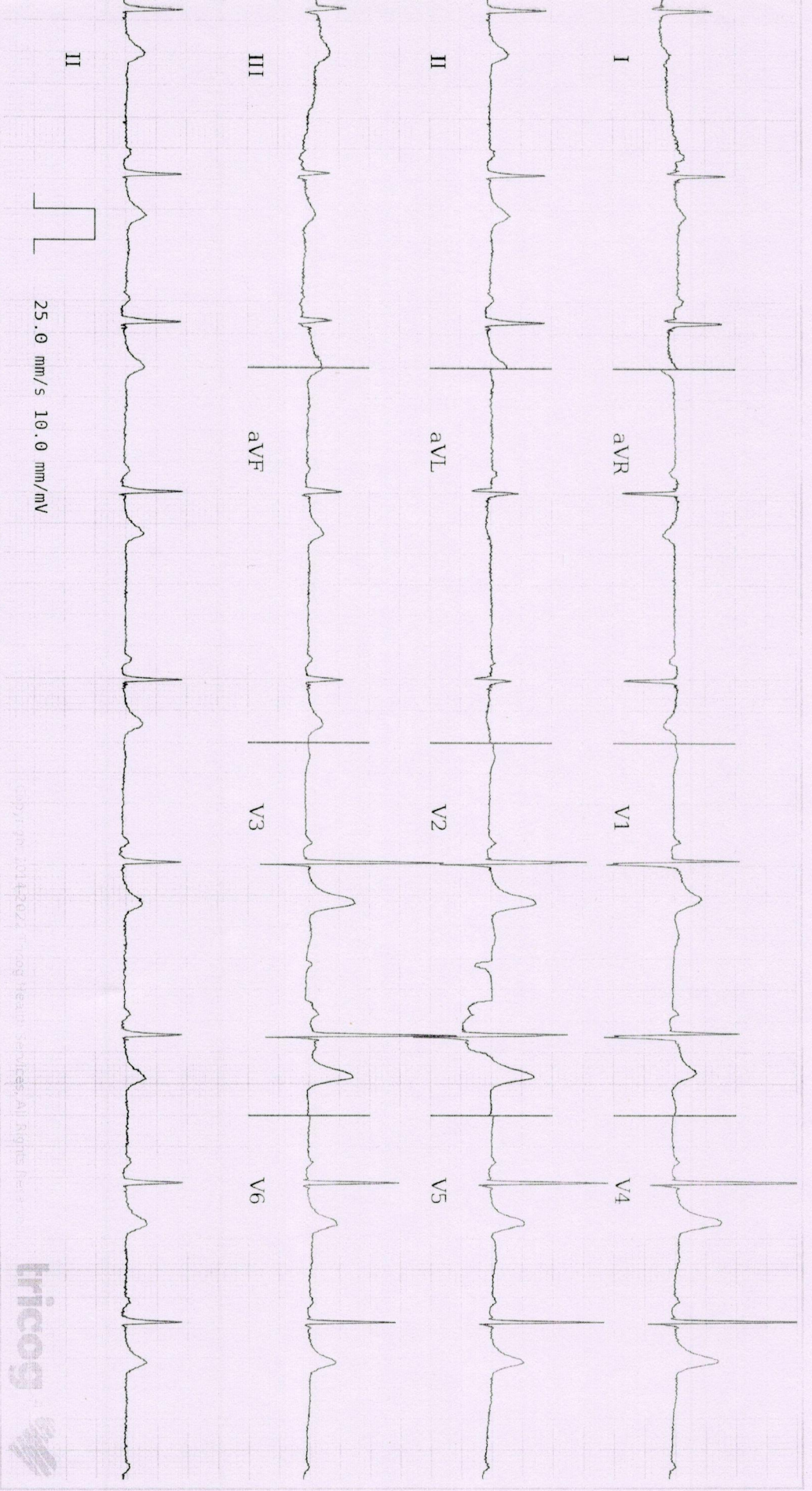
**HEALTHLINE - MUMBAI:** 022-6170-0000 | **OTHER CITIES:** 1800-266-4343 | **For Feedback -** customerservice@suburbandiagnosics.com | [www.suburbandiagnosics.com](http://www.suburbandiagnosics.com)

**SUBURBAN DIAGNOSTICS - LULLANAGAR, PUNE**

Patient Name: DIPALI RAHUL RAMTEKE

Date and Time: 12th Mar 22 9:43 AM

Patient ID: 2207126389



25.0 mm/s 10.0 mm/mV

Copyright © 2014-2022 Tricog Health Services. All Rights Reserved.



Age 31 11 10  
years months days

Gender Male

Heart Rate 57bpm

**Patient Vitals**

BP: 100/70 mmHg  
Weight: 55 kg  
Height: 156 cm  
Pulse: NA  
Spo2: NA  
Resp: NA  
Others:

**Measurements**

QSRD: 80ms  
QT: 394ms  
QTc: 383ms  
PR: 136ms  
P-R-T: 23° 50° 75°

REPORTED BY

*Dr. Milind Shinde*



Dr. Milind Shinde  
MBBS, DNB Medicine  
2011/05/1544

ECG Within Normal Limits: Sinus Bradycardia. Please correlate clinically.

Disclaimer: 1) Analysis in this report is based on ECG alone and should be used as an adjunct to clinical history, symptoms, and results of other invasive and non-invasive tests and must be interpreted by a qualified physician. 2) Patient vitals are as entered by the clinician and not derived from the ECG.

CID#	: 2207126389	SID#	: 177804960452
Name	: MRS.DIPALI RAHUL RAMTEKE	Registered	: 12-Mar-2022 / 09:12
Age / Gender	: 31 Years/Female	Collected	: 12-Mar-2022 / 09:12
Consulting Dr.	: -	Reported	: 12-Mar-2022 / 10:17
Reg.Location	: Lulla Nagar, Pune (Main Centre)	Printed	: 12-Mar-2022 / 10:19

**USG WHOLE ABDOMEN**

**LIVER** : The liver is normal in size, shape and smooth margins. It shows normal parenchymal echo pattern. The intra hepatic biliary and portal radical appear normal. No evidence of any intra hepatic cystic or solid lesion seen. The main portal vein and CBD appears normal.

**GALL BLADDER** : The gall bladder is physiologically distended. The visualized gall bladder appears normal. No evidence of pericholecystic fluid is seen.

**PANCREAS** : The pancreas is well visualised and appears normal. No evidence of solid or cystic mass lesion is noted.

**KIDNEYS** : Both the kidneys are normal in size, shape and echotexture. No evidence of any calculus, hydronephrosis or mass lesion seen.

**SPLEEN** : The spleen is normal in size, shape and echotexture. No evidence of focal lesion is noted.

**URINARY BLADDER** : The urinary bladder is well distended. It shows thin walls and sharp mucosa. No evidence of calculus is noted. No mass or diverticulum is seen.

**UTERUS** : The uterus is anteverted and appears normal. No obvious focal lesion. The endometrial thickness is 7.9 mm.

**OVARIES** :  
Right ovary is visualised and appear normal.  
Left ovary is visualised and shows small developing follicle within.  
Minimal free fluid in pelvis.

**PUNE LAB ADDRESS:** Seraph Centre, Opp. BSNL Exchange, Shahu College Road, Off Pune-Satara Road, Behind Panchami Hotel, Pune - 411009  
**CENTRAL PROCESSING LAB:** 2<sup>nd</sup> Floor, Aston, Sundervan Complex, Above Mercedes Showroom, Andheri West, Mumbai - 400053

**HEALTHLINE - MUMBAI:** 022-6170-0000 | **OTHER CITIES:** 1800-266-4343 | **For Feedback** - customerservice@suburbandiagnosics.com | [www.suburbandiagnosics.com](http://www.suburbandiagnosics.com)

**Brief Disclaimer:** (1) Suburban Diagnostics ensures that the tests are conducted with utmost care and safety and are performed on samples received as per the sample collection guide of Suburban Diagnostics. (2) Sample may be rejected if unacceptable for the requested tests. (3) Test results may vary from laboratory to laboratory and also in some parameters from time to time for the same patient. (4) Report must not be copied in part, only in full. (5) This report is not valid for medico-legal purposes. (6) Patient information or data will not be communicated to a third party except in the case of a notifiable disease to a Public Care Unit. (7) Suburban Diagnostics reserves the right to subcontract samples to other laboratories as required. (8) Suburban Diagnostics is not liable for any penalties or liabilities arising out of or relating in any way to these services and/or content or information provided herein. (9) For the elaborated disclaimer, please turn over the page or visit our website.

CID#	: 2207126389	SID#	: 177804960452
Name	: MRS.DIPALI RAHUL RAMTEKE	Registered	: 12-Mar-2022 / 09:12
Age / Gender	: 31 Years/Female	Collected	: 12-Mar-2022 / 09:12
Consulting Dr.	: -	Reported	: 12-Mar-2022 / 10:17
Reg.Location	: Lulla Nagar, Pune (Main Centre)	Printed	: 12-Mar-2022 / 10:19


Visualized small bowel loops appear non-dilated. Gaseous distension of large bowel loops. There is no evidence of any lymphadenopathy.

**IMPRESSION :**

Ø No significant abnormality seen.

**Advice - Clinical and lab correlation.**

\*\*\* End Of Report \*\*\*



**Dr. Navid Shattari**  
**MD, DNB, Radio-Diagnosis Reg No.**  
**2015/05/2742**

**PUNE LAB ADDRESS:** Seraph Centre, Opp. BSNL Exchange, Shahu College Road, Off Pune-Satara Road, Behind Panchami Hotel, Pune - 411009

**CENTRAL PROCESSING LAB:** 2<sup>nd</sup> Floor, Aston, Sundervan Complex, Above Mercedes Showroom, Andheri West, Mumbai - 400053

**HEALTHLINE - MUMBAI:** 022-6170-0000 | **OTHER CITIES:** 1800-266-4343 | **For Feedback -** customerservice@suburbandiagnosics.com | [www.suburbandiagnosics.com](http://www.suburbandiagnosics.com)

**Brief Disclaimer:** (1)Suburban Diagnostics ensures that the tests are conducted with utmost care and safety and are performed on samples received as per the sample collection guide of Suburban Diagnostics.(2)Sample may be rejected if unacceptable for the requested tests. (3)Test results may vary from laboratory to laboratory and also in some parameters from time to time for the same patient.(4)Report must not be copied in part, only in full. (5)This report is not valid for medico-legal purposes.(6)Patient information or data will not be communicated to a third party except in the case of a notifiable disease to a Public Care Unit.(7)Suburban Diagnostics reserves the right to subcontract samples to other laboratories as required.(8)Suburban Diagnostics is not liable for any penalties or liabilities arising out of or relating in any way to these services and/or content or information provided herein.(9) For the elaborated disclaimer, please turn over the page or visit our website.

CID#	: 2207126389	SID#	: 177804960452
Name	: MRS.DIPALI RAHUL RAMTEKE	Registered	: 12-Mar-2022 / 09:12
Age / Gender	: 31 Years/Female	Collected	: 12-Mar-2022 / 09:12
Consulting Dr.	: -	Reported	: 12-Mar-2022 / 11:15
Reg.Location	: Lulla Nagar, Pune (Main Centre)	Printed	: 12-Mar-2022 / 11:18

### X-RAY CHEST PA VIEW

Bilateral lung field appears clear.

No obvious consolidation/cavitation.

The cardiothoracic ratio is maintained.


The domes of the diaphragm are normal.

The cardio and costophrenic angles are clear.

Bony thorax is normal.

*Advice - Clinical and lab correlation.*

\*\*\* End Of Report \*\*\*



**Dr. Navid Shattari**

**MD, DNB, Radio-Diagnosis Reg No.  
2015/05/2742**

**PUNE LAB ADDRESS:** Seraph Centre, Opp. BSNL Exchange, Shahu College Road, Off Pune-Satara Road, Behind Panchami Hotel, Pune - 411009

**CENTRAL PROCESSING LAB:** 2<sup>nd</sup> Floor, Aston, Sundervan Complex, Above Mercedes Showroom, Andheri West, Mumbai - 400053

**HEALTHLINE - MUMBAI:** 022-6170-0000 | **OTHER CITIES:** 1800-266-4343 | **For Feedback -** customerservice@suburbandiagnosics.com | [www.suburbandiagnosics.com](http://www.suburbandiagnosics.com)