

- COMPU. PATHOLOGY • ALLERGY TESTING
- DIGITAL WHOLE BODY X-RAYS
- DIGITAL 3D SONOGRAPHY
- DIGITAL WHOLE BODY COLOUR DOPPLER
- DIGITAL 2-D ECHO WITH COLOUR DOPPLER
- E.C.G. • LUNG FUNCTION TEST
- MAMMOGRAPHY & BONE MINERAL DENSITOMETRY

- COMPUTERISED STRESS TEST
- DENTAL
- ADVANCED DENTISTRY
- PHYSIOTHERAPY
- AUDIOMETRY & SPEECH THERAPY
- FULL BODY HEALTH CHECK-UPS
- CORPORATE HEALTH CHECKUPS



HEALTHCARE

MEDICAL CENTRE & DIAGNOSTICS

NAME	MR AKULA MOHAN UDAY BHASKAR	DATE	26.03.2022
		AGE	38 YRS
REF. BY DR	MEDIWHEEL	SEX	MALE

X-RAY CHEST (PAVIEW).

The lungs on the either side show equal translucency.

The pleural spaces are normal.

The cardiac size is normal.

The domes of the diaphragms are normal in position, and show smooth outline.

Ribs appear normal.

IMPRESSION :

NO EVIDENCE OF PLEURAL OR PARENCHYMAL PATHOLOGY IS NOTED.

Correlate clinically .

DR.SHRIKANT BODKE
(Consultant Radiologist)

Investigations have their limitation.Solitary pathological/Radiological & other investigations never confirm the final diagnosis.They only help in diagnosing the disease in correlation to clinical symptoms & other related tests.Please interpret accordingly.

Clinical correlation and further evaluation is required ,if indicated.

BORIVALI CENTRE	1ST FLR., YOGI AVENUE, YOGI NAGAR, BORIVALI (W), MUMBAI - 400092. • TEL.: 2899 6565 / 2899 1376 • MOB.: 90222 39301
KANDIVALI CENTRE	MAHAVIR SURYADARSHAN SOC., SATYANAGAR RD., MAHAVIR NAGAR, KANDIVALI (W), MUMBAI - 67. • TEL.: 2868 0090 / 6522 6565 / 2869 7808 • MOB.: 90220 54458
KANDIVALI CENTRE	SHOP NO. 44/49, EMP 71, EVERSHINE MILLENNIUM PARADISE, THAKUR VILLAGE, 120 FEET ROAD, KANDIVALI (E) MUMBAI - 400101. • TEL.: 2885 7171 / 89288 41541
DAHISAR CENTRE	NILANGI APARTMENT, KANDERPADA JUNCTION, DAHISAR (W), MUMBAI - 400068. • TEL.: 2893 3427 • MOB.: 90220 58504
GORAI CENTRE	VICTORY HEIGHTS, GORAI MAIN ROAD, OPP SUVIDYA SCHOOL, BORIVALI (W), MUMBAI - 400092. • TEL.: 2869 6566 • MOB.: 90224 88354 / 72080 02565
GOREGAON CENTRE	M.G. ROAD, NEAR JAIN MANDIR, GOREGAON (W), MUMBAI - 400062. • TEL.: 2873 3030 / 2873 3131 • MOB.: 93213 83806
GOREGAON (EAST)	SATELLITE GARDENS, FILM CITY ROAD, NEAR SATELLITE TOWER, GOREGAON (EAST), MUMBAI - 400063 • TEL.: 79773 74838 / 79773 62922
MIRA ROOD	UNIT NO. R13, RNA LIBERTY REST, NEAR JANGID CIRCLE, VIJAY PARK, MIRA ROAD (EAST), MUMBAI - 401107. • TEL.: 70218 04221 / 70218 27389

Website : www.healthcarediag.com • E-mail : healthcare.medicals@gmail.com

"Home Visit Facility Call On 76667 66307"

- COMPU. PATHOLOGY • ALLERGY TESTING
- DIGITAL WHOLE BODY X-RAYS
- DIGITAL 3D SONOGRAPHY
- DIGITAL WHOLE BODY COLOUR DOPPLER
- DIGITAL 2-D ECHO WITH COLOUR DOPPLER
- E.C.G. • LUNG FUNCTION TEST
- MAMMOGRAPHY & BONE MINERAL DENSITOMETRY

- COMPUTERISED STRESS TEST
- DENTAL
- ADVANCED DENTISTRY
- PHYSIOTHERAPY
- AUDIOMETRY & SPEECH THERAPY
- FULL BODY HEALTH CHECK-UPS
- CORPORATE HEALTH CHECKUPS



HEALTHCARE

MEDICAL CENTRE & DIAGNOSTICS

NAME	MR AKULA MOHAN UDAY BHASKAR	DATE	26.03.2022
		AGE	38 YRS
REF. BY DR.	MEDIWHEEL	SEX	MALE

REAL TIME ABDOMINAL SONOGRAPHY SHOWS ,

LIVER : Liver is normal in size showing **bright** parenchymal echotexture . There is no evidence of solid or cystic mass .The portal and the hepatic venous system appears normal.

GALL BLADDER : The Gall bladder is partially distended .The gall bladder wall of normal thickness . No evidence of gall stones.

PANCREAS : Pancreas is normal in size with smooth margin and homogenous paranchymal echotexture.No focal lesion seen.

KIDNEYS : Both kidneys are normal in size and shows homogenous cortical echotexture.Central calyceal echoes appears normal.There is no evidence of hydronephrosis or renal calculus.

(a) Right kidney measures: 9.1 x 3.3 cms

(b) Left kidney measures: 9.6 x 4.3 cms.

SPLEEN : The spleen is normal in size with homogenous paranchymal echotexture.No focal lesion are seen.

URINARY BLADDER : Urinary bladder is well distended.No evidence of calculus or intraluminal mass seen in the bladder.

Prevoid volume = 324 cc, Postvoid residue = nil.

PROSTATE : Prostate is normal in size & volume is 12 cc.

IMPRESSION :
Grade I fatty liver.


DR.SHRIKANT BODKE
CONS.RADIOLOGIST.

Note : Investigations have their limitations. Solitary radiological investigations never confirm the final diagnosis. They only help in diagnosing the disease in correlation to clinical symptoms and other related tests. USG is known to have interobserver variation. Further / Follow-up imaging may be needed in some cases for confirmation of USG finings. Patient was explained in detail about the USG findings and its limitations. Please interpret accordingly.

BORIVALI CENTRE	1ST FLR., YOGI AVENUE, YOGI NAGAR, BORIVALI (W), MUMBAI - 400092. • TEL.: 2899 6565 / 2899 1376 • MOB.: 90222 39301
KANDIVALI CENTRE	MAHAVIR SURYADARSHAN SOC., SATYANAGAR RD., MAHAVIR NAGAR, KANDIVALI (W), MUMBAI - 67. • TEL.: 2868 0090 / 6522 6565 / 2869 7808 • MOB.: 90220 54458
KANDIVALI CENTRE	SHOP NO. 44/49, EMP 71, EVERSHINE MILLENNIUM PARADISE, THAKUR VILLAGE, 120 FEET ROAD, KANDIVALI (E) MUMBAI - 400101. • TE.: 2885 7171 / 89288 41541
DAHISAR CENTRE	NILANGI APARTMENT, KANDERPADA JUNCTION, DAHISAR (W), MUMBAI - 400068. • TEL.: 2893 3427 • MOB.: 90220 58504
GORAI CENTRE	VICTORY HEIGHTS, GORAI MAIN ROAD, OPP. SUVIDYA SCHOOL, BORIVALI (W), MUMBAI - 400092. • TEL.: 2869 6556 • MOB.: 90224 88354 / 72080 02565
GOREGAON CENTRE	M.G. ROAD, NEAR JAIN MANDIR, GOREGAON (W), MUMBAI - 400062. • Tel.: 2873 3030 / 2873 3131 • MOB.: 93213 83806
GOREGAON (EAST)	SATELLITE GARDENS, FILM CITY ROAD, NEAR SATELLITE TOWER, GOREGAON (EAST), MUMBAI - 400063 • TEL.: 79773 74838 / 79773 62922
MIRA ROOD	UNIT NO. R13, RNA LIBERTY REST, NEAR JANGID CIRCLE, VIJAY PARK, MIRA ROAD (EAST), MUMBAI - 401107. • TEL.: 70218 04221 / 70218 27389

Website : www.healthcarediag.com • E-mail : healthcare.medicals@gmail.com

"Home Visit Facility Call On 76667 66307"

- COMPU. PATHOLOGY
- DIGITAL X-RAY
- DIGITAL SONOGRAPHY
- DIGITAL COLOR DOPPLER
- 2D ECHO CARDIOGRAPHY
- MAMMOGRAPHY & BONE MINERAL DENSITOMETRY (BMD)
- ECG ■ PFT
- COMPU. TREADMILL TEST
- PHYSIOTHERAPY
- DENTAL
- HEALTH CHECK-UP



HEALTHCARE
MEDICAL CENTRE & DIAGNOSTICS

ELECTROCARDIOGRAM (ECG)


MIR AKULA MOHAN UDAY P
EJCA8558 26-Mar-2022
ECG

PATIENT MR AKULA MOHAN UDAY BHASIKAR AGE. _____ SEX M
 REF. BY DR. MEDINHEEL DATE 26.03.2022

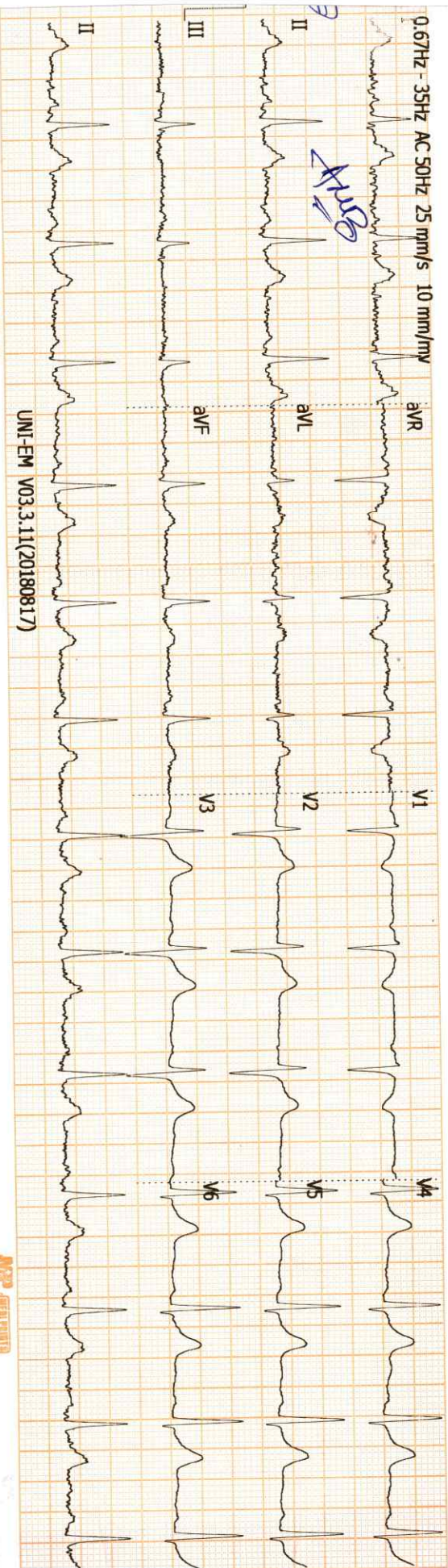
INTERPRETATION : LOW

HEALTHCARE MEDICAL CENTRE & DIAGNOSTICS
 Opp. Rajej...
 Triakur Village, E...
 Kandivali (East), Mumbai - 400101.

Dr. Dr. NUPUR RAI
 MBBS, DIPLOMA CARDIOLOGY
 Reg. No.: 2018110048



0.67Hz - 35Hz AC 50Hz 25 mm/s 10 mm/mV



MP - XI - 20

UNI-EM V03.3.1(20180817)

MP2



History :

B.P. :

Drugs :

Standard :

Auricular Rate : 9

Ventricular Rate : 86 bpm

Rhythm : ky.

Mechanism :

Voltage :

Axis :

P Waves :

PR Interval :

Q Waves : (u)

QRS Interval :

ST Segment :

T Waves :

QT Interval :

Extra Systoles :

REMARKS & CONCLUSIONS : normal