



BANK OF BARODA MEDICAL EXAMINATION REPORT

Client name :- Sab Surabhi Khare
 Ref. No. :-
 Date of birth :- 17.03.1991 Sex :- Male / Female
 Identification mark on the body :- Cut mark at cheen
 Photo ID Xerox :- Adhar 73576999 0323
 Date & place of medical examination :- 24.06.23 A

Request for medical exam. of **BANK OF BARODA** through Medi Assist Health Care India (Pvt.) Ltd.

- A) 1. Height :- 157 cm. 2. Weight :- 55 kgs.
 3. Chest Inspiration :- 99 cm. 4. Chest Expiration :- 93 cm.
 5. Abdomen Girth :- 86 cm.
 6. Blood Pressure :- I) 110/80 mm. of Hg. II) mm. of Hg.
 7. Pulse Rate :- 80 / minute. Character of pulse :- Regular
- B) 1. Are you now in good health ? Yes
 2. Are you currently taking any medicine ? No
 3.) Are you married ? Yes
 4. Have you ever had a positive test for HIV / AIDS / Malignancy ? No
 5. Have you ever suffering from sexually transmitted disease or Hepatitis B or C ?
 No
 6. Have you any congenital disorders ? No
 7. Have you any respiratory disorders ? No
 8. Have you any musculo skeletal disorders ? No
 9. Have you CVS disorders ? No
 10. Have you GI system disorders ? No
 11. Have you urinary system disorders ? Left ureteric cal at just proximal junction
 12. Have you reproductive system disorders ? No

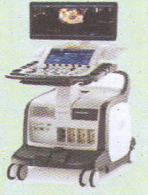16.11.22



ANUBIKSHAN

Diagnostic Centre

Near Asansol District Hospital(Main Gate)
S.B. Gorai Road, Asansol-713301
Email ID : anubikshan.dc@gmail.com
Ph. : 0341-3590332, M. : 9732362727, 7872772680



13. Have you Diabetes / Hypertension / Endocrine disorders? NO

14. Have you ever done any surgical operation? NO

15. Have you any ear problem? NO

16. Have you any eye problem? No, V.A. $\frac{40}{60}$, Nearkin No, CV - Normal

17. Have you nervous system disorders? NO

18. Have you any abnormal growth? NO

19. Have you any blood disorders? NO

20. What is general appearance of the client? Healthy

21. Does the appearance correspond with the age? Yes

22. Is there any personal peculiarities? NO

23. Tobacco (Stick / gms)- Panmasala/Cigar / Cigarette / Bidi / Gutkha Yes No
Alcohol(ml)- Beer / Wine / Hard Liquor :- Qty./ Day For No. of Yrs

24.Family History	Age if living	Age at death	Present state of health or cause of death
Father	62y	Good health	
Mother	57y	'	
Brother (s)	18y	'	
Sister (s)			

25. ANY REMARK BY THE MEDICAL EXAMINAR: - Left ureterine Cal. at proximal junction

[Signature]
Signature of the Client

DR. S. K. SHAH
Name of the Doctor

Date: - 24/06/2023

[Signature]
Signature & Seal of the Doctor

Dr. Sanjeev Kevin Shah
M.B.B.S., MD (Med.)
Reg. No. 16138

बैंक ऑफ बरोडा
Bank of Baroda

नाम
Name
सुरभि खरे
SURABHI KHARE

कर्मचारी कूट क्र.
E.C. No. 127035



Surabhi Khare

धारक के हस्ताक्षर
Signature of Holder

Kevin
जारीकर्ता प्राधिकारी
Issuing Authority



Kevin
Dr. Sanjeev Kevin Shan
M.B.B.S., MD (Med.)
Reg. No. 16138



भारत सरकार
GOVERNMENT OF INDIA



सुरभि खरे
Surabhi Khare
जन्म वर्ष / Year of Birth : 1991
महिला / Female



7357 6999 0323

आधार – आम आदमी का अधिकार

Surabhi



भारतीय विशिष्ट पहचान प्राधिकरण
UNIQUE IDENTIFICATION AUTHORITY OF INDIA

पता: D/O सुधीर कुमार खरे, ११६,,
शास्त्री विहार कॉलोनी त्रिमूर्ति नगर के
पास, राजीव गाँधी वार्ड, जबलपुर,
जबलपुर, मध्य प्रदेश, 482001

Address: D/O Sudhir Kumar
Khare, 116., shastri vihar colony
trimurti nagar ke pass, Rajeev
gandhi ward, Jabalpur, Jabalpur,
Madhya Pradesh, 482001

1947
1800 180 1947

help@uidai.gov.in

www.uidai.gov.in

P.O. Box No.1947,
Bengaluru-560 001



Sanjeev K Shal
Dr. Sanjeev Kevin Shar
M.B.B.S., MD (Med.)
Reg. No. 16138
24.06.20

Dr. Rajib Banerjee

B.Sc., B.H.M.S., DOS (Kol)
Consultant Homoeopathic Physician
and optometric Eye Specialist

ADDRESS :

1 No. Mohishila Colony
Bottala Bazar
Asansol - 3
Mob. : 9832197360

Rx

MS Khore Swrabhi.

Rt. Eye		Lt. Eye	
Sph	Cyl	Sph	Cyl
∅	∅	∅	∅
Near Add. →	∅	Near Add. →	∅

VA T of

Near Vn. - N6

ev - Normal

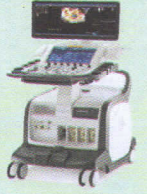RM 24/6/23

Chamber

Balananda Homoeo Clinic
Khejurtala More
Mohishila - 2, Asansol



Morning : 8.00 a.m. to 9.00 a.m.
Evening : 6.00 p.m. to 9.30 p.m.
Saturday Evening Closed
& Sunday Morning Closed



PATIENT'S NAME: - SURABHI KHARE

AGE: - 32 YEAR

GENDER: - FEMALE

REFERED BY DR: - M.O. BANK OF BARODA..

DATE: - 24.06.2023

REPORT

CHEST X - RAY P A VIEW

Soft tissue around chest and bony cage --- normal.


No active lung lesion in either field.

Cardiac configuration normal.

Pleural recesses are clear.

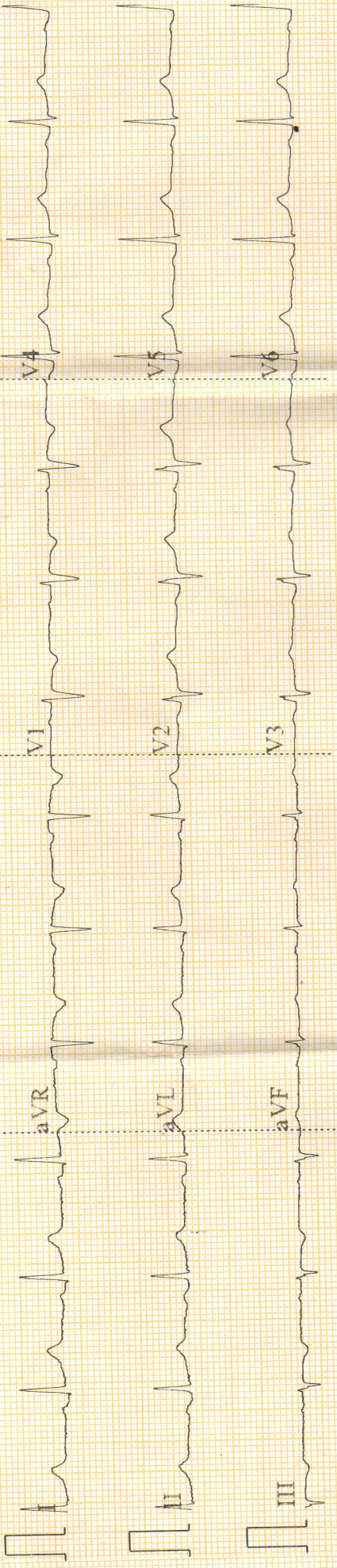
I M P R E S T I O N

✓ **NORMAL SKIAGRAM OF CHEST.**


DR. DIPANKAR DASGUPTA.
(M.B.B.S., D.M.R.D)
(Regd.No:- WB-34374)

BPL

ID: 820 24-06-2023 10:01:16 AM



0.67-35Hz AC50 25mm/s 10mm/mV ♡82 V1.0 SEMIP V1.7

CARDIART

BPL

ID: 820

Female

32 Years

cm

mmHg

kg

Diagnosis Information:
Sinus Rhythm
Poor R Wave Progression (V3)

[Handwritten signature]

[Handwritten signature]

Swathi Khanna, BSNR

Amritha

78 bpm

107 ms

152 ms

81 ms

372/425 ms

30/12/13 °

0.95/0.521 mV

HR

P

PR

QRS

QT/QTc

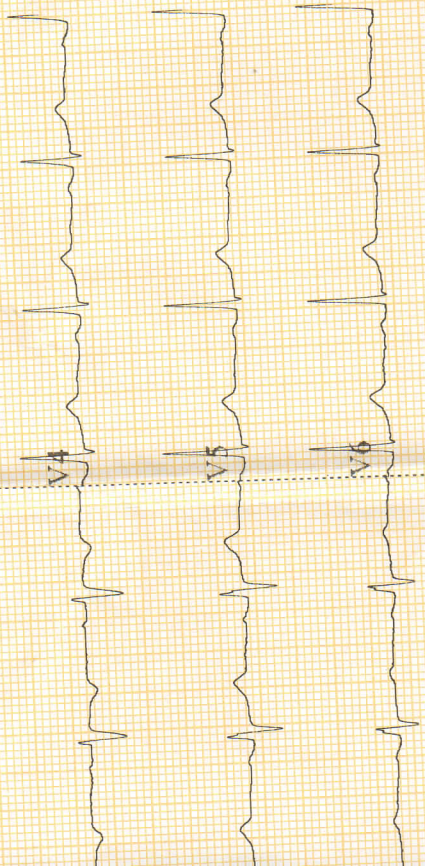
PQRST

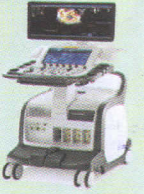RV5/SV1

Technician: DEBOJOYTI

Report Confirmed by:

CARDIART





ELECTRO CARDIO GRAM FORMAT

PATIENT'S NAME:- SURABHI KHARE	
AGE:- 32 YRS	SEX:- FEMALE
REF BY DR:- M.O. BANK OF BARODA..	DATE:- 24.06.2023

- ❖ RATE :- 78
- ❖ AXIS :- normal
- ❖ P-WAVE :- normal
- ❖ P-R :- normal
- ❖ QRS :- normal
- ❖ ST-T :- normal
- ❖ T-WAVE :- normal

➤ IMPRESSION :- Normal sinus rhythm


Dr. Sunil Gupta

48372
Dr. SUNIL GUPTA
M B B S MD (Medicine)
Reg No WBMC 48372



ANUBIKSHAN

Diagnostic Centre

Near Asansol District Hospital(Main Gate)
S.B. Gorai Road, Asansol-713301
Email ID : anubikshan.dc@gmail.com
Ph. : 0341-3590332, M. : 9732362727, 7872772680

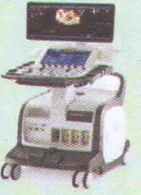PATIENT'S NAME: - SURABHI KHARE

AGE: - 32 YEAR

SEX: - FEMALE

REF. BY DR.:- M.O.BANK OF BARODA.

DATE: - 28.06.2023



U. S. G. OF WHOLE ABDOMEN

LIVER

Normal shape and size. Homogeneous echo texture of the liver is seen.
No focal parenchymal lesion is seen. (Measure:- 130.45 mm.)

PORTA

Portal vein at porta hepatis measures:- 5.63 mm. in diameter.
The appearance of porta is normal.

GALL BLADDER

Normal shape, size and position of the Gall Bladder is seen.
No calculus or any intraluminal mass is seen.

COMMON BILE DUCT

Common bile duct is not dilated (Measure:- 0.93 mm.)
No calculus or any intraluminal echogenicity.

PANCREAS

Normal echo-texture of the pancreas is seen. No space occupying lesion is seen.
Its relation with the anatomical landmark is normal.

SPLEEN

Normal dimension of the spleen is seen. It shows normal echo-texture.
No space occupying lesion is seen in the spleen. (Measure:- 90.50 mm.)

KIDNEYS

Both the kidneys are normal in shape, size, margin and axis.
Cortico medullary differentiation is normal.
No calculi or any hydronephrotic changes noted.
(Rt. Kidney Measure:- 91.88 mm. and Lt. Kidney Measure:- 96.86 mm. in length.)

URINARY BLADDER

Normal shape and size of the urinary bladder is seen.
No intraluminal echo is noted.

UTERUS

R/V, Bulky. (Measure: - 64.26 mm. x 27.44 mm. x 34.98 mm.)

OVARIES

Normal shape and size of the ovaries are seen.
Normal echo texture is seen.
No space occupying lesion is seen in the ovaries.
(Right ovary measure :- 29.88 mm. x 23.07 mm.)
(Left ovary measure :- 23.33 mm. x 24.89 mm.)

➤ IMPRESSION :-

❖ NORMAL STUDY.

Handwritten signature and date: 28/6

ADVICE
Clinical co-relation.

DR. DIPANKAR DASGUPTA.
(M.B.B.S., D.M.R.D)
(Regd.No:- WB-34374)

**PATHOLOGY ★ FNAC ★ PAP ★ USG-3D ★ ECHO COLOUR DOPPLER
ECG ★ TMT ★ NCS ★ BMG ★ BERA ★ VEP ★ EEG**

PATIENT'S NAME:- SURABHI KHARE

AGE:- 32 YEAR SEX:- FEMALE

REF BY DR: - M.O. BANK OF BARODA.

DATE:- 28.06.2023

USG OF WHOLE ABDOMEN

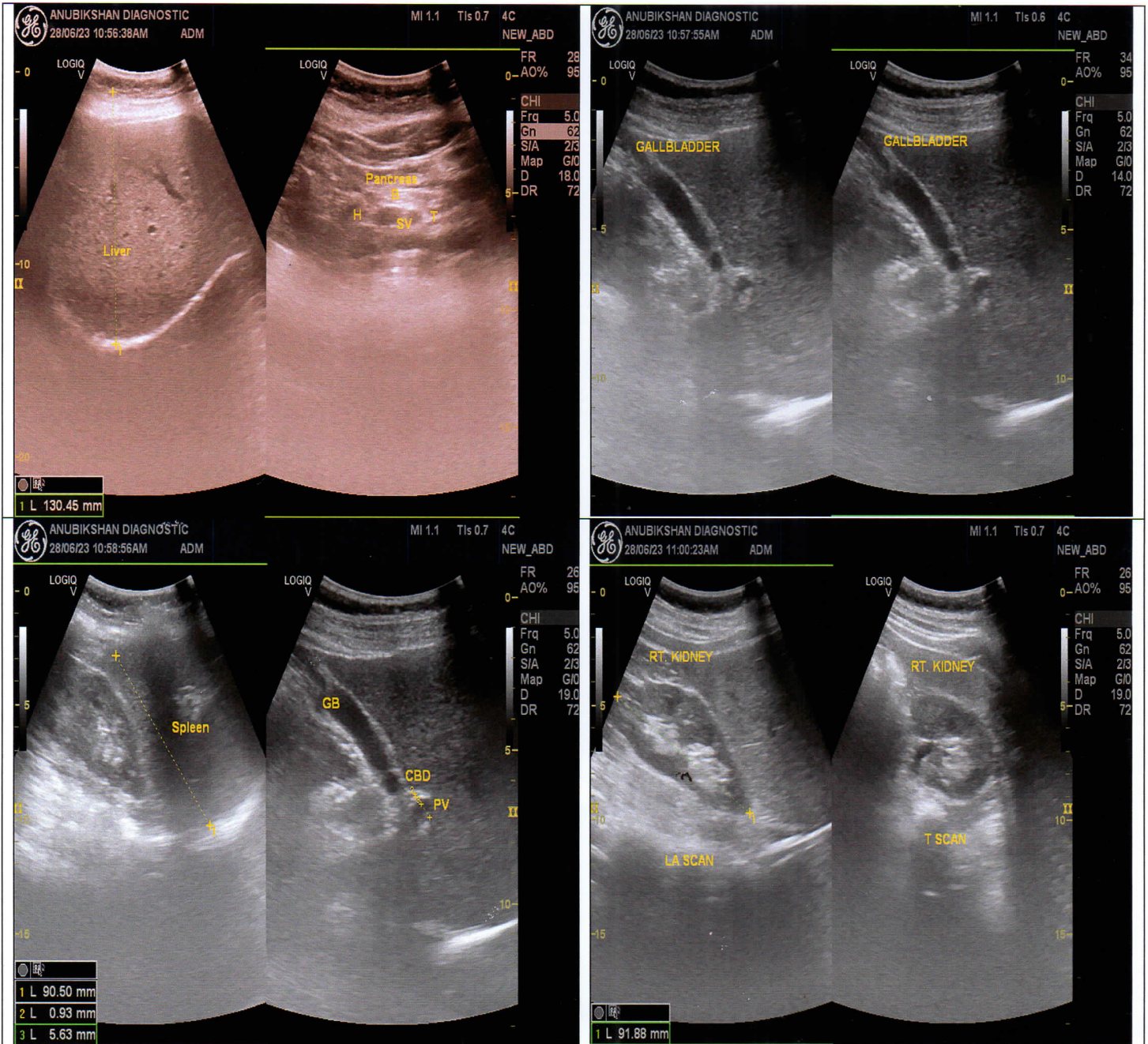
ANUBIKSHAN

DIAGNOSTIC CENTRE

**NEAR ASANSOL. DISTRICT HOSPITAL (MAIN GATE)
S.B.GORAI ROAD (EAST), PIN – 713301**

LANDLINE: - 0341-3590332 //MOB 7872772680

E- mail ID:- anubikshan.dc@gmail.com (1)



PATIENT'S NAME:- SURABHI KHARE

AGE:- 32 YEAR SEX:- FEMALE

REF BY DR: - M.O. BANK OF BARODA.

DATE:- 28.06.2023

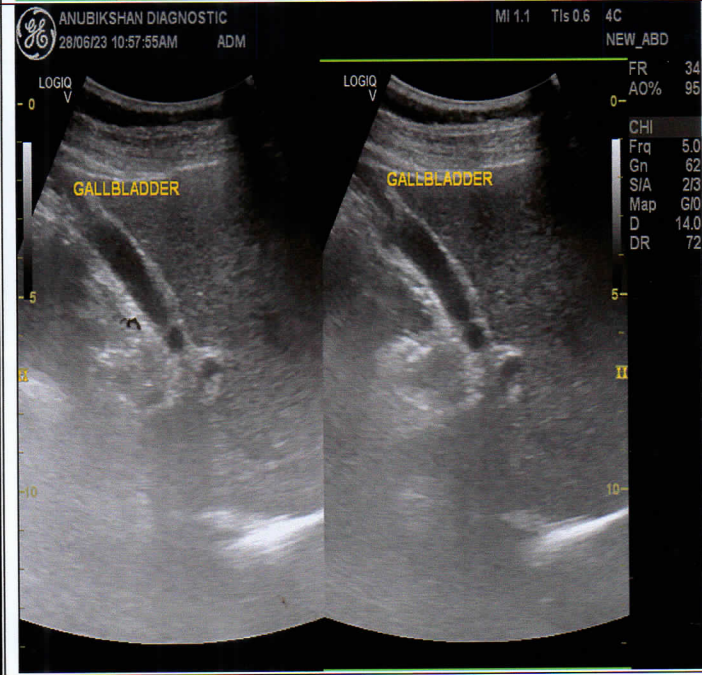
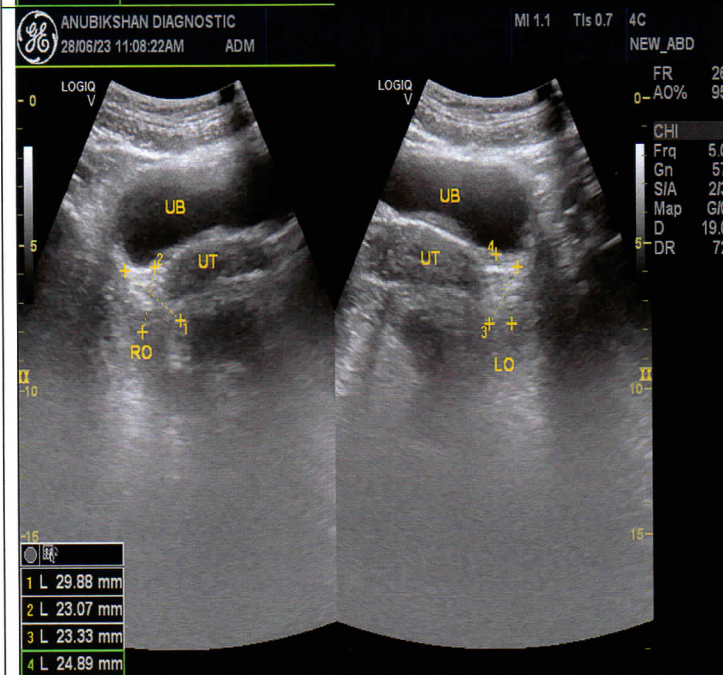
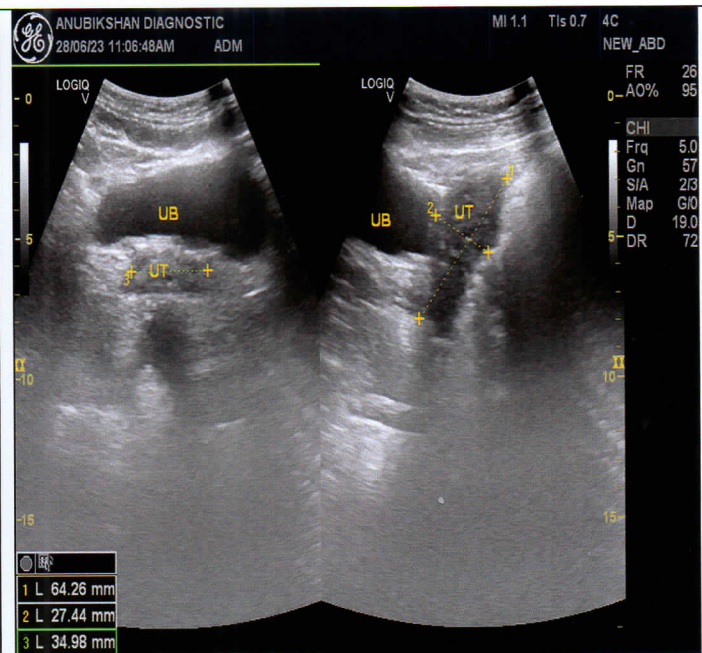
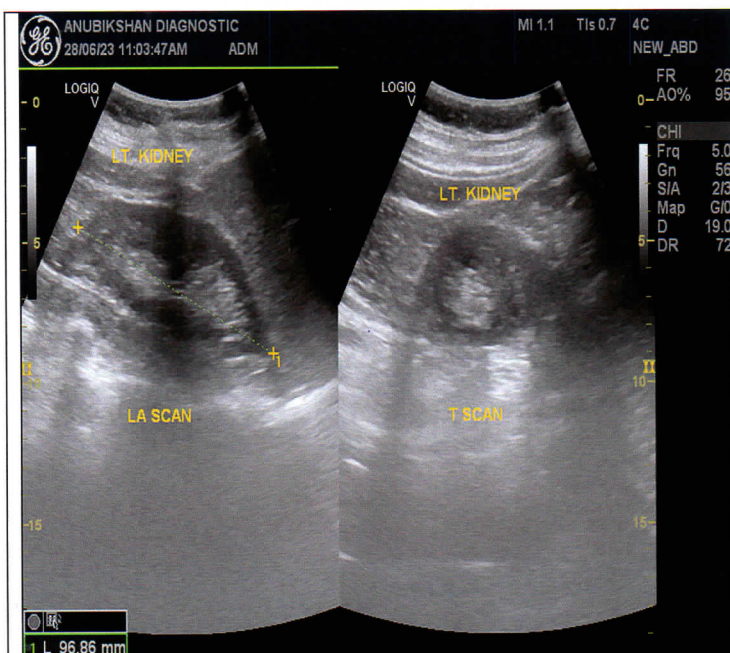
USG OF WHOLE ABDOMEN

ANUBIKSHAN **DIAGNOSTIC CENTRE**

**NEAR ASANSOL. DISTRICT HOSPITAL (MAIN GATE)
S.B.GORAI ROAD (EAST) , PIN – 713301**

LANDLINE: - 0341-3590332 //MOB 7872772680

E- mail ID:- anubikshan.dc@ gmail.com (2)





UID: 1307462

Nationality: Indian



Patient ID: 012306280129	Primary Sample Collection Time: 28/Jun/2023 13:30:07
Name: Ms. SURAVI KHARE	Collection Date/Time: 28/Jun/2023 01:38PM
Age/Gender: 32 Y/Female	Received Date/Time: 28/Jun/2023 07:38PM
Referred By: Dr. M.O. BANK OF BARODA	Approved Date/Time: 28/Jun/2023 09:06PM
LabID: 11307397	Print Date/Time: 28/Jun/2023 09:53PM
SpecimenType: Serum	Client Grp.: NIBEDITA COLLECTION

DEPARTMENT OF IMMUNOLOGY

Test Description	Observed Value	Unit	Method	Biological Ref. Interval
T3,T4,TSH (THYROID PROFILE)				
Triiodothyronine, Total (TT3)	1.32	ng/mL	ECI	0.97-1.69
Thyroxine, Total (TT4)	9.24	ug/dL	ECI	5.53-11.0
Thyroid Stimulating Hormone (TSH)	2.07	uIU/mL	ECI	0.46-4.68

Ultrasensitive / Third generation assay

TSH Clinical Condition	Range (uIU/mL) ECI	Range (uIU/mL) CMIA
Euthyroid	0.46-4.68	0.35-4.94
Hyperthyroid	<0.46	<0.35
Hypothyroid	>4.68	>4.94

* TSH: Interpretation (Pregnancy)

REFERENCE GROUP	REFERENCE RANGE in uIU/mL (As per American Thyroid Association)
Pregnancy	
1st Trimester	0.100 – 2.500
2nd Trimester	0.200 – 3.000
3rd Trimester	0.300 – 3.000

COMMENT :

The levels of thyroid hormone (T3 & T4) Are Low In case of Primary, secondary and tertiary hypothyroidism and sometimes in non-thyroidal illness also. Increased levels are found in grave's disease, hyperthyroidism and thyroid hormone resistance. T3 levels are also raised in T3 thyrotoxicosis. TSH levels are raised in primary hypothyroidism and are low in hyperthyroidism and secondary hypothyroidism.

Disclaimer: The test result mentioned here should be interpreted in view of clinical condition of the patient. In case of any clinical suspicion regarding any parameter, repeat test with fresh sample essential to conclude.

*** End Of Report ***

Vinay Shanker

Dr. Vinay Shanker
MBBS, MD (Path)
Senior Consultant Pathologist



MC-4154

Dr. N. Mondal

Dr. N. Mondal
MD (Biochemistry)
Consultant Biochemist