

CKOR.0000138856
31 Years

GELLE SREE LAKSHMI
Female

11-Mar-23 11:11:16 AM

Rate 84

PR 136

QRSD 83

QT 358

QTc 424

--AXIS--

P 72

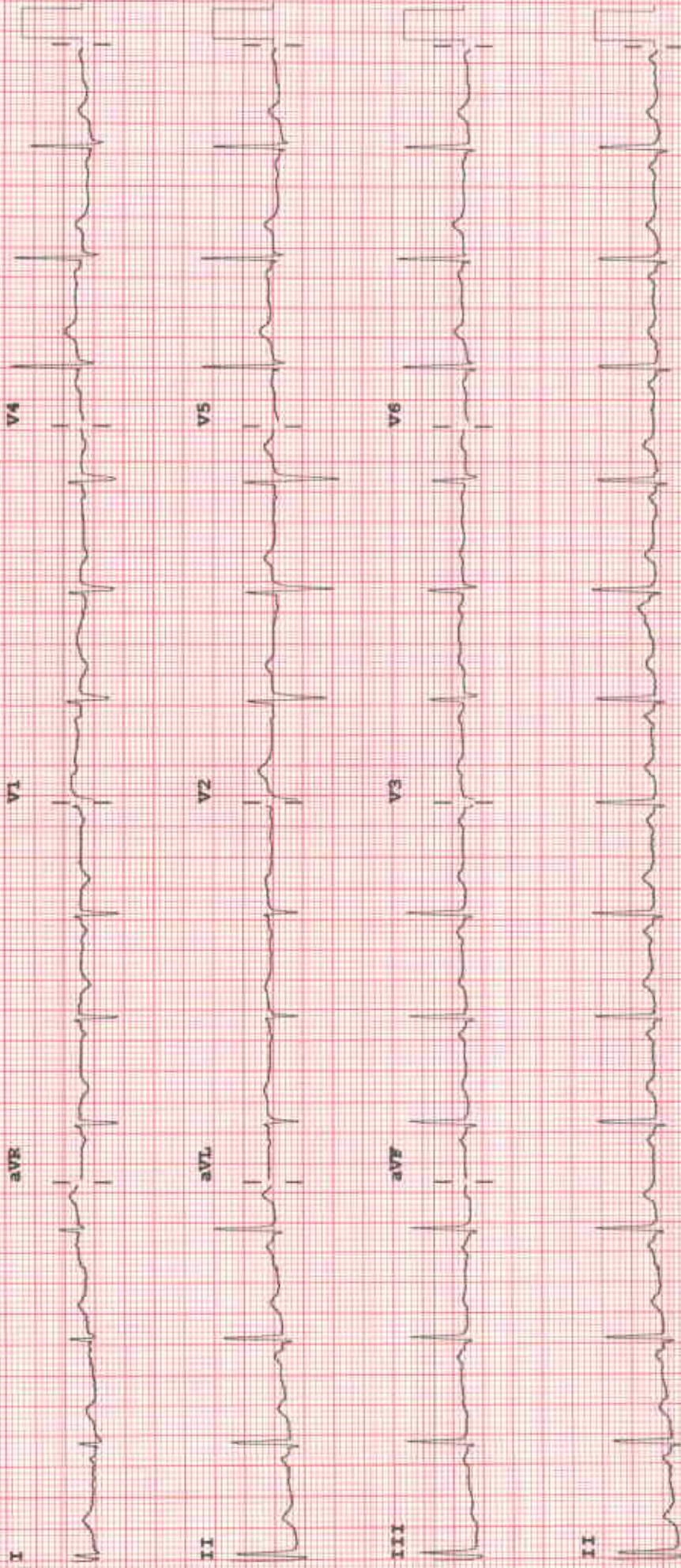
QRS 83

T 29

12 Lead; Standard Placement

CKOR.0000138856
MRS. GELLE SREE LAKSHMI

Age: 31 Year(s) Female
11 Mar 2023 10:08:17 AM



Device:

Speed: 25 mm/sec

Limb: 10 mm/mV

Chest: 10.0 mm/mV

P 50~ 0.15-100 Hz

100B

CL

P?

DEPT. OF APOLLO HEALTH CHECK



CASE RECORD

CKOR.0000136856
 MRS. GELLE SREE LAKSHMI
 Age: 31 Year(s) Year(s)/Female
 11 Mar 2023 10:08:18 AM

Age :

Sex : M/F

UHID :

Physical Examination

General : Build Height *174* Weight *62-8* BMI :

Anaemia Icterus Cyanosis Clubbing

Oedema Glands

HEAD & NECK :

ENT :

CVS : Heart Rate & Rhythm *74 bpm*

B.P. : Supine *121/86* Sitting Standing *SpO2 100*

Chest shape *normal*

Heart Sounds

Murmurs

Thrills

RS : Rate & Type

Breath Sounds

Screening Echo
 Normal LV function
 LVEF - 60%
 No RWMA

Abd : *91 c-*

6366901707
080-41103111

Form # 8301



Place Label Here
Name : Mrs. Gelle Sree Lakshmi
CKOR.0000138856
Age : 31Y/F
If label not available write Pt Name UHID No
Age, Sex, Date Name of Treating Physician

DENTAL CASE SHEET

CHIEF COMPLAINT : ANC

MEDICAL HISTORY : NRA

FINDINGS :

Drug Allergy : Not Answer

Caries : $\frac{6}{6}$

Abrasion :

Missing Teeth :

Calculus : Ca⁺⁺ Sn⁺⁺

Impactions :

Mobility :

Attrition :

Restored teeth :

Root Stumps :

Others :

87654321	12345678
87654321	12345678

DIAGNOSIS : CGG

X-rays :

IOPA :

OPG

Treatment Plan : Adv.

Oral prophylaxis
Restoration with $\frac{6}{6}$

Dr. Chandea
11/3/23



Dr. Shalini Shetty
 MBBS, MS (Oph), FRCS (UK)
 Sr. Consultant - Ophthalmology

Place Label Here
 Mrs. Geetha Sree Lakshmi
 31/F 138856
 If label not available, write Pt. Name, UHID No.,
 Age, Sex, Date, Name of Treating Physician

Allergies :	Fall Risk Assessment		Wt: _____	Ht: _____	T: _____	P: _____	BP: _____
	H/o fall (within 1 year)	Yes No	Mobility Aid		Gait		<input type="checkbox"/> Psychological & Social Assessment done
		Yes No	Dep.	Indep.	Pain _____/10		

Routine Eye Test

R L

6/6 6/6

without glasses

NG NG

Colour vision

$\frac{17}{17}$ $\frac{17}{17}$

Clinically Normal

Kindly get this document scanned at the counter for the record purpose

[Signature]

Signature and Date

11/03/23



Dr. Jyoti Jain
 MBBS, DNB (Family Medicine), PGDGM
 (Dip in Geriatric Medicine)
 Senior Consultant - Dept. of Apollo Health Check

Place Label Here
OKOR - 138858
Mrs. Othello Snee Lakshmi
 If label not available, write Pt. Name, UHID No.,
 Age, Sex, Date, Name of Treating Physician

Allergies : NEEDA.	Fall Risk Assessment		Wt: 62.5 Ht: 179 T: _____ P: 74 BP: 121/86 mmHg
	H/o fall (within 1 year) Mobility Aid Gait	Yes No Yes No Dep. Indep.	Pain _____ /10 <input type="checkbox"/> Psychological & Social Assessment done

Mild dyslipidemia LDL-102; HDL 31

Medicine Reconciliation Dose & Frequency

Advise

Advice & Plan

Regular Exercise
 low fat diet

Kindly get this document scanned at the counter for the record purpose

After 6 weeks - lipid profile

Jyoti Jain

11/3/23

Signature and Date

LBC-119101

CON.

8095271160

QF400AHB.pf.8203

DEPT. OF APOLLO HEALTH CHECK



GYNAECOLOGY CONSULT

Name :	CKOR.0000136056 MRS. GELLE SREE LAKSHM	UHID :		Date :	10-3-23
Age :	Age: 31 Year(s) Year(s)/Female 11 Mar 2023 10:08:16 AM	Consultant Gynaecologist :	Dr. Betty Antony		
DRUG ALLER		NIL.			

Complaints (related to Gynaec) - NIL SPECIFIC / YES

H/O intermenstrual spotting for 2 to 3 days

Known to have Diabetes / Hypertension / IHD / Asthma / Thyroid / Others NIL

Past Medical / Surgical History : NIL

Family History : NIL

OTHER SYSTEMS: NIL

GYNAEC HISTORY :

- Marital Status - SM Others
- Children - 1
- Deliveries - NVD
- L.C.B. - 3-7yr
- Abortion - -
- Periods - Regular 3-4/30ds
- L.M.P. - 18-2-23
- Menopause - -
- Contraception - Cofu-T ly back

Present Medication : NIL

GYNAEC EXAMINATION :

- P/A - soft
- P/V - not bulky
- S/E - Vaginal Normal. Cofu-T ly back
- P/R - not willing for Papsmear

GENERAL EXAMINATION :

- Weight : _____ Kgs, Height : _____ cm
- General Condition :
- Blood Pressure :
- Thyroid : NAD
- Others :

BREASTS : No shadows palpable

PAP SMEAR: Taken / Not Taken (Reason)

OPINION & ADVICE : Papsmear - 3 year

REVIEW DETAILS : (with date)
With Patient / With reports only

→ Papsmear - 3 year
→ B/L sonogram 3 year

Signature with Date & Time

11-3-23
3-15 PM

P.T.O. For more space

Jan 2014

APOLLO HOSPITALS
BANNERGHATTA ROAD
BANGALORE 560076

Station
Telephone:

EXERCISE STRESS TEST REPORT

Patient Name: GELLE SREE LAKSHMI,
Patient ID: CKOR/138856
Height: 174 cm
Weight: 62 kg

DOB: 24.08.1991
Age: 31yrs
Gender: Female
Race: Indian

Study Date: 11.03.2023
Test Type: Treadmill Stress Test
Protocol: BRUCE

Referring Physician: AHC
Attending Physician: DR K M NAIR
Technician: Suramya

Medications:
NONE

Medical History:
NONE

Reason for Exercise Test:
Screening for CAD

Exercise Test Summary

Phase Name	Stage Name	Time in Stage	Speed (mph)	Grade (%)	HR (bpm)	BP (mmHg)	Comment
PRETEST	SUPINE	00:04	0.00	0.00	101	120/80	
	STANDING	00:02	0.00	0.00	101	120/80	
	HYPERV.	00:02	0.00	0.00	100	120/80	
EXERCISE	WARM-UP	00:12	0.90	0.00	100	120/80	
	STAGE 1	03:00	1.70	10.00	130	120/80	
	STAGE 2	03:00	2.50	12.00	148	140/80	
RECOVERY	STAGE 3	01:36	3.40	14.00	166	140/80	
		03:23	0.00	0.00	103	130/80	

The patient exercised according to the BRUCE for 7:36 min:s, achieving a work level of Max. METS: 10.10. The resting heart rate of 100 bpm rose to a maximal heart rate of 166 bpm. This value represents 87% of the maximal, age-predicted heart rate. The resting blood pressure of 120/80 mmHg, rose to a maximum blood pressure of 150/80 mmHg. The exercise test was stopped due to Target heart rate achieved.

Interpretation

Summary: Functional Capacity: normal.
HR Response to Exercise: appropriate.
BP Response to Exercise: normal resting BP - appropriate response.
Chest Pain: none.
Arrhythmias: none.
ST Changes: none.

Conclusions

IMP:- STRESS TEST NEGATIVE FOR INDUCIBLE ISCHEMIA.

Physician

Technician

DEPARTMENT OF RADIOLOGY

Patient's Details	: Mrs. GELLE SREE LAKSHMI	
UHID	: CKOR.0000138856	F 031Y
I.P.No./Bill No.	: AHBHC119209	Ward/Bed No. : AHC / AHC
Accession Number	: 10601.223022810	Scanned on : 11-Mar-2023 14:40
Referring Doctor	: null	Reported On :

ULTRASOUND WHOLE ABDOMEN

Clinical Information: - Routine health checkup.

Liver appears normal in size, shape and echopattern. No focal parenchymal lesions identified. No evidence of intra/extrahepatic biliary tree dilatation noted. Portal vein appears to be of normal size.

Gall bladder is moderately distended. No definite calculi identified. No evidence of abnormal wall thickening noted.

Spleen appears normal in size, shape and echopattern. No focal parenchymal lesions identified.

Pancreas appears normal in size, shape and echopattern. No definite calcification or ductal dilatation noted.

Both kidneys appear normal in size, shape and echopattern. Corticomedullary differentiation appears maintained. No evidence of calculi or hydronephrosis seen on either side.

Urinary bladder is distended and appears normal. No evidence of abnormal wall thickening noted.

Uterus appears normal in size. Myometrial echoes appear normal. Endometrial thickness measures ~ 5 mm. An echogenic linear focus noted within the endometrial cavity in lower uterine segment. IUD in situ.

Both ovaries appear normal in size and echopattern.

No evidence of ascites or pleural effusion seen.

=====
IMPRESSION:

UD in situ at lower uterine segment.
- Suggested clinical correlation.

=====
(Enclosed report) M/

DR. APURVA A J
RESIDENT

DR. ARUNA R. PATIL
MD, DNB, FRCR
CONSULTANT

N.B. : This is only a professional opinion and not the final diagnosis. Radiological investigations are subject to variations due to technical limitations. Hence, correlation with clinical findings and other investigations should be carried out to know true nature of illness.