


भारत सरकार
Government of India


Soumik Biswas
DOB : 10/02/1989
Male

5998 0365 4565



आधार - आम आदमी का अधिकार

APOLLO CLINIC OM TOWER
36C, B.I.ROAD OPP "RBU"
KOL 700002
Ph 033 25565555
033 25563333

Soumik Biswas



संयुक्त विशिष्टता प्रमाण अधिकारक

Unique Identification Authority of India

Address:

S/O: Bimal Krishna Biswas, 169, ALIPORE MAIN ROAD,
North Dumdum (m), North 24 Parganas, Nimta, West
Bengal, 700049

5998 0365 4565

1800 300 1947



help@uidai.gov.in



www.uidai.gov.in

APOLLO CLINIC OM TOWER

36C, B.T.ROAD OPP "RBU"
KOL 700002

Ph 033 25565555

033 25563333

APOLLO CLINIC ON TOWER
36C, B.T. ROAD OPP "RBU"
KOL 700002
Ph 033 25565555
033 25563333

Soumik Biswas



APOLLO CLINIC
Opp. of Rabindra

36C, B.T. Road, Kolkata

E-mail : sinthimor@theap

satyamcreditpvtltd@gmail.com

033 2556 5555

+91 98521 66666

+91 74392 97827

E.Z.

पिसेत वर रिपॉर्डीशन को लोडणे
व्यक्तिगत मालमाल (सुरक्षा), बँके आणि बँकेचा, बँकेचा कॉर्पोरेट सेक्टर
से-26, जी ब्लॉक, बँकेचा-कुर्ना कॉम्प्लेक्स, मुंबई 400 051, भारत
फोन 91 22 6688 5198 फॅक्स 91 22 2652 5747

If found, please return to:
Asst. General Manager (Security), Bank of Baroda, Baroda Corporate Centre
C-26, G Block, Eastern Kurla Complex, Mumbai 400 051, India

फोन : 91 22 6688 5198 फॅक्स : 91 22 2652 5747

नाम व पत्ता यास वर सूचना मिळते सांख्यिकी व पत्ते यात
Name & Ph./Person of emergency contact : **Bimal Krishna Biswas (Father)**
98367 50036

रक्त गट/रक्त समूह : **B+ve** अर्पण/Allergy : **Nil**
अर्पण निशान/Identification mark : **Stretch marks on Left Arm**

आर्पण कार्यालय / Issuing Office
BOB, Eastern Zone, Plot No. 382, Block - GN, Sector - V, Salt Lake City, Kolkata - 700 061

APOLLO CLINIC OM TOWER

26C, B.I. ROAD OPP "RBU"

KOL 700002

Ph 033 25556555

933 25556333

To,
The HR Managers
Appollo Clinic
Sinthi More Branch

Dated: 26/01/2022.

[Sub: Not willing to test for ECG]
and TMT

Dear Sir / Madam,

I, Mr Soumik Biswas, am not willing to appear for ECG test as I recently tested the same and all was found regular for me.

So, I do not want to test the same and requested the operators with full my consent not to perform ECG and also the TMT.

Regards,

Soumik Biswas.

APOLLO CLINIC OM TOWER
36C, B.T ROAD OPP "RBU"
KOL 700002
Ph 033 25565555
033 25563333



LETTER OF APPROVAL / RECOMMENDATION

To,

The Coordinator,
Mediwheel (Arcofemi Healthcare Limited)
Helpline number: 011- 41195959

Dear Sir / Madam,

Sub: Annual Health Checkup for the employees of Bank of Baroda

This is to inform you that the following employee wishes to avail the facility of Cashless Annual Health Checkup provided by you in terms of our agreement.

PARTICULARS	EMPLOYEE DETAILS
NAME	MR. BISWAS SOUMIK
EC NO.	112132
DESIGNATION	BRANCH OPERATIONS
PLACE OF WORK	KHARDAHA
BIRTHDATE	10-02-1989
PROPOSED DATE OF HEALTH CHECKUP	26-01-2022
BOOKING REFERENCE NO.	21M112132100009966E

This letter of approval / recommendation is valid if submitted along with copy of the Bank of Baroda employee id card. This approval is valid from **21-01-2022** till **31-03-2022**. The list of medical tests to be conducted is provided in the annexure to this letter. Please note that the said health checkup is a **cashless facility** as per our tie up arrangement. We request you to attend to the health checkup requirement of our employee and accord your top priority and best resources in this regard. The EC Number and the booking reference number as given in the above table shall be mentioned in the invoice, invariably.

We solicit your co-operation in this regard.

Yours faithfully,

Sd/-

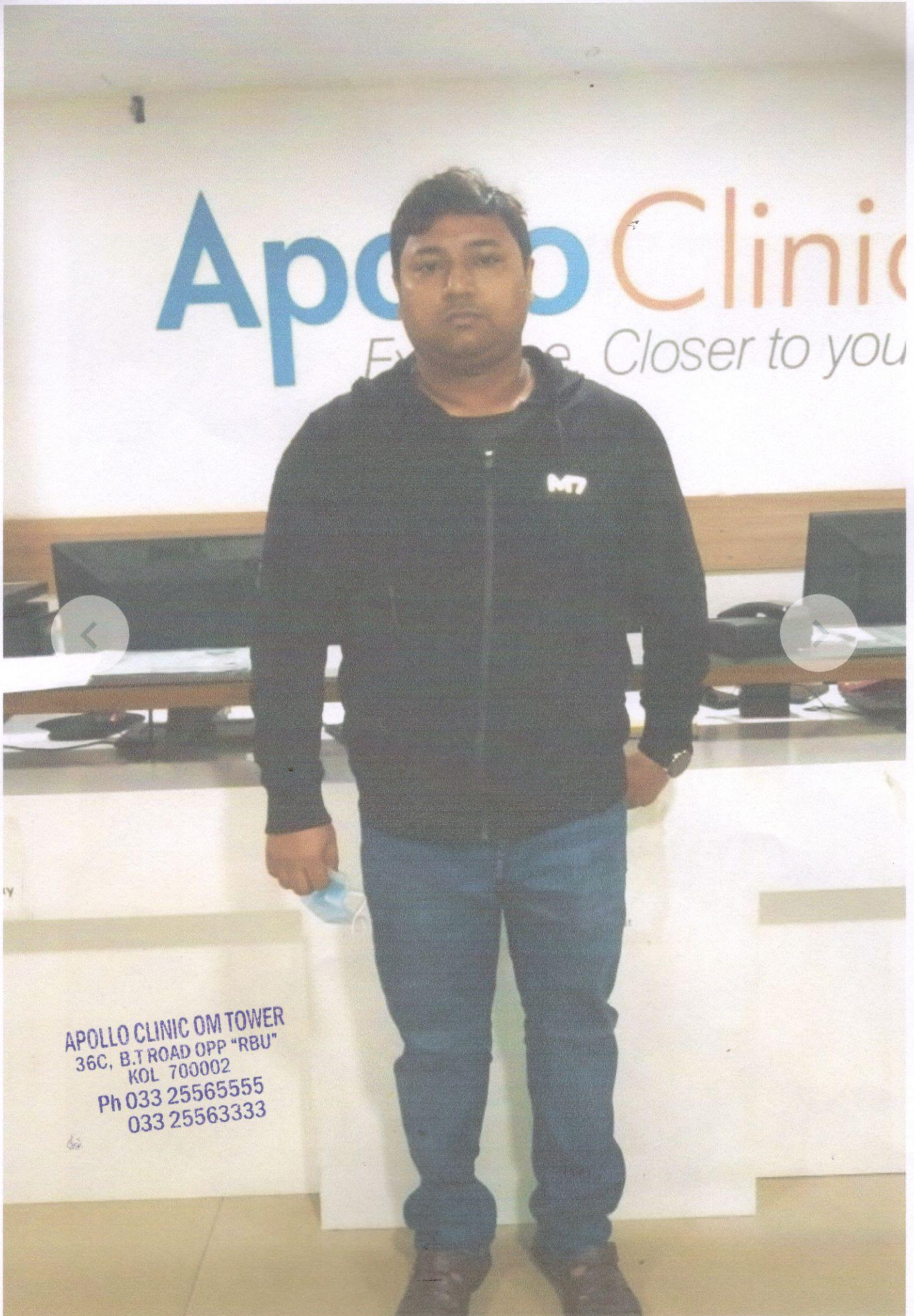
Chief General Manager
HRM Department
Bank of Baroda

(Note: This is a computer generated letter. No Signature required. For any clarification, please contact Mediwheel (Arcofemi Healthcare Limited))

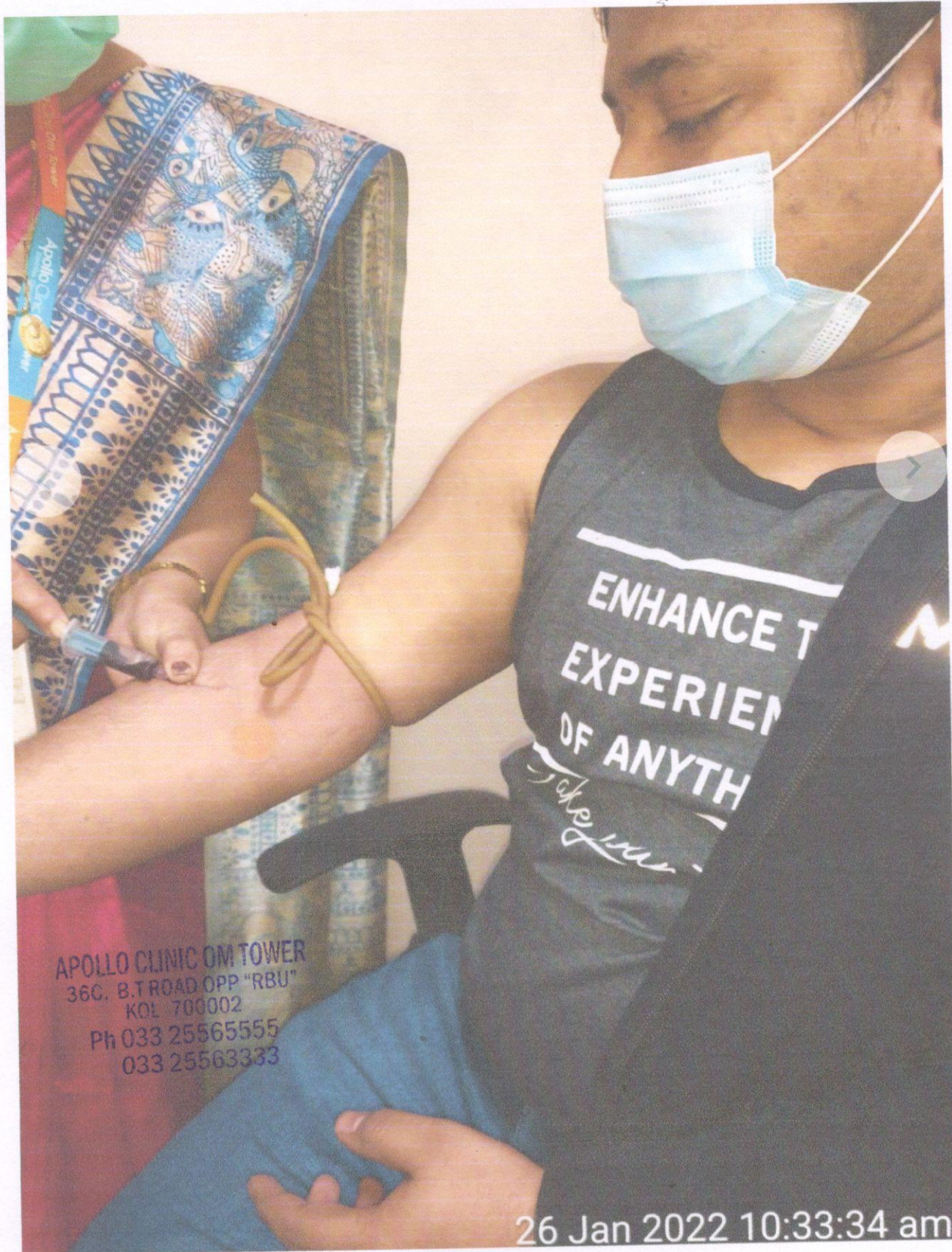
APOLLO CLINIC OM TOWER
36C, B.T ROAD OPP "RBU"
KOL 700002
Ph 033 25565555
033 25563333

SUGGESTIVE LIST OF MEDICAL TESTS

FOR MALE	FOR FEMALE
CBC	CBC
ESR	ESR
Blood Group & RH Factor	Blood Group & RH Factor
Blood and Urine Sugar Fasting	Blood and Urine Sugar Fasting
Blood and Urine Sugar PP	Blood and Urine Sugar PP
Stool Routine	Stool Routine
Lipid Profile	Lipid Profile
Total Cholesterol	Total Cholesterol
HDL	HDL
LDL	LDL
VLDL	VLDL
Triglycerides	Triglycerides
HDL / LDL ratio	HDL / LDL ratio
Liver Profile	Liver Profile
AST	AST
ALT	ALT
GGT	GGT
Bilirubin (total, direct, indirect)	Bilirubin (total, direct, indirect)
ALP	ALP
Proteins (T, Albumin, Globulin)	Proteins (T, Albumin, Globulin)
Kidney Profile	Kidney Profile
Serum creatinine	Serum creatinine
Blood Urea Nitrogen	Blood Urea Nitrogen
Uric Acid	Uric Acid
HBA1C	HBA1C
Routine urine analysis	Routine urine analysis
USG Whole Abdomen	USG Whole Abdomen
General Tests	General Tests
X Ray Chest	X Ray Chest
ECG	ECG
2D/3D ECHO / TMT	2D/3D ECHO / TMT
Stress Test	Thyroid Profile (T3, T4, TSH)
PSA Male (above 40 years)	Mammography (above 40 years) and Pap Smear (above 30 years).
Thyroid Profile (T3, T4, TSH)	Dental Check-up consultation
Dental Check-up consultation	Physician Consultation
Physician Consultation	Eye Check-up consultation
Eye Check-up consultation	Skin/ENT consultation
Skin/ENT consultation	Gynaec Consultation



APOLLO CLINIC OM TOWER
36C, B.T ROAD OPP "RBU"
KOL 700002
Ph 033 25565555
033 25563333



APOLLO CLINIC OM TOWER
36C, B.T ROAD OPP "RBU"
KOL 700002
Ph 033 25565555
033 25563333

26 Jan 2022 10:33:34 am

DR. BOUDHAYAN BHATTACHARJEE
MBBS. (MEDICAL COLLEGE, KOLKATA) MD (TROPICAL MEDICINE)
CONSULTANT PHYSICIAN & INTENSIVIST

APOLLO CLINIC @ OM TOWER
Opp. of Rabindra Bharati University

TO WHOM IT MAY CONCERN

THIS IS TO CERTIFY THAT, **MR. SOUMIK BISWAS,**
AGE- 32Y/MALE, IS PHYSICALLY FIT BUT HE DETECTED VLDL
CHOLESTROL.

DATE: 29.1.22.....

Boudhayan Bhattacharjee

SIGNATURE

STAMP

Dr. BOUDHAYAN BHATTACHARJEE
MBBS, MD (TROPICAL MEDICINE)
85631 of WBMC

APOLLO CLINIC OM TOWER
36C, B.T ROAD OPP "RBU"
KOL 700002
Ph 033 25565555
033 25563333

APOLLO CLINIC @ OM TOWER
Opp. of Rabindra Bharati University
Licensee : Satyam Credit Pvt. Ltd.
36C, B. T. Road, Kolkata - 700 002
E-mail : sinthimor@theapolloclinic.com
satyamcreditpvtltd@gmail.com



033 2556 3333



033 2556 5555



+91 98521 66666



+91 74392 97827

DR. ABHIRUP MUKHERJEE


BDS (WBUHS)
Oral & Dental Surgeon
Regn.No. 3726 Part A (Wbdc)

TO WHOM IT MAY CONCERN

THIS IS TO CERTIFY THAT **MR.SOUMIK BISWAS, 32Y/MALE,**
HAS NO ORAL PROBLEM.

THERE IS NO CAVITY AND BAD SMELL OBSERVED IN HIS MOUTH.

DATE: 29-03-2022



SIGNATURE
DC STAMP

APOLLO CLINIC OM TOWER
36C, B.T ROAD OPP "RBU"
KOL 700002
Ph 033 25565555
033 25563333

Dr. ABHIRUP MUKHERJEE
BDS (WBUHS)
Oral & Dental Surgeon
Regn. No. 3726 Part A (WBDC)



DR. RAKTIMA BAKSHI MANDAL

CONSULTANT EYE SURGEON
& OPHTHALMOLOGIST

TO WHOM IT MAY CONCERN

THIS IS TO CERTIFY THAT MR. SOUMIK BISWAS,
AGE- 32Y/MALE.

HE IS WITH CLEAR VISION, WITH NO COLOR BLINDNESS.

RIGHT EYE	NORMAL
LEFT EYE	NORMAL

DATE: 29/1/22.....

R. B. Mandal.....

SIGNATURE
DC STAMP

APOLLO CLINIC OM TOWER
36C, B.T.ROAD OPP "RBU"
KOL 700002
Ph 033 25565555
033 25563333

DR. RAKTIMA BAKSHI MANDAL
M.B.B.S., M.S. (OPHTHALMOLOGY)
Regn. No.. 69521 of WBMC
Consultant Eye Surgeon

APOLLO CLINIC @ OM TOWER
Opp. of Rabindra Bharati University
Licensee : **Satyam Credit Pvt. Ltd.**

36C, B.T. Road, Kolkata - 700 002
E-mail : sinthimor@theapolloclinic.com
satyamcreditpvtltd@gmail.com



033 2556 3333



033 2556 5555



+91 98521 66666



+91 74392 97827

DR. SOURADEEP RAY

MBBS, MS (ENT)
ASSOCIATE PROFESSOR R.G. KAR MEDICAL, KOLKATA.
REGD.NO. 63999 (WBMC)

TO WHOM IT MAY CONCERN

THIS IS TO CERTIFY THAT
MR. SOUMIK BISWAS, AGE- 32Y/MALE,
HAS NO PROBLEM IN HIS EAR, NOSE AND THROAT.

HIS EAR IS CLEAN, NO HEARING PROBLEM OBSERVED,
NASAL PASAGE IS CLEAR, WITH PROPER SMELLING CAPACITY,
THROAT IS CLEAR, NO INFECTION FOUND IN TONSILS.

DATE:29/10/2022.....

Souradeep Ray.....

SIGNATURE
DC STAMP

APOLLO CLINIC OM TOWER
36C, B.T.ROAD OPP "RBU"
KOL 700002
Ph 033 25565555
033 25563333



DEPARTMENT OF RADIOLOGY X-RAY REPORT OF CHEST-PA

MR. NO- FSIN.0000002684

SEX- MALE

NAME- SOUMIK BISWAS

EXAMINATION DATE-26/01/2022

AGE- 32 YRS

REPORT DATE- 27/01/2022

REF DR- SELF

FINDINGS:


- Bilateral lung fields are clear.
- Tracheal shadow is in the midline.
- Bilateral CP angle are clear.
- Both hilum appear unremarkable.
- CTR within normal limit.
- No definite bone fracture is noted.


DR. ARNAB MANDAL


MD, Physician, PGDUS (Delhi) CEBT-USG (WBUHS KOLKATA)
Fellow of Jefferson Ultrasound Radiology and Education Institute
Philadelphia Ex-Radiology Resident (S.E. Railway)
Regd.No:72022(WBMC)

APOLLO CLINIC @ OM TOWER
Opp. of Rabindra Bharati University
Licensee : **Satyam Credit Pvt. Ltd.**
36C, B.T. Road, Kolkata - 700 002
E-mail : sinthimor@theapolloclinic.com
satyamcreditpvtltd@gmail.com

 **033 2556 3333**

 **033 2556 5555**

 **+91 98521 66666**

 **+91 74392 97827**

NAME:MR.SOUMIK BISWAS	MR. NO: FSIN-0000	DATE: 28/01/2022
AGE :32YRS	SEX:MALE	REF. BY: SELF

ULTRASOUND OF WHOLE ABDOMEN

LIVER: Liver is Enlarged moderate fatty changes seen in size (17.98cm) shape, outline and echotexture. The intrahepatic tubular structures are normal. Enlarged liver with increased echogenicity is noted. The porta hepatis is normal. The common bile duct measures 0.29cm. in diameater. The portal vein measures 0.75cm. at porta.

GALLBLADDER: Gall bladder seen is inadequately distended state visible portion is normal. wall is normal. No calculus or mass is seen within the gall bladder.

PANCREAS: It is normal in size, Shape, Outline and echotexture. Pancreatic duct is not dilated.

SPLEEN: It is normal in size 9.34cm, Shape, Outline and echotexture. No parenchymal lesion is noted.

BOTH KIDNEYS: Both kidneys are normal in position, size, shape, outline and echotexture. The cortico medullary differentiation is maintained. No calculus or hydronephrosis is seen.

RIGHT KIDNEY measures 8.88cm.


LEFT KIDNEY measures 10.16cm.

URINARY BLADDER: It is well distended with normal wall thickness. No calculus or mass is seen within the urinary bladder. The post void residual volume of urine is insignificant.

PROSTATE: It has a homogenous echotexture. The prostatic outline is smooth. The periprostatic plane is normal. It is normal in size measures 2.43cmX2.45cmX2.71cm VOL= 8.45 gms

IMPRESSION:

- HEPATOMEGALY WITH MODERATE FATTY CHANGES


DR. SUSMITA CHOWDHURY
MBBS, MD.
CONSULTANT SONOLOGIST