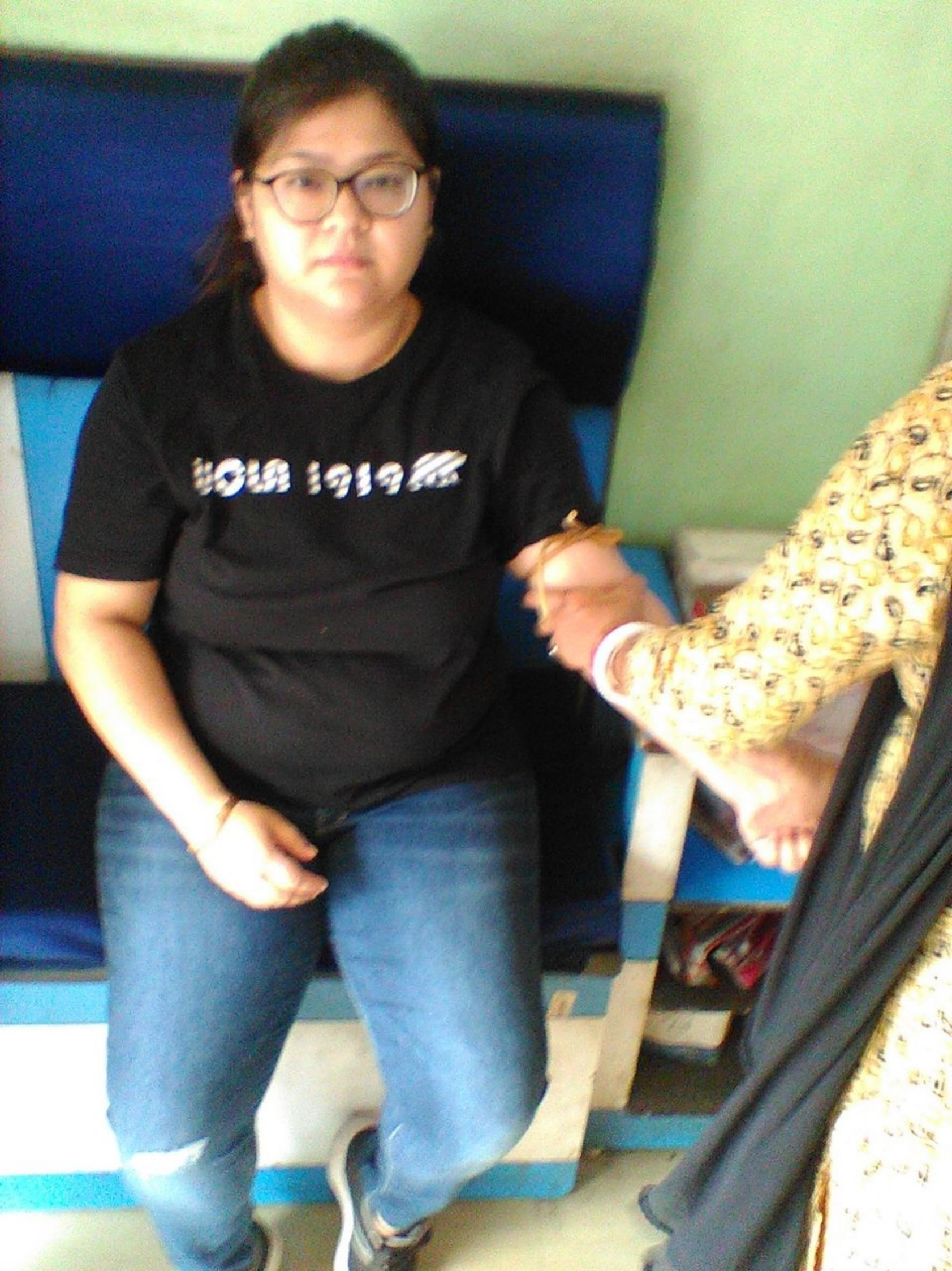





BANK OF BARODA MEDICAL EXAMINATION REPORT

Client name :- Sudakshina Sur
 Ref. No. :-
 Date of birth :- 11.05.1991, Sex :- Male / Female ✓
 Identification mark on the body :- Nothing as such found.
 Photo ID Xerox :- Adhar card No. 841315512536
 Date & place of medical examination :- 25.06.22. Asansol

Request for medical exam. of **BANK OF BARODA** through Medi Assist Health Care India (Pvt.) Ltd.

- A) 1. Height :- 155 cm. 2. Weight :- 85 kgs.
 3. Chest Inspiration :- 119 cm. 4. Chest Expiration :- 117 cm.
 5. Abdomen Girth :- 104 cm.
 6. Blood Pressure :- I) 128/90 mm. of Hg. II) mm. of Hg.
 7. Pulse Rate :- 78 / minute. Character of pulse :- Regular
 B) 1. Are you now in good health? Yes
 2. Are you currently taking any medicine? NO
 3.) Are you married? Yes
 4. Have you ever had a positive test for HIV / AIDS / Malignancy? NO
 5. Have you ever suffering from sexually transmitted disease or Hepatitis B or C? NO
 6. Have you any congenital disorders? NO.
 7. Have you any respiratory disorders? NO
 8. Have you any musculo skeletal disorders? NO
 9. Have you CVS disorders? NO
 10. Have you GI system disorders? NO
 11. Have you urinary system disorders? NO
 12. Have you reproductive system disorders? NO

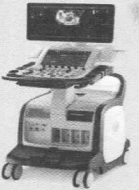



ANUBIKSHAN

Diagnostic Centre

Near Asansol District Hospital(Main Gate)
S.B. Gorai Road, Asansol-713301
Email ID : anubikshan.dc@gmail.com
Ph. : 0341-2221195, M. : 9732362727, 7872772680



ANUBIKSHAN DIAGNOSTIC CENTRE ANUBIKSHAN DIAGNOSTIC CENTRE ANUBIKSHAN DIAGNOSTIC CENTRE
ANUBIKSHAN DIAGNOSTIC CENTRE ANUBIKSHAN DIAGNOSTIC CENTRE ANUBIKSHAN DIAGNOSTIC CENTRE
ANUBIKSHAN DIAGNOSTIC CENTRE ANUBIKSHAN DIAGNOSTIC CENTRE ANUBIKSHAN DIAGNOSTIC CENTRE
ANUBIKSHAN DIAGNOSTIC CENTRE ANUBIKSHAN DIAGNOSTIC CENTRE ANUBIKSHAN DIAGNOSTIC CENTRE
ANUBIKSHAN DIAGNOSTIC CENTRE ANUBIKSHAN DIAGNOSTIC CENTRE ANUBIKSHAN DIAGNOSTIC CENTRE
ANUBIKSHAN DIAGNOSTIC CENTRE ANUBIKSHAN DIAGNOSTIC CENTRE ANUBIKSHAN DIAGNOSTIC CENTRE

13. Have you Diabetes / Hypertension / Endocrine disorders? NO
14. Have you ever done any surgical operation? NO
15. Have you any ear problem? NO
16. Have you any eye problem? VA 6/60, with wonglam VA 6/60 Normal CV-Normal
17. Have you nervous system disorders? NO
18. Have you any abnormal growth? NO
19. Have you any blood disorders? NO
20. What is general appearance of the client? Healthy
21. Does the appearance correspond with the age? Yes
22. Is there any personal peculiarities? NO
23. Tobacco (Stick / gms)- Panmasala/Cigar / Cigarette / Bidi / Gutkha Yes No
Alcohol(ml)- Beer / Wine / Hard Liquor :- Qty./ Day. For No. of Yrs

25/6/22



24.Family History	Age if living	Age at death	Present state of health or cause of death
Father	74y		Good health
Mother	64y		Good health
Brother (s)	48y		Good health
Sister (s)	NIL		

25. ANY REMARK BY THE MEDICAL EXAMINAR: - She is fit
except her T&H level is higher than
normal (11.03 ulmp/ml)


Shubhline Sin
Signature of the Client


Dr. S.K. SHARMA
Name of the Doctor


Date: - 25/6/22

Sanjeev Kumar
Signature & Seal of the Doctor

Dr. Sanjeev Kumar
M.B.B.S., MD (Med.)
Reg. No. 16138

 भारत सरकार
GOVERNMENT OF INDIA

 Sudakshina Sur
DOB: 11/05/1991
Female / FEMALE




8413 1551 2536

Sudakshina Sur



Sanjeev K
25/06/22

Dr. Sanjeev Kevin Shah
M.B.B.S., MD (Med.)
Reg. No. 16138

 भारतीय विशिष्ट पहचान प्राधिकरण
UNIQUE IDENTIFICATION AUTHORITY OF INDIA

Address:
D/O: Ravi Shanker Sur,
VIVEKANANDA PALLY, S.B GORAI
ROAD, ISMILE, Asansol (m Corp.),
Bardhaman,
West Bengal - 713301

8413 1551 2536

Dr. Rajib Banerjee

B.Sc., B.H.M.S., DOS (Kol)
Consultant Homoeopathic Physician
and optometric Eye Specialist

ADDRESS :

1 No. Mohishila Colony
Bottala Bazar
Asansol - 3
Mob. : 9832197360

R_x

Sudakshine Dar

Rt. Eye		Lt. Eye	
Sph	Cyl	Sph	Cyl
<i>α</i>	<i>α</i>	<i>α</i>	<i>9</i>
Near Add. →	<i>α</i>	Near Add. →	<i>α</i>

VAK 4/60
VAK 4/60
with wave glass

VAK 6/6
Near vision - NC
CV - Normal



RMZ 25/6/22

Chamber

Balananda Homoeo Clinic
Khejurtala More
Mohishila - 2, Asansol

Morning : 8.00 a.m. to 9.00 a.m.
Evening : 6.00 p.m. to 9.30 p.m.
Saturday Evening Closed
& Sunday Morning Closed

Test Report



SUDAKSHINA SUR


PID NO: P2242200007825

Age: 31.0 Year(s) Sex: Female



Reference: Dr.BANK OF BARODA

Sample Collected At:
Anubikshan Diagnostic Centre
Near Asansol District Hospital Main Gate,
Asansol : 713301
713301



VID: 220224000005299

Registered On:

25/06/2022 01:54 PM

Collected On:

25/06/2022 1:54PM

Reported On:

25/06/2022 03:57 PM

Investigation	Observed Value	Unit	Biological Reference Interval
Thyroid panel-1 (T3/T4/TSH) (Serum,ECLIA)			
T3 (Total)	113.4	ng/dL	84.63-201.8
T4 (Total)	7.78	µg/dL	5.13-14.06
TSH(Ultrasensitive)	11.03	µIU/mL	0.54-5.3 First Trimester : 0.1-2.5 Second Trimester : 0.2-3.0 Third trimester : 0.3-3.0

INTERPRETATION

TSH	T3 / FT3	T4 / FT4	Suggested Interpretation for the Thyroid Function Tests Pattern
Within Range	Decreased	Within Range	• Isolated Low T3-often seen in elderly & associated Non-Thyroidal illness. In elderly the drop in T3 level can be upto 25%.
Raised	Within Range	Within Range	•Isolated High TSHespecially in the range of 4.7 to 15 mIU/ml is commonly associated with Physiological & Biological TSH Variability. •Subclinical Autoimmune Hypothyroidism •Intermittent T4 therapy for hypothyroidism •Recovery phase after Non-Thyroidal illness"
Raised	Decreased	Decreased	•Chronic Autoimmune Thyroiditis •Post thyroidectomy,Post radioiodine •Hypothyroid phase of transient thyroiditis"
Raised or within Range	Raised	Raised or within Range	•Interfering antibodies to thyroid hormones (anti-TPO antibodies) •Intermittent T4 therapy or T4 overdose •Drug interference- Amiodarone, Heparin,Beta blockers,steroids, anti-epileptics"
Decreased	Raised or within Range	Raised or within Range	•Isolated Low TSH -especially in the range of 0.1 to 0.4 often seen in elderly & associated with Non-Thyroidal illness •Subclinical Hyperthyroidism •Thyroxine ingestion"
Decreased	Decreased	Decreased	•Central Hypothyroidism •Non-Thyroidal illness •Recent treatment for Hyperthyroidism (TSH remains suppressed)"
Decreased	Raised	Raised	•Primary Hyperthyroidism (Graves' disease),Multinodular goitre, Toxic nodule •Transient thyroiditis:Postpartum, Silent (lymphocytic), Postviral (granulomatous,subacute, DeQuervain's),Gestational thyrotoxicosis with hyperemesis gravidarum"
Decreased or within Range	Raised	Within Range	•T3 toxicosis •Non-Thyroidal illness"

- References: 1. Interpretation of thyroid function tests. Dayan et al. THE LANCET • Vol 357 • February 24, 2001
2. Laboratory Evaluation of Thyroid Function, Indian Thyroid Guidelines, JAPI, January 2011,vol. 59

-- End of Report --

Results relate only to the sample as received. Refer to conditions of reporting overleaf.

† This test was outsourced to Metropolis Healthcare Ltd. Mumbai

Dr. Satabdi.Mitra
M.D (Pathology)



ANUBIKSHAN

Diagnostic Centre


Near Asansol District Hospital(Main Gate)
S.B. Gorai Road, Asansol-713301
Email ID : anubikshan.dc@gmail.com
website: www.anubikshan.com

PATIENT ID:2022F3313 NAME: SUDAKSHINA SUR AGE:31 YR FEMALE
ADVISED BY:Dr. .M.O., BANK OF BARODA.,
DATE OF RECEIPT : 25/06/2022 DELIVERY DATE : 25/06/2022 TIME : 07:00 PM

HEAMATOLOGY TEST

TEST	RESULT	NORMAL RANGE
* Haemoglobin :-	11.5 gm/dl	12 - 16 gm/dl
* Total Leucocyte Count :-	6,200 /cu mm	4,000-11,000/cu mm
* Differential Leucocyte Count ::		
* -----		
Neutrophil	60 %	40-75%
Lymphocyte	35 %	20-45%
Monocyte	00 %	2-10%
Eosinophil	05 %	1-6%
Basophil	00 %	0-1%
* Erythrocyte Sedimentation	20 mm / 1st hour	Less than 15 mm (M) Less than 20 mm (F)
* P. C. V.	39 %	45.0-50.0% (M) 37.0-47.0% (F)
* M. C. V.	88.6 fl.	77-93 fl
* M. C. H.	26.1 pg.	27.0-32.0 pg
* M.C.H.C.	29.5 gm/dl.	31.0-35.0 gm/dl
* Platelet Count	2,12,000 /cu mm	1.5 - 4.0Lakh/cu mm
* R. B. C.	4.4 million/cu mm	6.0-8.0million/cu mm(M) 3.8-5.8million/cu mm(F)

All Reference ranges are age and sex matched. Reference limit mentioned, herein are in accordance with the literature provided along with the kit. Which may change in chemistry or the kit.


Dr. Swarup Ghosh
MBBS. MD. (Pathology)
Regd No 52140



ANUBIKSHAN

Diagnostic Centre


Near Asansol District Hospital(Main Gate)
S.B. Gorai Road, Asansol-713301
Email ID : anubikshan.dc@gmail.com
website: www.anubikshan.com

PATIENT ID: 2022F3313 NAME: SUDAKSHINA SUR AGE: 31 YR FEMALE
ADVISED BY: Dr. .M.O., BANK OF BARODA.,
DATE OF RECEIPT : 25/06/2022 DELIVERY DATE : 25/06/2022 TIME : 07:00 PM

REPORT ON BLOOD GROUP & Rh

TEST	RESULT	NORMAL RANGE
BLOOD GROUP	"A"	
RH Factor	"POSITIVE"	

All Reference ranges are age and sex matched. Reference limit mentioned herein are in accordance with the literature provided along with the kit. Which may change in chemistry or the kit.


Dr. Swarup Ghosh
MBBS. MD. (Pathology)
Regd No.52140



ANUBIKSHAN

Diagnostic Centre

Near Asansol District Hospital(Main Gate)
S.B. Gorai Road, Asansol-713301
Email ID : anubikshan.dc@gmail.com
website: www.anubikshan.com


PATIENT ID: 2022F3313 NAME: SUDAKSHINA SUR AGE: 31 YR FEMALE
ADVISED BY: Dr. .M.O., BANK OF BARODA.,
DATE OF RECEIPT : 25/06/2022 DELIVERY DATE : 25/06/2022 TIME : 07:00 PM

BIO CHEMISTRY REPORT

TEST	RESULT	NORMAL RANGE
Plasma Glucose (Fasting)	96.5 mg/dl	70 - 115 mg/dl
Plasma Glucose (P.P)	120.2 mg/dl	80 - 150 mg/dl.
Urea	28.6 mg/dl	17 - 43 mg/dl
Creatinine	0.82 mg/dl	0.7 - 1.4 mg/dl
Uric-Acid	4.5 mg/dl	2.6 mg/dl - 6.0 mg/dl
Cholesterol	155.0 mg/dl	00 - 200 mg/dl
Triglyceride	195.0 mg/dl	0 - 200 mg/dl
HDL Cholesterol	35.0 mg/dl	40 - 90.0 mg/dl
LDL Cholesterol	81.0 mg/dl	00 - 130 mg/dl
V.L.D.L.	39.0 mg/dl	23 - 45 mg/dl
CHOLESTEROL/HDL RATIO	4.4 : 1	upto - 5.0
LDL/HDL RATIO	2.3 : 1	upto - 3.0
Serum Bilirubin(Total)	0.79 mg/dl	0.1 - 1.2 mg/dl
Serum Bilirubin (Direct)	0.36 mg/dl	0.0 - 0.4 mg/dl
Serum Bilirubin(Indirect)	0.43 mg/dl	UPTO - 0.8 mg/dl

All biochemistry done by fully automated system Diasys respons 910.

All Reference ranges are age and sex matched. Reference limit mentioned herein are in accordance with the literature provided along with the kit. Which may change in chemistry or the kit.


Dr. Swarup Ghosh
MBBS. MD. (Pathology)
Regd No 52140



ANUBIKSHAN

Diagnostic Centre

Near Asansol District Hospital(Main Gate)
S.B. Gorai Road, Asansol-713301
Email ID : anubikshan.dc@gmail.com
website: www.anubikshan.com


PATIENT ID:2022F3313 NAME: SUDAKSHINA SUR AGE:31 YR FEMALE
ADVISED BY:Dr. .M.O., BANK OF BARODA.,
DATE OF RECEIPT : 25/06/2022 DELIVERY DATE : 25/06/2022 TIME : 07:00 PM

BIO CHEMISTRY REPORT

TEST	RESULT	NORMAL RANGE
S.G.P.T	25.6 U/L	00 - - 35.0 U/L
S.G.O.T	22.7 U/L	00 - 31.0 U/L
Alkaline Phosphatase	70.5 U/L	35 - 105 U/L
Total Protein	7.3 gm/dl	6.6 - 8.8 gm/dl
Albumin	4.2 gm/dl	3.5 - 5.2 gm/dl
Globulin	3.1 gm/dl	2.3 - 3.5 gm/dl
A : G	1.2:1	upto - 2.5:1

All biochemistry done by fully automated system Diasys respons 910.

All Reference ranges are age and sex matched. Reference limit mentioned herein are in accordance with the literature provided along with the kit. Which may change in chemistry or the kit.


Dr. Swarup Ghosh
MBBS. MD. (Pathology)
Regd No 52140



ANUBIKSHAN

Diagnostic Centre

Near Asansol District Hospital(Main Gate)
S.B. Gorai Road, Asansol-713301
Email ID : anubikshan.dc@gmail.com
website: www.anubikshan.com

PATIENT ID:2022G3606 NAME: SUDAKSHINA SUR AGE:31 YR FEMALE
ADVISED BY:Dr. .M.O., BANK OF BARODA.,
DATE OF RECEIPT : 01/07/2022 DELIVERY DATE : 01/07/2022 TIME : 07:00 PM

URINE ROUTINE EXAMINATION

PHYSICAL EXAMINATION

Colour : STRAW
S.P.Gravity : 1.010
Appearance : HAZY
Sediment : NIL

CHEMICAL EXAMINATION

pH : 6.0
Protein : TRACE
Sugar : NIL
Blood : NIL

MICROSCOPICAL EXAMINATION

R.B.C : NIL
Pus Cells : 1-2/HPF
Epethilial Cells : 3-4/HPF
Casts : NOT FOUND
Crystals : NOT FOUND
Bacteria : NOT FOUND
Others : NOT FOUND

All Reference ranges are age and sex matched. Reference limit mentioned herein are in accordance with the literature provided along with the kit. Which may change in chemistry of the kit.

Dr. Swarup Ghosh
MBBS. MD. (Pathology)
Regd No 52140



ANUBIKSHAN

Diagnostic Centre

Near Asansol District Hospital(Main Gate)
S.B. Gorai Road, Asansol-713301
Email ID : anubikshan.dc@gmail.com
website: www.anubikshan.com


PATIENT ID: 2022F3313 NAME: SUDAKSHINA SUR AGE: 31 YR FEMALE
ADVISED BY: Dr. .M.O., BANK OF BARODA.,
DATE OF RECEIPT : 25/06/2022 DELIVERY DATE : 25/06/2022 TIME : 07:00 PM

BIO CHEMISTRY REPORT

TEST	RESULT	NORMAL RANGE
S.G.P.T	25.6 U/L	00 - - 35.0 U/L
S.G.O.T	22.7 U/L	00 - 31.0 U/L
Alkaline Phosphatase	70.5 U/L	35 - 105 U/L
Total Protein	7.3 gm/dl	6.6 - 8.8 gm/dl
Albumin	4.2 gm/dl	3.5 - 5.2 gm/dl
Globulin	3.1 gm/dl	2.3 - 3.5 gm/dl
A : G	1.2:1	upto - 2.5:1

All biochemistry done by fully automated system Diasys respons 910.

All Reference ranges are age and sex matched. Reference limit mentioned herein are in accordance with the literature provided along with the kit. Which may change in chemistry or the kit.


Dr. Swarup Ghosh
MBBS. MD. (Pathology)
Regd No 52140



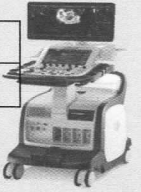PATIENT'S NAME: - SUDAKSHINA SUR

AGE:- 31 year

SEX:- Female

REF. BY DR.:- BANK OF BARODA.

DATE: - 01-07-2022



U.S.G OF WHOLE ABDOMEN

LIVER

Normal shape and size. Homogeneous echo texture of the liver is seen.

No focal parenchymal lesion is seen. (Measure:- 127.65 mm.)

PORTA VEIN

Portal vein at porta hepatis measures:- 6.18 mm. in diameter.

The appearance of porta is normal.

GALL BLADDER

Normal shape, size and position of the Gall Bladder is seen.

No calculus or any intraluminal mass is seen.

COMMON BILEDUCT

Common bile duct is not dilated (1.06 mm.)

No calculus or any intraluminal echogenicity.

PANCREAS

Normal echo-texture of the pancreas is seen. No space occupying lesion is seen.

Its relation with the anatomical landmark is normal.

SPLEEN

Normal dimension of the spleen is seen. It shows normal echo-texture.

No space occupying lesion is seen in the spleen. (Measure:- 85.60 mm.)

KIDNEYS

Both kidneys are normal in shape, size, margin and axis.

Cortico medullary differentiation is normal.

No calculi or any hydronephrotic changes noted.

(Right Kidney Measure :- 107.32 mm & Left Kidney Measure :- 102.50 mm in length)

URINARY BLADDER

Inadequate.

UTERUS

Normal. (Measure: - 60.95 mm x 30.75 mm x 35.93 mm.)

OVARIES

Normal shape and size of the ovaries are seen.

No space occupying lesion is seen in the ovaries. Normal echo texture is seen.

(Right ovary Measure: - 28.53 mm. x 24.45 mm.)

(Left ovary Measure: - 30.49 mm. x 23.57 mm.)

➤ IMPRESSION :-

➤ NORMAL STUDY

ADVICE

Clinical co-relation.

DR. DIPANKAR DASGUPTA.
(M.B.B.S., D.M.R.D)
(Regd.No:- WB-34374)

PATIENT'S NAME:- SUDAKSHINA SUR

AGE:- 31 YEAR SEX:- FEMALE

REF BY DR: - BANK OF BARODA

DATE:- 01-07-2022

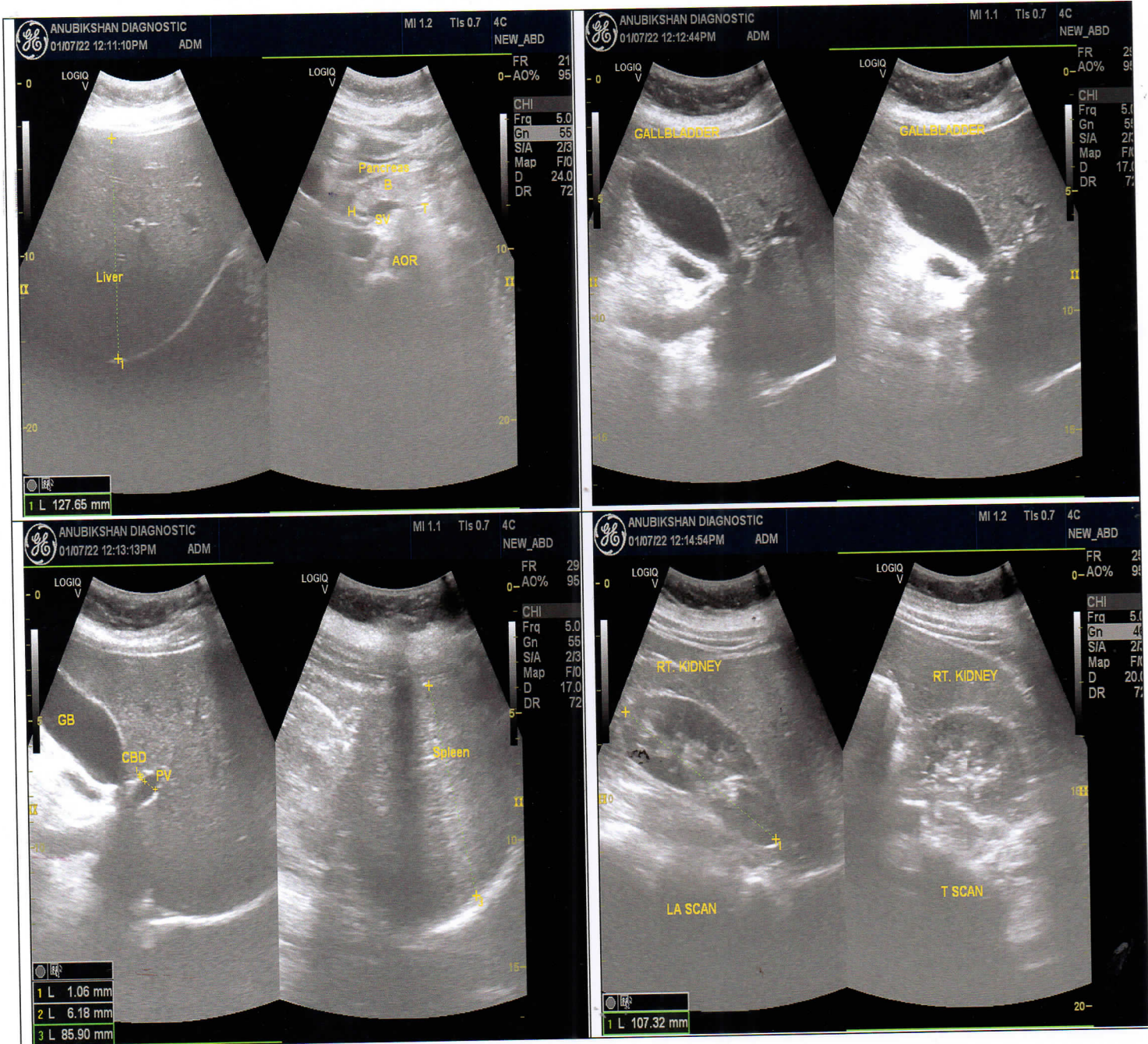
U.S.G. OF WHOLE ABDOMEN

ANUBIKSHAN DIAGNOSTIC CENTRE

NEAR ASANSOL DISTRICT HOSPITAL (MAIN GATE)
S.B.GORAI ROAD (EAST), PIN - 713301

LANDLINE: - 0341-3590332 // MOB - 7872772680

E- mail ID: - anubikshan.dc@gmail.com (1)



PATIENT'S NAME:- SUDAKSHINA SUR

AGE:- 31 YEAR SEX:- FEMALE

REF BY DR: - BANK OF BARODA

DATE:- 01-07-2022

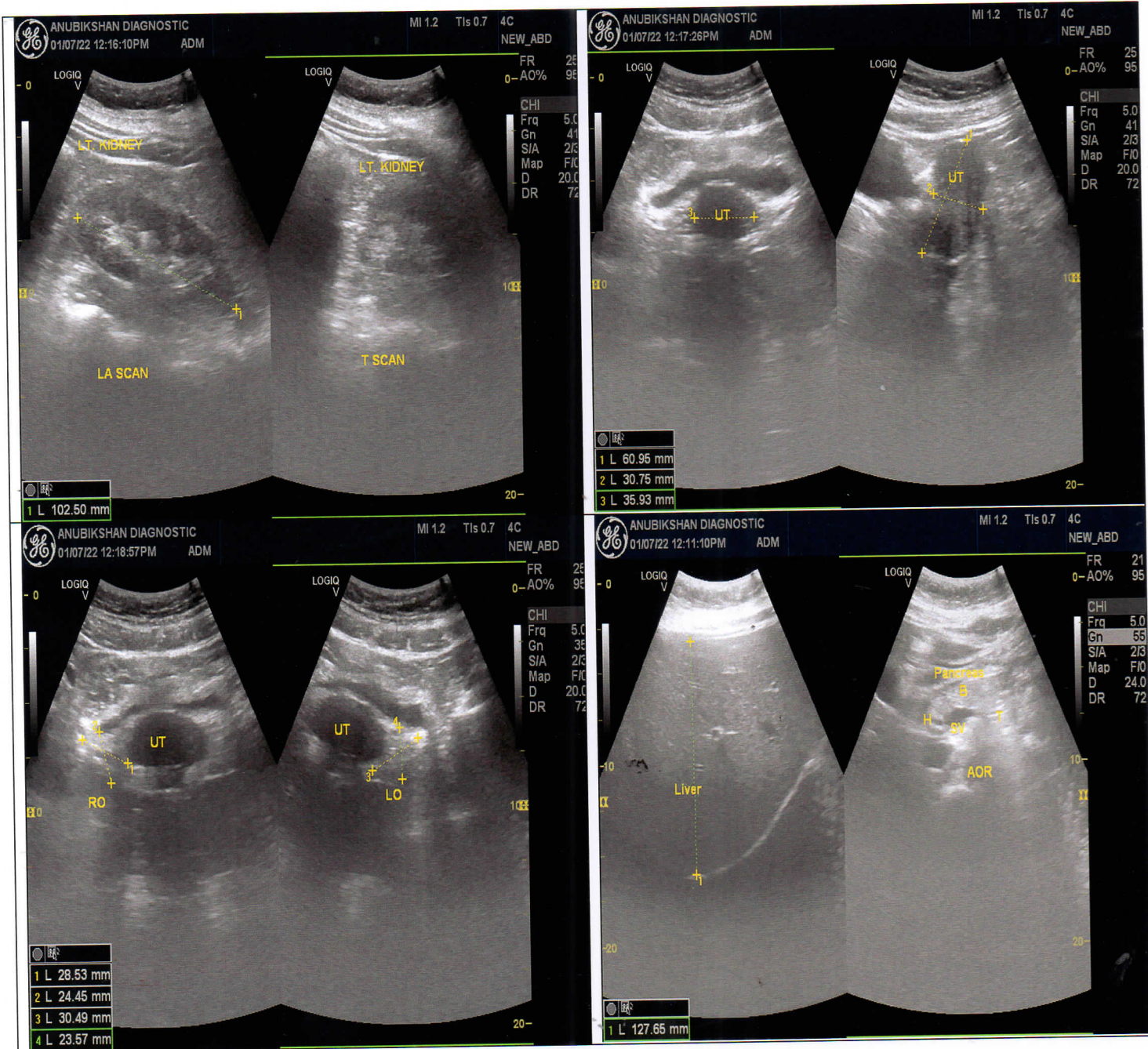
U.S.G. OF WHOLE ABDOMEN

ANUBIKSHAN DIAGNOSTIC CENTRE

NEAR ASANSOL DISTRICT HOSPITAL (MAIN GATE)
S.B.GORAI ROAD (EAST), PIN - 713301

LANDLINE: - 0341-3590332 // MOB - 7872772680

E- mail ID: - anubikshan.dc@gmail.com (2)





PATIENT'S NAME:- SUDAKSHINA SUR

AGE:- 31 YRS

GENDER:- FEMALE

REF BY DR.:- BANK OF BARODA

DATE:- 25.06.2022



ANUBIKSHAN DIAGNOSTIC CENTRE ANUBIKSHAN DIAGNOSTIC CENTRE ANUBIKSHAN DIAGNOSTIC CENTRE
ANUBIKSHAN DIAGNOSTIC CENTRE ANUBIKSHAN DIAGNOSTIC CENTRE ANUBIKSHAN DIAGNOSTIC CENTRE
ANUBIKSHAN DIAGNOSTIC CENTRE ANUBIKSHAN DIAGNOSTIC CENTRE ANUBIKSHAN DIAGNOSTIC CENTRE
ANUBIKSHAN DIAGNOSTIC CENTRE ANUBIKSHAN DIAGNOSTIC CENTRE ANUBIKSHAN DIAGNOSTIC CENTRE
ANUBIKSHAN DIAGNOSTIC CENTRE ANUBIKSHAN DIAGNOSTIC CENTRE ANUBIKSHAN DIAGNOSTIC CENTRE
ANUBIKSHAN DIAGNOSTIC CENTRE ANUBIKSHAN DIAGNOSTIC CENTRE ANUBIKSHAN DIAGNOSTIC CENTRE
ANUBIKSHAN DIAGNOSTIC CENTRE ANUBIKSHAN DIAGNOSTIC CENTRE ANUBIKSHAN DIAGNOSTIC CENTRE

REPORT

CHEST X – RAY P A VIEW

Soft tissue around chest and bony cage --- normal.

No active lung lesion in either field.

Cardiac configuration normal.

Pleural recesses are clear.

I M P R E S T I O N

✓ **NORMAL SKIAGRAM OF CHEST.**

ADVICE
Clinical co-relation.

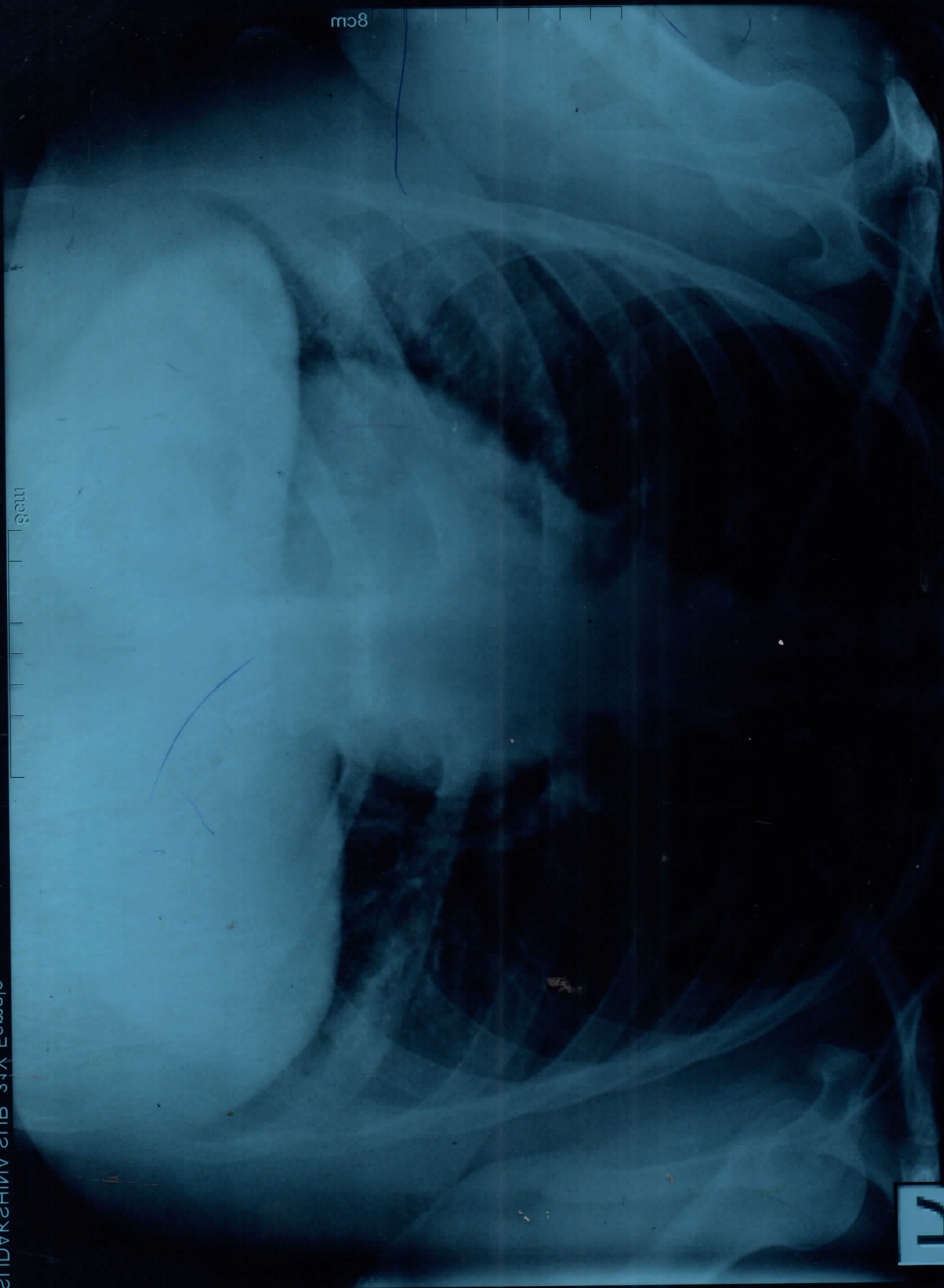
D 25/6/22
DR. DIPANKAR DASGUPTA.
(M.B.B.S., D.M.R.D)
(Regd.No:- WB-34374)

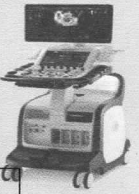5210815055
2611

NEW ASYNSOG X RAY CLINIC MOB-6434538885
SUNDAYAKSHIYA SUB 3TY Female

8cm

8cm





ELECTRO CARDIO GRAM FORMAT

PATIENT NAME:- SUDAKSHINA SUR	
AGE:- 31 YRS	GENDER:- FEMALE
REF BY DR:- BANK OF BARODA.	DATE:- 25.06.2022

❖ RATE :- 64 / min .

❖ AXIS :- Normal .

❖ P- WAVE :- 99 ms .

❖ P-R :- 124 ms

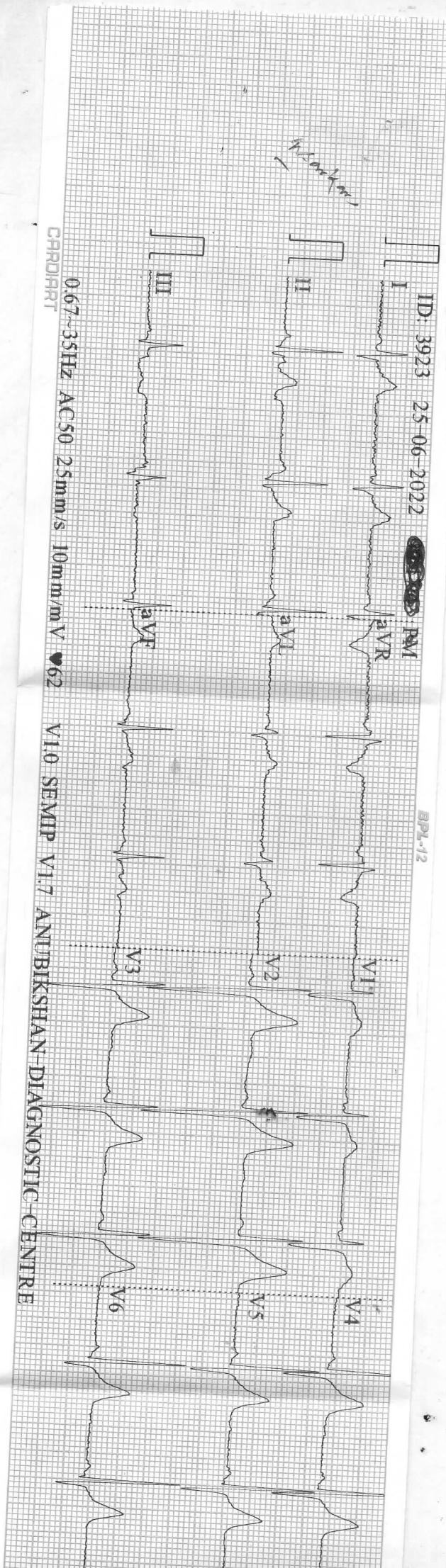
❖ QRS :- 89 ms .

❖ ST - T :- NO ST - T change .

❖ T - WAVE :-
Q - none
↓ in II
in III

➤ IMPRESSION :- Normal ECG.

Msankar
25.6.22
Dr. Nibha Sarkar
Physician Cardiologist
Ex C. H. Kalla



Normal

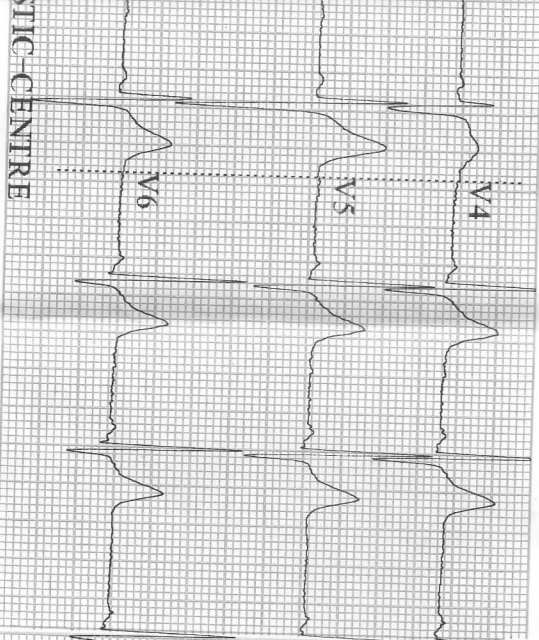
ID: 3923 25-06-2022

PMI

BPL-12

0.67~35Hz AC50 25mm/s 10mm/mV 62

CARDIART V10 SEMIP V1.7 ANUBIKSHAN-DIAGNOSTIC-CENTRE



ID: 3923
 Male
 31 Years
 cm
 kg
 mmHg
 HR 64 bpm
 P 99 ms
 PR 124 ms
 QRS 89 ms
 QT/QTc 362/374 ms
 P/QRS/T 55/73/24 °
 RV5/SV1 1.64/2.08/47 mV
 CARDIART

Minnesota Code:

Diagnosis Information:
 Sinus Rhythm
 Normal ECG

Sundakshina Sub 31Y F
MO. Bank of Barbuda.

Sundakshina Sun

Report Confirmed by:

BPL-12