



भारत सरकार
भारत सरकार



आधार

ಭಾರತೀಯ ಏಕೀಕೃತ ಗುರುತು ಪ್ರಾಧಿಕಾರ

ಭಾರತ ಸರ್ಕಾರ

Unique Identification Authority of India
Government of India

ನೋಂದಾವಣೆ ಕ್ರಮ ಸಂಖ್ಯೆ / Enrollment No.: 1178/93724/11777

To

ಸುಮನ್ ದೇಬ್ ಬರ್ಮನ್

Suman Deb Burman

S/O: Sujoy Deb Burman

5

Abinash chandra sarkar road

Dakshineswar

Dakshineswar

North 24 Paraganas North 24 Parganas

West Bengal 700076

9830518221

17/11/2015
305582753



MA055827533FT



ನಿಮ್ಮ ಆಧಾರ್ ಸಂಖ್ಯೆ / Your Aadhaar No. :

2018 0029 5931

ಆಧಾರ್ - ಶ್ರೀಸಾಮಾನ್ಯನ ಅಧಿಕಾರ



ಭಾರತ ಸರ್ಕಾರ

Government of India



ಸುಮನ್ ದೇಬ್ ಬರ್ಮನ್

Suman Deb Burman

ಜನ್ಮ ದಿನಾಂಕ / DOB : 04/07/1985

ಪುರುಷ / Male



2018 0029 5931

ಆಧಾರ್ - ಶ್ರೀಸಾಮಾನ್ಯನ ಅಧಿಕಾರ

Suman Deb Burman



ಮಾಹಿತಿ

- ಆಧಾರ್ ಗುರುತಿನ ಪುರಾವೆಯೇ ಹೊರತು ಪೌರತ್ವದಲ್ಲ .
- ನಿಮ್ಮ ಗುರುತನ್ನು ಸಾಬೀತುಪಡಿಸಲು, ಆನ್ ಲೈನ್ ಮೂಲಕ ದೃಢೀಕರಿಸಿ .

INFORMATION

- Aadhaar is proof of identity, not of citizenship .
- To establish identity, authenticate online .

- ಆಧಾರ್ ದೇಶದಾದ್ಯಂತ ಮಾನ್ಯತೆಯನ್ನು ಪಡೆದಿದೆ .
- ಭವಿಷ್ಯದಲ್ಲಿ, ಸರ್ಕಾರಿ ಹಾಗೂ ಸರ್ಕಾರೇತರ ಸೇವೆಗಳನ್ನು ಪಡೆಯಲು ಆಧಾರ್ ನಿಮಗೆ ಸಹಾಯಕವಾಗಲಿದೆ .
- Aadhaar is valid throughout the country .
- Aadhaar will be helpful in availing Government and Non-Government services in future .



ಭಾರತೀಯ ನಿಕಟ ಗುರುತು ಪ್ರಾಧಿಕಾರ
Unique Identification Authority of India

ವಿಳಾಸ:
ತಂದೆ / ತಾಯಿಯ ಹೆಸರು: ಸುಜೋಯ್
ದೇಬ್ ಬರ್ಮನ್, 5, ಅಬಿನಾಶ್ ಚಂದ್ರ
ಸರ್ಕಾರ್ ರಸ್ತೆ, ದಕ್ಷಿಣೇಶ್ವರ, ನಾರ್ತ್ 24
ಪಾರಗಣಾ, ದಕ್ಷಿಣೇಶ್ವರ, ವೆಸ್ಟ್ ಬೆಂಗಲ್,
700076

Address: .
S/O: Sujoy Deb Burman, 5,
Abinash chandra sarkar road,
Dakshineswar, North 24
Parganas, Dakshineswar, West
Bengal, 700076

2018 0029 5931

1947
1800 300 1947

help@uidai.gov.in

www
www.uidai.gov.in

Suman Deb Burman


बैंक ऑफ बरोडा
Bank of Baroda

नाम **देब बर्मन सुमन**
Name : **DEB BURMAN SUMAN**
सदस्यता क्र. : २६७९८२
E. C. No. 167982


सदस्यता प्रतिपादित


Suman Deb Burman
सदस्यता क्र. १६७९८२

Suman Deb Burman

K.Z.

આવેલ વસ્તુ ઠીકઠીક સંભાળીને સંબંધિત સંસ્થાને
જાહેર સંસ્થાને (પુસ્તક) આવી સંભાળીને સંબંધિત સંસ્થાને
સં - 26, સંબંધિત સંસ્થાને સંબંધિત સંસ્થાને, સંબંધિત સંસ્થાને, સંબંધિત સંસ્થાને
સંબંધિત સંસ્થાને: 91 22 6698 5196, સંબંધિત સંસ્થાને: 91 22 2652 5747

If Found, Please return to
Asst. General Manager (Security) Bank of Baroda, Baroda Corporate Centre
P-26, G. T. Road, Baroda-Sudha Complex, Mumbai 400 051, India
Phone:- 91 22 6698 5196 Fax:- 91 22 2652 5747

SULATA MONDAL

Name & Ph./Person of emergency contact. 9163245287

સંબંધિત સંસ્થાને/Allergy NIL

સંબંધિત સંસ્થાને/Blood Group B+

સંબંધિત સંસ્થાને/Identification mark

MOLE BELOW LOWER LIP (LEFT)

સંબંધિત સંસ્થાને/Issuing office

BOB, KOLKATA ZONE, Plot No 38/2,Block -GN, Sector-V,Salt Lake City, Kolkata - 700091

Suman Deb Burman

LETTER OF APPROVAL / RECOMMENDATION

To,

The Coordinator,
Mediwheel (Arcofemi Healthcare Limited)
Helpline number: 011- 41195959

Dear Sir / Madam,

Sub: Annual Health Checkup for the employees of Bank of Baroda

This is to inform you that the following employee wishes to avail the facility of Cashless Annual Health Checkup provided by you in terms of our agreement.

PARTICULARS	EMPLOYEE DETAILS
NAME	MR. BURMAN SUMAN DEB
EC NO.	167982
DESIGNATION	BRANCH HEAD
PLACE OF WORK	KOLKATA, K K TAGORE STREET
BIRTHDATE	04-07-1985
PROPOSED DATE OF HEALTH CHECKUP	16-05-2022
BOOKING REFERENCE NO.	22J167982100018820E

This letter of approval / recommendation is valid if submitted along with copy of the Bank of Baroda employee id card. This approval is valid from 13-05-2022 till 31-03-2023. The list of medical tests to be conducted is provided in the annexure to this letter. Please note that the said health checkup is a **cashless facility** as per our tie up arrangement. We request you to attend to the health checkup requirement of our employee and accord your top priority and best resources in this regard. The EC Number and the booking reference number as given in the above table shall be mentioned in the invoice, invariably.

We solicit your co-operation in this regard.

Yours faithfully,

Sd/-

Chief General Manager
HRM Department
Bank of Baroda

(Note: This is a computer generated letter. No Signature required. For any clarification, please contact Mediwheel (Arcofemi Healthcare Limited))

SUGGESTIVE LIST OF MEDICAL TESTS

FOR MALE	FOR FEMALE
CBC	CBC
ESR	ESR
Blood Group & RH Factor	Blood Group & RH Factor
Blood and Urine Sugar Fasting	Blood and Urine Sugar Fasting
Blood and Urine Sugar PP	Blood and Urine Sugar PP
Stool Routine	Stool Routine
Lipid Profile	Lipid Profile
Total Cholesterol	Total Cholesterol
HDL	HDL
LDL	LDL
VLDL	VLDL
Triglycerides	Triglycerides
HDL / LDL ratio	HDL / LDL ratio
Liver Profile	Liver Profile
AST	AST
ALT	ALT
GGT	GGT
Bilirubin (total, direct, indirect)	Bilirubin (total, direct, indirect)
ALP	ALP
Proteins (T, Albumin, Globulin)	Proteins (T, Albumin, Globulin)
Kidney Profile	Kidney Profile
Serum creatinine	Serum creatinine
Blood Urea Nitrogen	Blood Urea Nitrogen
Uric Acid	Uric Acid
HBA1C	HBA1C
Routine urine analysis	Routine urine analysis
USG Whole Abdomen	USG Whole Abdomen
General Tests	General Tests
X Ray Chest	X Ray Chest
ECG*	ECG
2D/3D ECHO / TMT	2D/3D ECHO / TMT
Stress Test	Thyroid Profile (T3, T4, TSH)
PSA Male (above 40 years)	Mammography (above 40 years) and Pap Smear (above 30 years).
Thyroid Profile (T3, T4, TSH)	Dental Check-up consultation
Dental Check-up consultation	Physician Consultation
Physician Consultation	Eye Check-up consultation
Eye Check-up consultation	Skin/ENT consultation
Skin/ENT consultation	Gynaec Consultation

Patient Name: SUMAN DEB BURMAN 37/M

Resting ECG Report

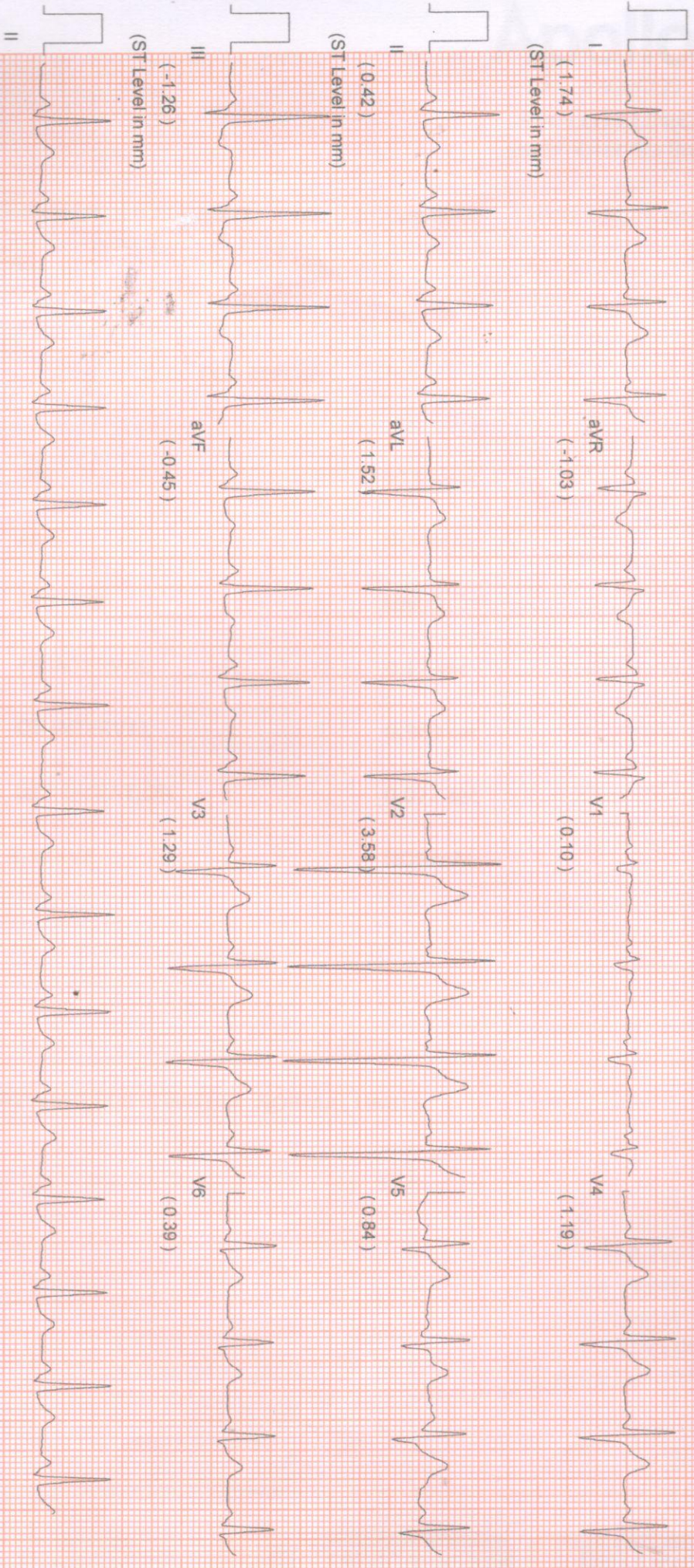
May 16, 2022
Time: 13:44:50

QT / QTc : 0.296 / 0.363 Sec
P-QRS-T Axis (58)-(47)-(22) deg

PR Interval: 0.12 sec
QRS Duration : 0.072 Sec

RR Interval: 0.66 sec

HR : 90 bpm
BP : 110 / 70 mmHg



Comments :-

Suman Deb Burman


NAME: MR.SUMAN DEB BURMAN	MR NO: FSIN-0000	DATE : 16.05.2022
AGE: 37YRS.	SEX:MALE	REF BY:SELF

ECG REPORT

HR : 90 b/min
AXIS : NORMAL
RHYTHM : SINUS
PR INTERVAL : 0.12 sec
QT INTERVAL : 0.363 sec
QRS DURATION : 0.072 sec
T-WAVE : NORMAL.

IMPRESSION:

- RESTING ECG IS WITHIN NORMAL LIMITS.


Dr. SIDDHARTHA KUNDU
BBS (Cal), PGDCC, CCEBDM
Clinical Cardiologist
Ex Sr Resident, Cardiology Dept
B.R Singh Hospital, Eastern Railway



DEPARTMENT OF RADIOLOGY X-RAY OF CHEST (PA) VIEW

MR. NO- FSIN.0000000

SEX-MALE

NAME: -SUMAN DEB BURMAN

EXAMINATION DATE-16/05/2022


AGE-36YRS

REPORT DATE-16/05/2022

REF DR. SELF

FINDINGS:

- Bilateral lung fields are clear.
- Tracheal shadow is in the midline.
- Bilateral CP angle are clear
- Both hila appear normal .
- CTR appears normal .
- No definite bone fracture is noted.


DR.ARNAB MANDAL

MD, Physician, PGDUS (Delhi) CEBT-USG (WBUHS KOLKATA)
Fellow of Jefferson Ultrasound Radiology and Education Institute
Philadelphia Ex-Radiology Resident (S.E.Railway)
Regd.No:72022(WBMC)



NAME:MR.SUMAN DEB BURMAN	MR. NO: FSIN-0000	DATE: 16/05/2022
AGE :36YRS	SEX:MALE	REF. BY: SELF

ULTRASOUND OF WHOLE ABDOMEN

LIVER: Liver is **Enlarged moderate fatty changes** seen in size, shape, outline and echotexture. The intrahepatic tubular structures are normal. Enlarged liver with increased echogenicity is noted. The porta hepatis is normal. The common bile duct measures **0.95cm** in diameter. The portal vein measures **0.44cm** at porta.

GALLBLADDER: Gall bladder is **partially distended**. Wall is normal. No calculus or mass is seen within the gall bladder.

PANCREAS: It is normal in size, Shape, Outline and echotexture. Pancreatic duct is not dilated.

SPLEEN: It is normal in size **9.93cm**, Shape, Outline and echotexture. No parenchymal lesion is noted.

RIGHT KIDNEY: It is normal in position, size, shape, outline and echotexture. The cortico medullary differentiation is maintained. No calculus or hydronephrosis is seen.

RIGHT KIDNEY measures **9.47cm**.

LEFT KIDNEY: It is normal in position, size, shape, outline and echotexture. The cortico medullary differentiation is maintained. No calculus or hydronephrosis is seen.


LEFT KIDNEY measures **10.17cm**.

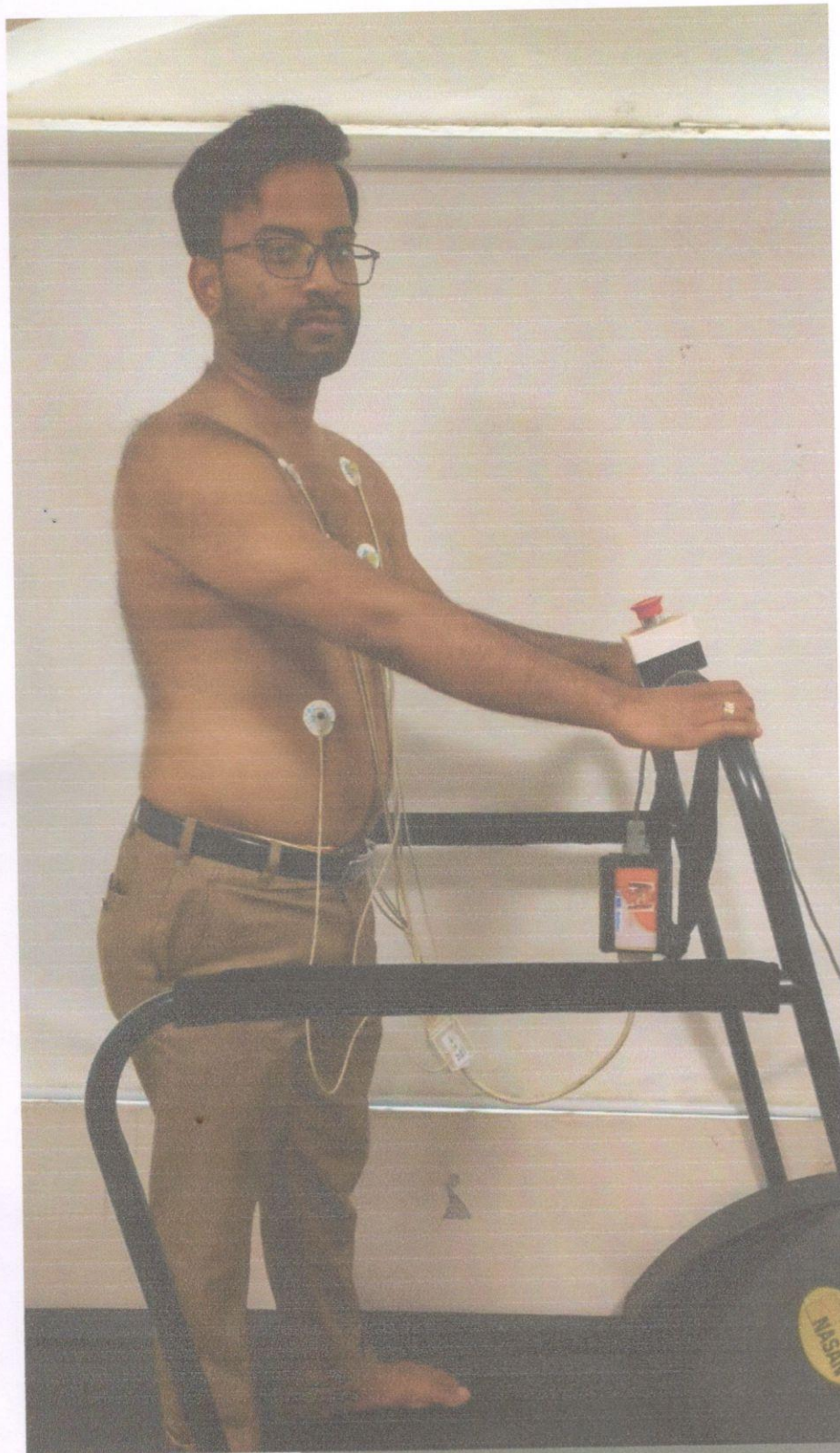
URINARY BLADDER: It is well **partially distended** with normal wall thickness. No calculus or mass is seen within the urinary bladder.

PROSTATE: It has a homogenous echotexture. The prostatic outline is smooth. The periprostatic plane is normal. It is normal in size measures **2.48cmX3.75cmX2.74cm** **VOL-13.54gms**

IMPRESSION:

- **HEPATOMEGALY WITH MODERATE FATTY CHANGES SEEN**


DR.SUSMITA CHOWDHURY
CONSULTANT SONOLOGIST
M.B.B.S, MD.



UNIVERSITY OF CALCUTTA
কলিকতা বিশ্ববিদ্যালয়

Om Tower
ওম টাওয়ার

RABINDRA BHARATI UNIVERSITY
রবীন্দ্র ভারতী বিশ্ববিদ্যালয়

SATCHASI PARA
সাতশাসী পরা

S Sinthee Rd
সিন্ধী রোড

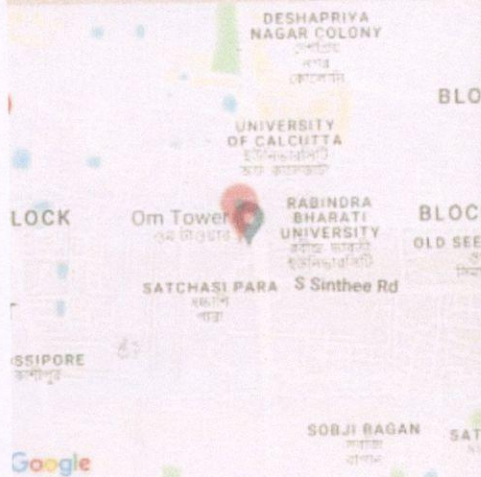
Google

3MC, Barackpore Trunk Rd, C/T, Satchasi Para, Kolkata, West Bengal 700002, India

Kolkata
West Bengal
India

35°C
95°F

2022-05-16(Mon) 02:11(PM)



36C, Barrackpore Trunk Rd, C.T. Satchasi Para, Kolkata, West Bengal 700002, India

Kolkata

West Bengal

India

2022-05-16 (Mon) 09:50 (AM)

32°C
90°F

Patient Name: MR. SUMAN DEB BURMAN
UHID/MR No.: FSIN.0000014666
Visit Date: 17.05.2022
Sample collected on: 17.05.2022
Ref Doctor: SELF

Age/Gender: 36 Years / Male
OP Visit No.: FSINOPV17735
Reported on: 17.05.2022
Specimen: STOOL

STOOL ROUTINE EXAMINATION

STOOL FOR ROUTINE EXAMINATION

<u>Test Name</u>	<u>Result</u>	<u>Unit</u>	<u>Method</u>
<u>PHYSICAL EXAMINATION</u>			
COLOUR	Brownish		Naked Eye Observation
CONSISTANCY	Semi solid		Naked Eye Observation
ODOUR	Offensive		Naked Eye Observation
MUCUS	Present (+)		Naked Eye Observation
<u>CHEMICAL EXAMINATION</u>			
REACTION	Acidic		
OCCULT BLOOD TEST	Negative		
Ph	6.5		
<u>MICROSCOPICAL EXAMINATION</u>			
VEG CELL	Present(+)	/hpf	Light Microscopy
PUS CELL	1-2	/hpf	Light Microscopy
RBC	Nil	/hpf	Light Microscopy
OVA	Nil		Light Microscopy
PARASITE	NIL		Light Microscopy
CYST	NIL		Light Microscopy
OTHERS	NIL		Light Microscopy

Note : Any Abnormal Chemical Analysis Rechecked By Rechecked By Respective Manual Method
End of Report

BL

Lab Technician / Technologist
Madhumita_Biswas

Dr.BIPARNAK HALDER
MBBS, MD (PATHOLOGY)
CONSULTANT PATHOLOGIST

DR. RAKTIMA BAKSHI MANDAL

CONSULTANT EYE SURGEON
& OPHTHALMOLOGIST

TO WHOM IT MAY CONCERN

THIS IS TO CERTIFY THAT MR. SUMAN DEB BURMAN,

AGE- 36Y/MALE.

SHE IS WITH CLEAR VISION, WITH NO COLOR BLINDNESS.

RIGHT EYE	POWER - 2
LEFT EYE	POWER -2

DATE: 19/06/2022

APOLLO CLINIC OM TOWER
36C, B.T ROAD OPP "PBU"
KOL 700002
Ph 033 25565555
033 25563333

R.B. Mandal

SIGNATURE

DC STAMP

DR. RAKTIMA BAKSHI MANDAL
M.B.B.S., M.S. (OPHTHALMOLOGY)
Regn. No. 69521 of WBMC
Consultant Eye Surgeon



DR. ABHIRUP MUKHERJEE

BDS (WBUHS)
Oral & Dental Surgeon
Regn.No. 3726 Part A (Wbdc)

TO WHOM IT MAY CONCERN

THIS IS TO CERTIFY THAT MR. SUMAN DEB BURMAN, 36Y/MALE,
HAS NO ORAL PROBLEM.

THERE IS NO CAVITY AND BAD SMELL OBSERVED IN HIS MOUTH.

DATE: 19-05-2022

APOLLO CLINIC OM TOWER
36C, B.T. ROAD OPP "RBU"
KOL-700002
Ph 033 25565555
033 25563333

A. Mukherjee

SIGNATURE
DC STAMP

DR. ABHIRUP MUKHERJEE
BDS (WBUHS)
Oral & Dental Surgeon
Regn. No. 3726 Part A (WBDC)

DR. SOURADEEP RAY

MBBS, MS (ENT)
ASSOCIATE PROFESSOR R.G. KAR MEDICAL, KOLKATA.
REGD.NO. 63999 (WBMC)

TO WHOM IT MAY CONCERN

THIS IS TO CERTIFY THAT
MR. SUMAN DEB BURMAN , AGE- 36Y/MALE,
HAS NO PROBLEM IN HIS EAR, NOSE AND THROAT.

HIS EAR IS CLEAN, NO HEARING PROBLEM OBSERVED,
NASAL PASAGE IS CLEAR, WITH PROPER SMELLING CAPACITY,
THROAT IS CLEAR, NO INFECTION FOUND IN TONSILS.

DATE: 19.05.2022.....



SIGNATURE
DC STAMP

APOLLO CLINIC OM TOWER
36C B.T.ROAD OPP "RBU"
KOL 700002
Ph 033 25565555
033 25563333

DR. BOUDHAYAN BHATTACHARJEE

MBBS. (MEDICAL COLLEGE, KOLKATA) MD (TROPICAL MEDICINE)
CONSULTANT PHYSICIAN & INTENSIVIST

APOLLO CLINIC @ OM TOWER
Opp. of Rabindra Bharati University

TO WHOM IT MAY CONCERN

THIS IS TO CERTIFY THAT, MR. SUMAN DEB BURMAN ,
AGE- 36Y/MALE, IS PHYSICALLY FIT .

DATE: 19/05/22

APOLLO CLINIC OM TOWER
36C, B.T.ROAD OPP "RBU"
KOL 700002
Ph 033 25565555
033 25563333

Boudhayan Bhattacharjee.

SIGNATURE

STAMP

Dr. BOUDHAYAN BHATTACHARJEE
MBBS, MD (TROPICAL MEDICINE)
65631 of WBMC

