

**DAKSH HOSPITAL**

396 - 397, Gandhi Nagar, Scheme No. 8, ALWAR -301001

Ref. No.

Date.....

MEDICAL EXAMINATION REPORT  
Mediwheel (BOB)

Name: Mr. Sachin

Age: 31 yrs

Sex: Male

Date: 23/09/2023

General Physical Examination

Height : 173 cm  
Pulse : 80 /mt  
Respiration : 18 /mt

Weight : 75.2 kg  
BP : 120/80 mm/hg  
BMI : 25.1 kg/m<sup>2</sup>

Systemic Exam:- NORMALDental Check up :- NORMALEye check-up :- NORMALSkin Check up:- NORMALENT Check up:- NORMALImpression:- NormalRecommendation:-

In view of increase of PT (in blood test) & mild fatty liver - life style intervention recommended with HBSAG, HCV, CRP.

Dr. Mukesh Kumar Gupta  
MD Gen. Medicine  
Reg. No 5423/16262  
दक्ष हॉस्पिटल, अलवर  
रजि० नं०-5423/16262



## Results

Run Date 23/09/2023 11:19:45 AM

Operator DAKSH

Last Name

Sample ID 6

First Name MR. SACHIN

Department

Gender Male

Age

Physician DR. MUKESH GUPTA M.D

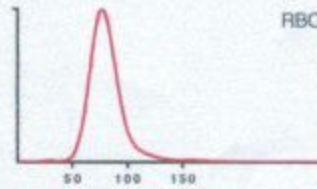
Patient ID AUTO\_PID16199

Type Man

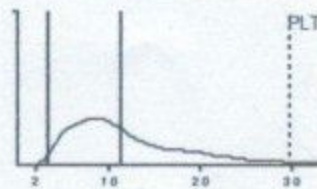
Date of birth

Sample comments

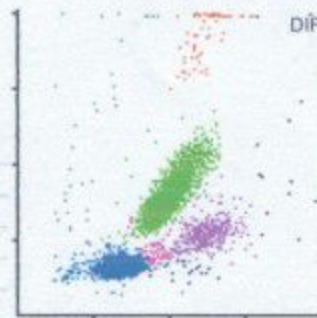
				Range
RBC	5.12	*	10 <sup>6</sup> /μL	3.80 - 5.50
HGB	14.1		g/dL	13.0 - 17.0
HCT	44.9	*	%	39.0 - 52.0
MCV	87.8	*	μm <sup>3</sup>	76.0 - 100.0
MCH	27.5		pg	26.0 - 34.0
MCHC	31.3	L	g/dL	32.0 - 35.0
RDW-CV	15.5		%	11.0 - 16.0
RDW-SD	50.0	h	μm <sup>3</sup>	37.0 - 49.0



				Range
PLT	221		10 <sup>3</sup> /μL	150 - 450
PCT	0.25		%	0.15 - 0.40
MPV	11.3	h	μm <sup>3</sup>	8.0 - 11.0
PDW	21.7		μm <sup>3</sup>	11.0 - 22.0
P-LCC	91		10 <sup>3</sup> /μL	44 - 140
P-LCR	41.2		%	18.0 - 50.0



				Range		
WBC	7.07		10 <sup>3</sup> /μL	3.50 - 10.00		
	#		Range	%	Range	
NEU	3.26		1.60 - 7.00	46.3	40.0 - 75.0	
LYM	3.37	h	1.00 - 3.00	47.8	h	20.0 - 45.0
MON	0.18	l	0.20 - 0.80	2.6		2.0 - 10.0
EOS	0.13		0.00 - 0.50	1.9		1.0 - 6.0
BAS	0.10		0.00 - 0.15	1.4	h	0.0 - 1.0
LIC	0.03		0.00 - 0.10	0.4		0.0 - 1.0



*Dr. R.S. GUPTA*  
MD (Pathology) (MAHE)  
RMC No. 7924/19778



Date :- 23/09/2023 Name :- MR. SACHIN

Age &amp; Sex :- -31 Yrs/ male

Refd. :- Dr Mukesh Gupta M.D.

	TEST NAME	RESULT	REFERENCE RANGE
	ESR		10 00 -20 mm/hrs
	Blood Group & Rh Factor	A " POSITIVE	
	HbA1C	4.32	4 - 5.6%
	Blood Sugar (F)	79.1	< 70 - 100 mg/dl
	Blood Sugar (PP)	102.1	< 140 mg/dl
	Urine Sugar (F)	NIL	-
	Urine Sugar (PP)	NIL	-
LIVER	S.Bilirubin Total	0.80	0.30 - 1.20 mg/dl
	S.Bilirubin Direct	0.20	0.10 - 0.30 mg/dl
	S.Bilirubin Indirect	0.60	0.30 - 0.90 mg/dl
	S.G.O.T.	52 ✓	> 37 u/l
	S.G.P.T.	65 ✓	> 40 u/l
	S.Alk. Phosp.	192	80 - 306 u/l
	G.G.T.	20.1	5 -40 u/l
	Total Protein	6.8	6.5 - 8.5 gm/dl
	Albumin	3.7	3.8 - 5.4 gm/dl
	Globulin	3.1	2.3 - 3.5 gm/dl
	A/G Ratio	1.2	-
AST/ALT Ratio	0.8	-	
KIDNEY	Blood Urea	29.1	15 -45 mg/dl
	S.Creatinine	1	0.60 - 1.30 mg/dl
	BUN	17.1	6 -24 mg/dl
	S.Uric Acid	5.0	M 3.1 - 7.0, F 2.5 - 5.6 mg/dl
	BUN/Creatinine Ratio	20.1	-
LIPID PROFILE	Total Cholesterol	160.1	Up to 200 mg/dl
	S.HDL	43.1	30 - 70 mg/dl
	S.LDL	88.1	Up to 170 mg/dl
	S.VLDL	29.1	5.0 - 40 mg/dl
	S. Triglycerides	145.1	Up to 170 mg/dl
	LDL/HDL Ratio	2.04	-
	Total Cholesterol/ HDL Ratio	3.7	-
THYROID	T3	98.1	40 - 181 ng/dl
	T4	7.8	4.6 - 10.5 µg/dl
	TSH	4.32	0.30 - 5.0 mIU/L

**URINE EXAMINATION**
**Microscopic Examination :**

General/Chemical Examination:	Colour	Pale Yellow	RBC	Absent
	Reaction	Acidic	WBC	7 -8
	Specific Gravity	QNS	Epithelial Cells	0- 1
	Appearance	S.TURBID	Cast	Absent
	Albumin	Nil	Crystal	Absent
	Sugar	Nil	Spermatozoa	Absent
			Amorphous Sediments	Absent
		Other	Absent	

**X-RAY CHEST**
**NORMAL STUDY**
**STOOL EXAMINATION**
**Microscopic Examination :**

General/Chemical Examination:	Colour	-	RBC	-
	Consistency	-	WBC	-
	PH	-	Ova & Parasites	-
	Reducing Substances	-		

  
**Dr. R.S. GUPTA**  
 MD Pathology (MAHE)  
 BMC No. 7924/19778

  
**TECHNOLOGIST**

All investigation have their own limitations regarding the sensitivity & specificity of individual assay procedures, Isolated laboratory investigations never confirm the final diagnosis of the disease. They only help in arriving at a diagnosis in conjunction with clinical presentation and other related investigations. Report is not valid for medico-legal purpose subject to ALWAR jurisdiction only.





# दक्ष हॉस्पिटल

396, गाँधी नगर स्कीम नं.8, अलवर (राज०) ☎ 0144-2703340

## Sonography / 2D Echo Cardiography / Doppler Report

### 2D/ ECHO REPORT

Name: - Mr Sachin

Age: - 31 Yrs

Date: - 23-Sep-23

Reg. No.:- Alw/2009/04  
BOB health checkup

PROCEDURES:

M-MODE/2D/DOPPLER/COLOR/CONTRASTB.A.S. M<sup>2</sup>

MEASUREMENT:		DOPPLER:	
AOD	24	NORMAL (20- 37mm)	MV 0.5 (0.8- 1.3)
LA	25	(19- 40mm)	AV 1.2 (1.2- 1.8)
AVO	17	(12- 25mm)	TV 0.6 (0.3- 0.8)
RVDd.	14.9	(03- 09mm)	PV 0.8 (0.7- 1.1)
LVDd	30	(37- 56mm)	MITRAL VALVE-
LVDs	30	(22- 40mm)	AML Normal
IVS d	7.8	(06- 12mm)	PML Normal
IVS s	15.5		
PWd	3.9	(05- 10mm)	AORTIC VALVE Normal
LV FUNCTION		TV & PV are normal.	
M- E- S Separation	<0.9cm		
Minor	24.42%		
LV Ejection Fraction	68%	65 +/- 12%	

LV WALL MOTION: NO RWMA  
ALL CARDIAC CHAMBERS ARE NORMAL  
ALL VALVES ARE NORMAL  
NO CLOT, VEGETATION, PERICARDIAL EFFUSION

FINAL DIAGNOSIS: NORMAL STUDY

Adv: - Follow up/ review at higher center for confirmation

Note:- Please Correlate clinically. Due to technical limitations as well as inaccuracies inherent in the laboratory and statistical analysis of biological process. Diagnostic accuracy of ECHO is up to 95% only.  
Report is not valid for medico-legal purpose.

  
Dr. DR. RAKESH KUMAR GUPTA  
PHYSICIAN & SONOLOGIST  
RM 5423/16262



"भ्रूण लिंग परीक्षण की शिकायत  
104 टोल फ्री सेवा पर भी की  
जा सकती है"

भ्रूण लिंग परीक्षण की शिकायत 104 टोल फ्री सेवा पर भी की जा सकती है।



# दक्ष हॉस्पिटल

396, गाँधी नगर स्कीम नं.8, अलवर ( राज० ) ☎ 0144-2703340

## Sonography / 2D Echo Cardiography / Doppler Report

Name: MR. SACHIN /M/31 YRS

Date: 23-Sep-23

BOB HEALTH CHECK UP

### U.S.G. OF ABDOMEN & PELVIS

#### LIVER

Liver is 14.3 cm at MCL with **mild increase echogenicty**. Intra hepatic billiary radicals are not dilated.  
No evidence of focal or diffuse lesion.

#### GALL BLADDER

Gall bladder is normal dilated. Lumen clear. Wall thickness normal. CBD normal

#### PANCREAS

Pancreas is normal in size, shape & echo-texture.

#### SPLEEN

9.4 cm in size with normal shape & echo- texture.

#### BOTH KIDENY

Both kidneys are normal in size shape and echo- texture.

URINARY BLADDER is normal shape, size & echo texture..

PROSTATE is normal shape, size (13 grm) and echo texture.

Advice- X Ray KUB / URINE EXAM

*Fully Uve - Mid*

Please correlate clinically. USG accuracy is 95 % due to technical limitations as well as inaccuracies inherent in the laboratory and statistical analysis biological process.

This report is not valid for medico-legal cases.

  
DR. MUKESH GUPTA  
SONOLOGIST  
Dr. ~~MUKESH~~ Sumar Gupta  
Physician & Sonologist  
RM 5423/16262



"भ्रूण लिंग परीक्षण की शिकायत  
104 टोल फ्री सेवा पर भी की  
जा सकती है"

भ्रूण लिंग परीक्षण की शिकायत 104 टोल फ्री सेवा पर भी की जा सकती है।



ID: 959

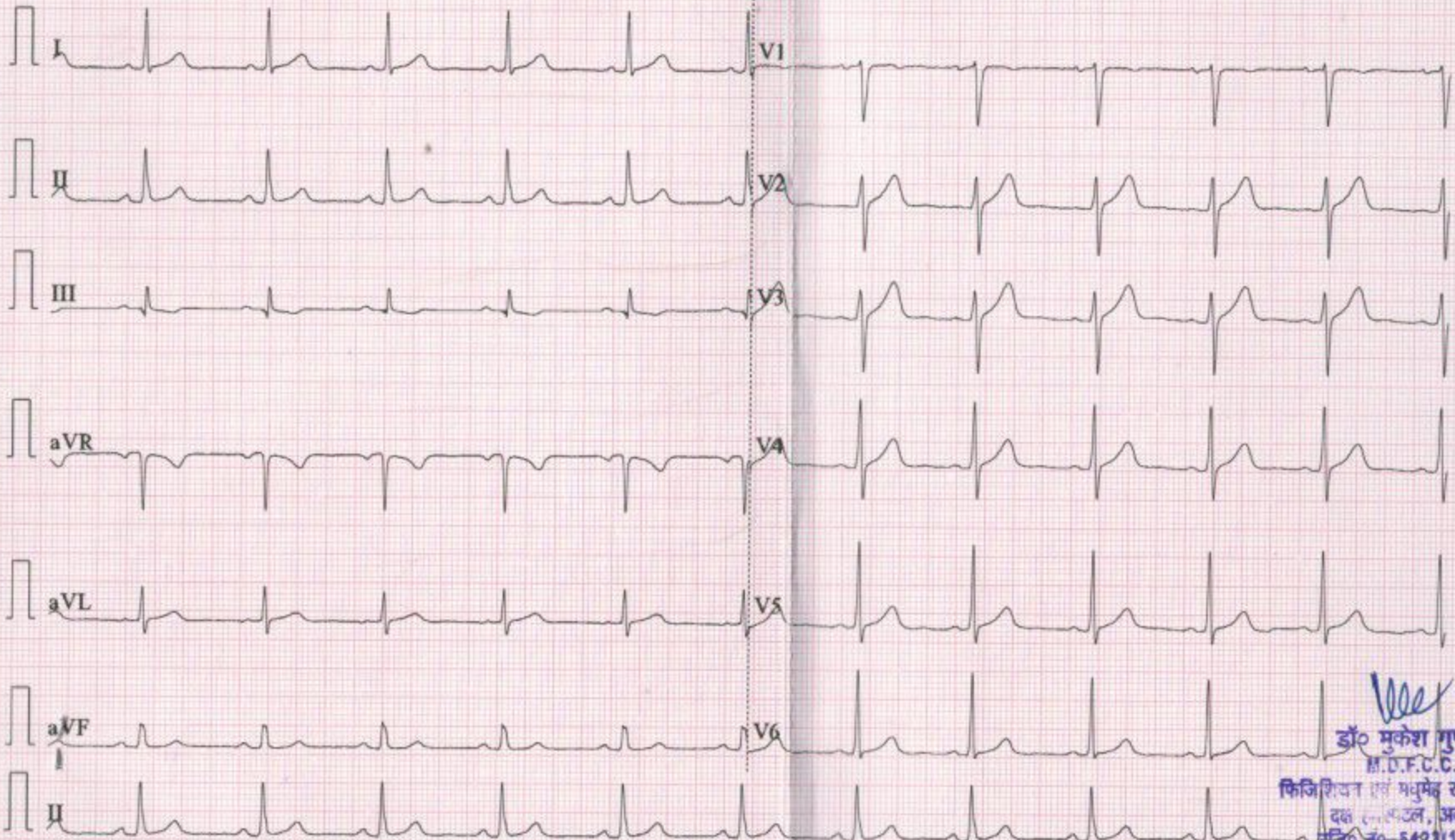
23-09-2023 13:51:11

male Years  
Req. No. :

HR : 71 bpm  
P : 96 ms  
PR : 146 ms  
QRS : 86 ms  
QT/QTcBz : 378/411 ms  
P/QRS/T : 55/37/23 °  
RV5/SV1 : 1.418/0.986 mV

Diagnosis Information:  
Sinus rhythm  
Normal ECG

Report Confirmed by:

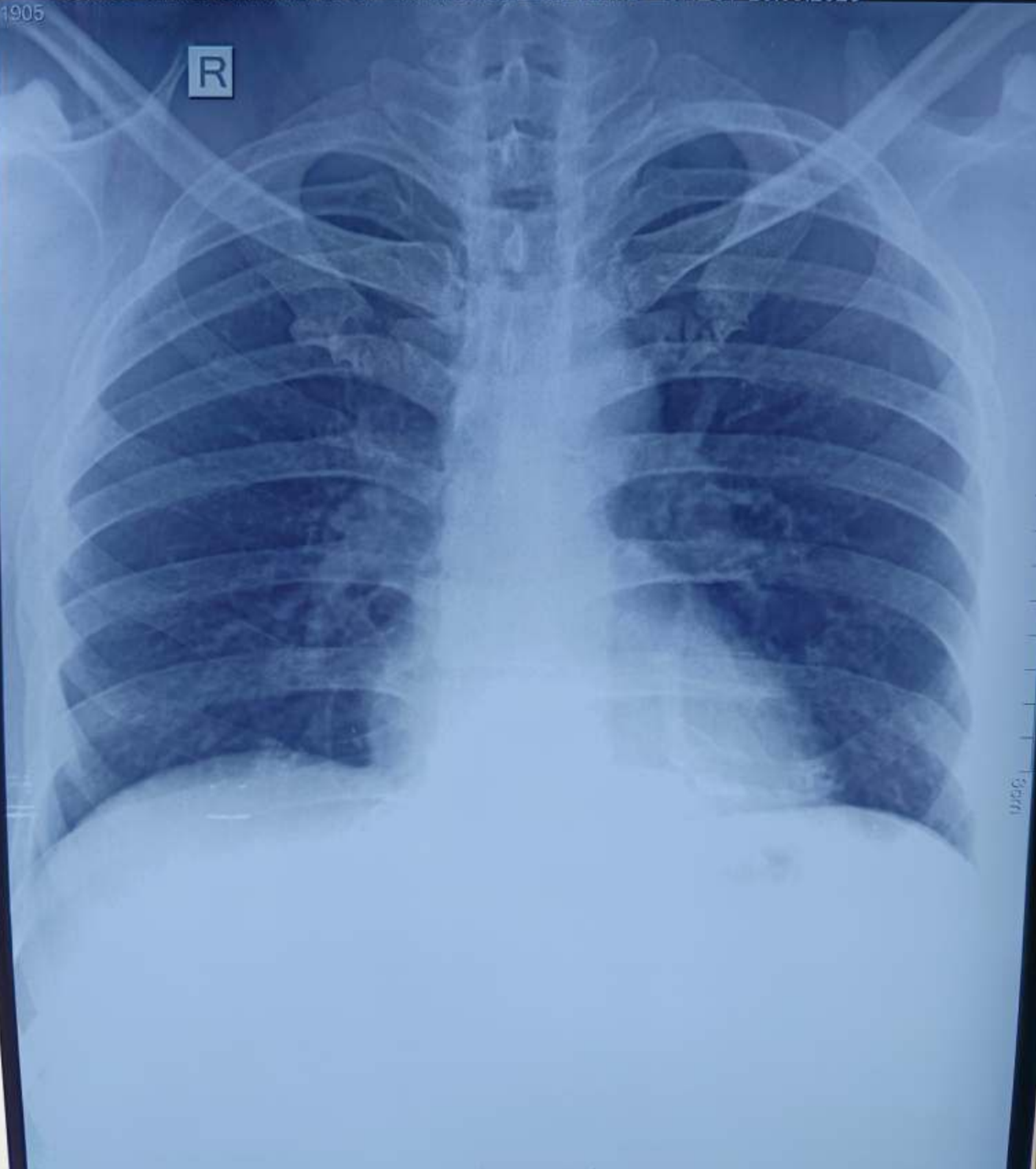


*M. D. F. C. S.*  
डॉ० मुकेश गुप्ता  
M.D.F.C.C.S.

फिजिशियन एवं मधुमेह रोग विशेषज्ञ  
दक्ष हॉस्पिटल, अलवर  
फ़ोन नं०-542316262



R



3cm

4cm