

# VASAVI HOSPITAL

#15, 1st Stage, 70th Cross, Kumaraswamy Layout, Bangalore - 560 078

## DEPARTMENT OF OPHTHAMOLOGY

### SPECTACLE PRESCRIPTION

NAME: Virek Ramuh Kulkarni

AGE: 46/M.

	RIGHT			LEFT		
	SPH	CYL	AXIS	SPH	CYL	AXIS
DV	$\pm$	—	6/6	+0.50	-1.00	180°
NV	+1.50	—	No	+2.50	-1.00	180

INSTRUCTIONS:

*Prescription is as above*

*Vasavi*

Date:

*25/9/18*

Signature of the Doctor

# Vasavi Hospital (A Unit of Sree Vasavi Trust)

#15, First Stage, 70th Cross, Kumaraswamy Layout, Bangalore - 560078

080 7150 0500

MRN : 185599      IP No:  
Name : VIVEK RAMESH KULKARNI  
Address : NO D201 GR HEIGHTS JP NAGAR 8TH PHASE, BANGALORE  
Doctor : WALK-IN

Date : 25-Sep-2021  
Gender/Age : Male/47Y  
Ph : 9620429007

Dr. Sridhar

Case Reviewed

No medical complaints.

OK

PR - 74/min

SpO<sub>2</sub> - 98%

Bp - 120/70 mmHg

Cos - S<sub>2</sub> heard

Rs - BL MURS.

Investigation Reports noted

uric acid - 9.5 mg/dl.

Advice

**Patient Name :** Mr. Vivek      **Age / Sex :** 46/M      **UHID No. :**

**Contact No. :**      **Date & Time :** 27/09/20

**Vital Parameters :**

**Height :**      **BP :**      **Weight :**      **BMI :**

Dear Oral Health Care guest, welcome to Vasavi hospital. We thank you for choosing us to address your dental care needs. You are very much a part of our team that will work closely and effectively to achieve the expected results.

Please spend few minutes to fill this form, which will aid us diagnose and treat your issues efficiently. Please ensure that the details being entered are accurate. Do feel free to contact us for any assistance.

Please tick (✓) the below details. If YES please enter the details.

Have you been diagnosed with any medical conditions ?	NO <input type="radio"/>	YES <input type="radio"/>
Do you take any medicines on a regular basis?	NO <input type="radio"/>	YES <input type="radio"/>
Are you allergic to any medication / material?	NO <input type="radio"/>	YES <input type="radio"/>
Were you hospitalized for any reason?	NO <input type="radio"/>	YES <input type="radio"/>
Have you sought dental treatment earlier?	NO <input type="radio"/>	YES <input type="radio"/>

The information provided by me is complete and accurate to the best of my knowledge.

\_\_\_\_\_  
**Patient's name and Signature**

**Chief Complaint :**

Extra oral Examination	Facial Symmetry	Lymph nodes	TMJ

**Other Findings :**

**Intra oral examination :**

Gingiva : Normal / Localised / Generalised Gingivits    Localised / General Periodontitis.

Soft Palate :

Hard Palate :

Tongue :

Oral Mucosa :

Hard tissues	Class 1	Class 2	Class 3	Class 4	Class 5	Class 6
<b>1. Decayed teeth</b>	87854321 12345678 87854321 12345678	87854321 12345678 87854321 12345678	87854321 12345678 87854321 12345678	87854321 12345678 87854321 12345678	87854321 12345678 87854321 12345678	87854321 12345678 87854321 12345678
<b>2. Fractured teeth</b>	87854321 12345678 87854321 12345678	87854321 12345678 87854321 12345678	87854321 12345678 87854321 12345678	87854321 12345678 87854321 12345678	87854321 12345678 87854321 12345678	87854321 12345678 87854321 12345678
<b>3. Malformed teeth</b>	87854321 12345678 87854321 12345678	87854321 12345678 87854321 12345678	87854321 12345678 87854321 12345678	87854321 12345678 87854321 12345678	87854321 12345678 87854321 12345678	87854321 12345678 87854321 12345678
<b>4. Missing teeth</b>	87854321 12345678 87854321 12345678	87854321 12345678 87854321 12345678	87854321 12345678 87854321 12345678	87854321 12345678 87854321 12345678	87854321 12345678 87854321 12345678	87854321 12345678 87854321 12345678
<b>5. Malpositioned teeth</b>	87854321 12345678 87854321 12345678	87854321 12345678 87854321 12345678	87854321 12345678 87854321 12345678	87854321 12345678 87854321 12345678	87854321 12345678 87854321 12345678	87854321 12345678 87854321 12345678
<b>6. Impacted teeth</b>	87854321 12345678 87854321 12345678	87854321 12345678 87854321 12345678	87854321 12345678 87854321 12345678	87854321 12345678 87854321 12345678	87854321 12345678 87854321 12345678	87854321 12345678 87854321 12345678
<b>7. Abraded teeth</b>	87854321 12345678 87854321 12345678	87854321 12345678 87854321 12345678	87854321 12345678 87854321 12345678	87854321 12345678 87854321 12345678	87854321 12345678 87854321 12345678	87854321 12345678 87854321 12345678
<b>8. Eroded teeth</b>	87854321 12345678 87854321 12345678	87854321 12345678 87854321 12345678	87854321 12345678 87854321 12345678	87854321 12345678 87854321 12345678	87854321 12345678 87854321 12345678	87854321 12345678 87854321 12345678
<b>9. Attrited teeth</b>	87854321 12345678 87854321 12345678	87854321 12345678 87854321 12345678	87854321 12345678 87854321 12345678	87854321 12345678 87854321 12345678	87854321 12345678 87854321 12345678	87854321 12345678 87854321 12345678
<b>10. Discolored teeth</b>	87854321 12345678 87854321 12345678	87854321 12345678 87854321 12345678	87854321 12345678 87854321 12345678	87854321 12345678 87854321 12345678	87854321 12345678 87854321 12345678	87854321 12345678 87854321 12345678

Treatment plan : A / B → Slowly progressing decay. Nevertheless →  
 Provisional Diagnosis : Enamel is fractured & a small cavity is present.  
 Restoration is indicated.

Treatment Done : Oral prophylaxis / Health decay

Date & Time :

  
 Dr. Name & Signature

# OUT PATIENT RECORD NOTE

Name: UVER Kamesh Kulkarni Age / Sex: 46/M Ph. No.: \_\_\_\_\_ UHID No: \_\_\_\_\_

## OUT PATIENT HISTORY, FINDINGS & ADVISE

25/9/21.

ophthal OPD

routine check up.

Using ~~near~~ plaque proglumines comfortable.  
 Nil systemic complaints.

O/E.

Visual.

VA ( 6/6  
 6/6(P)

NU ( N10  
 N10.

ROP ( 15 mmHg  
 18 mmHg :

color vision (normal).

Anterior eye ( Hypo chromic illi  
 Rest WNL.

Undilated fundus ( WNL.

Imp: Presbyopia

rxn :-

spares ( t,  
 +0.50 / -1.00 @ 180°

add +1.50

Annual eye check up

G. V. V.

PLEASE SIGN AFTER EACH ENTRY



**VASAVI  
HOSPITAL**

WE CURE WITH CARE

**DEPARTMENT OF RADIOLOGY & IMAGING** (Unit of Sree Vasavi Trust)

**Patient Name** : VIVEK RAMESH KULKARNI

**Age & Gender** : 47Y / Male

**MR No** : 185599

**OP/ IP** : OP

**Consultant** : Dr. WALK-IN

**Bill / IP No** : 149731 /

**Billing On** : 25-Sep-2021/08:40 AM

**Reported On** : 25-Sep-2021 10:10 AM/

**Study ID** : 35498

**X-RAY CHEST PA VIEW**

**FINDINGS:**

Expiratory phase film.

The lungs on the either side show equal translucency.

Cardiac size and ventricular configuration are normal.

Both hilar region appears normal.

Both C P angles appear clear.

Both domes of diaphragm appear normal.

Bony cage and soft tissue appear normal.

*SRK*

**Dr. KIRUTHIKA SELVARAJ MBBS, DMRD.**

**Consultant Radiologist**

**KMC Reg. No. 101138**

.... End report ....



#15, 70th Cross, 14th Main, 1st Stage, Kumaraswamy Layout, (Opp. to 15E Bus Stop), Bengaluru - 560 078

☎ 080 7150 0500 / 88844 66000 ✉ info@vasavihospitals.com 🌐 www.vasavihospitals.com

Gastroenterology • Neurology • Orthopaedics • General Surgery • Obstetrics & Gynecology • Nephrology & Urology • ENT • Emergency & Critical Care

**24/7 Radiology Services (Digital X-Ray, Ultrasound, Computed Tomography (CT))**



**VASAVI  
HOSPITAL**

WE CURE WITH CARE

(A Unit of Sree Vasavi Trust)

**DEPARTMENT OF RADIOLOGY & IMAGING**

**Patient Name** : VIVEK RAMESH KULKARNI

**Age & Gender** : 47Y / Male

**MR No** : 185599

**OP/ IP** : OP

**Consultant** : Dr. WALK-IN

**Bill / IP No** : 149731 /

**Billing On** : 25-Sep-2021/08:40 AM

**Reported On** : 25-Sep-2021/11:01 AM

**Study ID** : 19530

**ULTRASOUND SCAN OF ABDOMEN AND PELVIS**

**LIVER:** Liver is 13.3 cms, in size, both lobes of liver are normal in size and homogeneous echotexture. No evidence of any focal lesion / intrahepatic biliary dilatation noted. CBD and Portal vein normal in size and echotexture.

**GALL BLADDER:** Well distended, gall bladder wall thickness is normal. Contents are clear. No evidence of gall stones / cholecystitis.

**PANCREAS:** Head and body appears normal. Uncinate process and tail could not be assessed due to bowel gas. MPD is normal.

**SPLEEN:** Normal in size measuring 9.2 cms with normal echotexture.

**KIDNEYS:** Both Kidneys are normal in size, shape, contour & position. Corticomedullary differentiation is well maintained. No evidence of any hydronephrosis / hydroureter.

Right Kidney measures : 9.0 x 4.7 cms. Parenchymal thickness 1.3 cms.

Left Kidney measures : 9.8 x 5.1 cms. Parenchymal thickness 1.4 cms.

**URINARY BLADDER:** Well distended with clear contents. Wall thickness is normal.

**PROSTATE:** Normal in size and echotexture. Prostate volume - 17 cc.

No focal lesion seen. Both seminal vesicles appear normal.

No obvious free fluid in the peritoneal cavity / pleural collection.

**IMPRESSION:**

> **NO SONOLOGICALLY DETECTABLE ABNORMALITY IN THIS STUDY.**

\*\* Note: All abnormalities cannot be detected by Ultrasound scan due to technical limitation, obesity and other factors. Scan findings to be correlated with old reports or other investigations.

*SRK*

**Dr. KIRUTHIKA SELVARAJ MBBS, DMRD.**

**Consultant Radiologist**

**KMC Reg. No. 101138**

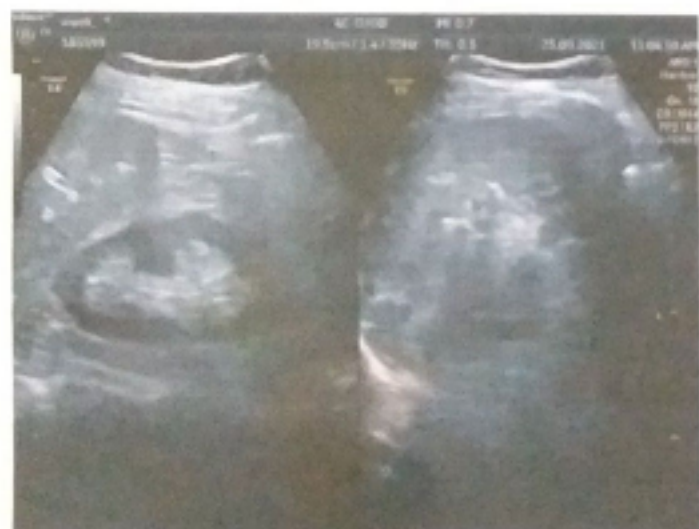
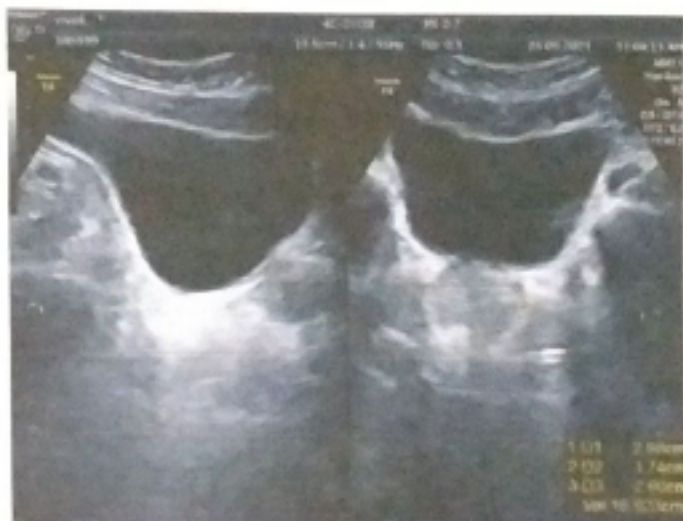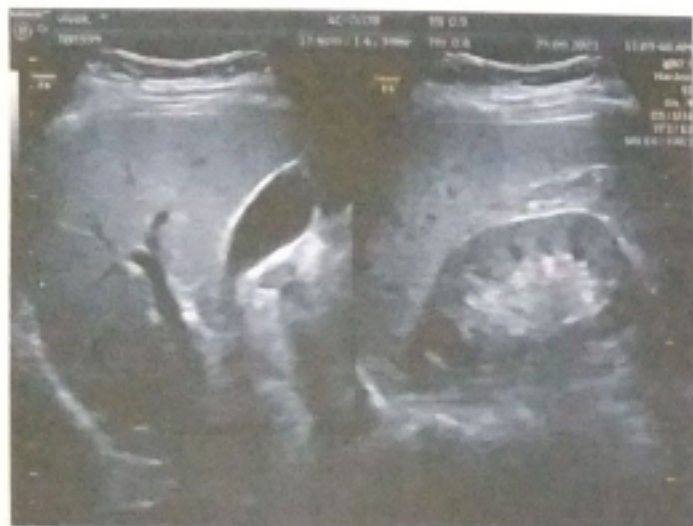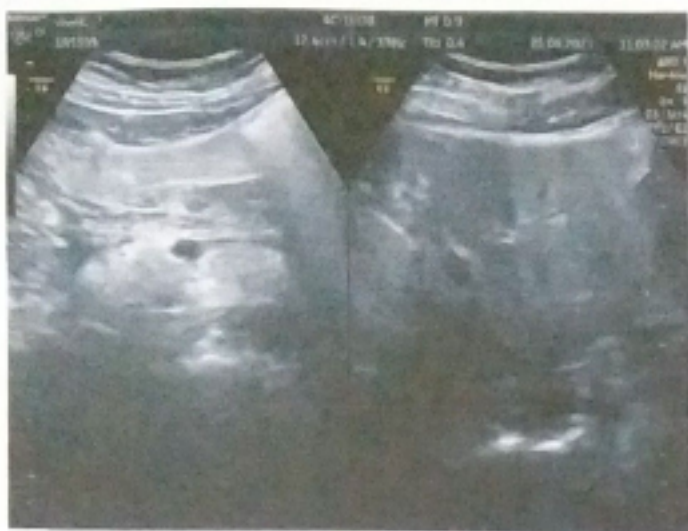.... End report ....

#15, 70th Cross, 14th Main, 1st Stage, Kumaraswamy Layout, (Opp. to 15E Bus Stop), Bengaluru - 560 078

☎ 080 7150 0500 / 88844 66000 ✉ info@vasavihospitals.com 🌐 www.vasavihospitals.com

Gastroenterology • Neurology • Orthopaedics • General Surgery • Obstetrics & Gynecology • Nephrology & Urology • ENT • Emergency & Critical Care

**24/7 Radiology Services (Digital X-Ray, Ultrasound, Computed Tomography (CT))**







Name	: VIVEK RAMESH KULKARNI	REG/LAB NO.	: 21090701 / 149730
AGE/SEX	: 46 Yrs / Male	DATE OF COLLECTION	: 25-09-2021 at 08:56 AM
REFERRED BY	:	DATE OF REPORT	: 25-09-2021 at 11:49 AM
CONTACT NO.	: 9620429007	BILL NO.	: 030728



TEST PARAMETER	RESULT	REFERENCE RANGE
<b>Mediwheel Full Body Health Checkup (above 40 yrs male - 80148)</b>		
<b><u>COMPLETE BLOOD COUNT (CBC)</u></b>		
HAEMOGLOBIN	13.0 gm/dl	14 - 18 gm/dl
TOTAL COUNT	5820 cells/cumm	4000 - 11000 cells/cumm
<b><u>DIFFERENTIAL COUNT</u></b>		
NEUTROPHILS	53 %	40 - 70 %
LYMPHOCYTES	34 %	20 - 45 %
MONOCYTES	07 %	2 - 8 %
EOSINOPHILS	06 %	1 - 6 %
BASOPHILS	00 %	0 - 1 %
R.B.C COUNT	4.53 mill/cumm	4.5 - 6.2 mill/cumm
PACKED CELL VOLUME (PCV)	39.4 %	37 - 47 %
PLATELET COUNT	2.27 Lakhs/cumm	1.5 - 4.5 Lakhs/cumm
M.C.V	86.9 fl	80 - 98 fl
M.C.H	28.8 pg	26 - 34 pg
M.C.H.C	33.1 %	31 - 38 %

### **BLOOD GROUP & Rh TYPE**

BLOOD GROUP	"B"
RH TYPE	POSITIVE

**Dr Badrinath S**

MD(PGI) KMC No. 18014  
Senior Consultant



Name : **VIVEK RAMESH KULKARNI**

AGE/SEX : 46 Yrs / Male

REFERRED BY :

CONTACT NO. : 9620429007

REG/LAB NO. : 21090701 / 149730

DATE OF COLLECTION : 25-09-2021 at 08:56 AM

DATE OF REPORT : 25-09-2021 at 11:49 AM

BILL NO. : 030728



TEST PARAMETER	RESULT	REFERENCE RANGE
<b><u>E S R (westergren)</u></b>		
ESR	36 mm/hr	0 - 9 mm/hr
<b><u>BLOOD UREA NITROGEN (BUN)</u></b>		
BLOOD UREA NITROGEN	9.4 mg/dl	8 - 24 mg/dl
<b><u>FASTING BLOOD SUGAR</u></b>		
FASTING BLOOD SUGAR	97 mg/dl	74 - 100 mg/dl
<b><u>GLYCOSYLATED HEMOGLOBIN (HbA1c)</u></b>		
HbA1c (GLYCOSYLATED Hb)	5.7 %	4 - 6 %

Degree of Control	HbA1c	MBG
Normal	< 6.0 %	61-124 mg/dl
Good Control	6.0-7.0 %	124-156 mg/dl
Fair Control	7.0-8.0 %	158-188 mg/dl
Poor Control	> 8.0 %	>188 mg/dl

**Dr Badrinath S**

MD(PGI) KMC No. 19014  
Senior Consultant



Name : VIVEK RAMESH KULKARNI  
AGE/SEX : 46 Yrs / Male  
REFERRED BY :  
CONTACT NO. : 9620429007

REG/LAB NO. : 21090701 / 149730  
DATE OF COLLECTION : 25-09-2021 at 08:56 AM  
DATE OF REPORT : 25-09-2021 at 11:49 AM  
BILL NO. : 030728



TEST PARAMETER	RESULT	REFERENCE RANGE
<b>LIPID PROFILE</b>		
TOTAL CHOLESTEROL	171 mg/dl	up to 200 mg/dl
TRIGLYCERIDES	132 mg/dl	up to 200 mg/dl
		<b>Special condition:</b> Borderline high risk : 200 - 400 mg/dL Elevated : > 400 mg/dL
HDL CHOLESTEROL - DIRECT	45 mg/dl	35 - 55 mg/dl
LDL CHOLESTEROL - DIRECT	112 mg/dl	up to 130 mg/dl
TC/HDL	3.8	
LDL/HDL	2.4	

**Dr Badrinath S**  
MD(PGI) KMC No 19014  
Senior Consultant



Name : VIVEK RAMESH KULKARNI

AGE/SEX : 46 Yrs / Male

REFERRED BY :


CONTACT NO. : 9620429007

REG/LAB NO. : 21090701 / 149730

DATE OF COLLECTION : 25-09-2021 at 08:56 AM

DATE OF REPORT : 25-09-2021 at 11:49 AM

BILL NO. : 030728



TEST PARAMETER	RESULT	REFERENCE RANGE
<b>LIVER FUNCTION TEST (LFT)</b>		
TOTAL BILIRUBIN	0.60 mg/dl	Adult - 0.2 - 1.3 mg/ dL
<b>Special condition:</b> Premature - <2.0 mg/ dL Full term - <2.0 mg/ dL 0-1 day - Premature- 1.0 - 8.0 mg/ dL 0-1 day - Full term - 2.0 - 6.0 mg/ dL 1 - 2 days Premature - 6.0 - 12.0 mg/ dL 1 - 2 days Full term - 6.0 - 10.0 mg/ dL 3 - 5 days Premature - 10.0 - 14.0 mg/ dL 3 - 5 days Full term - 4.0 - 8.0 mg/ dL		
DIRECT BILIRUBIN	0.28 mg/dl	0 - 0.25 mg/dl
INDIRECT BILIRUBIN	0.32 mg/dl	
ASPARATE AMINOTRANSFERASE (SGOT/AST)	16.5 U/L	up to 40 U/L
ALANINE AMINOTRANSFERASE (SGPT/ALT)	17.4 U/L	up to 40 U/L
ALKALINE PHOSPHATASE	70 IU/L	25 - 147 IU/L
TOTAL PROTEIN	6.9 g/dl	6 - 8.5 g/dl
SERUM ALBUMIN	4.0 g/dl	3.5 - 5.2 g/dl
SERUM GLOBULIN	2.9 g/dL	2.3 - 3.5 g/dL
A/G RATIO	1.4	1 - 1.5

Dr Badrinath S

MD(PGI) KMC No. 19014  
Senior Consultant



Name : VIVEK RAMESH KULKARNI  
AGE/SEX : 46 Yrs / Male  
REFERRED BY :  
CONTACT NO. : 9620429007

REG/LAB NO. : 21090701 / 149730  
DATE OF COLLECTION : 25-09-2021 at 08:56 AM  
DATE OF REPORT : 25-09-2021 at 11:49 AM  
BILL NO. : 030728



TEST PARAMETER	RESULT	REFERENCE RANGE
SERUM CREATININE	0.78 mg/dL	0.6 - 1.4 mg/dL
<b>URIC ACID</b>		
URIC ACID	9.5 mg/dL ↑	4.5 - 8.1 mg/dL
<b>THYROID PROFILE (T3, T4, TSH)</b>		
TOTAL TRIIODOTHYRONINE (T3)	2.0 nmol/L	0.93 - 3.3 nmol/L
TOTAL THYROXINE (T4)	158.8 nmol/L	60 - 120 nmol/L
		<b>Special condition:</b> in Pregnancy (nmol/L) First Trimesters: 100-190 Second Trimesters: 92-252 Third Trimesters: 108-219
THYROID STIMULATING HORMONE (TSH)	1.50 µIU/ml	0.27 - 5 µIU/ml
<b>Urine Sugar (fasting)</b>		
Urine Sugar (fasting)	Nil	

1


Dr Badrinath S

MD(PGI) KMC No. 19014  
Senior Consultant



Name : **VIVEK RAMESH KULKARNI**  
AGE/SEX : 46 Yrs / Male  
REFERRED BY :  
CONTACT NO. : 9620429007

REG/LAB NO. : 21090701 / 149730  
DATE OF COLLECTION : 25-09-2021 at 08:56 AM  
DATE OF REPORT : 25-09-2021 at 11:49 AM  
BILL NO. : 030728



TEST PARAMETER	RESULT	REFERENCE RANGE
<b>URINE ROUTINE</b>		
<b>PHYSICAL CHARACTERS</b>		
COLOUR	PALE YELLOW	
APPEARANCE	CLEAR	
SPECIFIC GRAVITY	1.005	
pH	6.0	
<b>CHEMICAL CONSTITUENTS</b>		
ALBUMIN	NIL	
SUGAR	NIL	
BILE SALTS	ABSENT	
BILE PIGMENTS	ABSENT	
KETONE BODIES	ABSENT	
BLOOD	ABSENT	
<b>MICROSCOPY</b>		
PUS CELLS	2 - 3 /hpf	
R.B.C	NIL	
EPITHELIAL CELLS	1 - 2 /hpf	
CASTS	ABSENT	
CRYSTALS	ABSENT	

**Dr Badrinath S**  
MD(PG) KMC No. 19014  
Senior Consultant

Dispatched by: Dr Badrinath S

\*\*\*\* End of Report \*\*\*\*

Printed by: Shwetha on 25-09-2021 at 12:42 PM



Name : **VIVEK RAMESH KULKARNI**

AGE/SEX : 46 Yrs / Male

REFERRED BY :


CONTACT NO. : 9620429007

REG/LAB NO. : 21090701 / 149730


DATE OF COLLECTION : 25-09-2021 at 08:56 AM

DATE OF REPORT : 25-09-2021 at 12:21 PM

BILL NO. : 030728



TEST PARAMETER	RESULT	REFERENCE RANGE
<b>Mediwheel Full Body Health Checkup (above 40 yrs male - 80148)</b>		
<b>POSTPRANDIAL BLOOD GLUCOSE</b>		
POST PRANDIAL BLOOD SUGAR	103 mg/dl	70 - 140 mg/dl
<b>Urine Sugar (PP)</b>		
Urine Sugar (PP)	Nil	

  
**Dr Badrinath S**  
MD(PGI) KMC No. 19014  
Senior Consultant

Dispatched by: Dr Badrinath S

\*\*\*\* End of Report \*\*\*\*

Printed by: Shwetha on 25-09-2021 at 12:42 PM

Vivek Ramesh Kulkarni

25/09/2021 12:16:24 PM

Rate 54  
PR 167  
QRS 99  
QT 419  
QTc 398

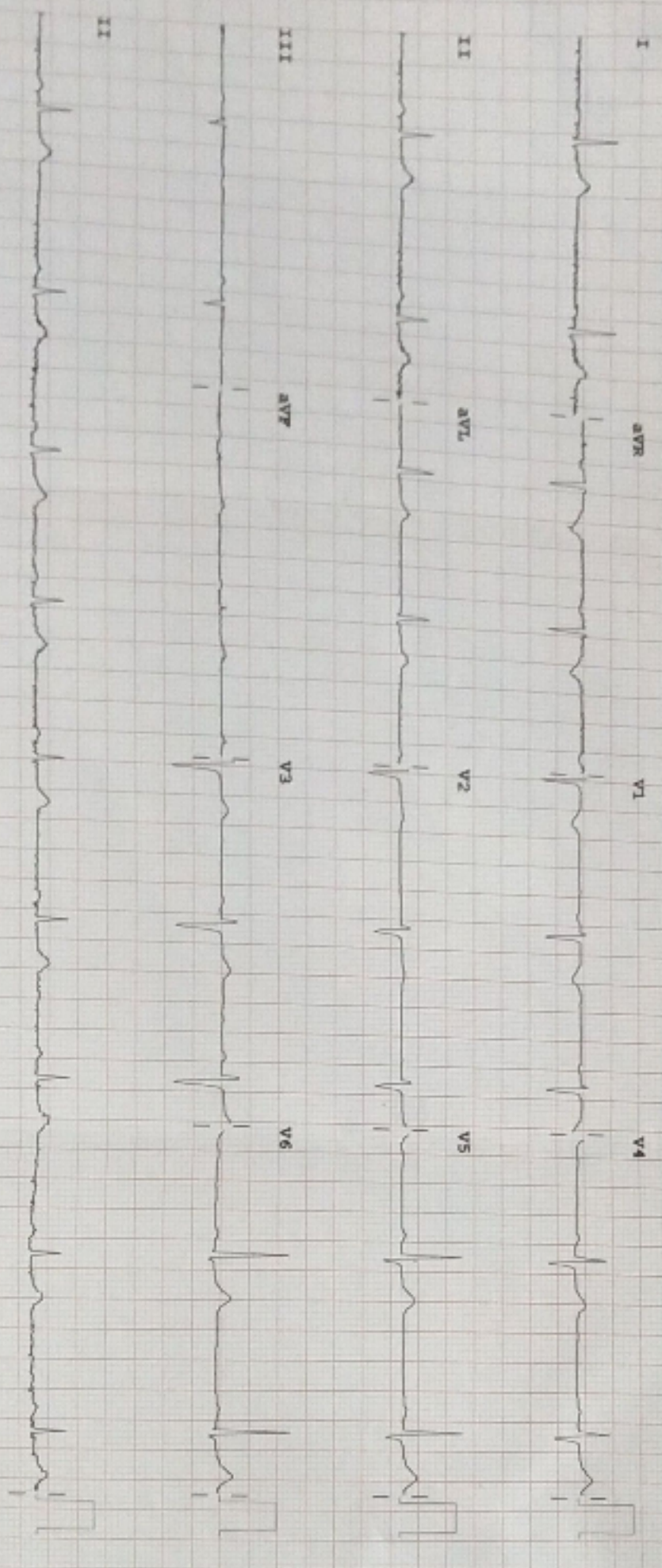
--AXIS--  
P 43  
QRS 6  
T 28

12 Lead: Standard Placement

Age not entered, assumed to be 50 years old for purpose of ECG interpretation  
Sinus rhythm.  
Baseline wander in lead(s) V5  
normal P axis, V-rate 50-99

- NORMAL ECG -

Unconfirmed Diagnosis



ospital

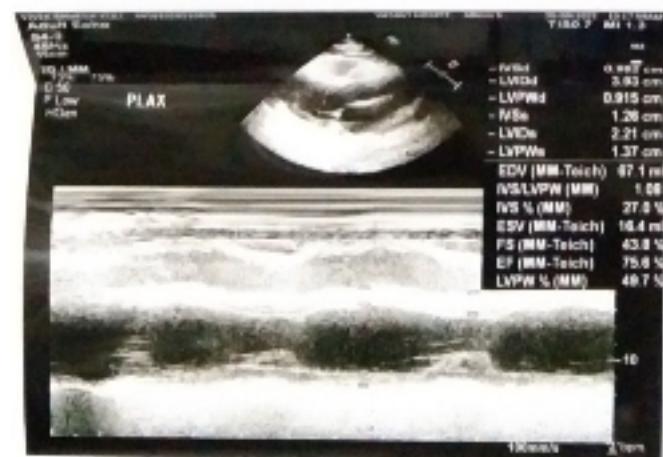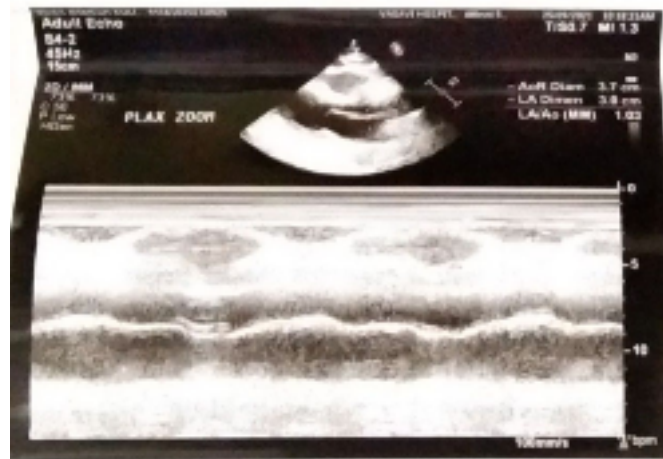
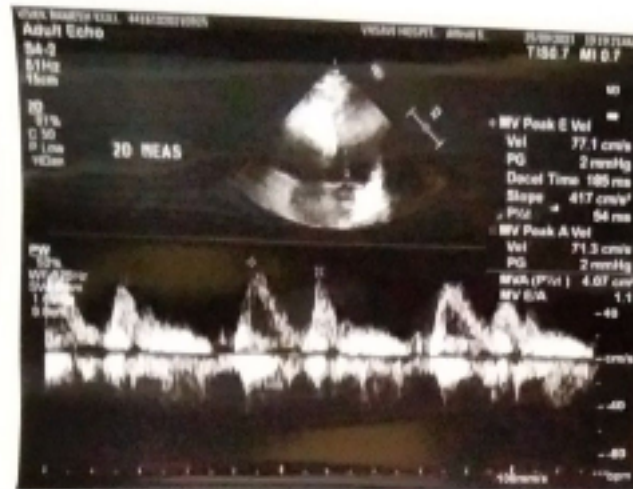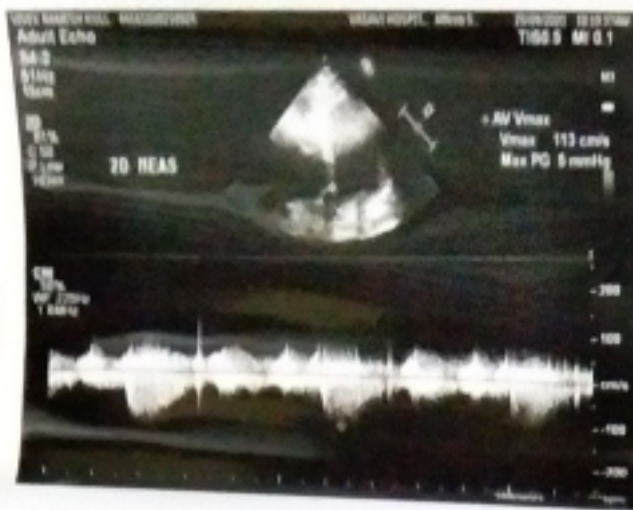Device: Speed: 25 mm/sec 10 mm/mV 10.0 mm/mV

PHILIPS

REORDER # 454544

P 50-0.15-100 Hz 100B CL P2







## CARDIOLOGY - NON INVASIVE DEPARTMENT

Patient Name : VIVEK RAMESH KULKARNI

Age & Gender : 47Y / Male

MR No : 185599

OP/ IP : OP

Consultant : Dr. WALK-IN

Bill / IP No : 149731 /

Billing On : 25-Sep-2021/08:40 AM

Reported On : 25-Sep-2021/08:41 AM

Study ID :

### 2D ECHO CARDIOGRAPHY REPORT

#### M - MODE MEASUREMENTS

AO	3.75	cm	RVIDD	1.20	cm
LA	3.82	cm	IVSD	0.99	cm
AO/LA RATIO	1.12	cm	LVIDD	3.93	cm
AV CUP	0.92	cm	LVPWD	0.91	cm
EPSS	0.9	cm	IVSS	1.26	cm
DE	1.83	cm	LVIDS	2.21	cm
EF SLOPE	0.7	cm	LVPWS	1.37	cm
SV	57.41		EDV	67.12	ml
CO			ESV	16.40	ml
HR			EF	75.63	%
LVMl			FS	43.85	%
OTHERS			LV MASS	127.35	grams

**DESCRIPTIVE FINDINGS:** Technically Adequate Study. Normal Sinus rhythm during Study

LEFT VENTRICLE	Normal in size
LEFT ATRIUM	Normal in size
RIGHT VENTRICLE	Normal in size
RIGHT ATRIUM	Normal in size
WALL MOTION ANALYSIS	No RWMA
TRICUSPID VALVE	Normal
MITRAL VALVE	Normal
PULMONIC VALVE	Normal
AORTIC VALVE	Normal
IAS & IVS	Intact
AORTA & PA	Normal In Size
SYSTEMIC & PULMONARY VENIS	Normally Draining
PERICARDIUM	Normal
OTHERS	No Intra Cardiac Thrombus, Tumour or Vegetation

#15, 70th Cross, 14th Main, 1st Stage, Kumaraswamy Layout (Opp. to 15 E Bus Stop), Bengaluru - 560 078

☎ 080 7150 0500 / 88844 66000 ✉ info@vasavihospitals.com 🌐 www.vasavihospitals.com


**DOPPLER STUDY**

VALVES	VELOCITY	GRADIENT	REGURGITATION	OTHERS
P V	0.71m/s		NO PR	
MV	E: 0.77 m/s A: 0.71m/s		NO MR	
AV	1.13 m/s		NO AR	
TV	E: 0.60m/s A: 0.40m/s		NO TR	
OTHERS				

**SUMMARY FINDINGS:**

NORMAL CARDIAC CHAMBERS & VOLUMES  
 NO REGIONAL WALL MOTION ABNORMALITY PRESENT  
 NORMAL LV SYSTOLIC FUNCTION (EF- 75 %)  
 NO CLOT / EFFUSION / VEGETATION / PAH

**Mr. DEVASAGAYAM C**  
**Sr. CARDIOTECHNOLOGIST**



**Dr. PRANEETH S**  
**CONSULTANT CARDIOLOGIST**

