

To,

The Coordinator,
Mediwheel (Arcofemi Healthcare Limited)
Helpline number: 011- 41195959

Dear Sir / Madam,

Sub: Annual Health Checkup for the employees of Bank of Baroda

This is to inform you that the following spouse of our employee wishes to avail the facility of Cashless Annual Health Checkup provided by you in terms of our agreement.

PARTICULARS OF HEALTH CHECK UP BENEFICIARY	
NAME	POONAM KUMARI 39/F
DATE OF BIRTH	01-01-1983
PROPOSED DATE OF HEALTH CHECKUP FOR EMPLOYEE SPOUSE	24-03-2023
BOOKING REFERENCE NO.	22M73944100051418S
SPOUSE DETAILS	
EMPLOYEE NAME	MR. KUMAR MANISH
EMPLOYEE EC NO.	73944
EMPLOYEE DESIGNATION	BRANCH HEAD
EMPLOYEE PLACE OF WORK	CANSA
EMPLOYEE BIRTHDATE	01-03-1983

This letter of approval / recommendation is valid if submitted along with copy of the Bank of Baroda employee id card. This approval is valid from **21-03-2023** till **31-03-2023**. The list of medical tests to be conducted is provided in the annexure to this letter. Please note that the said health checkup is a **cashless facility** as per our tie up arrangement. We request you to attend to the health checkup requirement of our employee's spouse and accord your top priority and best resources in this regard. The EC Number and the booking reference number as given in the above table shall be mentioned in the invoice, invariably.

We solicit your co-operation in this regard.

Yours faithfully,

Sd/-

Chief General Manager
HRM Department
Bank of Baroda

(Note: This is a computer generated letter. No Signature required. For any clarification, please contact Mediwheel (Arcofemi Healthcare Limited))

 **भारत सरकार**
GOVERNMENT OF INDIA

 Poonam Kumari
Date of Birth/DOB: 01/01/1983
Female/ FEMALE
Mobile No: 9403560230

7408 3630 7698
VID : 9162 4869 7400 4039



मेरा आधार, मेरी पहचान

 **भारतीय विशिष्ट पहचान प्राधिकरण**
UNIQUE IDENTIFICATION AUTHORITY OF INDIA

Address :
W/O Manish Kumar, House no-110,
Panahar Ka Tola Imadapur, Imadapur,
Panhar, Nalanda,
Bihar - 801303





 1947
 head@uidai.gov.in
 www.uidai.gov.in
 P.O. Box No. 1947
Bangalore-560 081

Generation Date: 27/03/2018



SAVAIKAR HOSPITAL & LAPAROSCOPY CENTRE



Warkhandem, Ponda, Goa 403 401

Hosp. Reg. No. T/0/412

Tel. No. 2312603, 2319202 OPD.: 2311031 Fax No. 2319870

website : www.savaikarhospital.com

email : drsavaikar@gmail.com

Patient : MRS. POONAM KUMARI

LHID No : SHLC/28726

Ref.by : DR.MEGHA SAVAIKAR

Bill No : 8672

Age/Sex : 40/Female

Date : 24.03.2023

Print Date : 24.03.2023 01:28:12 PM

HAEMATOLOGY REPORT

<u>Test Done</u>	<u>Observed values</u>	<u>Ref. Range</u>
<u>COMPLETE BLOOD COUNT</u>		
HAEMOGLOBIN (HB)	<u>10.2</u> g/dl	M: 13.5 - 19.5 g/dl, F: 11.5 - 16.5 g/dl
TOTAL WBC COUNT	6,400 Cells/cu mm	4,000-10,500 /cu mm
<u>DIFFERENTIAL COUNT</u>		
STAB CELLS (IMMATURE NEUTROPHILS)	02 %	0 - 5 %
NEUTROPHILS	55 %	40 - 70 %
LYMPHOCYTES	36 %	20 - 45 %
EOSINOPHILS	03 %	1 - 4 %
MONOCYTES	04 %	2 - 8 %
BASOPHILS	00 %	0 - 1 %
PLATELETS	1,56,000 /cu mm	1,50,000 - 4,00,000 /cu mm
RBC COUNT	3.82 millions/cu mm	4.5 - 6.5 / cu mm
HCT	30.4 %	40 to 54 %

<u>Test Done</u>	<u>Observed values</u>	<u>Ref. Range</u>
<u>COMPLETE BLOOD COUNT</u>		
ESR	26 mm/hr	0 - 20 mm/hr

..... End of Report

CHECKED BY

LAB TECHNICIAN

Usha V. Priolkar

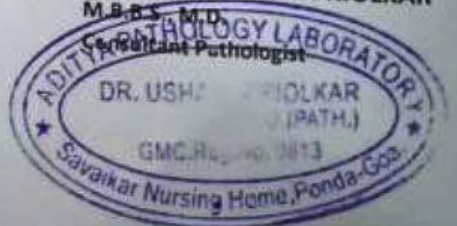DR. MRS. USHA V. PRIOLKAR

M.B.B.S. M.D.

Consultant Pathologist

DR. USHA V. PRIOLKAR (PATH.)

GMC.Reg. No. 2813



The Hospital for perfect health



SAVAIKAR HOSPITAL & LAPAROSCOPY CENTRE



Warkhandem, Ponda, Goa-403 401

Hosp. Reg. No. T/0/412

Tel. No. 2312603, 2319202 OPD.: 2311031 Fax No. 2319870

website : www.savaikarhospital.com

email : drsavaikar@gmail.com



Patient : MRS. POONAM KUMARI

Age/Sex : 40/Female

UHID No : SHLC/28726

Date : 24.03.2023

Ref.by : DR.MEGHA SAVAIKAR

Bill No : 8672

Print Date : 24.03.2023 03:19:05 PM

<u>Test Done</u>	<u>Observed values</u>	<u>Ref. Range</u>
FASTING BLOOD SUGAR		
FASTING BLOOD SUGAR	80.1 mg/dl	60 to 110
BLOOD SUGAR POST PRANDIAL		
BLOOD SUGAR POST PRANDIAL	96.3 mg/dl	70 to 150 mg/dl
HBA1C		
HBA1C	4.61 %	Normal 0.0-6.0% Good Control 6.0-7.0% Fair Control 7.0-8.0% Poor Control 8.0-10.0% Unsatisfactory c

<u>Test Done</u>	<u>Observed values</u>	<u>Ref. Range</u>
HBA1C		
Mean Blood Glucose	86.81 mg%	100-140

..... End of Report

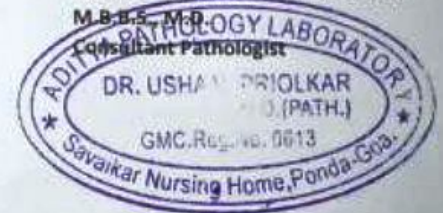CHECKED BY

LAB TECHNICIAN

DR. MRS. USHA V. PRIOLKAR

M.B.B.S., M.D.

Consultant Pathologist



DR. USHA V. PRIOLKAR

M.D. (PATH.)

GMC.Reg.No. 0613

Savaikar Nursing Home, Ponda-Goa.

The Hospital for perfect health



SAVAIKAR HOSPITAL & LAPAROSCOPY CENTRE



Warkhandem, Ponda, Goa 403 401
 Hosp. Reg. No. T/0/412
 Tel. No. 2312603, 2319202 OPD.: 2311031 Fax No. 2319870
 website : www.savaikarhospital.com
 email : drsavaikar@gmail.com

॥ आरोग्यं धनं परमं ॥

Patient : MRS. POONAM KUMARI
 UHID No : SHLC/28726
 Ref.by : DR.MEGHA SAVAIKAR
 Bill No : 8672

Age/Sex : 40/Female
 Date : 24.03.2023
 Print Date : 24.03.2023 03:25:04 PM

Test Done	Observed values	Ref. Range
BLOOD GROUP RH TYPING		
BLOOD GROUP RH TYPING	'B' Rh Positive	

BIOCHEMISTRY REPORT

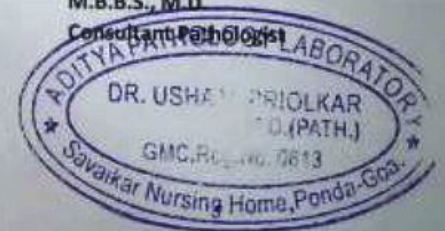Test Done	Observed values	Ref. Range
RENAL FUNCTION TEST		
Blood Urea	30.8 mg/dl	15.0 - 40.0
BUN	14.38 mg/dl	5.0 - 21.0
CREATININE	0.82 mg/dl	0.5 - 1.5
URIC ACID	3.61 mg/dl	Male : 3.5 - 7.2, Female : 2.5 - 6.2
LIPID PROFILE		
SERUM CHOLESTEROL	148.0 mg/dl	130 to 240 mg/dl
HDL CHOLESTEROL	49.3 mg/dl	M:35-80,F:42-88
SERUM TRIGLYCERIDES	83.6 mg/dl	0 to 200
VLDL CHOLESTEROL	16.72 mg/dl	0 - 35
LDL CHOLESTEROL	81.98 mg/dl	0 - 160
LDL/HDL CHOLESTROL (R)	1.66	0.0 - 4.0
TOTAL CHOL / HDL CHO	3.00	0.0 - 4.5

..... End of Report

CHECKED BY

 LAB TECHNICIAN

DR. MRS. USHA V. PRIOLKAR
 M.B.B.S., M.D.
 Consultant Pathologist





SAVAIKAR HOSPITAL & LAPAROSCOPY CENTRE



Warkhandem, Ponda, Goa 403 401

Hosp. Reg. No. T/0/412

Tel. No. 2312603, 2319202 OPD.: 2311031 Fax No. 2319870

website : www.savaikarhospital.com

email : drsavaikar@gmail.com

॥ आरोग्यं परमं धनम् ॥

Patient : MRS. POONAM KUMARI

Age/Sex : 40/Female

UHID No : SHLC/28726

Date : 24.03.2023

Ref.by : DR.MEGHA SAVAIKAR

Bill No : 8672

Print Date : 24.03.2023 03:28:07 PM

BIOCHEMISTRY REPORT

<u>Test Done</u>	<u>Observed values</u>	<u>Ref. Range</u>
<u>LIVER FUNCTION TEST WITH PROTEINS</u>		
SGOT	23.0 U/L	5 - 40
SGPT	27.1 U/L	7 - 50
<u>BILIRUBIN</u>		
TOTAL	0.31 mg/dl	0.1 - 1.2
DIRECT	0.16 mg/dl	0.058 - 0.3
INDIRECT	0.15 mg/dl	0.2 - 0.7
ALKALINE PHOSPHATASE	107.6 U/L	53 - 128
<u>SERUM PROTEIN</u>		
TOTAL PROTEINS	6.01 gms %	6.0 - 8.5
ALBUMIN	3.32 gms %	3.2 - 5.5
GLOBULIN	2.69 gms %	2.1 - 3.3
A:G RATIO	1.23	1.5 - 2.1:1

..... End of Report

CHECKED BY

LAB TECHNICIAN

DR. MRS. USHA V. PRIOLKAR
 M.B.B.S., M.D.
 Consultant Pathologist
 ADIYAN PATHOLOGY LABORATORY
 DR. USHA V. PRIOLKAR
 (PATH.)
 GMC, Ponda, Goa 403 401
 Savaikar Nursing Home, Ponda-Goa



SAVAIKAR HOSPITAL & LAPAROSCOPY CENTRE

Warkhandem, Ponda, Goa 403 401

Hosp. Reg. No. T/0/412

Tel. No. 2312603, 2319202 OPD.: 2311031 Fax No. 2319870

website : www.savaikarhospital.com

email : drsavaikar@gmail.com



॥ अस्मिन्मन्त्रे ॥

Patient : MRS. POONAM KUMARI

Age/Sex : 40/Female

UHID No : SHLC/28726

Date : 24.03.2023

Ref.by : DR.MEGHA SAVAIKAR

Bill No : 8672

Print Date : 24.03.2023 03:13:49 PM

CLINICAL PATHOLOGY REPORT

Test Done

Observed values

Ref. Range

URINE ROUTINE

PHYSICAL EXAMINATION

Colour	Pale Yellow
Odour	Faintly Aromatic
Appearance	Slightly Hazy

CHEMICAL EXAMINATION

Reaction	6.0	5.5 - 7.5
Specific Gravity	1.025	1.010 - 1.025
Deposit	Absent	
Protein	Absent	
Sugar	Absent	
Ketones	Absent	

MICROSCOPIC EXAMINATION

Pus Cells	6-8 /hpf	0 - 5 hpf
Epithelial Cells	3-4 /hpf	
RBC's	nil /hpf	0 - 2hpf

..... End of Report

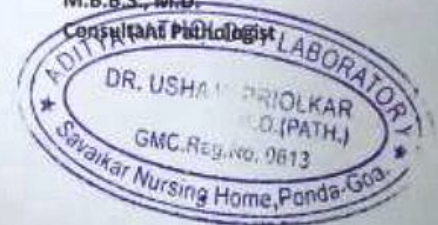
CHECKED BY

LAB TECHNICIAN

DR. MRS. USHA V. PRIOLKAR

M.B.B.S., M.D.

Consultant Pathologist



The Hospital for perfect health



SAVAIKAR HOSPITAL & LAPAROSCOPY CENTRE



Warkhandem, Ponda, Goa 403 401

Hosp. Reg. No. T/0/412

Tel. No. 2312603, 2319202 OPD.: 2311031 Fax No. 2319870

website : www.savaikarhospital.com

email : drsavaikar@gmail.com

|| अस्मिन्मन्त्रेण भवति यथा ||

Patient : MRS. POONAM KUMARI

UHID No : SHLC/28726

Ref.by : DR.MEGHA SAVAIKAR

Bill No : 8672

Age/Sex : 40/Female

Date : 24.03.2023

Print Date : 24.03.2023 03:17:43 PM

CLINICAL PATHOLOGY REPORT

Test Done

STOOL REPORT

PHYSICAL EXAMINATION

Test Done	Observed values	Ref. Range
Colour	Brownish	
Consistency	Semi- solid	
Mucus	Absent	
Blood	Absent	

CHEMICAL EXAMINATION

Reaction	6.0	
Occult Blood	Negative	
Reducing Substances	Absent	

MICROSCOPIC EXAMINATION

Epithelial Cells	1-2 /hpf	
Pus Cells	2-3 /hpf	
RBCs	Nil /hpf	
Ova	Absent	
cysts	Absent	
veg. forms	Present	

..... End of Report

CHECKED BY

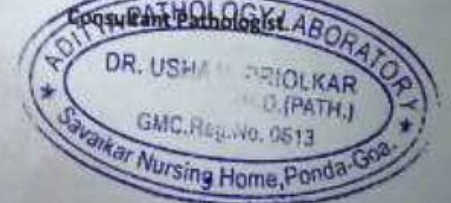LAB TECHNICIAN

Priolkar

DR. MRS. USHA V. PRIOLKAR

M.B.B.S., M.D.

Consultant Pathologist



The Hospital for perfect health



CID : 2308318757
Name : MS. POONAM KUMARI
Age / Gender : 39 Years / Female
Consulting Dr. : MEGHA SAVAIKAR
Reg. Location : Margao, South Goa

Use a QR Code Scanner Application To Scan the Code
Collected : 24-Mar-2023 / 13:51
Reported : 24-Mar-2023 / 15:42

THYROID FUNCTION TEST

PARAMETER	RESULTS	BIOLOGICAL REF RANGE	METHOD
Total T3, Serum	1.5	1.3-3.1 nmol/l	ECLIA
NOTE: The unbound fraction of total T3 concentrations, free triiodothyronine (FT3) is metabolically active hence, more useful than measuring total T3 as altered levels of total T3 occur due to changes in T3 binding proteins, especially TBG as in case of normal pregnancy and steroid therapy.			
Total T4, Serum	99.6	66-181 nmol/l	ECLIA
NOTE: T4 circulates in the blood as an equilibrium mixture of free and protein bound hormone. FT4 is a better indicator of thyroid hormone action than Total T4 because it is not affected by changes in Thyroxine Binding Globulin (TBG) or other Thyroxine Binding Proteins like in illness, drug intake or pregnancy.			
sensitiveTSH, Serum	<u>7.72</u>	0.35-5.5 microIU/ml First Trimester:0.1-2.5 Second Trimester:0.2-3.0 Third Trimester:0.3-3.0	ECLIA



CID : 2308318757
Name : MS. POONAM KUMARI
Age / Gender : 39 Years / Female
Consulting Dr. : MEGHA SAVAIKAR
Reg. Location : Margao, South Goa

Collected : 24-Mar-2023 / 13:51
Reported : 24-Mar-2023 / 15:42

Use a QR Code Scanner Application To Scan the Code

Interpretation:

A thyroid panel is used to evaluate thyroid function and/or help diagnose various thyroid disorders.

Clinical Significance:

- 1) TSH Values between high abnormal upto 15 microIU/ml should be correlated clinically or repeat the test with new sample as physiological factors can give falsely high TSH.
- 2) TSH values may be transiently altered because of non thyroidal illness like severe infections, liver disease, renal and heart severe burns, trauma and surgery etc.

TSH	FT4 / T4	FT3 / T3	Interpretation
High	Normal	Normal	Subclinical hypothyroidism, poor compliance with thyroxine, drugs like amiodarone, Recovery phase of non-thyroidal illness, TSH Resistance.
High	Low	Low	Hypothyroidism, Autoimmune thyroiditis, post radio iodine Rx, post thyroidectomy, Anti thyroid drugs, tyrosinase inhibitors & amiodarone, amyloid deposits in thyroid, thyroid tumors & congenital hypothyroidism.
Low	High	High	Hyperthyroidism, Graves disease, toxic multinodular goiter, toxic adenoma, excess iodine or thyroxine intake pregnancy related (hyperemesis gravidarum, hydatiform mole)
Low	Normal	Normal	Subclinical Hyperthyroidism, recent Rx for Hyperthyroidism, drugs like steroids & dopamine), Non thyroidal illness.
Low	Low	Low	Central Hypothyroidism, Non Thyroidal Illness, Recent Rx for Hyperthyroidism.
High	High	High	Interfering anti TPO antibodies, Drug interference: Amiodarone, Heparin, Beta Blockers, steroids & anti epileptics.

Diurnal Variation: TSH follows a diurnal rhythm and is at maximum between 2 am and 4 am , and is at a minimum between 6 pm and 10 pm. The variation is on the order of 50 to 200%. Biological variation: 19.7% (with in subject variation)

Reflex Tests: Anti thyroid Antibodies, USG Thyroid , TSH receptor Antibody, Thyroglobulin, Calcitonin

Limitations:

1. Samples should not be taken from patients receiving therapy with high biotin doses (i.e. >5 mg/day) until atleast 8 hours following the last biotin administration.
2. Patient samples may contain heterophilic antibodies that could react in immunoassays to give falsely elevated or depressed results. this assay is designed to minimize interference from heterophilic antibodies.

Reference:

1. O.koulouri et al. / Best Practice and Research clinical Endocrinology and Metabolism 27(2013)
2. Interpretation of the thyroid function tests, Dayan et al. THE LANCET . Vol 357
3. Tietz , Text Book of Clinical Chemistry and Molecular Biology -5th Edition
4. Biological Variation: From principles to Practice- Callum G Fraser (AACC Press)

*Sample processed at SUBURBANI DIAGNOSTICS (INDIA) PVT. LTD Goa Lab, Margao
*** End Of Report ***



[Signature]
Dr. VIJEETH NAIR
M.D. (PATH)
Pathologist

SAVAIKAR HOSPITAL & LAPAROSCOPY CENTRE

Warkhandem, Ponda, Goa 403 401

Hosp. Reg. No. T/0/412

Tel. No. 2312603, 2319202 OPD.: 2311031 Fax No. 2319870

website : www.savaikarhospital.com

email : drsavaikar@gmail.com



॥ अस्मिन्सुखं जनसंघात ॥

ECHOCARDIOGRAPHY REPORT

Name: Poonam Kumari 40Y/F

Date: 24th March - 2023

Referred by:

M Mode Measurements :

IVSd (cms) = 0.998	LVsD (cms) = 2.26
LVdD (cms) = 3.66	Aorta (cms) = 2.7
PWd (cms) = 0.998	LA (cms) = 3.1
EF (%) = 65%	RVD (cms) =

Doppler Data :

Mitral Valve :

E (m/s) = 0.83

A (m/s) = 0.72

Regurgitation : nil

Stenosis : nil

MVA -

Tricuspid Valve :

Regurgitation - nil

PASP = + RAP mmHg

Stenosis : Nil

Aortic Valve :

Peak velocity (m/s+) = 1.03

Gradient (mmHg): PG/MG = nil

Regurgitation : nil

Stenosis : nil

Pulmonary valve :

Peak velocity (m/s) 1.36

Gradient (mmHg): PG/MG = normal

Regurgitation : nil

Stenosis : Nil

Regional Wall Motion Abnormality (RWMA) : nil

FINAL IMPRESSION :

NORMAL SIZE ALL 4 CARDIAC CHAMBERS

VALVES NORMAL

NO RWMA, IAS/IVS INTACT,

NORMAL LV FUNCTION(EF= 65%)

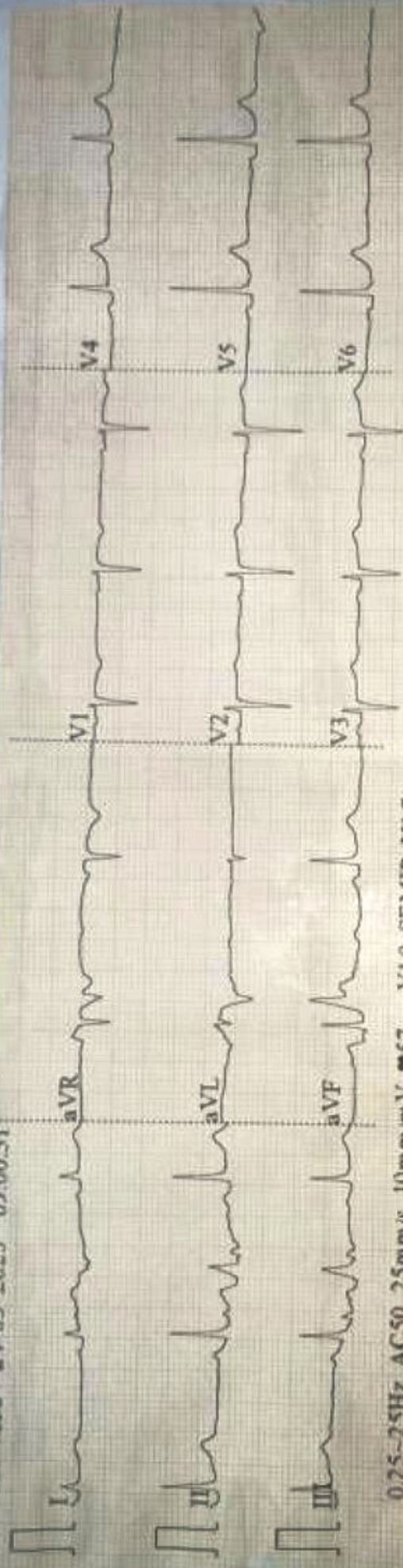
NO CLOT/VEGETATION/PE



Dr. Sabyasachi Mukhopadhyay
Consultant Cardiologist

The Hospital for perfect health

ID: 7858 24-03-2023 09:00:51



0.25-2.5Hz AC50 25mm/s 10mm/mV ♥57 V1.0 SEMIP V1.7


Ecg within normal limits -

Dr Lalana Bakhale

DR(Mrs.) LALANA BAKHALE
 Reg. No. GMC 0920
 Consulting Physician & Cardiologist
 Savaiker Nursing Home,
 Warkhandem, Ponda-Goa

Poonam Kumari 34/F
DATE - 24/3/23

ECG Within Normal Limits


Dr. (Mrs.) Lalitana V. Bakhale
M.D. (BOM), Reg. No. 5023
Consultant Physician
Ponda-Goa



NAME: POONAM KUMARI
REF BY: HEALTH CHECK UP
DATE: 24/03/2023

RADIOGRAPH OF THE CHEST-PA VIEW

The trachea is central
The lung fields are clear
Both CP angles are clear
Cardiothoracic ratio is within normal limits
The rib cage is normal
Both the diaphragm contours are normal

With warm regards.

Dr. RESHMA DALVI
M.D, D.N.B (RADIO-DIAGNOSIS)

Dr. Reshma Dalvi
MD, DNB (RADIO-DIAGNOSIS)
Reg. No. 0896

SAVAIKAR HOSPITAL & LAPAROSCOPY CENTRE



Warkhandem, Ponda, Goa 403 401
Hosp. Reg. No. T/0/412
Tel. No. 2312603, 2319202 OPD.: 2311031 Fax No. 2319870
website : www.savaikarhospital.com
email : drsavaikar@gmail.com

॥ अस्मिन् चिकित्सये ॥

Name: POONAM KUMARI 40/F

Date :24-03-2023

HEALTH CHECKUP

USG ABDOMEN & PELVIS

Liver: normal in size, with normal echotexture. Hepatic veins are normal. No focal mass lesion noted. The **Portal Vein** is normal.

There is no dilatation of intra-hepatic biliary radicals. The **CBD** is normal in caliber.

Gall bladder: contracted. No calculi. No wall thickening. No peri-cholecystic fluid.

Spleen: normal in size, with normal echotexture. No focal mass lesion.

Pancreas: normal in size and echotexture. No focal mass noted. The pancreatic duct is normal. No calculi / calcification. No peri-pancreatic collection.

Right kidney: measures 10.6 cm. The cortical echogenicity is normal. Cortico-medullary differentiation is maintained. No dilatation of pelvicalyceal system noted. No calculi. No focal lesion.

Left kidney: measures 10.2 cm. The cortical echogenicity is normal. Cortico-medullary differentiation is maintained. No dilatation of pelvicalyceal system noted. No calculi. No focal lesion.

Urinary bladder: adequately distended. No calculi. No focal mass. No wall thickening. No e/o internal echoes.

The **uterus** is anteverted.

The endometrial echo is central, well-defined. Endometrial thickness measures 5 mm.

Both the **ovaries** are normal in size and appearance. There is no adnexal mass.

The great vessels are normal.

No bowel wall thickening.

No intra-abdominal lymphadenopathy.

No free fluid in the abdominal cavity.

No basal pleural effusion.

No obvious mass lesion.

Impression:

No significant abnormality detected during present examination.



Dr. Sarvesh L. S. Dubhashi
Consulting Radiologist

Thanks for the reference

The Hospital for perfect health

SAVAIKAR HOSPITAL & LAPAROSCOPY CENTRE



Warkhandem, Ponda, Goa 403 401

Hosp. Reg. No. T/0/412

Tel. No. 2312603, 2319202 OPD.: 2311031 Fax No. 2319870

website : www.savaikarhospital.com

email : drsavaikar@gmail.com

॥ अरोगम् परमं वैदिकम् ॥

Name: POONAM KUMARI 40/F

Date :24-03-2023

HEALTH CHECKUP

SONOMAMMOGRAPHY-BOTH BREASTS

Right breast:

There is no solid / cystic lesion in any quadrant of the right breast.

There is no axillary lymphadenopathy.

Left breast:

There is no solid / cystic lesion in any quadrant of the left breast.

There is no axillary lymphadenopathy.

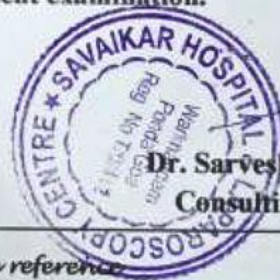Impression:

Right breast :

No significant abnormality detected during present examination.

Left breast :

No significant abnormality detected during present examination.



Dr. Sarvesh L. S. Dubhashi
Consulting Radiologist

Thanks for the reference

The Hospital for perfect health



SAVAIKAR HOSPITAL & LAPAROSCOPY CENTRE

Warkhandem, Ponda, Goa 403 401

Hosp. Reg. No. T/0/412

Tel. No. 2312603, 2319202 OPD.: 2311031 Fax No. 2319870

website : www.savaikarhospital.com

email : drsavaikar@gmail.com



॥ अस्मिन्मन्त्रे ॥

Date:- 24.03.2023

NAME:- Poonam kumari

AGE:- 39

SEX:- Female

COMPANY NAME :- _____

OPHTHALMIC EXAMINATION:

VISION	DISTANT		NEAR	
	RIGHT	LEFT	RIGHT	LEFT
VISUAL ACUITY				
WITH SPECTS				
WITHOUT SPECTS	6/6	6/6	M/6	M/6
COLOUR VISION	NORMAL			
SIGNS OF NIGHT BLINDNESS:- Yes <input type="radio"/> No <input checked="" type="radio"/>			PHORIAS :- Nil	

SIGNATURE OF THE EMPLOYEE



The Hospital for perfect health

Sawaikar Hospital & Laparoscopy Centre

Warkhandem, Ponda - Goa 403 401.

Hosp. Reg.No.: T/0/412

Dr. S. V. Sawaikar
M.B.B.S., M.D. (Delhi)
Obstetrician & Gynaecologist
Reg. No. 0834 GMC

Phone: Hosp.: (0832) 2312603

(0832) 2319202

Res.: (0832) 2314913

Timings: 10 a.m. to 12 30 p.m.

5 p.m. to 6.30 p.m.

EX. CONSULTANT

CHRISTIAN MEDICAL COLLEGE & HOSPITAL, VELLORE

WANLESS MISSION HOSPITAL MEDICAL COLLEGE, MIRAJ

AGE:- 40/F

Poonam Kumari

Date: 24.03.2023

wt - 48 kg

BP

• Married 15 yrs.

• Gr2 P2 L2 11⁺ 6⁺ N. det. 120/80

Menstrual history - Nil

L.M.P. → 13-3-23.

Cycles Normal.

2-3/3 body

Gr2 P1A Normal. P/S w/ CX healthy
Aish. healthy.

P/V. NS. w/ Adnexae
Normal

Gynaecological check up
Normal:

Dr. S. V. SAWAIKAR

M.B.B.S., M.D. (Delhi)

OBST & Gyn. Reg. No. 0834

Sawaikar Hospital & Laparoscopy Centre

Ponda-Goa 403 401



SAVAIKAR HOSPITAL & LAPAROSCOPY CENTRE

Warkhandem, Ponda, Goa 403 401

Hosp. Reg. No. T/0/412

Tel. No. 2312603, 2319202 OPD.: 2311031 Fax No. 2319870

website : www.savaikarhospital.com

email : drsavaikar@gmail.com



॥ सावित्री सवायकार ॥

Poonam Kumari

Exercise:- walking 1 hour

Water Intake:- 3 litres

Sleeping:- 7 hours.

Stress \times .

Age=40

Weight = 48

height:-152

● Early morning:- Almonds (5-6 nos) + Dates (2 nos) + 1 glass water

Breakfast:- Veg Poha \rightarrow 1 Bowl
OR

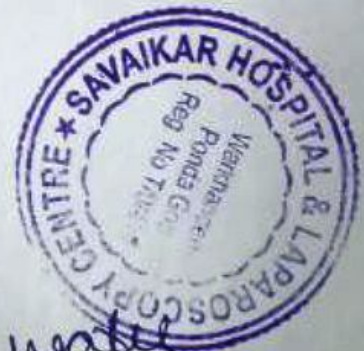Ragi Dosa \rightarrow 2 nos.
Chutney \rightarrow 1 tsp.

● Lunch:- Brown Rice \rightarrow 1 Bowl
Masoor Dal / Rajma \rightarrow 1 cup
Sprouts / Paneer /

paneer
Curd \rightarrow 1 cup
Salad \rightarrow 1 cup

5:00 pm:- ABC juice or lemon water

8:00 pm:- Veg Pulav OR Sprout salad / Kala chana
choat \rightarrow 1 Bowl.



The Hospital for perfect health

Savaikar Hospital Health Check Summary

Date :- 24.03.2023

Name :- Poonam Kumari

Age :- 40

Sex :- Female

Address :- Chimbhel

Cont. No. :- 7219629673

Height - 152

Weight - 48

Past History :- Nil.

Obstetric History :- Gr II - Para II,
FTSD.

Menstrual History :- 4-5 days, heavy flow,
20-25 days.

Personal History :-
✓ Appetite - good.
Sleep - ~~not~~ sleeps late.
Urine - normal.
Stool - normal.
Addictions - Nil.

Family History :-
Mother - asthma.
Father - healthy

On Examination :-

CVS :- H.S. normal. No murmur.

R/S :- Lung clear - B.S. normal

CNS :- No deficit

P/A :- soft - no tenderness

Liver / N.P. No mass
Spleen

Lab Investigations:-

HB 10.2 gm/dl
TSH 7.72
rest normal

Significant Findings:-

Resting ECG :- → normal

Ultrasound:- normal
mamograph

X-Ray:- normal

Summary:- Anaemia
TSH marginally high

Advice:-
+ Tab Ferrous D3 daily
- Tab Zentel HS
- Tab Eltroxin (25mg)

Repeat - HB after 2 mths
TFT

Dr. (Mrs.) Lalana Bakhale
M.B.B.S., M.D.
DR (Mrs.) LALANA BAKHALE
Reg. No. GMC 0920
Consulting Physician & Cardiologist
Savaiker Nursing Home,
Warkhandem, Ponda-Goa