

**Diwakar Diagnostic Centre**  
E-7/636, Arera Colony, Bhopal

906 / NIKHIL MADAVI / 30 Yrs / M / 0 Cms / 0 Kg Date: 10-Dec-2022 Refd By : BOB

**Report :**

TEST OBJECTIVE	: ROUTINE CHECK UP
RISK FACTOR	: MALE
ACTIVITY	: MODERATE ACTIVE
MEDICATION	: NONE
REASON FOR TERMINATION	: HEART RATE ACHIEVED
EXERCISE TOLERANCE	: GOOD
EXERCISE INDUCED ARRHYTHMIAS	: NO
HAEMODYNAMIC RESPONSE	: NORMAL
CHRONOTROPIC RESPONSE	: NORMAL
FINAL IMPRESSION	: STRESS TEST IS NEGATIVE FOR EXERCISE INDUCED ISCHAEMIC HEART DISEASE



**Report**

(GEM213180307)(R)Allengers







906 / NIKHIL MADAVI / 30 Yrs / M / 0 Cms / 0 Kg Date: 10-Dec-2022 Refd By : BOB

Stage	Time	Duration	Belt Speed (mph)	Elevation	METS	Rate	% THR Achieved	BP	RPP	PVC	Comments
Supine	00:16	0:01	00.0	00.0	01.0	82	43 %	120/80	098	00	
Standing	00:26	0:01	00.0	00.0	01.0	68	36 %	120/80	081	00	
HV	00:36	0:01	00.0	00.0	01.0	079	42 %	120/80	094	00	
Warm Up	00:46	0:01	01.0	00.0	01.0	072	38 %	120/80	086	00	
ExStart	00:51	0:06	01.7	10.0	01.1	076	40 %	120/80	091	00	
BRUCE Stage 1	03:51	3:00	01.7	10.0	04.7	129	68 %	130/88	167	00	
BRUCE Stage 2	06:51	3:00	02.5	12.0	07.1	160	84 %	140/90	224	00	
PeakEx	06:58	0:07	03.4	14.0	07.2	160	84 %	140/90	224	00	
Recovery	07:57	1:00	00.0	00.0	01.2	096	51 %	130/88	124	00	
Recovery	08:57	2:00	00.0	00.0	01.0	088	46 %	120/80	105	00	
Recovery	09:21	2:23	00.0	00.0	01.0	093	49 %	120/80	111	00	

**Findings :**

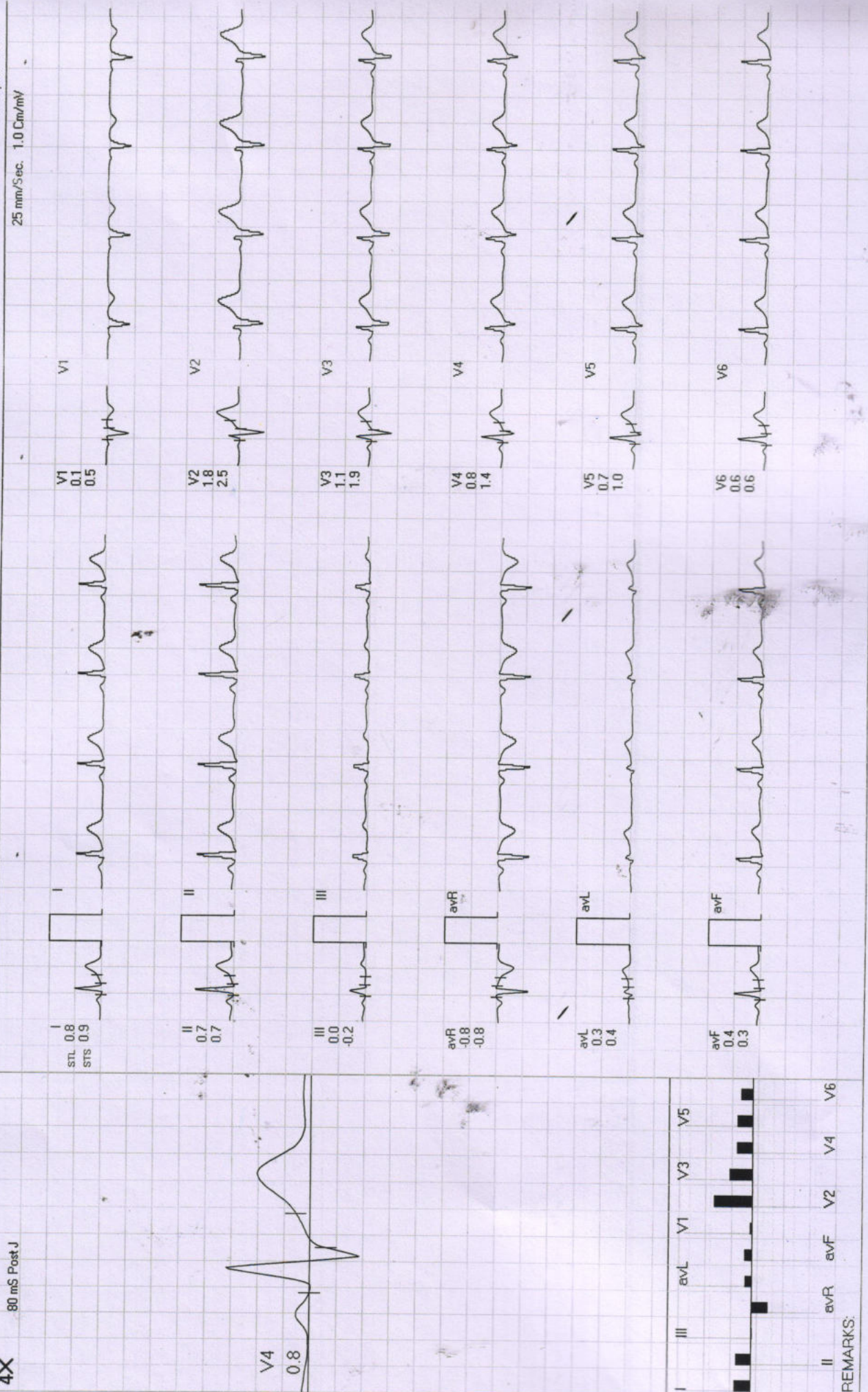
Exercise Time : 06:08  
 Max HR Attained : 160 bpm 84% of Target 190  
 Max BP Attained : (Sys) 140/90  
 Max WorkLoad Attained : 7.2 Fair response to induced stress  
 Test End Reasons : Heart Rate Achieved



Date: 10-Dec-2022 02:44:10 PM METS: 1.0/ 82 bpm 43% of THR BP: 120/80 mmHg Raw ECG/ BLC On/ Notch On/ HF 0.05 Hz/LF 20 Hz

ExTime: 00:15 0.0 mph, 0.0%

4X 80 ms Post J



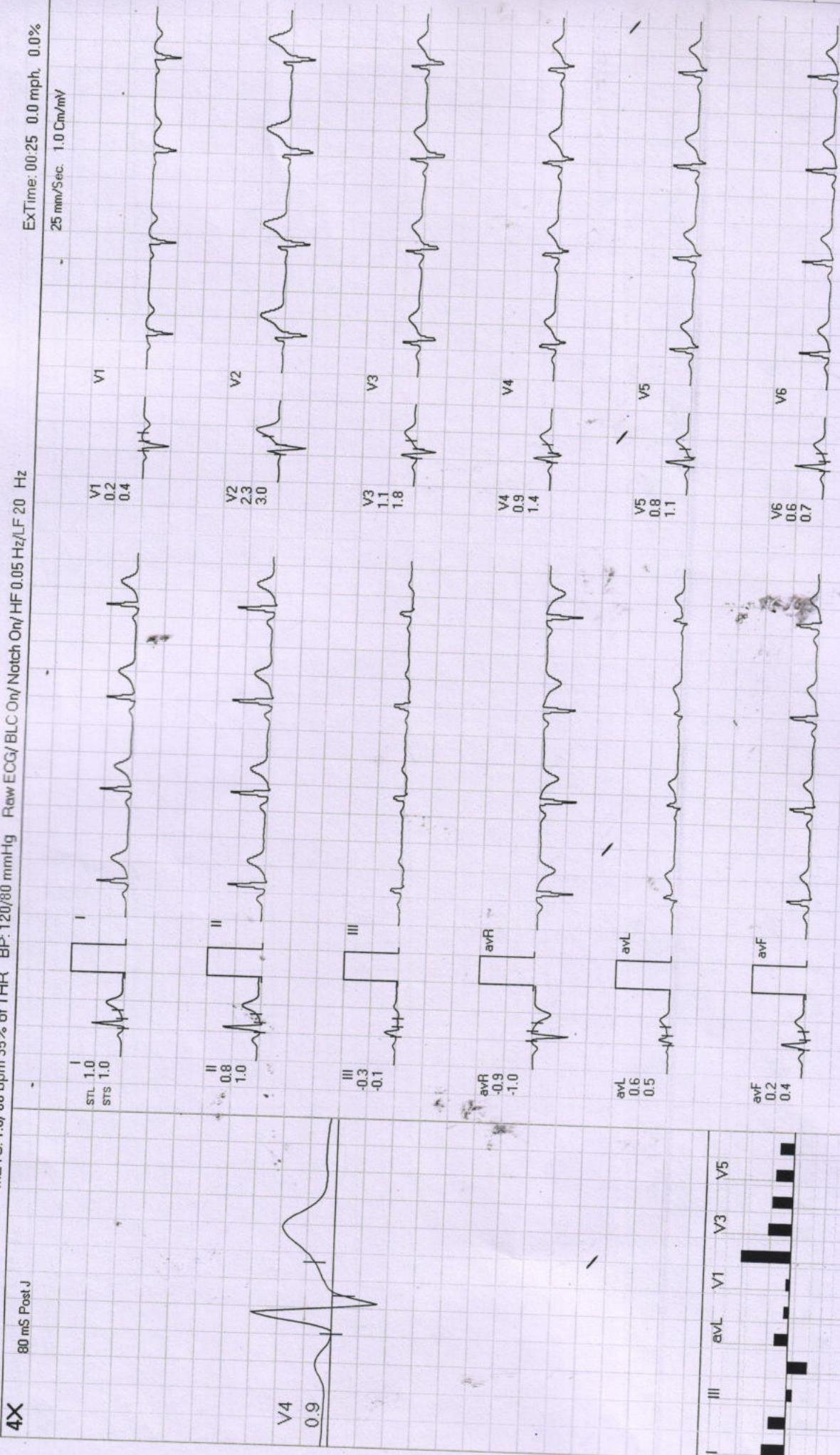
REMARKS:





Date: 10-Dec-2022 02:44:10 PM METS: 1.0/ 68 bpm 35% of THR BP: 120/80 mmHg Raw ECG/ BLC Ony/ Notch Ony/ HF 0.05 Hz/ LF 20 Hz

ExTime: 00:25 0.0 mph, 0.0%



REMARKS:





HV

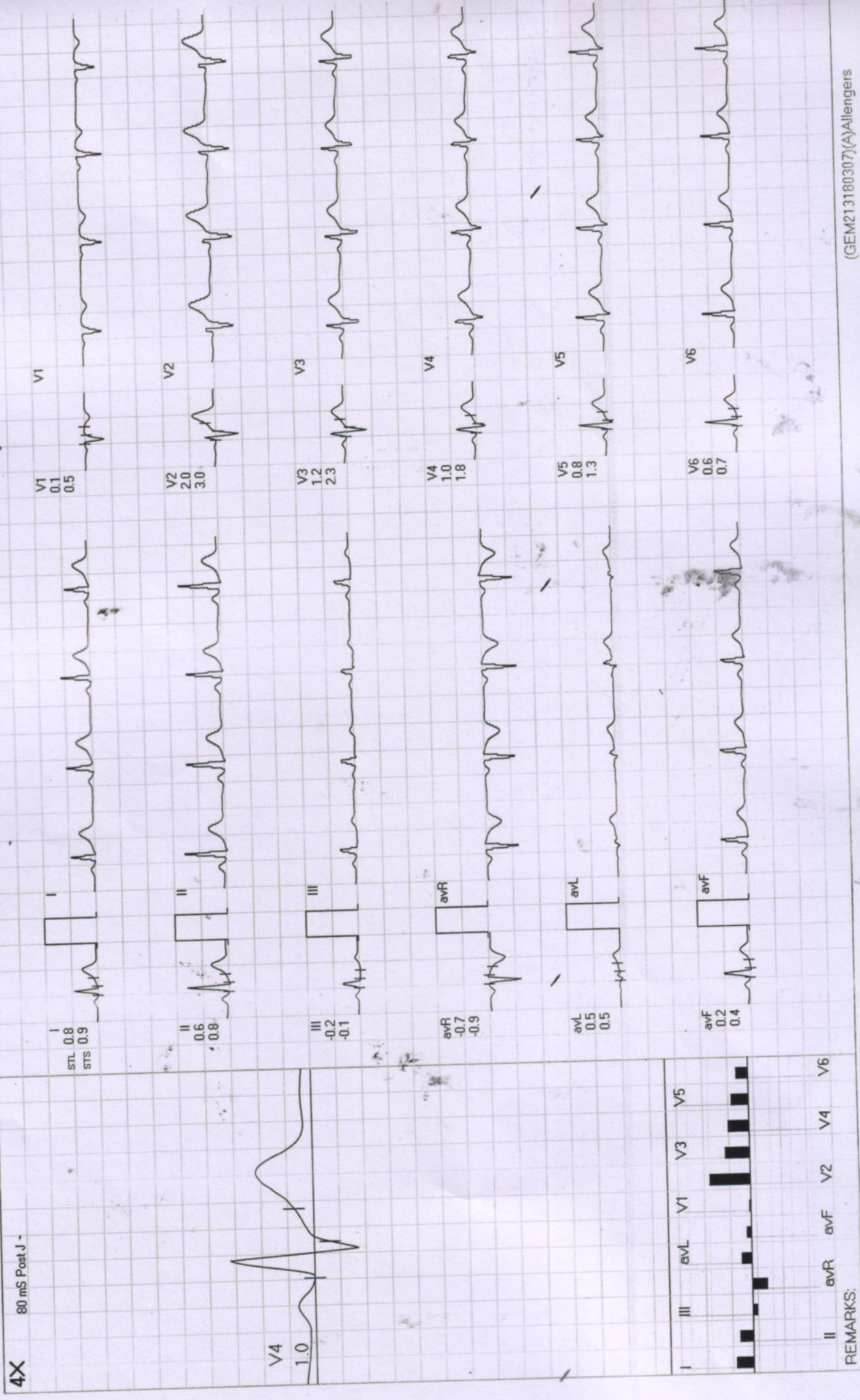
# Diwakar Diagnostic Centre

906 / NIKHIL MADAVI / 30 Yrs / M

ExTime: 00:35 0.0 mph, 0.0%

25 mm/Sec. 1.0 Cm/mV

Date: 10-Dec-2022 02:44:10 PM METS: 1.0/ 79 bpm 41% of THR BP: 120/80 mmHg Raw ECG/BLC On/ Natch On/ HF 0.05 Hz/LF 20 Hz



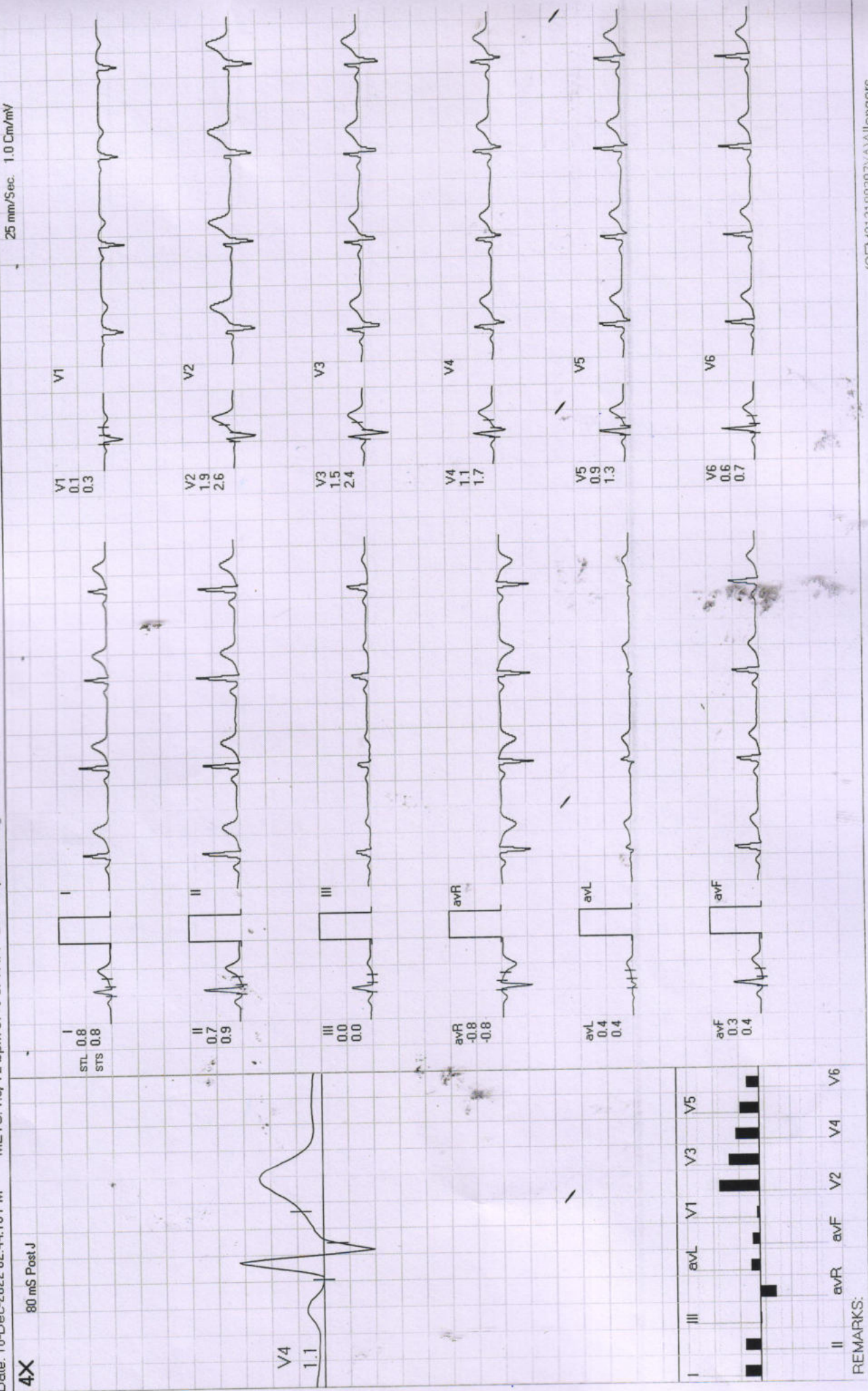
REMARKS:





ExTime: 00:45 1.0 mph, 0.0%

Date: 10-Dec-2022 02:44:10 PM METS: 1.0/72 bpm 37% of THR BP: 120/80 mmHg Raw ECG/BLC On/ Notch On/ HF 0.05 Hz/LF 20 Hz

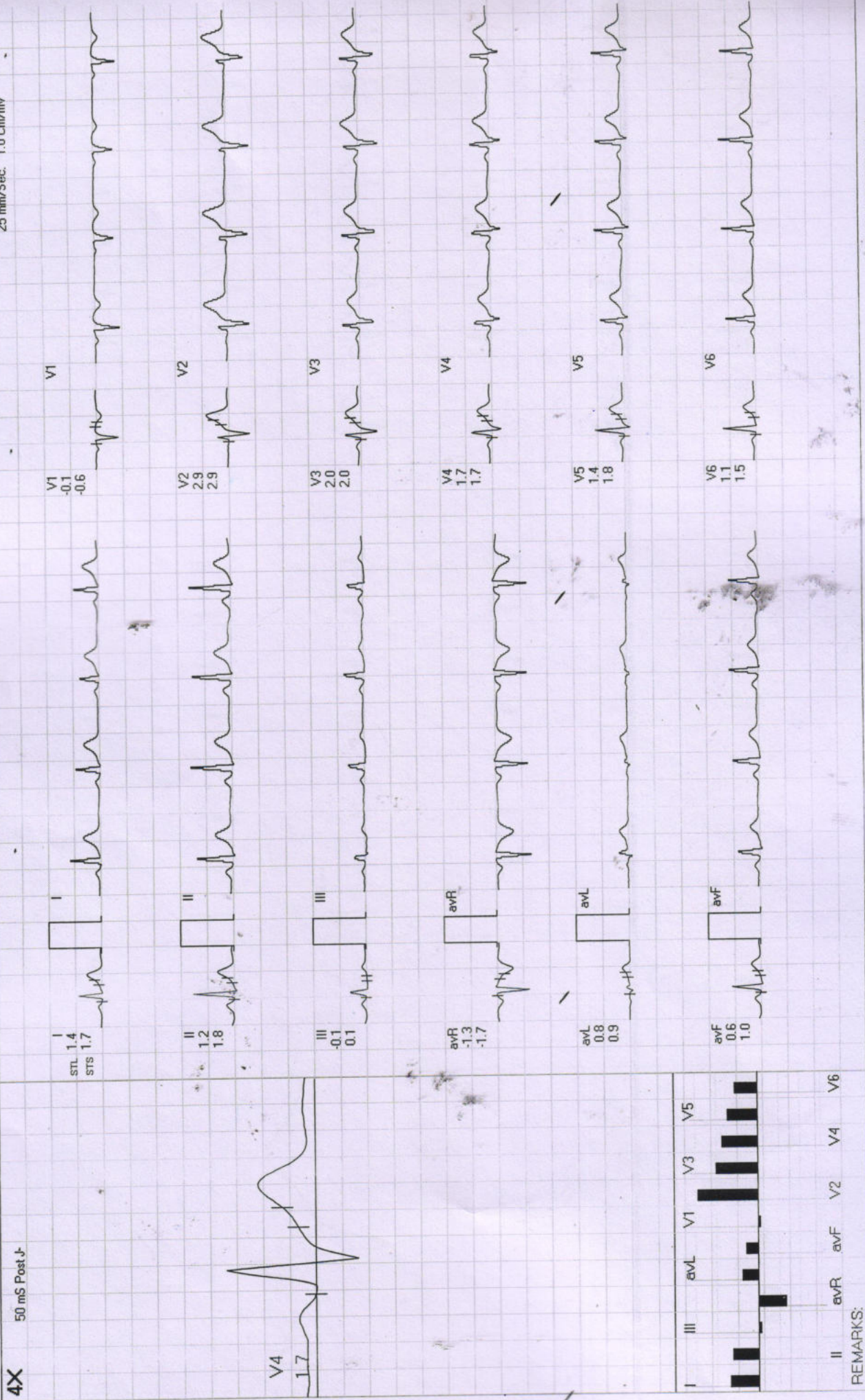


REMARKS:





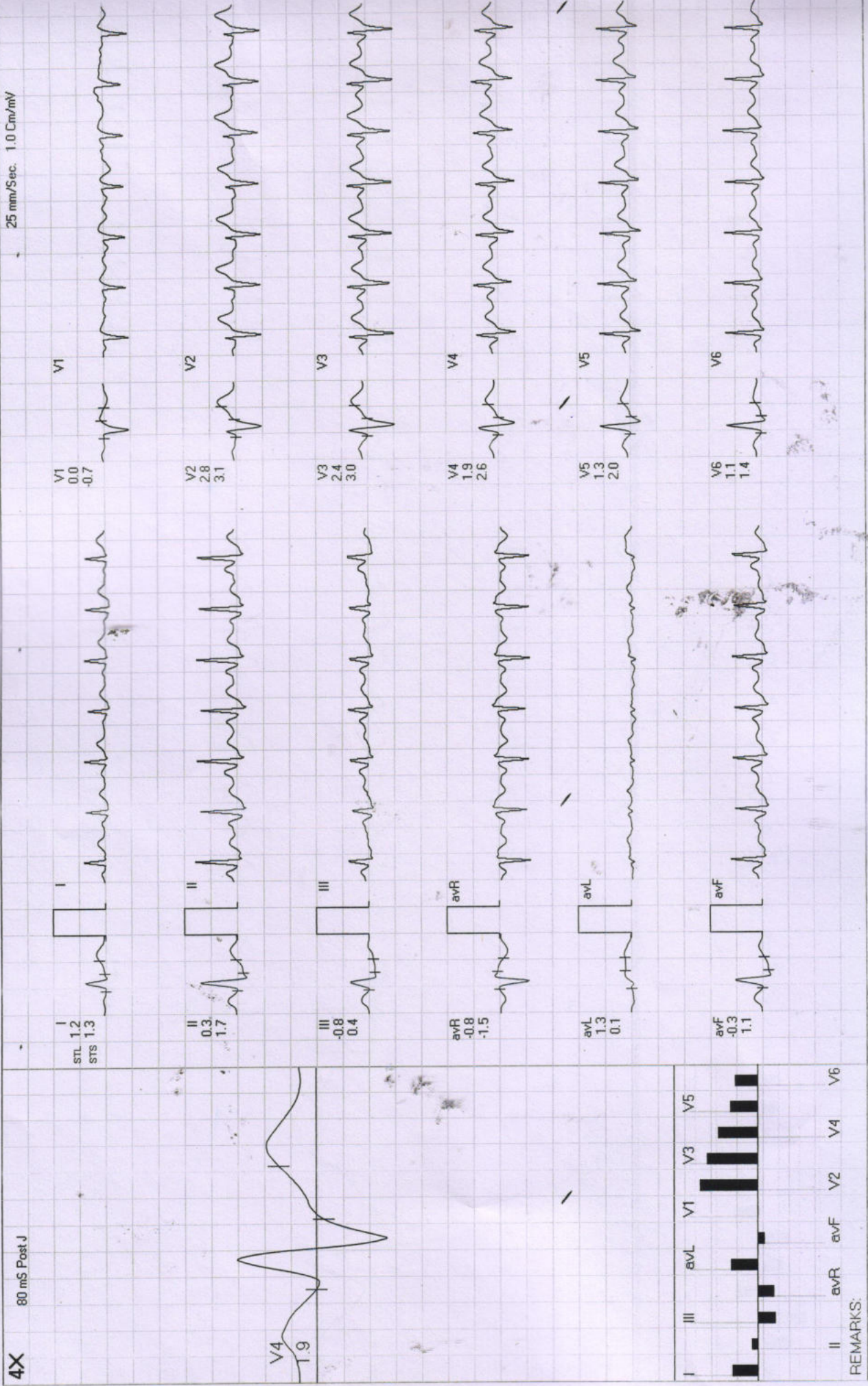
ExStrt







4X 80 mS Post J



REMARKS:



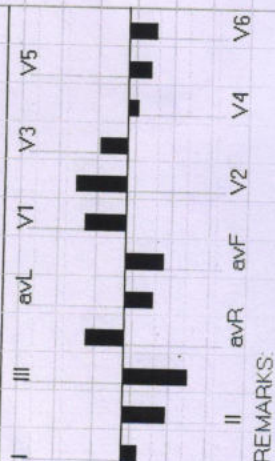

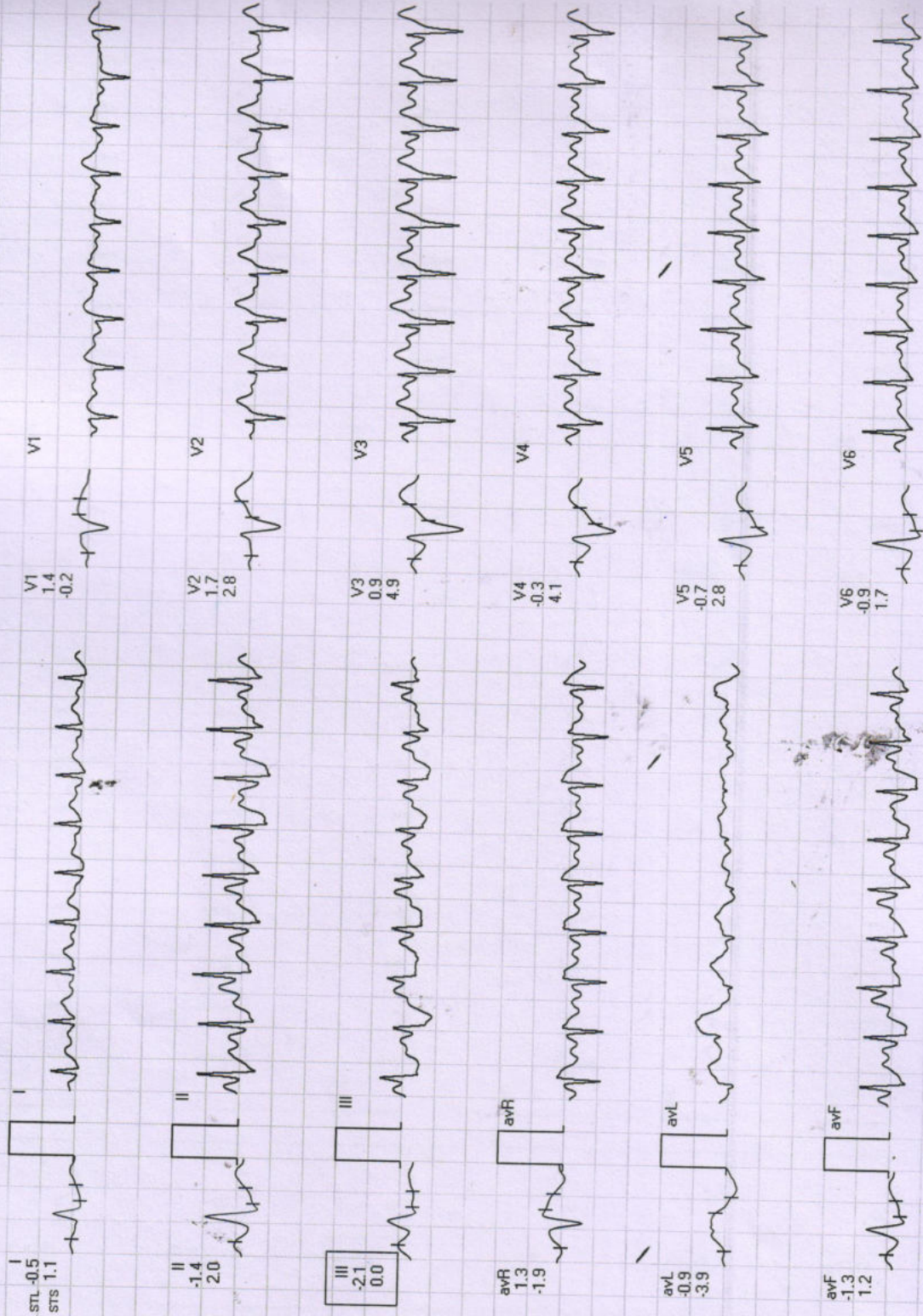
Date: 10-Dec-2022 02:44:10 PM

METS: 7.1 / 160 bpm 84% of THR BP: 140/90 mmHg Raw ECG/BLC On/ Natch On/ HF 0.05 Hz/LF 20 Hz

4X

60 ms Post J

ExTime: 06:00 2.5 mph, 12.0%  
25 mm/Sec. 1.0 Cm/mV



REMARKS:



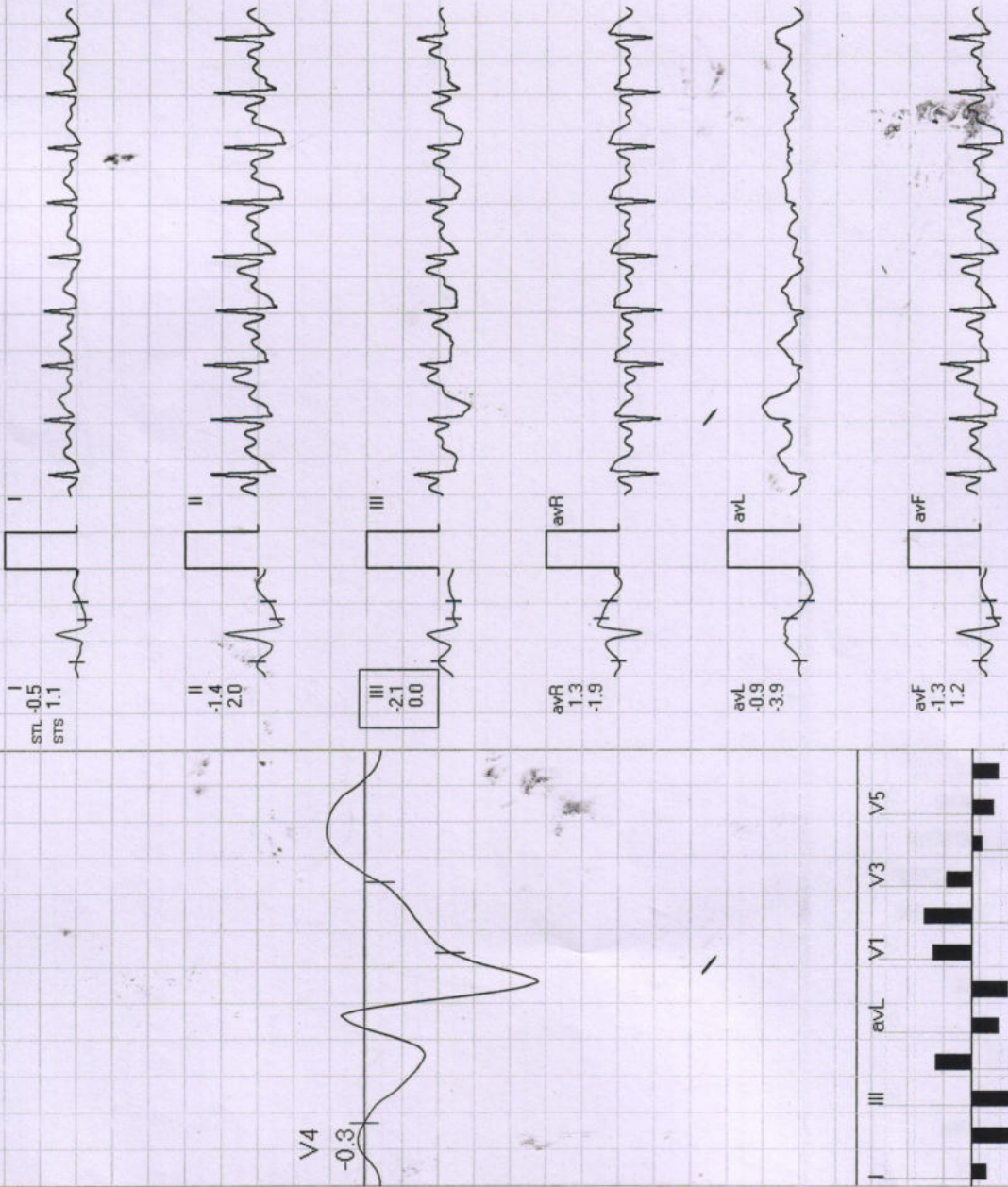
Date: 10-Dec-2022 02:44:10 PM METS: 7.2/160 bpm 84% of THR BP: 140/90 mmHg Raw ECG/BLC On/ Notch On/ HF 0.05 Hz/LF 20 Hz

ExTime: 06:07 3.4 mph, 14.0%

4X

60 ms Post J

25 mm/Sec. 1.0 Cm/mV



I  
STL -0.5  
STS 1.1

II  
-1.4  
2.0

III  
-2.1  
0.0

avR  
1.3  
-1.9

avL  
-0.9  
-3.9

avF  
-1.3  
1.2

V1  
1.4  
-0.2

V2  
1.7  
2.8

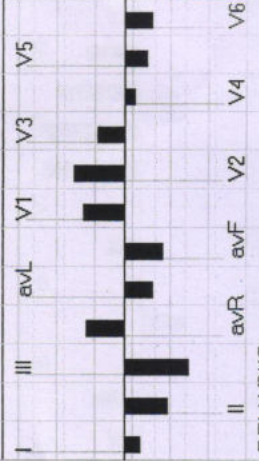
V3  
0.9  
4.9

V4  
-0.3  
4.1

V5  
-0.7  
2.8

V6  
-0.9  
1.7

V4  
-0.3



REMARKS:





Recovery : ( 01:00 )

# Diwakar Diagnostic Centre

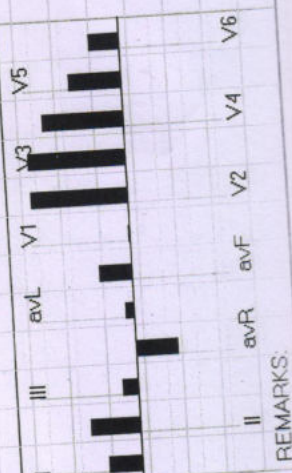

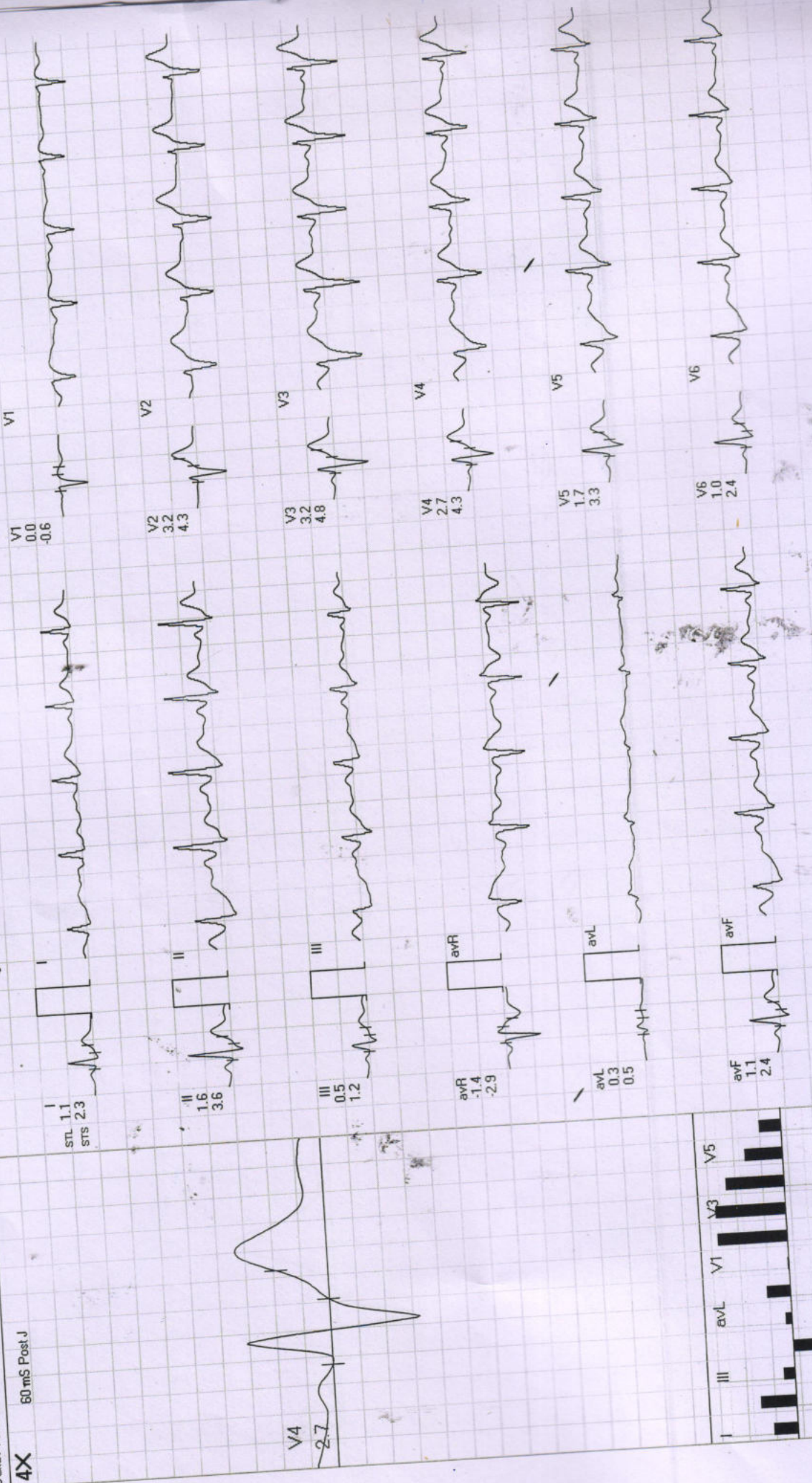
906 / NIKHIL MADAVI / 30 Yrs / M

ExTime: 06:07 0.0 mph. 0.0%

25 mm/Sec. 1.0 Cm/mV

Date: 10-Dec-2022 02:44:10 PM METS: 1.1/96 bpm 50% of THR BP: 130/88 mmHg Raw ECG/BLC On/ Notch On/ HF 0.05 Hz/LF 20 Hz

4X 60 mS Post J



REMARKS:





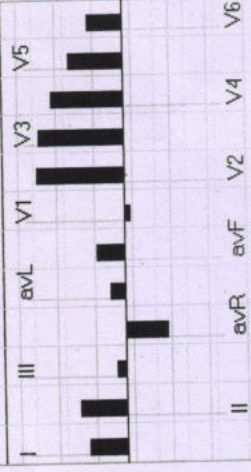
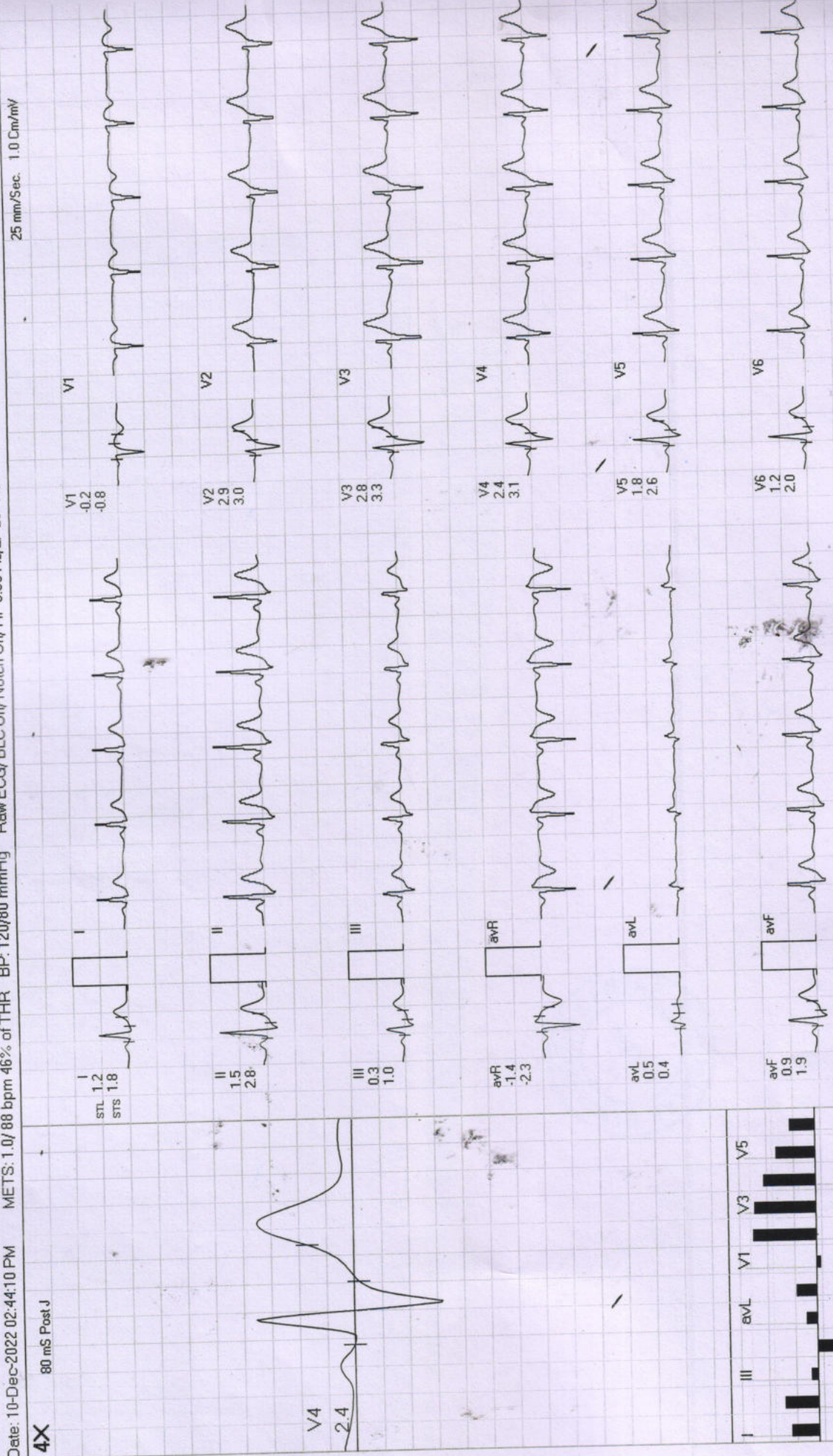
Recovery : ( 02:00 )

Diwakar Diagnostic Centre

906 / NIKHIL MADAVI / 30 Yrs / M

ExtTime: 06:07 0.0 mph 0.0%

Date: 10-Dec-2022 02:44:10 PM METS: 1.0/ 88 bpm 46% of THR BP: 120/80 mmHg Raw ECG/BLC On/ Notch On/ HF 0.05 Hz/LF 20 Hz

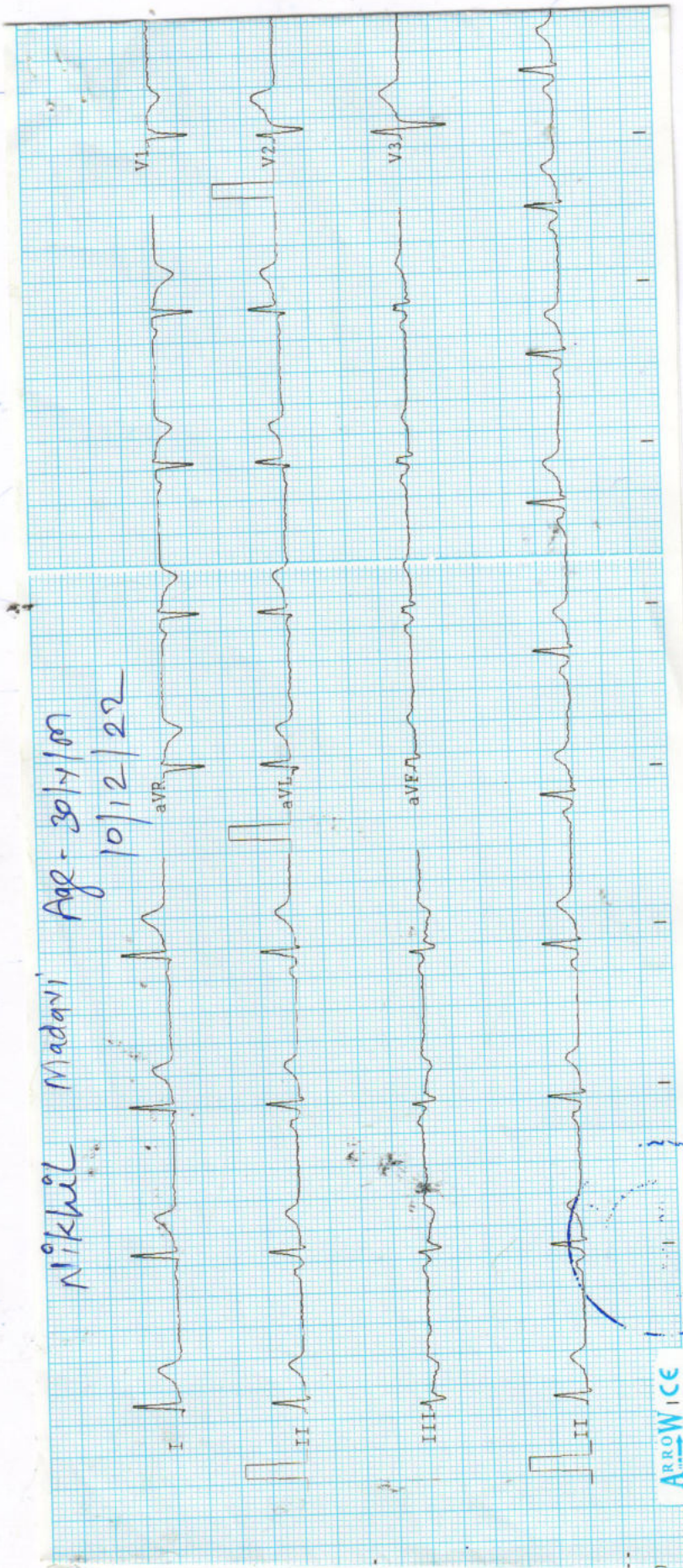


REMARKS:



Nikhil Madani Age - 30/4/08

10/12/22

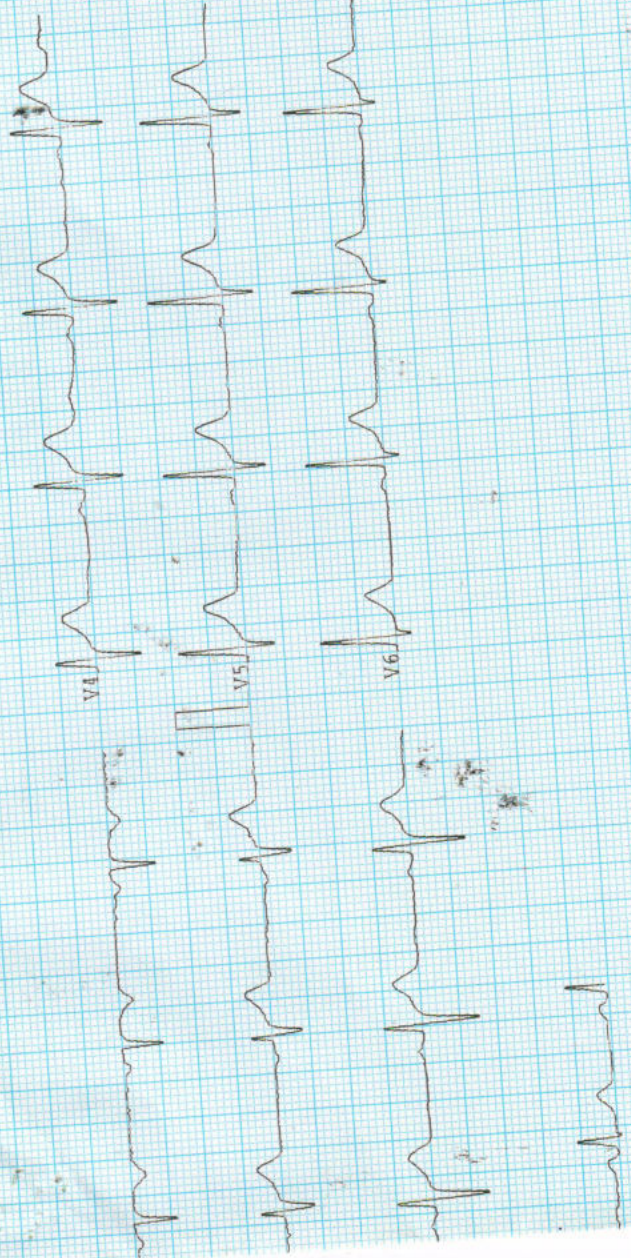



ARROWICE



Observations :-

HR :- 65 bpm  
R-R :- 910 ms  
P-R :- 0.56 ms  
QRS :- 70 ms  
QT/QTc :- 325/340 ms  
P Axis :- 57 °  
R Axis :- 60 °  
T Axis :- 54 °



Remarks :-

Unconfirmed report

2.09

ARROWI CE





# डॉ. सविता क्लिनिक

34, भूतल, मोहिनी अदिति आर्केड, शाहपुरा मस्जिद के पास  
भरत नगर रोड, ई-7/194, अरेरा कॉलोनी, भोपाल - 462038

Mob. : 8989649694, 9516333619

Clinic Registration : CL/5392/Jun/2017

PNDT Registration : MPPCPNDT/BPL/2017/206



Name : Mrs. Nikhil. Madavi Age.....YRS./F

R/B. Health check up. No. .... Date 10/12/2022.

## WHOLE ABDOMEN ULTRASOUND REPORT

### Indication :

**Liver** appears normal / ~~enlarged~~ in size and shape with smooth in outline. Normal / ~~increased~~ perenchymal echogenicity is noted. No E/O focal lesion / IHBR dilatation is seen. Hepatic veins and portal veins appear normal.

No E/O Subdiaphragmatic Collection.

**Gall Bladder** is physiologically well distended / ~~collapsed~~. No E/O echogenic foci in GB lumen. GB wall is normal / ~~thickened~~. No E/O pericholecystic collection. common duct reveals normal course and caliber.

**Pancreas** appear normal in size, shape and echo texture with smooth contour. No peripancreatic pathology seen. (Not seen due to gases)

**Spleen** is normal / ~~enlarged~~ in size and normal in echo texture.

IVC and aorta appear to be normal.

No evidence of lymphadenopathy is noted.

No evidence of free fluid is noted.

**Right Kidney** is normal in size, shape and position. Corticomedullary defferentiation (CMD) is well maintained. Normal cortical thickness is noted. No E/O hydronephrosis or calculus is noted.

PTO

Dr. P. Savita, MD  
MBBS, MD (O&G) Reg. No. 9971  
स्त्री रोग विशेषज्ञ

Dr. Jayant Yadav, MD  
MBBS, MD (Radiologist) Reg. No. 4166  
रेडियोलॉजिस्ट



**Left Kidney** is normal is size, shape and position. CMD is well maintained. Normal cortical thickness is noted. No E/O hydronephrosis or calculus is noted.

**Urinary Bladder** is well distended (physiological) / collapsed. Its contents are echo free. No E/O bladder wall thickening is noted. Post-void residue is insignificant.

**Prostate** is normal in size, shape and echo texture with smooth outline. No E/O focal lesion is noted.

**Uterus** is ante/retro verted and normal in size, shape and echotexture with smooth outline. No E/O focal lesion is noted, endometrial echo appear normal. Cervical and vaginal shadows appear normal.

**Right Ovary** appears Enlarged / Normal in size, shape and echo texture.

**Left Ovary** appears Enlarged / Normal in size, shape and echo texture.

Impression : Normal study.

Advised clinical Correlation.







Pt Name :- Mr. Nikhil Madavi  
 Age :- 30/M  
 Lab. No. :- 08  
 Date :- 10/12/2022

### EXAMINATION OF BLOOD

TEST	RESULT	NORMAL VALUE
Haemoglobin	13.3gms%	
Red Cell count	5.27	Female 12-16gms%, Male 14-18gms%
Platelet Count	2.86	4.5-5.6 million /cumm
Leucocytes per.cu.mm	7300/cumm	1.5-5.6 Lac/cumm
Neutrophils	51%	5000-11000/cumm
Lymphocytes	39%	50-70%
Eosinophils	05%	20-40%
Monocytes	05%	0-7%
PCV	42.5	2-8%
MCV	80.8	37-47
MCH	25.2	76-96
MCHC	31.2	27-32
ESR	05	31-35
Blood Group	"B" Positive	Male 0-9, Female 0-20mm/FHR
Total Serum Cholesterol	198.0	By slide method
Serum Triglyceride	165.0	100-250 mg%
Serum Cholesterol HDL	47.0	Up to 150 mg%
Serum Cholesterol LDL	118.0	Up to 65 mg%
VLDL	33.0	Up to 125 mg%
S.Bilirubin(Total)	0.99	Up to 30 mg%
Direct	0.59	0.2-1.0mg/dl
Indirect	0.40	0.0-0.25mg/dl
SGOT	30.0	5-35U/L
SGPT	36.0	8-40U/L
Alk Phosphatase	11.1	3-13 KA units
Albumin	6.9	6.0-8.0mg%
Globulin	4.9	3.7-5.3mg%
Blood Urea	2.0	1.5 to 3.5 mg%
S.Creatine	19.0	Up to 40 mg%
S.Uric Acid	0.97	0.5-1.4mg/dl
GGTP	6.9	3.5-7.5mg%
Fasting Blood Sugar	15.0	5-35 UL/dl
PP Blood Sugar	99.0	Up to 110 mg%
Glycosylated Hemoglobin	126.0	Up to 125 mg%
HBAtc	5.9	Below - 6.0 % -Non Diabetic control
		6-7 % -Excellent control
		Above - 8 % -Poor control
Thyrod Stimulating Hormone(TSH)	3.0	0.27-4.2

All test have technical limitation. Collaborative clinic pathological interpretation is mandatory. In case of disparity test may be repeated immediately. Typographical mistakes should be get correct instantly. This report is not valid for medico legal purpose

Dr. B. M. Agarwal  
 MBBS, DCP  
 Consultant Pathologist







Pathologist

Dr. B. M. Agarwal  
MBBS, DCP  
Consultant Pathologist

A. PHYSICAL EXAMINATION	
1. Colour	Pale Yellow
2. Appearance	Clear
3. Specific Gravity	Q.N.S.
B. CHEMICAL EXAMINATION	
1. Reaction	Acidic
2. Albumin	Nil
3. Sugar	Nil
4. Bile Salts	Absent
C. MICROSCOPIC EXAMINATION	
Pus Cells	2-3/HPF
R.B.C.	Nil
Epithelial Cell	1-2/HPF
Cast	Nil
Crystals(Cal.Oxa)	Nil
Bacteria	Nil
Amorphous	Nil
T. Vaginatis	Nil

### URINE ANALYSIS

Pt Name :- Mr. Nikhil Madavi  
 Age :- 30/M  
 Lab. No. :- 08  
 Date :- 10/12/2022



**दिवाकर डायग्नोस्टिक सेंटर**  
 E-7/636, पंजाब नगर बँक के पास, मंग रोड, अरुण कॉलोनी श्यामल (म.प.)  
 फोन: 0755-2465288, 0755-3520545 मो: 9826340190