

18/03/2023

Sushila Kumari | 46 years | Female

Oral Examination done.

Adv.

Composite Restoration w/it

38 and 48.

  
The Signature  
ADVANCED SUPER SPECIALITY  
H O S P I T A L  
18/3/2023

GST NO : 06AAICP8687M1ZH

Prescription

PAN NO : AAICP8687M


UHID : 25891	Date&Time : 18/03/2023 8.51 AM
Name : Mrs. SUSHILA KUMARI	Sex : Female
Doctor Name : Dr. CMO (CMO)	Age : 47Years 12Days
Address : H.NO 471 SEC 19 REWARI,Gurgaon,Gurgaon,Haryana	Mobile No : 9138362857
	Organisation : MEDIWHEEL

B.P	H.R	R.R	SPO2	Temp.	Height	Weight
138/85	87b/m	20b/m	96 %	98-6f		

mmHg

8bs. 96 mg/ml



Created By Chanchal1697	Create Date & Time 18/03/2023 8.51 AM	( Authorised Signatory )
Printed By CHANCHAL1697	Print Date & Time 18/03/2023 8.51 AM	 25891

18/3/23

Sushita kumar 42y/A.

Routine eye check up.

Vm (Distance)  $\left\{ \begin{array}{l} 6/6 \\ 6/0 \end{array} \right.$

Near Vm (+2.0DS) - N6 (OV)

Colour V - W M

Ant seg - NAD

Ado  
- reading glass no given  
- Annual eye check up.



Consultant  
Department of Ophthalmology  
SIGNATURE HOSPITAL  
Gurgaon

(This is only professional opinion and not the diagnosis. Please correlate clinically)

Sector 37-D, BPTP, Dwarka Express Way, Gurugram, Hry.,

Ph.: 0124-6034444, 6262828213, E-mail : signaturehospital@gmail.com, Web.: www.thesignaturehealthcare.com

PARK GROUP OF HOSPITAL : ★ West Delhi ★ South Delhi ★ Gurugram ★ Faridabad ★ Panipat ★ Karnal

13/3/23 - Mrs. Sushila Kumari  
 - 47y/F

2 FND <math>\begin{matrix} \text{♀} \\ \text{♀} \end{matrix}> = \begin{matrix} 20 \\ 25 \end{matrix} \text{y} \text{ } \textcircled{\text{C}} \\
 \text{Pt } 40 \text{ Left Breast Pain} \\
 \text{amp - H/O Lap Hysterectomy (TLH) x Syrs back} \\
 \text{PHFH - NAD}

O/E :-

- w/ah Breasts

(N) - NO lump felt  
 - B/L Breast Nipple

Soft non tender

- Vaginal vault well suspended  
 - Vaginal discharge

- Adv. s. Prolactin, H  
 - Lap smear

can't be H/O Hy

- t. Zincon  
 - t. Supreca

- Sono



**Dr. Manisha Singh**  
 Consultant Gynae Endoscopic Surgeon and Infertility Specialist  
 MBBS (MU), MS OBGY, F.MAS, D.MAS, FRM, CCGDM,  
 Advanced Dip in ART and Reproductive Endocrinology (Germany)  
 Certificate course in Advanced Ultrasound Obstetrics and Doppler  
 DMC Reg. No. 102065

(This is only professional opinion and not the diagnosis. Please correlate clinically)

Sector 37-D, BPTP, Dwarka Express Way, Gurugram, Hry.,

Ph.: 0124-6034444, 6262828213, E-mail : signaturehospital@gmail.com, Web.: www.thesignaturehealth  
**PARK GROUP OF HOSPITAL** : ★ West Delhi ★ South Delhi ★ Gurugram ★ Faridabad ★ Panipa

Patient Name : Mrs. SUSHILA KUMARI      UHID : 25891  
Age / Gender : 47 Years 0 Months 12Days / Female      IPNO :  
Referred By : Dr. CMO      Bill Date : 18/03/2023  
Req.No : 23268939      Reporting Date : 18/03/2023  
Sample ID : 2312218  
Patient Type : OPD  
Bed No :

**HEMATOLOGY**

**Complete Blood Count -CBC(HB\TLC\PCV\RBC\Platelet)**

TEST NAME TEST METHOD	RESULT	UNITS	BIOLOGICAL	
			REFERENCE INTERVAL	SPECIMEN TYPE
Hemoglobin (Hb) (Colorimetry)	13.4	gm/dl	11.5 - 15.0	WHOLE BLOOD
TLC (Electrical Impedence)	6130	cell/cumm	4500 - 11000	EDTA WHOLE
<b>DIFFERENTIAL COUNT</b>				
Neutrophils (Flow Cytometry)	68	%	40 - 75	EDTA WHOLE
Lymphocytes (Flow Cytometry)	23	%	20 - 45	EDTA WHOLE
Monocytes (Flow Cytometry)	05	%	1 - 10	EDTA WHOLE
Eosinophil (Flow Cytometry)	04	%	1 - 6	EDTA WHOLE
Basophil	00	%	0 - 1	
RBC (Electrical Impedence)	4.5	millions/cumm	4.2 - 5.4	EDTA WHOLE

-\*\*\*\* End of Report \*\*\*\*-

*This is Provisional Report*



Lab Technician      Dr.NishaTiwari  
(MD.Microbiology)

Dr. Neha Gupta  
MBBS,MD(Pathology)  
(Consultant Pathologist)

  
Dr. Shreya Pradhan  
MBBS,MD(Microbiology)  
(Consultant Microbiologist)

(This is only professional opinion and not the diagnosis. Please correlate clinically)

Sector 37-D, BPTP, Dwarka Express Way, Gurugram, Hry.,

Ph.: 0124-6034444, 6262828213, E-mail : signaturehospital@gmail.com, Web.: www.thesignaturehealthcare.com

**PARK GROUP OF HOSPITAL** : ★ West Delhi ★ South Delhi ★ Gurugram ★ Faridabad ★ Panipat ★ Karn

Patient Name : Mrs. SUSHILA KUMARI	UHID : 25891
Age / Gender : 47 Years 0 Months 12Days / Female	IPNO :
Referred By : Dr. CMO	Bill Date : 18/03/2023
Req.No : 23268939	Reporting Date : 18/03/2023
Sample ID : 2312218	
Patient Type : OPD	
Bed No :	

**HEMATOLOGY**

PCV (Electrical Impedence Calculation)	42.0	%	36 - 46	EDTA WHOLE
MCV (Electrical Impedence Calculation)	93.1	fl	76 - 96	EDTA WHOLE
MCH (Electrical Impedence Calculation)	29.7	pg	27 - 34	EDTA WHOLE
MCHC (Electrical Impedence Calculation)	31.9	gm/dl	30 - 36	EDTA WHOLE
RDW	13.3	%	11 - 16	
PLATELETE COUNT (Electrical Impedence)	264	1000/microLit	150 - 450	EDTA WHOLE

-\*\*\*\* End of Report \*\*\*\*

***This is Provisional Report***

Lab Technician                      Dr.NishaTiwari  
(MD.Microbiology)

Dr. Neha Gupta  
MBBS,MD(Pathology)  
(Consultant Pathologist)



Dr. Shreya Pradhan  
MBBS,MD(Microbiology)  
(Consultant Microbiologist)

(This is only professional opinion and not the diagnosis. Please correlate clinically)

Sector 37-D, BPTP, Dwarka Express Way, Gurugram, Hry.,

Ph.: 0124-6034444, 6262828213, E-mail : signaturehospital@gmail.com, Web.: www.thesignaturehealthcare.co

**PARK GROUP OF HOSPITAL : ★ West Delhi ★ South Delhi ★ Gurugram ★ Faridabad ★ Panipat ★ Karn**

Patient Name : Mrs. SUSHILA KUMARI	UHID : 25891
Age / Gender : 47 Years 0 Months 12Days / Female	IPNO :
Referred By : Dr. CMO	Bill Date : 18/03/2023
Req.No : 23268939	Reporting Date : 18/03/2023
Sample ID : 2312218	
Patient Type : OPD	
Bed No :	

**BIOCHEMISTRY**

**Blood Sugar Fasting**

TEST NAME	RESULT	UNITS	BIOLOGICAL REFERENCE INTERVAL	SPECIMEN TYPE
TEST METHOD				
BLOOD SUGAR FASTING (God- Trinders)	95	mg/dl	75 - 115	Flouride Plasma

Increased In:

- Diabetes Mellitus
- Stress ( e.g, emotion, burns, shock, anesthesia)
- Acute Pancreatitis
- Chronic Pancreatitis
- Wernicke encephalopathy ( Vitamin B1 deficiency)
- Effect of drugs (e.g. corticosterogens, alcohol, phenytoin, thiazides)

Decreased in :

- Pancreatitis disorders
- Extrapancreatic tumors
- Endocrine disorders
- Malnutrition
- Hypothalamic lesions
- Alcoholism
- Endocrine Disorders

-\*\*\*\* End of Report \*\*\*\*-

***This is Provisional Report***



Lab Technician	Dr.NishaTiwari (MD.Microbiology)	Dr. Neha Gupta MBBS,MD(Pathology) (Consultant Pathologist)	Dr. Shreya Pradhan MBBS,MD(Microbiology) (Consultant Microbiologist)
----------------	-------------------------------------	--	--

(This is only professional opinion and not the diagnosis. Please correlate clinically)

Sector 37-D, BPTP, Dwarka Express Way, Gurugram, Hry.,

Ph.: 0124-6034444, 6262828213, E-mail : signaturehospital@gmail.com, Web.: www.thesignaturehealthcare.com

**PARK GROUP OF HOSPITAL : ★ West Delhi ★ South Delhi ★ Gurugram ★ Faridabad ★ Panipat ★ Karnal**

Patient Name : Mrs. SUSHILA KUMARI	UHID : 25891
Age / Gender : 47 Years 0 Months 12Days / Female	IPNO :
Referred By : Dr. CMO	Bill Date : 18/03/2023
Req.No : 23268939	Reporting Date : 18/03/2023
Sample ID : 2312218	
Patient Type : OPD	
Bed No :	

**BIOCHEMISTRY**

**Blood Group And Rh Factor**

TEST NAME	RESULT	UNITS	BIOLOGICAL
TEST METHOD			REFERENCE INTERVAL SPECIMEN TYPE
BLOOD GROUP(ABORh)	'A' POSITIVE		

-\*\*\*\* End of Report \*\*\*\*-

**This is Provisional Report**

Lab Technician  
Dr.NishaTiwari  
(MD.Microbiology)

Dr. Neha Gupta  
MBBS,MD(Pathology)  
(Consultant Pathologist)



Dr. Shreya Pradhan  
MBBS,MD(Microbiology)  
(Consultant Microbiologist)

(This is only professional opinion and not the diagnosis. Please correlate clinically)

Sector 37-D, BPTP, Dwarka Express Way, Gurugram, Hry.,

Ph.: 0124-6034444, 6262828213, E-mail : signaturehospital@gmail.com, Web.: www.thesignaturehealthcare.com

**PARK GROUP OF HOSPITAL : ★ West Delhi ★ South Delhi ★ Gurugram ★ Faridabad ★ Panipat ★ Karnal**



**Patient Name:** Mrs. SUSHILA KUMARI  
 Age / Gender : 47 Years 0 Months 12Days / Female  
 Referred By : Dr. CMO  
**Req.No** : 2312218  
**Patient Type** : OPD

UHID : 25891  
 IPNO :  
 Registered : 18/03/2023/ 8.51 AM  
 Reported on : 18/03/2023/ 3.35 PM



**BIOCHEMISTRY**

**Blood Sugar 2 Hr. Pp**

TEST NAME	RESULT	UNITS	BIOLOGICAL REFERENCE INTERVAL
<b>BLOOD SUGAR POST PRANDIAL(BSPP)</b>	113	mg/dl	90 - 140

**Method:** God- Trinders

Increased In:  
 Diabetes Mellitus  
 Stress ( e.g, emotion, burns, shock, anesthesia)  
 Acute Pancreatitis  
 Chronic Pancreatitis  
 Wernicke encephalopathy ( Vitamin B1 deficiency)  
 Effect of drugs (e.g. corticosterogens, alcohol, phenytoin, thiazides)

Decreased in :  
 Pancreatitis disorders  
 Extrapancreatic tumors  
 Endocrine disorders  
 Malnutrition  
 Hypothalamic lesions  
 Alcoholism  
 Endocrine Disorders

-\*\*\*\* End of Report \*\*\*\*-

*Please Correlate With Clinical Findings If Necessary Discuss*  
 \* This is an Electronically Authenticated Report \*



\*\* Some of the test is performed in PARK HOSPITAL GROUP SUPER SPECIALITY HOSPITAL

Lab Technician

(This is only professional opinion and not the diagnosis. Please correlate clinically)

Sector 37-D, BPTP, Dwarka Express Way, Gurugram, Hry.,

Ph.: 0124-6034444, 6262828213, E-mail : signaturehospital@gmail.com, Web.: www.thesignaturehealthcare.com  
**PARK GROUP OF HOSPITAL** : ★ West Delhi ★ South Delhi ★ Gurugram ★ Faridabad ★ Panipat ★ Karnal

Patient Name : Mrs. SUSHILA KUMARI	UHID : 25891
Age / Gender : 47 Years 0 Months 12Days / Female	IPNO :
Referred By : Dr. CMO	Bill Date : 18/03/2023
Req.No : 23268939	Reporting Date : 20/03/2023
Sample ID : 2312218	
Patient Type : OPD	
Bed No :	

**SEROLOGY/IMMUNOLOGY**

**Thyroid Profile**

TEST NAME	RESULT	UNITS	BIOLOGICAL REFERENCE INTERVAL	SPECIMEN TYPE
TEST METHOD				
Triiodothyronine (T3)	1.21	ng/ml	0.60 - 1.81	SERUM
Thyroxine (T4) CLIA	5.94	ug/dL	5.01 - 12.45	
TSH ( Thyroid Stimulating Hormone ) CLIA	<b>10.4</b>	uIU/ml	0.55 - 5.55	

Remarks :  
 (1) 4.2 to 15 IU/mL - Correlate clinically as physiological and other factors may falsely elevate TSH level. (2) TSH Values may be transiently altered because of non thyroidal illness. (3) Some drugs may decrease TSH values, e.g., L-dopa, Glucocorticoids. (4) Some drugs may increase TSH values, e.g., Iodine, Lithium, Amiodarone. Abbreviations.

-\*\*\* End of Report \*\*\*-

***This is Provisional Report***

Lab Technician      Dr.NishaTiwari  
 (MD.Microbiology)

Dr. Neha Gupta  
 MBBS,MD(Pathology)  
 (Consultant Pathologist)

  
 Dr. Shreya Pradhan  
 MBBS,MD(Microbiology)  
 (Consultant Microbiologist)

(This is only professional opinion and not the diagnosis. Please correlate clinically)

Sector 37-D, BPTP, Dwarka Express Way, Gurugram, Hry.,

Ph.: 0124-6034444, 6262828213, E-mail : signaturehospital@gmail.com, Web.: www.thesignaturehealthcare.com

**PARK GROUP OF HOSPITAL : ★ West Delhi ★ South Delhi ★ Gurugram ★ Faridabad ★ Panipat ★ Karna**

Patient Name : Mrs. SUSHILA KUMARI	UHID : 25891
Age / Gender : 47 Years 0 Months 12Days / Female	IPNO :
Referred By : Dr. CMO	Bill Date : 18/03/2023
Req.No : 23268939	Reporting Date : 18/03/2023
Sample ID : 2312218	
Patient Type : OPD	
Bed No :	

**BIOCHEMISTRY**

**Lipid Profile**

TEST NAME	RESULT	UNITS	BIOLOGICAL REFERENCE INTERVAL	SPECIMEN TYPE
TEST METHOD				
<b><u>LIPID PROFILE</u></b>				
CHOLESTROL (CHOD-TRINDER)	174	mg/dl	00 - 200	SERUM
TRIGLYCERIDES (GPO-Trinders)	78	mg/dl	35 - 170	SERUM
HDL- CHOL (Direct Method/ Enzymatic Colorometric)	43	mg/dl	40 - 60	SERUM
VLDL-CHOL CALCULATED	15.6	mg/dl	10 - 40	
LDL-CHOLESTROL	115.4	mg/dl	0 - 130	
LDL/HDL RATIO	2.68		0-3	
CHOLESTROL/HDL RATIO	<b>4.05</b>			

-\*\*\* End of Report \*\*\*-

***This is Provisional Report***

Lab Technician	Dr.NishaTiwari (MD.Microbiology)	Dr. Neha Gupta MBBS,MD(Pathology) (Consultant Pathologist)	 Dr. Shireya Pradhan MBBS,MD(Microbiology) (Consultant Microbiologist)
----------------	-------------------------------------	--	--

(This is only professional opinion and not the diagnosis. Please correlate clinically)

Sector 37-D, BPTP, Dwarka Express Way, Gurugram, Hry.,

Ph.: 0124-6034444, 6262828213, E-mail : signaturehospital@gmail.com, Web.: www.thesignaturehealthcare.com

**PARK GROUP OF HOSPITAL : ★ West Delhi ★ South Delhi ★ Gurugram ★ Faridabad ★ Panipat ★ Karna**

Patient Name : Mrs. SUSHILA KUMARI	UHID : 25891
Age / Gender : 47 Years 0 Months 12Days / Female	IPNO :
Referred By : Dr. CMO	Bill Date : 18/03/2023
Req.No : 23268939	Reporting Date : 18/03/2023
Sample ID : 2312218	
Patient Type : OPD	
Bed No :	

**BIOCHEMISTRY**

**Kidney Function Test .**

TEST NAME	RESULT	UNITS	BIOLOGICAL REFERENCE INTERVAL	SPECIMEN TYPE
TEST METHOD				
BLOOD UREA (Urease UV/GLDH)	19	mg/dl	13 - 45	SERUM
SERUM CREATININE (Jaffe Rate)	0.8	mg/dl	0.6 - 1.2	SERUM
URIC ACID (Enzymatic/Uricase)	2.2	mg/dl	2.5 - 6.8	SERUM
<b><u>ELECTROLYTES</u></b>				
SODIUM (ISE-Indirect)	144	mmol/L	132 - 150	SERUM
POTASSIUM (ISE-Indirect)	4.7	mmol/L	3.5 - 5.5	SERUM

-\*\*\*\* End of Report \*\*\*\*-

***This is Provisional Report***



Lab Technician	Dr.NishaTiwari (MD.Microbiology)	Dr. Neha Gupta MBBS,MD(Pathology) (Consultant Pathologist)	Dr. Shreya Pradhan MBBS,MD(Microbiology) (Consultant Microbiologist)
----------------	-------------------------------------	--	--

(This is only professional opinion and not the diagnosis. Please correlate clinically)

Sector 37-D, BPTP, Dwarka Express Way, Gurugram, Hry.,

Ph.: 0124-6034444, 6262828213, E-mail : signaturehospital@gmail.com, Web.: www.thesignaturehealthcare.com

**PARK GROUP OF HOSPITAL : ★ West Delhi ★ South Delhi ★ Gurugram ★ Faridabad ★ Panipat ★ Karna**

Patient Name : Mrs. SUSHILA KUMARI	UHID : 25891
Age / Gender : 47 Years 0 Months 12Days / Female	IPNO :
Referred By : Dr. CMO	Bill Date : 18/03/2023
Req.No : 23268939	Reporting Date : 18/03/2023
Sample ID : 2312218	
Patient Type : OPD	
Bed No :	

**BIOCHEMISTRY**

**PROTEINS**

TOTAL PROTEIN (Biuret)	6.4	g/dl	6.0 - 8.3	SERUM
ALBUMIN (BCG- DYE)	3.9	g/dl	3.2 - 5.0	SERUM
GLOBULIN Calculated	2.5	gm/dl	1.5 - 3.6	
A/G RATIO Calculated	1.56		0.9 - 2.0	

-\*\*\* End of Report \*\*\*-

***This is Provisional Report***

Lab Technician

Dr.NishaTiwari  
(MD.Microbiology)

Dr. Neha Gupta  
MBBS,MD(Pathology)  
(Consultant Pathologist)



Dr. Shreya Pradhan  
MBBS,MD(Microbiology)  
(Consultant Microbiologist)

Page 2 of 2

(This is only professional opinion and not the diagnosis. Please correlate clinically)

Sector 37-D, BPTP, Dwarka Express Way, Gurugram, Hry.,

Ph.: 0124-6034444, 6262828213, E-mail : signaturehospital@gmail.com, Web.: www.thesignaturehealthcare.com  
**PARK GROUP OF HOSPITAL : ★ West Delhi ★ South Delhi ★ Gurugram ★ Faridabad ★ Panipat ★ Karnal**



Patient Name : Mrs. SUSHILA KUMARI	UHID : 25891
Age / Gender : 47 Years 0 Months 12Days / Female	IPNO :
Referred By : Dr. CMO	Bill Date : 18/03/2023
Req.No : 23268939	Reporting Date : 18/03/2023
Sample ID : 2312218	
Patient Type : OPD	
Bed No :	

**CLINICAL PATHOLOGY**

**CHEMICAL EXAMINATION**

UROBILINOGEN (Ehrlich's Aldehyde Reaction)	NORMAL	NORMAL	Urine
PROTEIN	NIL	NIL	
BLOOD	NIL	NIL	
KETONE (Sodium Nitroprusside)	NIL	NIL	Urine
BILIRUBIN (Diazonium Salt)	NIL	NIL	SERUM
GLUCOSE (Benedict's Test)	NIL	NIL	Urine
NITRITE	NEGATIVE		

-\*\*\*\* End of Report \*\*\*\*-

***This is Provisional Report***



Lab Technician	Dr.NishaTiwari (MD.Microbiology)	Dr. Neha Gupta MBBS,MD(Pathology) (Consultant Pathologist)	Dr. Shreya Pradhan MBBS,MD(Microbiology) (Consultant Microbiologist)
----------------	-------------------------------------	--	--

(This is only professional opinion and not the diagnosis. Please correlate clinically)

Sector 37-D, BPTP, Dwarka Express Way, Gurugram, Hry.,

Ph.: 0124-6034444, 6262828213, E-mail : signaturehospital@gmail.com, Web.: www.thesignaturehealthcare.com

**PARK GROUP OF HOSPITAL : ★ West Delhi ★ South Delhi ★ Gurugram ★ Faridabad ★ Panipat ★ Karnal**









**DEPARTMENT OF IMAGING & INTERVENTIONAL RADIOLOGY, THE SIGNATURE HOSPITAL**

NAME: SUSHILA KUMARI	DATE: 18/03/2023
AGE: 47/F	MR NO.: 25891

**X-RAY CHEST**

Lung fields are clear.

Bilateral hilar shadows are normal.

Mediastinum and domes are normal.

Costophrenic angles appear sharp.

Cardiac silhouette appears normal.

No obvious rib fracture seen.

*Adv: Clinical and lab data correlation.*



**Dr. Guru**  
Senior Consultant  
Diagnostic & Interventional Radiology

(This is only professional opinion and not the diagnosis. Please correlate clinically)

Sector 37-D, BPTP, Dwarka Express Way, Gurugram, Hry.,

Ph.: 0124-6034444, 6262828213, E-mail : signaturehospital@gmail.com, Web.: www.thesignaturehealthcare.com

**PARK GROUP OF HOSPITAL** : ★ West Delhi ★ South Delhi ★ Gurugram ★ Faridabad ★ Panipat ★ Karna

ID: 31  
AGE: 81 Y M D  
Cms: 60K9

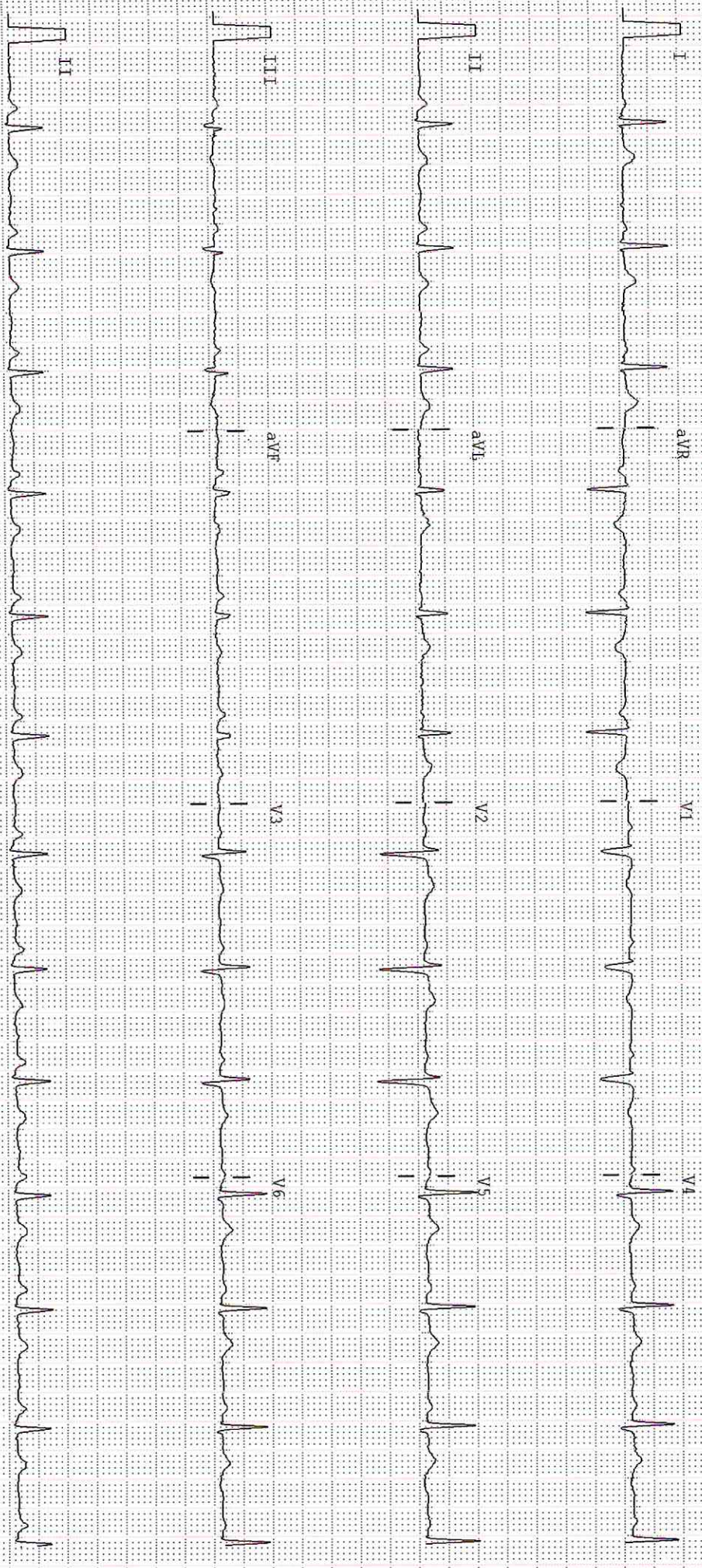

CASE: MRS SUSHILA KUMARI  
FEMALE

18/03/2023 08:55:28  
SIGNATURE HOSPITAL  
SEC-37(D) GURUGRAM

RATE: 76 bpm SINUS RHYTHM  
P-R: 786 ms ANTERIOR T WAVE ABNORMALITY IS NONSPECIFIC  
P-R: 144 ms  
QRS: 84 ms  
QT: 368 ms  
QTc: 396 ms

AXIS: P: 62°  
QRS: 36°  
T: 13°

12 SL. REPORT FORMAT: 3x4+1L SQ REF: DR. CMO



**TRANSTHORACIC ECHO- DOPPLER REPORT**

**NAME - MRS SUSHILA KUMARI**

**AGE/SEX/47/F**

**MR. NO. - 25891**

**DATE 18/03/2023**

**M-MODE / 2-D DESCRIPTION**

- ❖ **Left Ventricle:** No Regional Wall Motion Abnormality. LVEF 55%
- ❖ **Left Atrium:** Normal.
- ❖ **Right atrium:** It is Normal Sized.
- ❖ **Right ventricle:** It is Normal Sized. RV Systolic Function is Normal.
- ❖ **Aortic valve:** Aortic Cusps are Normal.
- ❖ **Mitral valve:** It Appears Normal.
- ❖ **Tricuspid valve:** It Appears Normal.
- ❖ **Pulmonic valve:** It Appears Normal.
- ❖ **Main pulmonary artery & its branches:** Appear Normal.
- ❖ **Pericardium:** No Pericardial Effusion Seen
- ❖ **Inter atrial septum:** It is Intact.
- ❖ **Inter ventricular septum:** It is Intact.
- ❖ **IVC:** It is Normal in Size, collapsing & Respiratory Variability.
- ❖ **Clot / Vegetation:** No Intracardiac Clot, Vegetation.

**Measurements (mm):**

LEFT HEART			RIGHT HEART		
	Observed values (mm)	Normal values		Observed values (mm)	Normal values
Aortic root	29	20-36 (22mm/M <sup>2</sup> )	IVC size	-	17-21mm
Aortic valve opening		15-26 (mm/M <sup>2</sup> )	IVC respiratory variability		>50%
LA size	30	19-40 (mm/M <sup>2</sup> )	RA size	-	<18cm <sup>2</sup>
LA volume index (ml/M <sup>2</sup> )		<34 ml/M <sup>2</sup>		-	
LVID(D)	45	(ED=37-56)	RV basal		24-42mm
LVID(S)	35		RV mid cavity	-	20-35mm
IVS(D)	8	(ED=6-12)	RV longitudinal	-	56-86mm
			RVOT proximal	-	18-33mm
PW(D)	9	(ED=5-10)	TAPSE	-	>15mm
			RV free wall thickness	-	<5mm
LVEF(%)	55%	55%-70%	RV EF		(%)

(This is only professional opinion and not the diagnosis. Please correlate clinically)

Sector 37-D, BPTP, Dwarka Express Way, Gurugram, Hry.,

Ph.: 0124-6034444, 6262828213, E-mail : signaturehospital@gmail.com, Web.: www.thesignaturehealthcare.com

**PARK GROUP OF HOSPITAL : ★ West Delhi ★ South Delhi ★ Gurugram ★ Faridabad ★ Panipat ★ Karn**

Doppler velocities (cm/sec)

Aortic valve		Pulmonary valve	
Max/ Vel	112	Max velocity	119
Max/ PG		Max PG	
Mitral valve		Tricuspid valve	
E	60	Max Velocity	
A	58	PASP	-
DT	-	E/E' (>6)	-
E/A	-	S' Velocity (>10cm2/sec)	-

Regurgitation

MR		TR	
Severity	Nil	Severity	Nil
AR		PR	
Severity	Nil	Severity	Nil

Final Interpretation:

- No Regional Wall Motion Abnormality. LVEF 55%
- Normal Cardiac Chamber.
- No MR, No AR, No TR.
- Grade I Diastolic dysfunction
- No Vegetation, Pericardial Effusion



**Dr. AJAY DUA**  
 DNB (Medicine), DNB (Cardiology)  
 Sr. Consultant Interventional Cardiology

(This is only professional opinion and not the diagnosis. Please correlate clinically)

Sector 37-D, BPTP, Dwarka Express Way, Gurugram, Hry.,

Ph.: 0124-6034444, 6262828213, E-mail : signaturehospital@gmail.com, Web.: www.thesignaturehealthcare.com

**PARK GROUP OF HOSPITAL : ★ West Delhi ★ South Delhi ★ Gurugram ★ Faridabad ★ Panipat ★ Karnal**

**DEPARTMENT OF IMAGING & INTERVENTIONAL RADIOLOGY, THE SIGNATURE HOSPITAL**

<b>NAME: SUSHILA KUMARI</b>	<b>DATE: 18/03/2023</b>
<b>AGE: 47/F</b>	<b>MR NO.: 25891</b>

**USG WHOLE ABDOMEN**

**LIVER:** is normal in size and shows raised in echotexture. No evidence of any focal lesion or IHBR dilation is present. Portal vein and CBD are normal in caliber at porta.

**GALL BLADDER** is well distended and lumen is echofree. Wall thickness is normal. No pericholecystic fluid is seen.

**SPLEEN:** is normal in size and echotexture. No focal lesion is seen.

**PANCREAS:** is normal in size and echotexture. Peripancreatic fat planes are clear. MPD is not dilated.

**RIGHT KIDNEY:** is normal in size and position and outline corticomedullary differentiation is maintained. There is no evidence of any focal lesion / calculus / backpressure changes.

**LEFT KIDNEY:** is normal in size and position and outline corticomedullary differentiation is maintained. There is no evidence of any focal lesion / calculus / backpressure changes.

**URINARY BLADDER** is well distended. Wall thickness is normal. No evidence of any focal lesion.

**UTERUS** is not visualised (Post hysterectomy). No adnexal mass lesion seen.

**IMPRESSION:**

• Grade II fatty liver.

**ADVICE:** LFT CORRELATION IF CLINICALLY INDICATED.

**Dr. Guru**

Senior Consultant

Diagnostic & Interventional Radiology

(This is only professional opinion and not the diagnosis. Please correlate clinically)

Sector 37-D, BPTP, Dwarka Express Way, Gurugram, Hry.,

Ph.: 0124-6034444, 6262828213, E-mail : signaturehospital@gmail.com, Web.: www.thesignaturehealthcare.cc

**PARK GROUP OF HOSPITAL :** ★ West Delhi ★ South Delhi ★ Gurugram ★ Faridabad ★ Panipat ★ Kar