



PARKLINE DIAGNOSTICS PVT. LTD.

L.G. 3, 4 & 5, Bhuvana Towers, S.D. Road, Secunderabad - 500 003.

Tel : +91 40-2784 5852, 6649 1787, 7995421787, 7093445852, Fax : +91 40 2784 7864

Email parklinediagnostics@gmail.com www.parklinediagnostics.com



NABL Accredited
Certificate No.MC-2566

MEDICAL EXAMINATION REPORT

Name	N.S. Pothankar Archana		Date :	23/03/2022	
Company	Q/O: Medi Wheel		Reg. No. :	1898852	
Contact No.	7988403185		Sex	<input checked="" type="checkbox"/>	Age : <input type="checkbox"/> 36
Type	Pre-Emp		Emp. No.:	Spouse	
	Overseas		Height	156 cm	
	Annual	<input checked="" type="checkbox"/>	Weight	76 kg	
Remarks	<ul style="list-style-type: none"> - ↑ ESR count. Advice follow up. - Impaired glucose tolerance ⊕ HbA1c - 6.5% - Advice follow up. - Baseline Cholesterolemia ⊕. Advice follow up. - Advised to improve Hb. levels. Repeat CRP after 4-6 weeks. 				
Fitness Status	Medically Fit / Unfit		<p style="text-align: right;">DR. PRIYANKA SANNIDHI MBBS Regn. No: 11351</p>		
			Physician's Signature		

COMPREHENSIVE MEDICAL EXAMINATION REPORT

NAME Ms. Pothankar Archana

AGE 26 yrs / Female

MARITAL STATUS married CHILDREN : M F

IDENTIFICATION (IF ANY) A mole on (R) eyeball (sclera)

PAST HISTORY

Any family H/o : High Blood Pressure, Heart Disease, Tuberculosis, Diabetes, Asthma, Cancer

HTN⁺ Mother

Any personal H/o Major illness like : Typhoid.....NIL.....Jaundice.....NIL.....Etc.

Any H/o STD.....NIL.....Skin infection.....Melasma x 2 months.

H/o Blood Transfusion.....NIL.....Recent Vaccination.....COVISHIELD 2 Doses ✓

H/o Epilepsy.....NIL.....Giddiness.....NIL

H/o Surgery.....2 USC e.....Fracture in the past.....NIL

Any Personal H/O. Subectomy done 2015, 2019.

High Blood Pressure, Heart Disease Tuberculosis, Diabetes, Asthma, Cancer

Drug Abuse, Drug Allergy, Micturition, Bowels, Alcohol, Smoking, Sleep, MC, Wt. Loss/Wt. Gain

T-PAN Young.

Present illness / Medication

GENERAL EXAMINATION

Conjunctiva :
Skin :
Ears :
Nose :
Throat & Oral Cavity :

NAD

Bone, Joints : (N)
Nutritional Status : well nourished
Lymph Nodes : NPD
Edema Feet : NIL
Varicose Veins : NIL

Distant Vision : Near Vision :

Right Eye: ^{6/60} -5.00 sph 6/6

With glasses / Without glasses

left Eye: ^{6/18} -1.50 sph 6/6

with glasses / without glasses

Colour Vision : BF normal

Right Ear

Hearing : (N)
Rinee's Test ; trc
Weber Test : central
Discharge : Absent

Right Eye: RG

With glasses / Without glasses

left Eye : RG

with glasses / without glasses

Dr. KATTA
Ophthalmologist's Signature
Regd: 8961 (AMC)

Left Ear

Hearing : (N)
Rinee's Test ; trc
Weber Test : central
Discharge : Absent

SYSTEMIC EXAMINATION

Pulse : 80 bpm B.P. : 120/80 mmHg

Lungs : A. Shape of Chest Sp symmetrical.
B. Breath Sounds Sp - clear ⊕
C. Adventitious Sounds No

Heart : A. Sounds S₁ S₂ ⊕
B. Murmurs No murmurs

Abdomen : A. Liver NPD
B. Spleen NPD
C. Piles NIL
D. Any Lump NIL

Nervous System

A. Higher Function :
B. Cranial Nerves :
C. Sensory System :
D. Motor System :
E. Jerks :

General : A. Hernia
B. Hydrocele
C. Varicocele] NPD

Breast : Rt (N) Lt. (N)

(N)

CANDIDATE'S DECLARATION

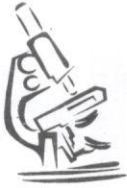I hereby solemnly declare that I am not suffering from Asthma, Hypertension, Diabetes, Occult Psychological disorders or any other ailment which can be suppressed without my voluntary declaration.

Date :

P. A. S.
Signature

Place :

Note : General Physical Examination and Investigation included in the health check-up Have certain limitations and may not be able to detect all latent and asymptomatic diseases. Any new symptoms developing after the health check-up or persisting thereafter should be brought to the attention of the treating physician.



PARKLINE DIAGNOSTICS PVT. LTD.

L.G. 3, 4 & 5, Bhuvana Towers, S.D. Road, Secunderabad - 500 003. Tel :+91 40-2784 5852, 6649 1787, 7995421787, 7093445852, Fax : +91 40 2784 7864 Email parklinediagnostics@gmail.com www.parklinediagnostics.com



NABL Accredited
Certificate No.MC-2566

ENT CONSULTATION

S.No. 1898853

Emp.No. spouse

Date 23/3/22

Name Ms. Pothankar
Aruna

Age 36 Yrs

Sex M/F

EARS :

Right

Left

EAC :

(N)

(N)

TM :

(N) (N)

(N)

(N)

TFT :

Rinne's AC > BC

AC > BC

central

Weber's



NOSE :

ABC same as examiner
AP - septum - central IT - (N)

THROAT :

AP - (N) TF - (N) PPh - (N)

NECK :

No central / lateral swelling

IMPRESSION:

ENT Examinations within (N) limits

Dr. D. Hari Krishna Reddy
MS (ENT)
Head & Neck Surgeon
Reg. No: 88379



Phone: 27844043
66339096

SECUNDERABAD DENTAL HOSPITAL

CENTRE FOR ADVANCED DENTAL CARE

24/3/2022

ORAL & MAXILLOFACIAL SURGEONS

Dr. Kazim Himathi M.D.S.

Dr. Gautam Dendukuri

FDSRCS (Eng), FFDRCS (Ire),
FFDRCS (OMFS),(Ire)

PISTHODONTIST

Dr. Chandrakanth Reddy M.D.S.

ENDODONTIST

Dr. Ram Narayan Reddy M.D.S.

ORTHODONTIST

Dr. Rajesh Reddy M.D.S., M.Orth RCS.

Dr. Sudeep Bhalerao M.D.S.

PERIODONTIST

Dr. Veerendranath Reddy M.D.S.

PEDODONTIST

Dr. Soumya M.D.S.

Dr. Mounika M.D.S.


DENTAL SURGEONS


Dr. N. Jagadish Rao B.D.S.

Dr. Baisakhi Saha B.D.S.

Mrs. Podhankar Archana

c/o :- Patient came for a regular
dental checkup

o/e :-
- old filling noted
- D.C. 
- stains

Adv :- Scaling
Bx1 





PARKLINE DIAGNOSTICS PVT. LTD.

L.G 3, 4 & 5, Bhuvana Towers, Sarojini Devi Road, Secunderabad - 500 003.
Tel. +91 40 2784 5852, 6649 1787, 77995421787, 7093445852, Fax : + 91 40 2784 7864
Email : parklinediagnostics@gmail.com, www.parklinediagnostics.com



TEST REPORT

Name : Ms . POTHANKAR ARCHANA [SPOUSE]
Age / Gender : 36 Years / Female
Ref.By : Medi Wheel
Req. No : BIL1898857

TID : UMR0750388
Registered on : 23-Mar-2022 08:50 AM
Reported On : 23-Mar-2022 11:27 AM

Ultrasound Abdomen and Pelvis

LIVER is normal shape, size (14.0 cms) and has uniform echopattern.
No evidence of focal lesion or intrahepatic biliary ductal dilatation.
Hepatic and portal vein radicals are normal.

GALL BLADDER shows normal shape and has clear contents.
Gall bladder wall is of normal thickness.

CBD is of normal calibre.

PANCREAS has normal shape, size and uniform echopattern.
No evidence of ductal dilatation or calcification.

SPLEEN shows normal shape, size and echopattern.

KIDNEYS move well with respiration and have normal shape, size and echopattern.
Cortico- medullary differentiations are well madeout.
No evidence of calculus or hydronephrosis.
Right kidney measures: 10.2 x 4.4 cms, Left kidney measures: 11.2 x 4.5 cms.

URINARY BLADDER shows normal shape and wall thickness.
It has clear contents. No evidence of diverticula.

UTERUS is anteverted has normal shape and size.
It has uniform myometrial echopattern.
Endometrial echo is of normal thickness 8.4 mm.
Uterus measures 6.9 x 3.8 x 5.6 cms.

OVARIES are normal in size, shape and echotexture.
Right ovary: 2.0 x 1.7 cms, Left ovary: 1.9 x 1.7 cms.

The Test marked with*are not accredited by NABL

Lab Timings (Weekdays) : 7.00 am to 8.30 pm
Sundays & Holidays : 7.00 am to 1.00 pm

Radiologists Timings (Weekdays) : 7.30 am to 1.30 pm
& 5.30 pm to 7.45 pm
Sundays & Holidays : 7.30 am to 9.30 am

PARKLINE DIAGNOSTICS PVT. LTD.



L.G 3, 4 & 5, Bhuvana Towers, Sarojini Devi Road, Secunderabad - 500 003.
Tel. +91 40 2784 5852, 6649 1787, 77995421787, 7093445852, Fax : + 91 40 2784 7864
Email : parklinediagnostics@gmail.com, www.parklinediagnostics.com



TEST REPORT


Name : Ms . POTHANKAR ARCHANA [SPOUSE]
Age / Gender : 36 Years / Female
Ref.By : Medi Wheel
Req. No : BIL1898857

TID : UMR0750388
Registered on : 23-Mar-2022 08:50 AM
Reported On : 23-Mar-2022 11:27 AM

No evidence of free fluid in the abdomen and pelvis.

IMPRESSION: * No sonographic abnormality detected.

Suggested clinical correlation and follow up


Dr. Abid Yazden
Consultant Radiologist

The Test marked with*are not accredited by NABL

Lab Timings (Weekdays) : 7.00 am to 8.30 pm
Sundays & Holidays : 7.00 am to 1.00 pm

Radiologists Timings (Weekdays) : 7.30 am to 1.30 pm
& 5.30 pm to 7.45 pm
Sundays & Holidays : 7.30 am to 9.30 am



PARKLINE DIAGNOSTICS PVT. LTD.

L.G 3, 4 & 5, Bhuvana Towers, Sarojini Devi Road, Secunderabad - 500 003.
Tel. +91 40 2784 5852, 6649 1787, 77995421787, 7093445852, Fax : + 91 40 2784 7864
Email : parklinediagnostics@gmail.com, www.parklinediagnostics.com



TEST REPORT

Name : Ms . POTHANKAR ARCHANA [SPOUSE]
Age / Gender : 36 Years / Female
Ref.By : Medi Wheel
Req. No : BIL1898857

TID : UMR0750388
Registered on : 23-Mar-2022 08:50 AM
Reported On : 23-Mar-2022 11:49 AM

X-RAY CHEST PA VIEW

Lung fields are clear.

Cardia is normal.

Hila are normal.


C P angles are free.

Bony cage is normal.

Soft tissues are normal.

IMPRESSION : NORMAL CHEST X-RAY




Dr. PRAJAKTA SUKHADEVE
DNB RADIOLOGY
Reg. No. 68493

The Test marked with*are not accredited by NABL

Lab Timings (Weekdays) : 7.00 am to 8.30 pm
Sundays & Holidays : 7.00 am to 1.00 pm

Radiologists Timings (Weekdays) : 7.30 am to 1.30 pm
& 5.30 pm to 7.45 pm
Sundays & Holidays : 7.30 am to 9.30 am

MRS. POTHANKAR ARCHANA

Female 36Years

HR : 89 bpm
P : 97 ms
PR : 143 ms
QRS : 77 ms
QT/QTc : 357/436 ms
P/QRS/T : 52/52/9 °
RV5/SV1 : 1.101/0.743 mV

NSR
WNC



Dr. NAVEEN KUMAR C
M.D., D.M.
Consultant Cardiologist
Reg. No. 52291

Diagnosis Information:
Sinus Rhythm
Poor R Wave Progression(V3,V4)

Report Confirmed by:

PARKLINE DIAGNOSTICS PVT.LTD

PATIENT SUMMARY REPORT

ID : 1898857
NAME : **MS POTHANKAR ARCHANA**
AGE / SEX : 36 / FEMALE

HEIGHT (cm) : 158
WEIGHT (kg) : 76
PROTOCOL : BRUCE

REF. BY : MEDIWHEEL
DONE BY : DR NAVEEN KUMAR C
TECHNICIAN : G.M.SURESH

CASE HISTORY :

MEDICATION :

OBJECT OF TEST :

Routine Check Up.

RISK FACTOR :

None.

ACTIVITY :

Very Active.

OTHER INVESTIGATION :

E C G

REASON FOR TERMINATION :

Dyspnea.

EXERCISE TOLERANCE :

Moderate (< 10 METS).

EXERCISE INDUCED ARRHYTHMIAS :

No.

HAEMO RESPONSE :

Normal.

CHRONO RESPONSE :

Normal.

FINAL IMPRESSION :

EXTRA COMMENTS :

Negative for inducible ischemia

Confirmed By: *[Signature]*
DR. NAVEEN KUMAR C

Signature M.D., D.M.
Consultant Cardiologist
Reg. No. 52201