



LETTER OF APPROVAL / RECOMMENDATION

To,

The Coordinator,
Mediwheel (Arcofemi Healthcare Limited)
Helpline number: 011- 41195959

Dear Sir / Madam,

Sub: Annual Health Checkup for the employees of Bank of Baroda

This is to inform you that the following employee wishes to avail the facility of Cashless Annual Health Checkup provided by you in terms of our agreement.

PARTICULARS	EMPLOYEE DETAILS
NAME	MR. PATRA AMULYA KUMAR
EC NO.	73190
DESIGNATION	HEAD CASHIER "E"_II
PLACE OF WORK	BERHAMPUR, BRAJANAGAR
BIRTHDATE	15-04-1970
PROPOSED DATE OF HEALTH CHECKUP	24-07-2021
BOOKING REFERENCE NO.	21S73190100001306E

This letter of approval / recommendation is valid if submitted along with copy of the Bank of Baroda employee id card. This approval is valid from **20-07-2021** till **31-03-2022** The list of medical tests to be conducted is provided in the annexure to this letter. Please note that the said health checkup is a **cashless facility** as per our tie up arrangement. We request you to attend to the health checkup requirement of our employee and accord your top priority and best resources in this regard. The EC Number and the booking reference number as given in the above table shall be mentioned in the invoice, invariably.

We solicit your co-operation in this regard.

Yours faithfully,

Sd/-

Chief General Manager
HRM Department
Bank of Baroda

(Note: This is a computer generated letter. No Signature required. For any clarification, please contact Mediwheel (Arcofemi Healthcare Limited))



बैंक ऑफ बड़ोदा
Bank of Baroda



नाम
Name AMULYA KUMAR PATRA

कर्मचारी कुट क्र
E.C. No 73190



अभिषेक इतिहास - २० प्रशासक
Issuing Authority - D.G.M.
Odisha Region

नाम के हस्ताक्षर
Signature of Holder



New
NEELACHALA HOSPITAL

A Promise for Life...

(AN ISO 9001 : 2008 CERTIFIED HOSPITAL)


NAME	AMULYA KU PATRA	Age/Sex	51Yrs/M
Ref. By.	New Neelachala Hospital	EC No.	73190
Sample.Dt.	24-07-2021	Reporting Dt	26-07-2021

BIOCHEMICAL TEST

<u>TEST</u>	<u>OBSERVED VALUE</u>	<u>UNIT</u>	<u>NORMAL VALUE</u>
Fasting Blood Sugar	85.2	mg/dl	70 - 110
Fasting Urine Sugar	0.1	mmol/L	0 - 0.8
2H PPBS	81	mg/dl	> 140
PP Urine Sugar	03	mg/dl	0 - 15
Serum Uric Acid	5.0	mg/dl	3.4 - 7.0
Serum Creatinine	0.6	mg/dl	0.0 - 1.2
Blood Urea Nitrogen	11.0	mg/dl	07 - 20
BUN Ratio	18.3		

LIPID PROFILE

<u>TEST</u>	<u>OBSERVED VALUE</u>	<u>UNIT</u>	<u>NORMAL VALUE</u>
Cholesterol	150	mg/dl	130 - 220
Triglycerides	97.5	mg/dl	50 - 160
HDL Cholesterol	48.0	mg/dl	35 - 70
LDL Cholesterol	82.5	mg/dl	60 - 130
VLDL	31	mg/dl	25 - 50
Cholesterol/HDL Ratio	3.12	mg/dl	< 4.5
LDL/HDL Ratio	1.72		


Swamy Prvya Pradhan
MD Pathologist
Regd. No.9431

N. B. : THIS REPORT IS NOT MEANT FOR MEDICO LEGAL PURPOSE

KAMAPALI - GOILUNDI LINK ROAD, NEAR NANDIGHOSH APARTMENT, BERHAMPUR - 760 004 (ODISHA)
CELL : 9438251721, 9337859729



New
NEELACHALA HOSPITAL


A Promise for Life...

(AN ISO 9001 : 2008 CERTIFIED HOSPITAL)

NAME	AMULYA KU PATRA	Age/Sex	51Yrs/M
Ref. By.	New Neelachala Hospital	EC No.	73190
Sample.Dt.	24-07-2021	Reporting Dt	26-07-2021

STOOL ANALYSIS REPORT

COLOUR :- Yellow
CONSISTENCY :- Pesty
REACTION :- Acidic
MUCUS :- Absent
BLOOD :- Absent
PARASITS :- Adequate
R.B.C. :- Not Seen
VEG.CELLS :- Present
STARCH :- Not Seen
MICROPHAGES :- Not Seen
FAT GLOBULES :- Not Seen
BACTERIAL FLORA :- Reduced.
YEAST/MOULDS :- Not Seen
SUGAR :- Not Seen
OVA/LARVA OF HELMINTUS:- Not Seen
CYST.VEG FORMS PROTOZOA:- Not Seen
OCCULT BLOOD :- Not Seen
PROTOZOA (Cysts/Trohozoites) :- Not Seen
HELMINTHES (Ova/Larva) :- Not Seen


Swamy Prava Pradhan
signature
MD Pathologist
Regd. No.9431

N. B. : THIS REPORT IS NOT MEANT FOR MEDICO LEGAL PURPOSE

KAMAPALI - GOILUNDI LINK ROAD, NEAR NANDIGHOSH APARTMENT, BERHAMPUR - 760 004 (ODISHA)
CELL : 9438251721, 9337859729



New
NEELACHALA HOSPITAL

A Promise for Life...

(AN ISO 9001 : 2008 CERTIFIED HOSPITAL)

NAME	AMULYA KU PATRA	Age/Sex	51Yrs/M
Ref. By.	New Neelachala Hospital	EC No.	73190
Sample.Dt.	24-07-2021	Reporting Dt	26-07-2021

URINE ANALYSIS REPORT

PHYSICAL EXAMINATION


VOLUME : 10 ML.
SPECIFIC GRAVITY : 1.012
COLOUR : PALE YELLOW.
APPEARANCE : CLEAR.
TURBIDITY : ABSENT.
SEDIMENT : ABSENT.
REACTION : ACIDIC.

CHEMICAL EXAMINATION

ALBUMIN : ABSENT.
SUGAR : NIL.
PHOSPHATE : ABSENT.
ACETONE : ABSENT.
BILE SALT : ABSENT.
BILE PIGMENT : NEGATIVE.
UROBILINOGEN : ABSENT.
CHYLE : ABSENT.
HAEMATURIA : ABSENT.

MICROSCOPIC EXAMINATION

EPITHELIAL CELL : 0 - 1 / H.P.F
PUS CELL : 2 - 3 / H.P.F
R.B.C : NIL.
CAST : NIL.
CRYSTAL : NIL.
YEAST : ABSENT.
OTHERS : ABSENT


Swayam Prava Pradhan
Signature
MD Pathologist
Regd. No.9431

N. B. : THIS REPORT IS NOT MEANT FOR MEDICO LEGAL PURPOSE

KAMAPALI - GOILUNDI LINK ROAD, NEAR NANDIGHOSH APARTMENT, BERHAMPUR - 760 004 (ODISHA)

CELL : 9438251721, 9337859729



New
NEELACHALA HOSPITAL

A Promise for Life...

(AN ISO 9001 : 2008 CERTIFIED HOSPITAL)

NAME	AMULYA KU PATRA	Age/Sex	51Yrs/M
Ref. By.	New Neelachala Hospital	EC No.	73190
Sample.Dt.	24-07-2021	Reporting Dt	26-07-2021

LIVER FUNCTION TEST (L.F.T)

TEST	OBSERVED VALUE	UNIT	NORMAL VALUE
Total Protein	6.6	g/dl	5.5 - 8.0
Albumin	4.5	g/dl	3.5 - 5.0
Globulin	2.09	g/dl	2.0 - 3.0
A/G Ratio	2.14		
S.G.O.T	29	IU/L	5 - 40
S.G.P.T	31	IU/L	5 - 50
G.G.T.P	25	mg/dl	15 - 40
Serum Bilirubin (Total)	0.6	mg/dl	0.3 - 1.0
(Direct)	0.2	mg/dl	0.0 - 0.3
(Indirect)	0.4	mg/dl	0.2 - 0.8
Alkaline Phosphate	135	IU/ML	60 - 170

Thyroid Test

TEST	OBSERVED VALUE	UNIT	NORMAL VALUE
T3	0.96	ng/mL	0.6 - 1.81
T4	8.52	ug/dl	4.61 - 14.94
TSH	3.45	IU/ml	0.35 - 5.5

TEST	OBSERVED VALUE	UNIT	NORMAL VALUE
HBA1C	5.2	%	below 6.0%-Normal Value 6.0%-7.0%-Good control 7.0%-8.0%-Fair Control 8.0%-10%-Unsatisfactory Control Above 10%-Poor Control

Swayam Prava Pradhan
Signature
MD Pathologist
Regd. No.9431

N. B. : THIS REPORT IS NOT MEANT FOR MEDICO LEGAL PURPOSE

KAMAPALI - GOILUNDI LINK ROAD, NEAR NANDIGHOSH APARTMENT, BERHAMPUR - 760 004 (ODISHA)
CELL : 9438251721, 9337859729



New

NEELACHALA HOSPITAL

A Promise for Life...

(AN ISO 9001 : 2008 CERTIFIED HOSPITAL)

NAME	AMULYA KU PATRA	Age/Sex	51Yrs/M
Ref. By.	New Neelachala Hospital	EC No.	73190
Sample.Dt.	24-07-2021	Reporting Dt	26-07-2021

HAEMOGRAM REPORT

<u>INVESTIGATION</u>	<u>RESULT</u>	<u>UNIT</u>	<u>NORMAL VALUE</u>
Hb%	13.2	gm%	(11.0 - 15.0 gm%)
TWBC	8400	Cumm	(4500-11000/ Cumm)
TRBC	4.3	Mill	(4.0- 5.5 Mill/ Cumm)
TPC	2.4	Lacs / Cumm	(1.5 - 4.0 Lacs / Cumm)
PCV	43	%	(35- 50%)
MCV	85	fl	(76 - 96 fl)
MCH	30.0	pg	(28 - 32 pg)
MCHC	33.8	%	(28 - 43%)
RDW (CV)	14.5	%	(13 - 16%)
MPV	9.2	fl	(8.0 - 10.5 fl)
PDW	8.9	fl	(8.2 - 10.0 fl)

<u>INVESTIGATION</u>	<u>DIFFERENTIAL COUNT</u>		<u>NORMAL VALUE</u>
	<u>RESULT</u>	<u>UNIT</u>	
Neutrophil	62	%	40 - 70
Eosinophil	05	%	01 - 06
Basophil	00	%	00 - 01
Lymphocyte	29	%	15 - 40
Monocyte	04	%	02 - 10

<u>INVESTIGATION</u>	<u>RESULT</u>	<u>UNIT</u>	<u>NORMAL VALUE</u>
ESR	12	/mm in 1 st hour	05 - 20

Cancer Test

<u>INVESTIGATION</u>	<u>RESULT</u>	<u>UNIT</u>	<u>NORMAL VALUE</u>
Prostate Specific Antigen Test(PSA)-	0.1	ng/ml	0 - 3.5

Swayam Srwva Pradhan
Signature
MD Pathologist
Regd. No.9431

N. B. : THIS REPORT IS NOT MEANT FOR MEDICO LEGAL PURPOSE

KAMAPALI - GOILUNDI LINK ROAD, NEAR NANDIGHOSH APARTMENT, BERHAMPUR - 760 004 (ODISHA)
CELL : 9438251721, 9337859729

Resting ECG Report

Patient Name Mr. AMULYA KUMAR PATRA 51/M

July 24, 2021

Time 12:06:13

QT / QTc: 0.392 / 0.405 Sec

P-QRS-T Axis (-21) (-109) (-45) deg

RR Interval: 0.94 sec

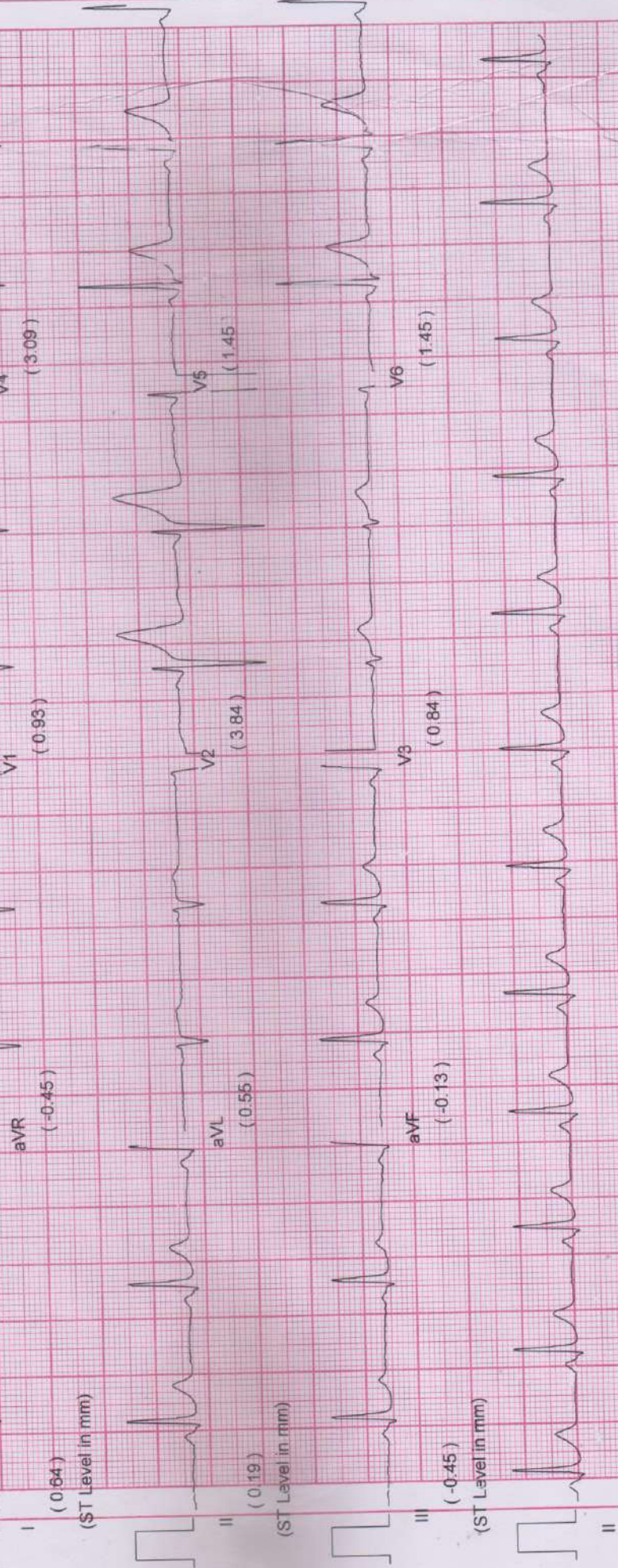
HR : 77 bpm

Bf : 0 / 0 mmHg

PR Interval: 0.04 sec

QRS Duration: 0.140 Sec

Page No. _____



Comments :-

SP
Dr. Susanta Kumar Saikia
 (M.D.) D.M.
 Dr. S.K. Saikia
 (M.D.) D.M. Cardiology
 10mm/mv, 25mm/sec NASAN (C) Simul-C

Date: _____



BHABANI DIAGNOSTIC CENTRE

Goilundi-Kamapalli Road,
Infront of Nandighos Apartment, Brahmapur
Mob. : 9078214639, 7008833151

PATIENT NAME : MR.AMULYA KUAMR PATRA

AGE :54Yrs SEX: M

REFERRED BY : NEELANCHAL HOSPITAL

DATE: 24-Jul-21

ULTRASOUND EXAMINATION OF WHOLE ABDOMEN

LIVER:

Normal in size. Measures 11.7 cm
Normal parenchymal echotexture. No focal lesion or IHBR Dilatation is seen.
P.V—normal.

GALL BLADDER:

Normal in shape and size with anechoic lumen.
Wall thickness is normal. CBD-normal.

PANCREAS:

Normal in size & outline. Parenchymal echo is normal. Pancreatic duct is not dilated.

KIDNEYS:

Rt. Kidney: Normal in shape and size-10.1 x4.0 cm.
Parenchymal echogenicity is normal. Cortical thickness is normal.
Cortico medullary differentiation is well maintained.
Collecting system appears normal.

No evidence of calculus or any pathological abnormalities is seen.
Lt. Kidney: Normal in shape and size 10.2x4.4cm..
Parenchymal echogenicity is normal. Cortical thickness is normal.
Cortico medullary differentiation is well maintained.
Collecting system appears normal.
No evidence of calculus or any pathological abnormalities is seen.

SPLEEN:

Normal in size & measures 8.4 cm
Parenchymal echogenicity appears normal.

URINARY BLADDER:

Normal in outline. Wall thickness is normal. .


PROSTATE:

Normal in size. Vol-13.6cc
Parenchymal echotexture is normal

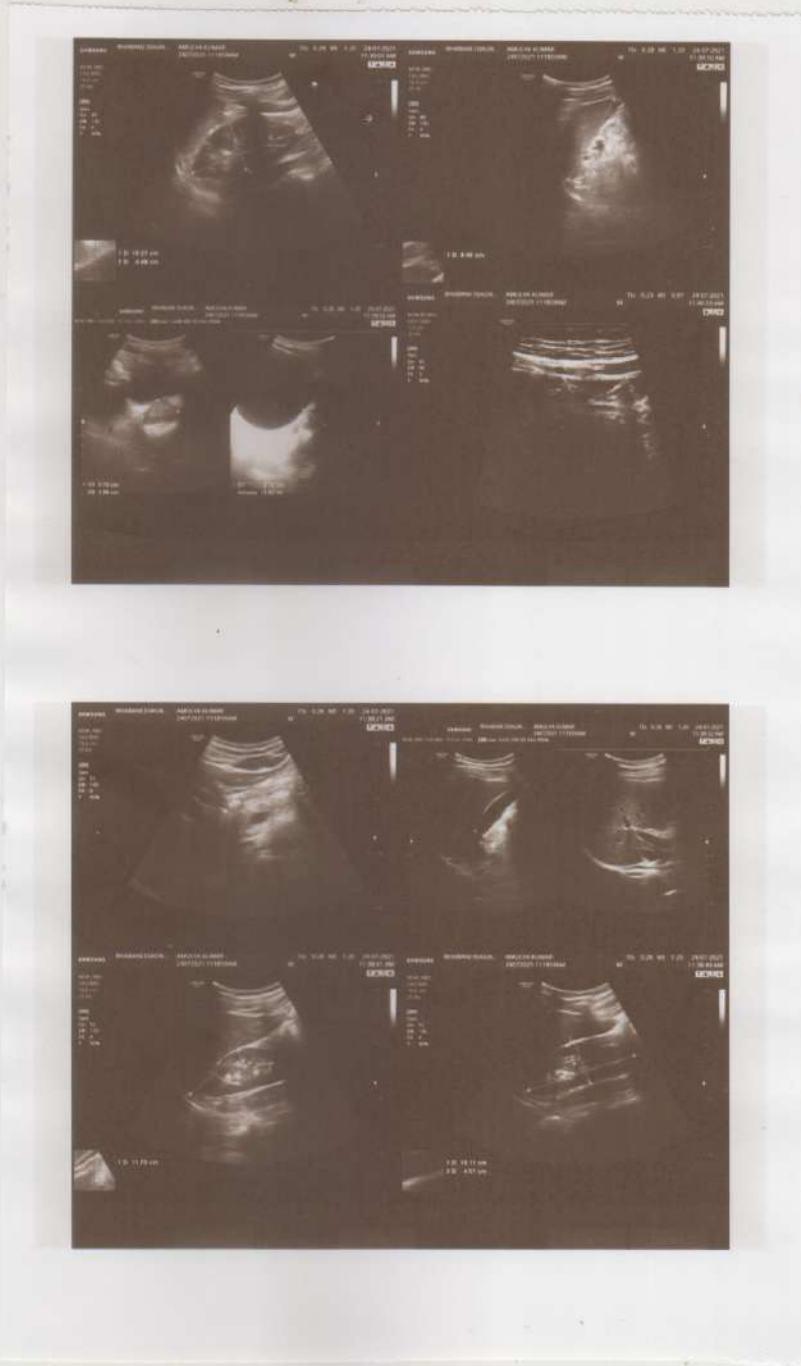
No free fluid is seen in peritoneal cavity.

IMPRESSION

- NO SIGNIFICANT ABNORMALITY IS NOTED IN ABDOMEN & PELVIS.


DR. B. A. SUBUDHI, M.D
RADIOLOGIST

Clinical correlation of this report is a must.



**BHABANI DIAGNOSTIC CENTRE**

Goilundi-Kamapalli Road,
Infront of Nandighos Apartment, Brahmapur
Mob. : 9078214639, 7008833151

PATIENTS NAME: AMULYA KUMAR PATRA
REFERRED BY : NEELANCHAL HOSPITAL

AGE:51 YRS SEX:M
DATE:24-Jul-2021

X-RAY CHEST PA / VIEW

- Tracheas is centre.
- Mediastium is central and normal.
- Both lung fields are clear.
- Pulmonary vasculatures are normal.
- Both hila are normal.
- Both cp angels are normal.
- Cardiac shape size are normal .
- Both domes of diaphragm are normal is position.
- Thoracic cage and soft tissue are normal.

IMPRESSION :NORMAL STUDY.

PROF: S.N.SAHU
CONSULTANT RADIOLOGIST

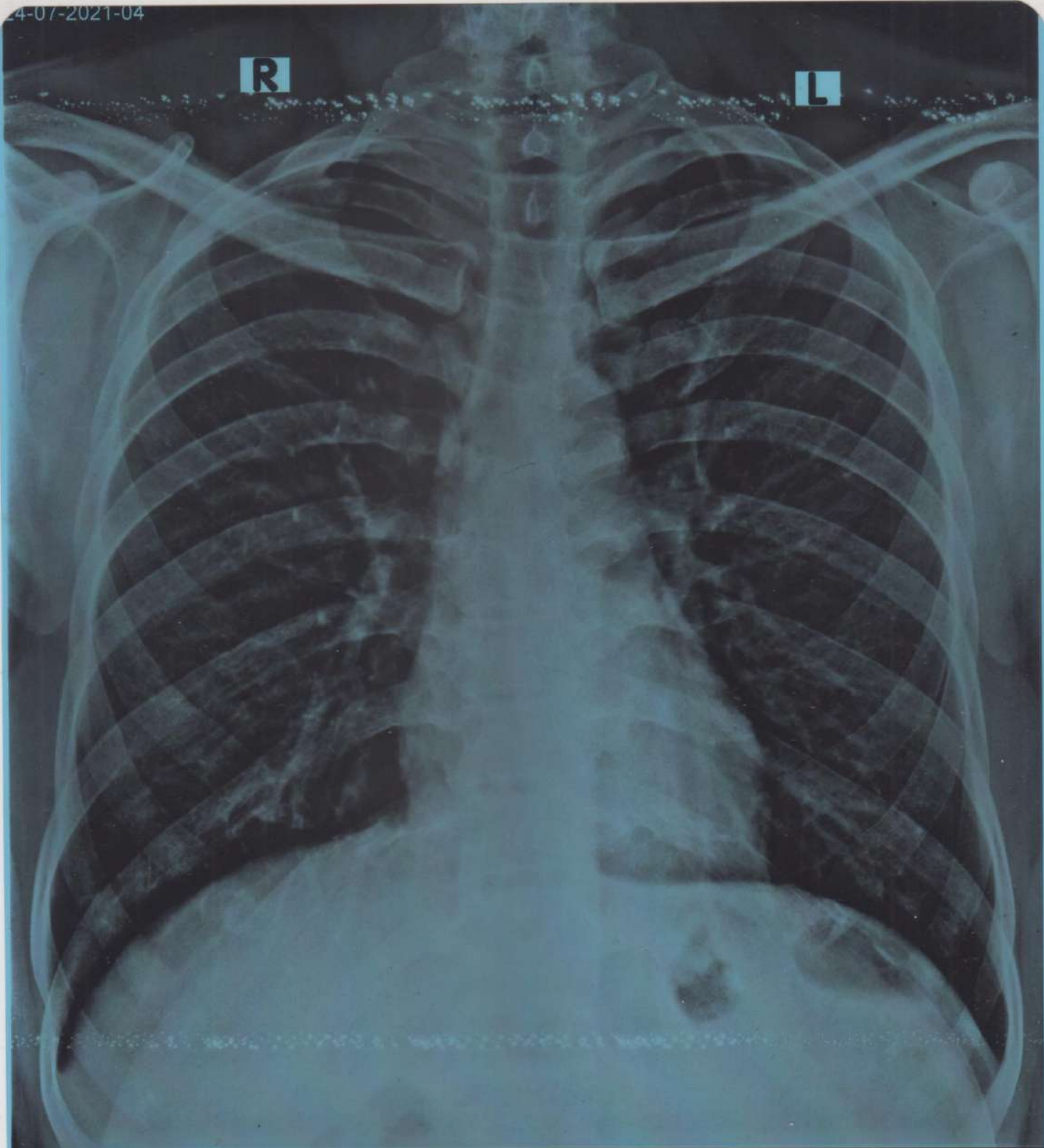
NB. : This report is not valid for medico legal purpose

ULTRA SOUND, DIGITAL X-RAY, VIDEO ENDOSCOPY, ECG, ALL PATHOLOGICAL INVESTIGATION DONE HERE

24-07-2021-04

R

L



SC: 62 %

24-07-2021-04 AMULYA KU PATRA, (M) AGE-51 YRS (NEELANCHAL HOSPITAL)
2021.JUL.24 X -RAY -CHEST-PA VIEW
BHABANI DIAGNOSTIC CENTER, BERHAMPUR