



Panem. Bade

Panem. Bade  
34/11

Date: 10/9/22

**Dr. AJAY KUMAR. G**  
M.S. M.Ch. (Urology)  
Fellow in Paediatric Urology  
Regd. No. 96380  
Consultant Urologist  
SENTINI HOSPITALS PVT. LTD.,  
# 54-15-5, D & C, Beside Vinayaka Theatre  
Ring Road, VIJAYAWADA-520 00P  
Cell: 9666940001

Case for Health package

Use Abd & pelvis:-  
Stc mm renal calculus

Abd  
Plenty of renal calculi  
① On vultum during cross @ day  
(CPM)  
② Syp Alkacabul 56 10ml  
2 months

After 3-6 months  
Kidney package  
699/-  
2000/seat



Panem Bade  
Age: 34 / M

Date: 10/09/22  
Dr: P. Lalitha  
Dr: K. Harish

Bp: - 110/20 mmHg.

patient came for M.H.C.

patient → Had H/O ⊕ loose pain  
1 1/2 month back

aus / NAD

→ Ad

USG abdomen  
SL renal calculi

urologist's  
opion



10-09-2022 09:59:18 AM

ID : 23  
Name :  
Age :

Years :  
Gender : Male

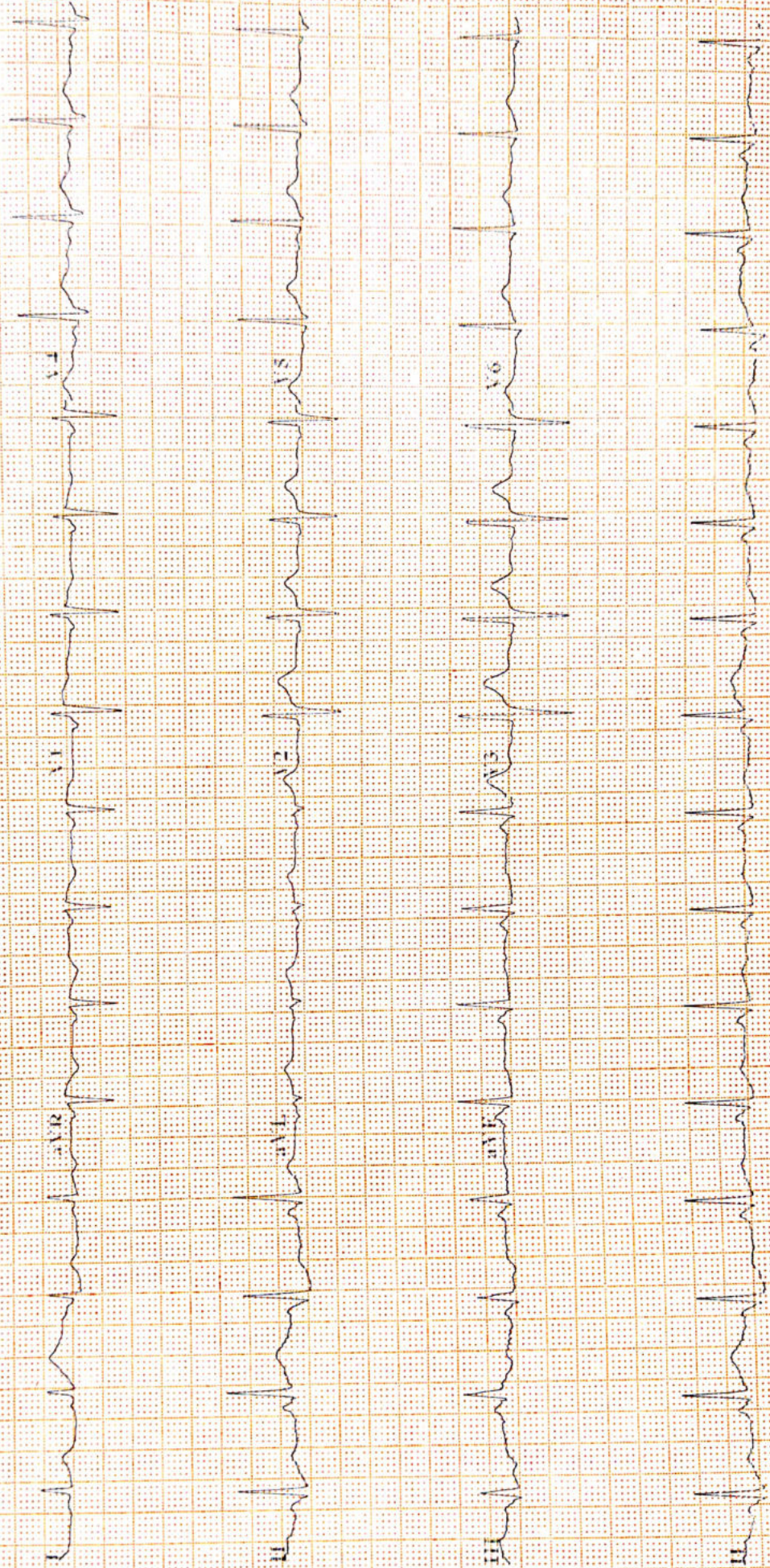
HR : 95 BPM  
P Dur : 93 ms  
PR int : 107 ms  
QRS Dur : 98 ms  
QT/QTc int : 332/418 ms  
P/QRS/T axis : 71/66/-12 °  
RV5/SV1 amp : 1.192/0.849 mV  
RV5+SV1 amp : 2.041 mV  
RV6/SV2 amp : 1.020/0.766 mV

Diagnosis Information:

00: Sinus Rhythm  
401: Short PR Interval

B. Paroxysmal  
Supraventricular

Report Confirmed by:







# Sentini Hospitals (P) Limited

Cardiology Department

## ECHOCARDIOGRAM REPORT

Name : MR P.BADE  
Age : 34 Years  
Date : 10 /09/2022  
Technician: Srinivas/Chetansai

UMR/OP/IP No : 2212416  
Sex : M  
Echo No : 169

MITRAL VALVE : Normal  
AORTIC VALVE : Normal  
TRICUSPID VALVE : Normal  
PULMONARY VALVE : Normal  
AORTA : 27 mm  
LEFT ATRIUM : 34 mm  
LEFT VENTRICLE : Normal  
RWMA : No LV RWMA  
IVS : 11 mm LV IDd : 43 mm  
PW : 10 mm LVIDs : 27 mm  
LV EF : 64 %  
RIGHT ATRIUM : Normal  
RIGHT VENTRICLE : Normal  
PULMONARY ARTERY : Normal  
PULMONARY VEINS : Normal  
IAS : Intact  
IVS : Intact  
PERICARDIUM : Normal  
PERICARDIAL EFFUSION : No Effusion

### DOPPLER STUDY

MITRAL FLOW : E>A  
TRICUSPID FLOW : TRJV- m/s TR Gr: 12 mmHg RVSP: 22 mmHg  
AORTIC JET VELOCITY : 1.3 m/s AV Gr: mmHg  
PULMONARY JET VELOCITY : 0.9 m/s  
COLOUR DOPPLER : 1+ MR 1+ TR No AR No PR  
IVC : Normal  
SVC : Normal  
OTHERS :  
CONCLUSION : Normal Sized Cardiac Chambers,  
No LV RWMA,  
Trivial MR, TR, No PAH,  
Normal LV Systolic Function,  
No Pericardial Effusion,  
No Clot/Vegetation/Masses.

Name :  
Age : Years  
Date : /09/2022

UMR/OP/IP No :  
Sex :  
Echo No : 170

Dr. MADHURI MD.DM  
CONSULTANT CARDIOLOGIST

Dr. A.RAVI KUMAR MD.DM  
CONSULTANT CARDIOLOGIST

Dr. P.V. SIVA PRASAD MD. DM. FESC  
CHIEF CARDIOLOGIST

**Department Of Laboratory**

Date :

<b>Name</b> : Mr. PANEM BADE	<b>Age /Sex</b> : 34 Y(s)/Male
<b>Bill Date</b> : 10-Sep-2022 08:50 AM	<b>UMR No.</b> : UMR2212416
<b>Rept. Dt</b> : 10-Sep-2022 11:25 AM	<b>Bill No.</b> : BIL22018366
<b>Ref By</b> : Dr.GENERAL HEALTH CHECK UP	<b>Result No</b> : 0 / RES22019590

<b>Parameter</b>	<b>Result</b>	<b>Normal Values</b>
<b>LFT(LIVER FUNCTION TEST)</b>		
Total Bilirubin	: 0.4 mg/dl	0.1 - 1.2 mg/dl
Direct Bilirubin	: 0.1 mg/dl	0.0 - 0.3 mg/dl
Indirect Bilirubin	: 0.3 mg/dl	
SGOT	: 21 IU/L	5 - 55 IU/L
SGPT	: 30 IU/L	5 - 55 IU/L
Alkaline Phosphatase	: 75 IU/L	Adult : 35 - 125 IU/L Children : 125 - 330 IU/L
Total Protein	: 6.9 gm/dl	6.0 - 8.3 gm/dl
Albumin	: 3.9 gm/dl	3.2 - 5.0 gm/dl
Globulin	: 3.0 gm/dl	2.5 - 3.0 gm/dl
A / G RATIO	:* 1.3	1.51 - 1.81
<b>CBC (COMPLETE BLOOD COUNT)</b>		
HAEMOGLOBIN	: 15.3 g/dl	12.0 - 17.0 g/dl
Total WBC Count	: 8,600 cells/cumm	4000 - 11000 cells/cumm
<b>DC COUNT</b>		
Neutrophils	: 60 %	50 - 70 %
Lymphocytes	: 35 %	15 - 40 %
Eosinophils	: 03 %	0 - 7 %
Monocytes	: 02 %	0 - 4 %
Basophils	: 00 %	0 - 1 %
RBC COUNT	: 5.1 millions/cumm	4.5 - 6.5 millions/cumm
PLATELET COUNT	: 2.0 lakhscells/cumm	1.5 - 4.0 lakhscells/cumm

\*\*\* End Of Report \*\*\*

  
Lab Tech.

Bio-Chemist

Lab In-Charge

Incharge Pathologist

Correlate Clinically, We use only sterilised disposable syringes & needles.

Discrepancies due to technical or typing errors should be reported within 3 days for correction.

This report is to help you for better management of patient and not valid for medicolegal purpose.

D.No.54-15-5B & 5C, Near Vinayaka Theatre, Ring Road, **Vijayawada - 8**, Krishna Dist. Phone : 0866-6465111 & 2451145  
Reg Off : Plot No. 1229, Road No.60, Jubilee Hills, Hyderabad.



Department Of Laboratory      Date :

<b>Name</b> : Mr. PANEM BADE	<b>Age /Sex</b> : 34 Y(s)/Male
<b>Bill Date</b> : 10-Sep-2022 08:50 AM	<b>UMR No.</b> : UMR2212416
<b>Rept. Dt</b> : 10-Sep-2022 11:25 AM	<b>Bill No.</b> : BIL22018366
<b>Ref By</b> : Dr.GENERAL HEALTH CHECK UP	<b>Result No</b> : 0 / RES22019590

<u>Parameter</u>	<u>Result</u>	<u>Normal Values</u>
------------------	---------------	----------------------

Fasting Blood Sugar	: 95 mg/dl	70 - 110 mg/dl
---------------------	------------	----------------

**RFT (RENAL FUNCTION TEST)**

BLOOD UREA	: 17 mg/dl	13 - 45 mg/dl
Serum Creatinine	: 0.9 mg/dl	0.7 - 1.4 mg/dl

**LIPID PROFILE**

Fasting Blood Sugar	: 95 mg/dl	70 - 110 mg/dl
Total Cholesterol	: 204 mg/dl	150 - 240 mg/dl
Triglycerides	: 178 mg/dl	50 - 200 mg/dl
HDL Cholesterol	: 39 mg/dl	35 - 80 mg/dl
LDL Cholesterol	: 130 mg/dl	80 - 160 mg/dl
VLDL	: 35 mg/dl	10 - 50 mg/dl
Cholesterol / HDL ratio	: 5.2	< 6
LDL / HDL	: 3.3	< 4

Blood Grouping & Rh Typing	: "AB" POSITIVE
----------------------------	-----------------

\*\*\* End Of Report \*\*\*

*Chand*  
Lab Tech.

Bio-Chemist

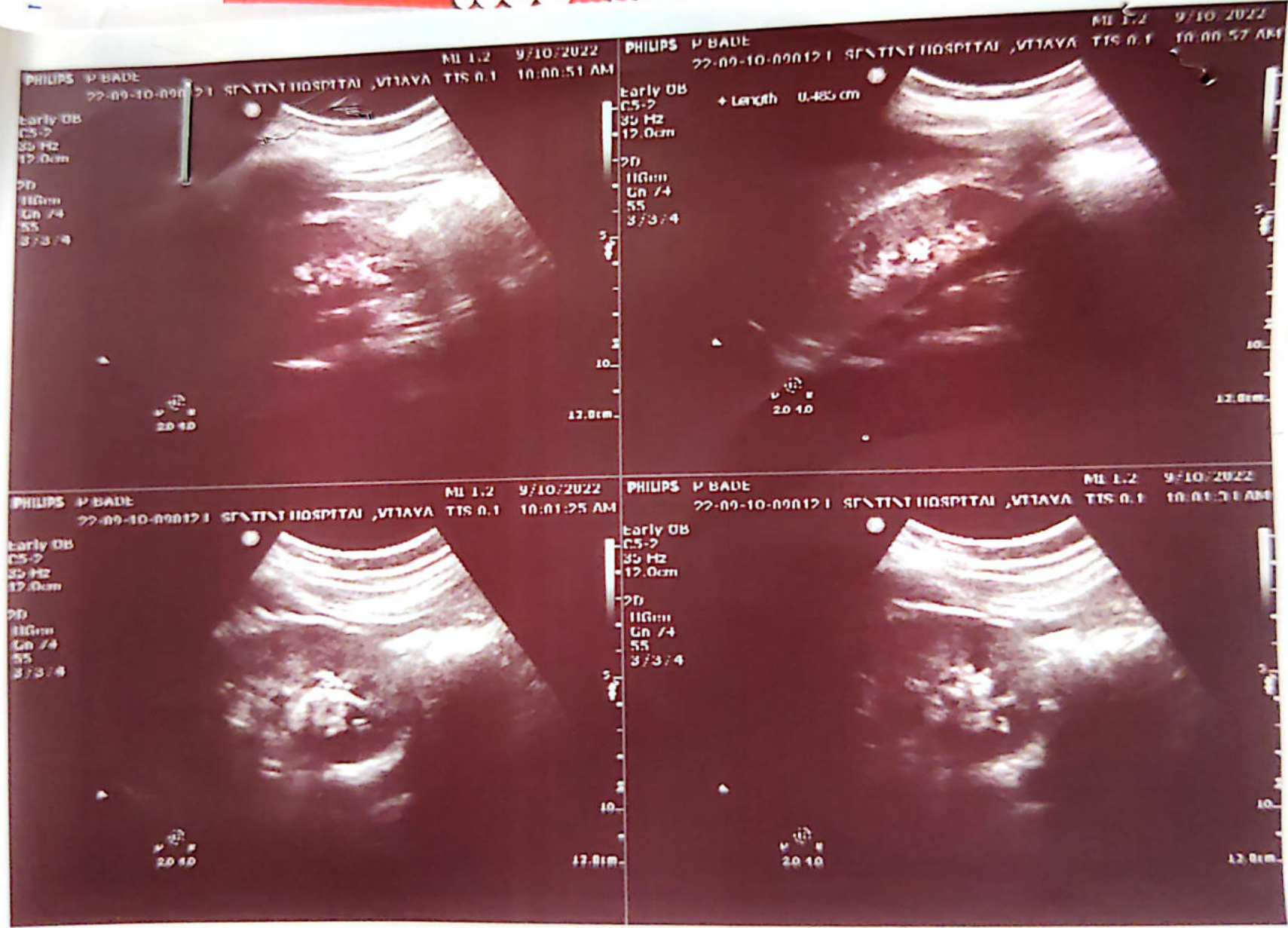
Lab In-Charge

Incharge Pathologist

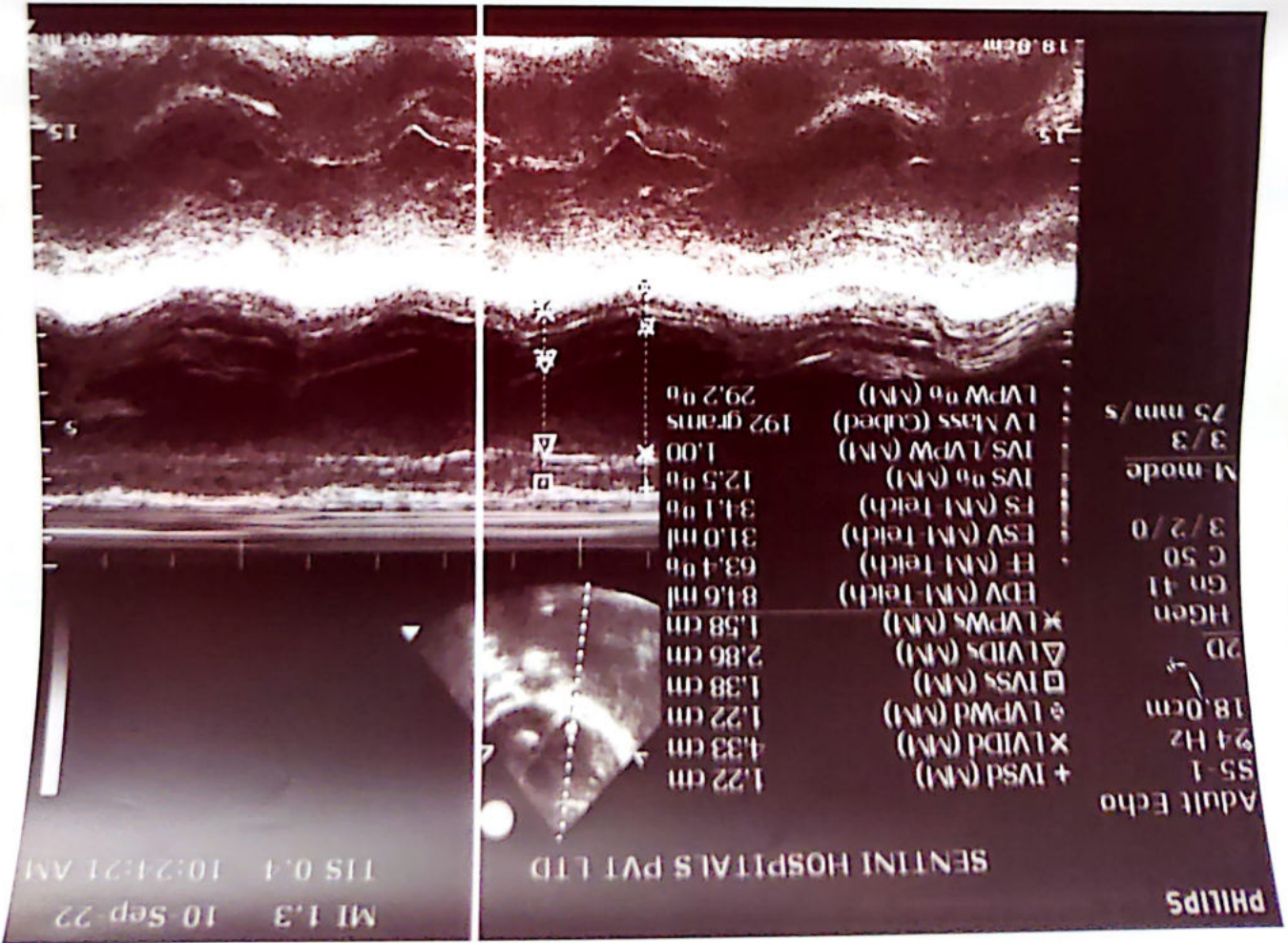
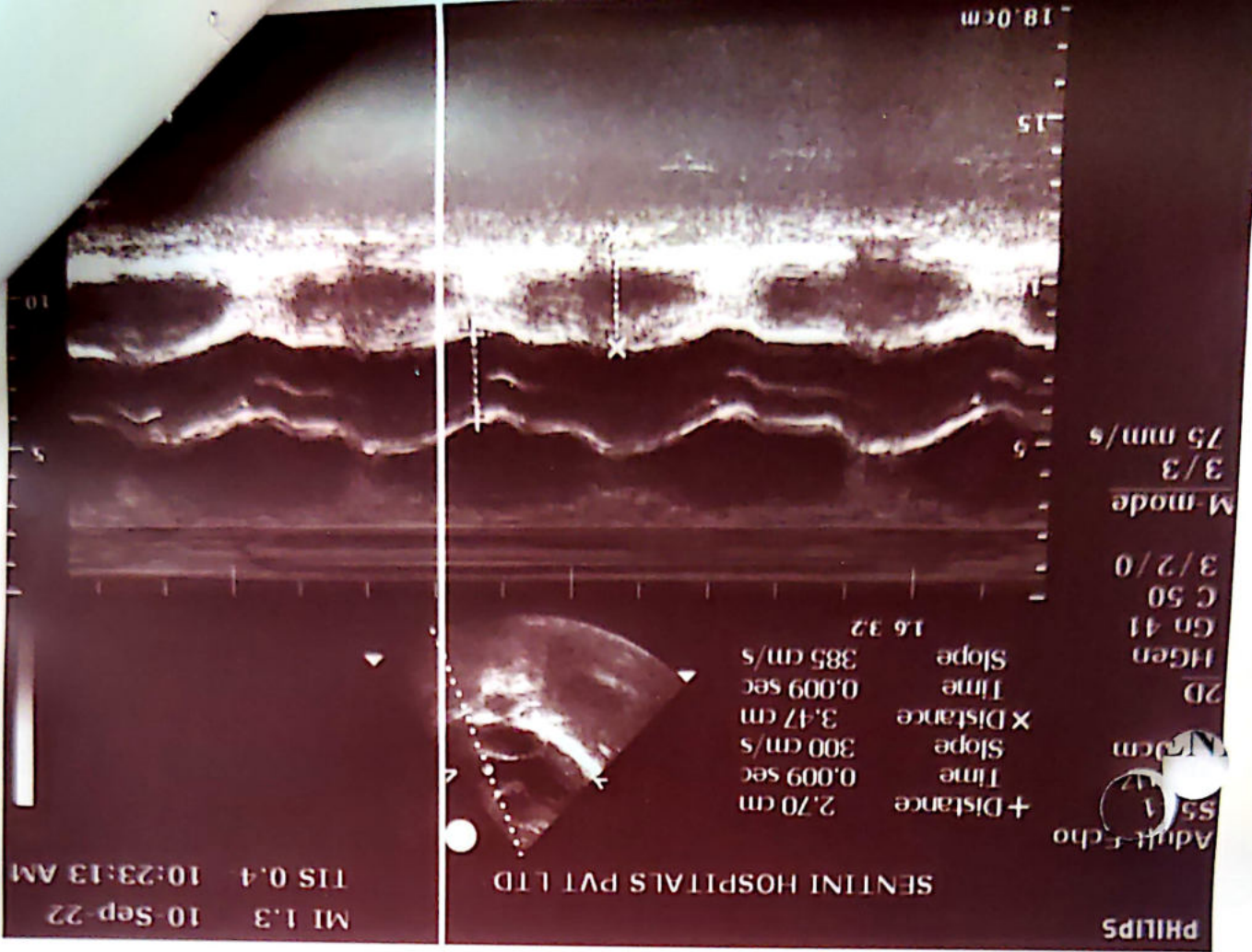




# మూల సిద్ధాంతం











PANEM BADE

Date: 10/09/2022

UMD 202212416

Age/Sex: 34Y/M

Ref :GENERAL

## REAL TIME ULTRASONOGRAPHY OF THE ABDOMEN

**LIVER:** Normal in size, shape and outline. Parenchymal texture normal. No focal cystic or solid mass lesion. No intrahepatic biliary dilatation. Intrahepatic portion of IVC is normal.  
Portal vein is normal. Porta hepatis is normal.

**G. B:** Normal.  
**C.B.D:** Not dilated.

**PANCREAS:** Parenchymal texture normal. No ductal dilatation. No calculi.

**SPLEEN:** Normal in size & echotexture.

**AORTA:** Normal.

**KIDNEYS:** **Right kidney** measures 9.0 x 4.2cm .  
Normal in size, shape and outline. Parenchymal texture normal.  
Corticomedullary differentiation is well made out and is normal.  
Few tiny calculi, one measuring 4 mm in inter pole  
No evidence of Hydronephrosis.

**Left kidney** measures 9.3 x 4.3cm  
Normal in size, shape and outline. Parenchymal texture normal.  
Corticomedullary differentiation is well made out and is normal.  
Two tiny calculi, one measuring 4 mm in lower pole  
No evidence of Hydronephrosis.

**U.B:** Normal.  
**Prostate** : Normal in size & echotexture.

\* No evidence of free fluid / lymphadenopathy.

## IMPRESSION:

➤ BILATERAL RENAL CALCULI.

- For clinical correlation & follow up.

Dr. P.JAYARAM MD RD.,  
[Consultant Radiologist]