

and Lab
Phone: 011-42480101
की परामर्श नहीं की जाती।
की और पीएनडीटी
परामर्श है
disclosure of sex
is not done.
under law.
OF CHILD IS
R PC & PNDT ACT
& PNDT Act Contact:
Delhi, Kanjhawala, Delhi-64
Sector-13, Rohini, Delhi-85

USG ROOM
NO. 1

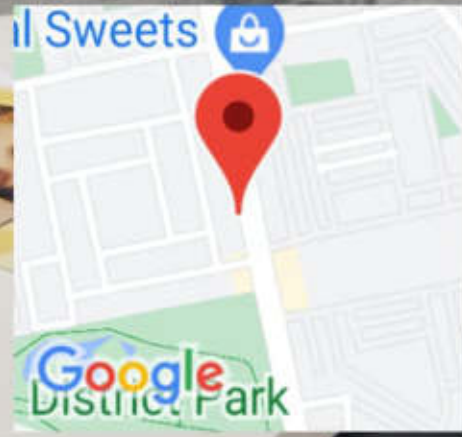ULTRASOUND

No Admission
Without

Dr. P
Ra
MBBS (MA
Imaging Expert in Pa
University of
Total Medicine Founda
REG. M

FACILITIES

- Ultrasound
- 3D/4D/5D
Ultrasound
- Color Doppler
- ECHO
- Digital X-Ray
- Special Tests
IVP, Barium
Studies, HSG
- All Lab Tests
- Hormones
- FNAC
- Histopathology
- TMT, ECG
- Dual/Triple
/Quadruple
Marker Tests
- Timings
8:00 am to
8:00 pm
7 Days Open



47, Mahatma Hansraj Marg, Harsh
Vihar, Pitampura, Delhi, 110034, India

Lat : 28.6935959
Long : 77.1347352

25/11/2023 10:19:49

आयकर विभाग

INCOME TAX DEPARTMENT

ROHIT KUMAR

AJAY KUMAR

04/01/1991

Permanent Account Number

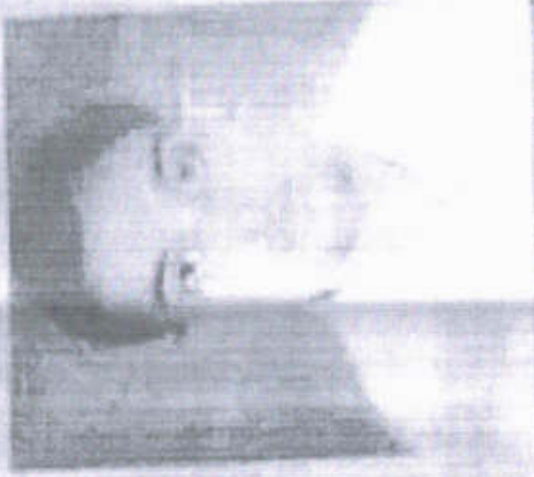CFVPK4810C

Rohit Kumar

Signature



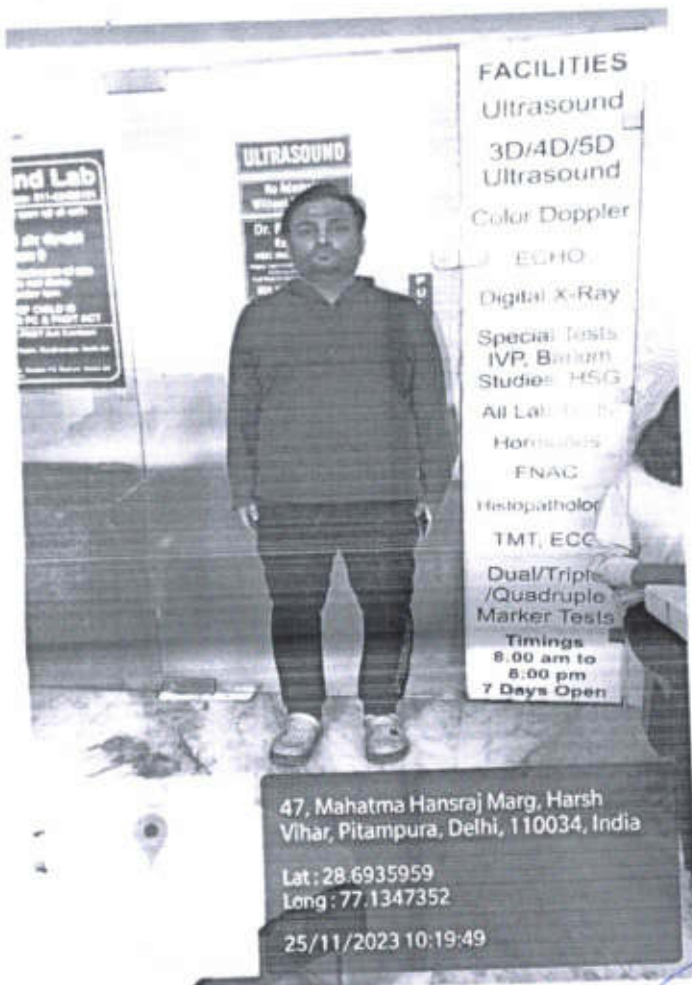
भारत सरकार
GOVT. OF INDIA



05102014

ONEPLUS ULTRASOUND LAB
47 Hiran Vihar Phase 2, Gurgaon
Delhi-110034
Ph. 011-27180101, 9959913051
E-mail onepplus@gmail.com

[Signature]
Dr. KISHOR AGRAWAL
MBBS, MD
Regn. No. DMC-R-1436



FACILITIES

- Ultrasound
- 3D/4D/5D Ultrasound
- Color Doppler
- ECHO
- Digital X-Ray
- Special Tests
- IVP, Barium
- Studies: HSG
- All Lab Tests
- Hormones
- FNAC
- Histopathology
- TMT, ECG
- Dual/Triple/Quadruple Marker Tests
- Timings
- 8.00 am to 8.00 pm
- 7 Days Open

47, Mahatma Hansraj Marg, Harsh Vihar, Pitampura, Delhi, 110034, India

Lat : 28.6935959
Long : 77.1347352

25/11/2023 10:19:49

[Signature]
Dr. NITIN AGARWAL
 MBBS, MD
 Regn. No. DMC-R-1436

[Signature]
ONEPLUS ULTRASOUND LAB
 47 Harsh Vihar, Pitam Pura,
 Delhi-110034
 Ph. 011-42480101, 9599913051
 E-mail: oneplusul@gmail.com



OnePLUS
Ultrasound Lab
— QUALITY FIRST... ALWAYS! —

Dr. Nitin Agarwal

Pathologist & Director
Ex. Sr. Res. MAMC
& Lok Nayak Hospital
Ex. Chief of Lab Dr. Lal Path labs.

Dr. Pooja (Garg) Agarwal

Radiologist & Director
MBBS(MAMC) DMRC (MAMC)
Imaging Expert in Fetal and Maternal Medicine,
University of Barcelona, Spain
Fetal Medicine Foundation ,(UK) Accreditation

Name	: Mr. ROHIT KUMAR	Age/Sex	: 32 YRS/Male
Ref. By	: Dr. MEDIWHEEL	Lab No	: 012311250015
Date	: 25-Nov-2023	Patient ID	: LSHHI125298

ULTRASOUND EXAMINATION---WHOLE ABDOMEN

Liver is normal in size (14.7 cm) and outline with normal altered echopattern. **Diffuse increase in echogenicity of liver parenchyma is noted, suggestive of fatty infiltration (grade II).** No abscess or mass lesion seen. Hepatic veins, portal vein, IVC and aorta are normal. Intrahepatic biliary radicles are not dilated. CBD is normal in caliber.

Gall bladder is well distended with anechoic lumen. Wall thickness is normal.

Both kidneys are normal in size, shape, position, outline and echopattern. Corticomedullary differentiation is maintained. No pelvicalyceal dilation or calculus or mass lesion is seen.

Spleen is normal in size and echotexture. No mass lesion seen.

Pancreas is normal in size, outline and echotexture.

Urinary bladder is normal in shape and position. No evidence of intravesical stone or mass seen.

Prostate is normal in size, shape and echopattern.

Prostate measures 3.5 x 2.5 x 2.5 cm. **Weight of prostate is 12.0 grams.**

No abnormal bowel wall thickening seen in right iliac fossa.

No free fluid seen anywhere in abdomen.

IMPRESSION: Fatty infiltration of liver (grade II) with no hepatomegaly.

DR. POOJA GARG
RADIOLOGIST
REG NO-DMC/R/03398

Type By : pooja

47, Harsh Vihar, Pitampura, Delhi-34 ☎ 011-4248 0101, 9599913051

✉ Email: oneplusul@gmail.com 🌐 www.oneplusul.in

- Clinical correlation is essential for final diagnosis. • If test results are unsatisfactory please contact personally or on phone.
- This report is for perusal of doctors only. • All disputes are subject to Delhi jurisdiction only. • Not for medico legal case.
- All congenital anomalies in a foetus may not be diagnosed in routine obstetric ultrasound.

ONEPLUS ULTRASOUND LAB

47, HARSH VIHAR, PITAMPURA, DELHI- 110034

Mr. ROHIT KUMAR
 Age : 32/M
 Ref. by : ME.DIWHEEL

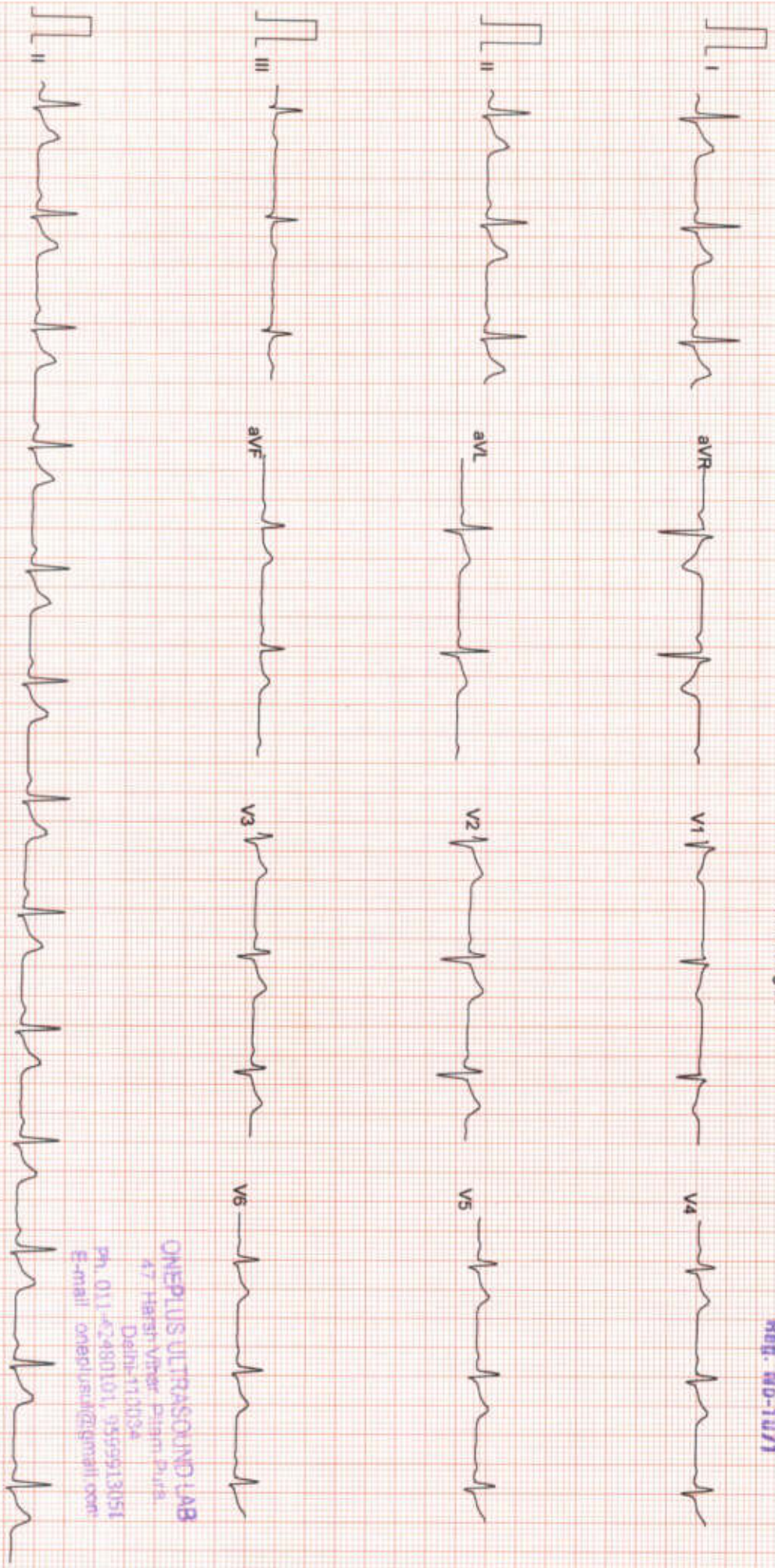
ID : 2381
 HWM : 186/90
 Recorded : 25-11-2023 10:44

BP : 78
 P Axis : 130/84
 QRS Axis : 18 deg
 T Axis : 43 deg
 25 deg

P duration : 73 msec
 PR duration : 130 msec
 QRS duration : 93 msec
 QT Interval : 306 msec
 QTc Interval : 337 msec

Raw ECG (Seq)
 Dr. P.K. AGUPTA
 MBBS, MD
 Reg. No-1071

Unconfirmed Report Reviewed By:
 Cardiologist



Filtered

25mm/sec 10mm/mV

CardCom, INDIA

gk

ONEPLUS ULTRASOUND LAB
 47 Harsh Vihar Pitampura, Delhi-110034
 Ph. 011-43480101, 9559913151
 E-mail: oneplusul@gmail.com

ONEPLUS ULTRASOUND LAB

47, HARSH VIHAR PITAMPURA DELHI 110034

Mr. ROHIT KUMAR

ID : 871

Age/Sex : 32/M
 HIWV : 166/90
 Recorded : 25-11-2023 10:46

Ref. by : MEDIWHEEL
 Indication1 :
 Indication2 :
 Indication3 :

TREADMILL TEST SUMMARY REPORT
 Protocol: BRUCE
 History:
 Medication1 :
 Medication2 :
 Medication3 :

PHASE	PHASE TIME	STAGE TIME	SPEED (Km/Hr.)	GRADE (%)	HR. (BPM)	B.P. (mmHg)	RPP X100	II	ST LEVEL (mm) V2	V5	METS
SUPINE											
STANDING											
STAGE 1	2:59	2:59	2.70	10.00	80	130/84	104	0.8	1.1	0.6	4.80
STAGE 2	5:59	2:59	4.00	12.00	79	130/84	102	0.9	1.1	0.5	7.10
STAGE 3	7:14	1:14	5.40	14.00	116	130/84	150	0.8	1.3	1.0	8.30
PEAK EXER	7:27	1:27			139	144/86	200	0.6	1.0	0.7	
RECOVERY	2:59	2:59	0.00	0.00	166	160/90	265	0.4	0.9	0.4	
					168	160/90	268	0.4	0.7	0.6	8.51
					105	134/84	140	0.2	0.3	0.1	

RESULTS

Exercise Duration 7:27 Minutes
 Max Heart Rate 168 bpm 89 % of target heart rate: 188 bpm
 Max Blood Pressure 160/90 mmHg
 Max Work Load 8.51 METS
 Reason of Termination

Medication for Treadmill test

IMPRESSIONS

Dr. R.K. GUPTA
 MBBS, MD
 Reg. No-1071
 Cardiologist

ONEPLUS ULTRASOUND LAB
 47 Harsh Vihar Pitampura
 Delhi-110034
 Ph. 011-42482107 9599913051
 E-mail oneplus11@gmail.com

gk

Mr. ROHIT KUMAR

I.D. : 871

AGE/SEX : 32/M

RECORDED : 25-11-2023 10:46

RATE : 80 BPM

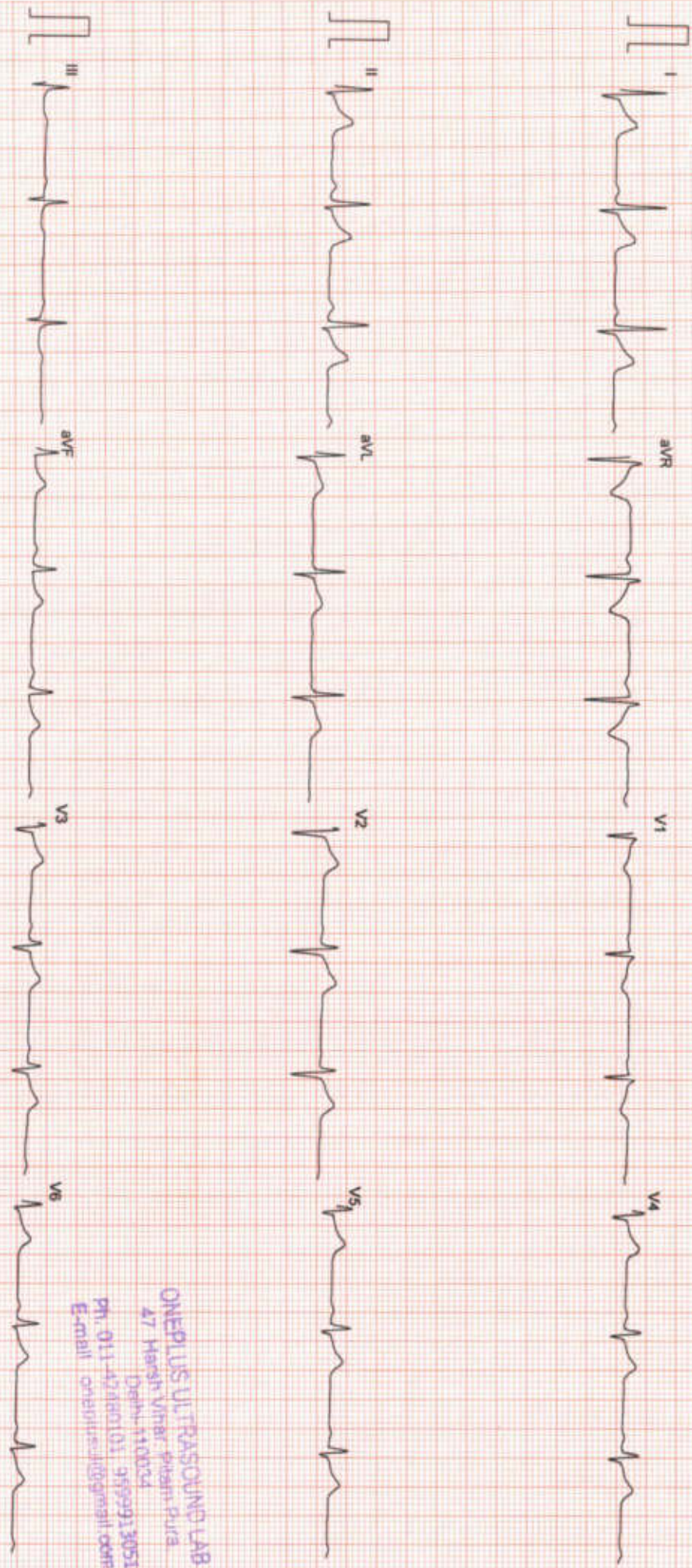
B.P. : 130/84 mmHg

ONEPLUS ULTRASOUND LAB

SUPINE
PRETEST

ST @ 10mm/mV
80ms PostJ

RAW E.C.G.



ONEPLUS ULTRASOUND LAB
47 Hansh Vihar Phase-1, Pura
Delhi-110034
Ph. 011-42480101, 9599913051
E-mail: oneplus@jagdish.com

Filtered

25mm/sec 10mm/mV

CardiCom, INDIA Ph. 091-731-2620740, Telefax: 091-731-2431214

ONEPLUS ULTRASOUND LAB

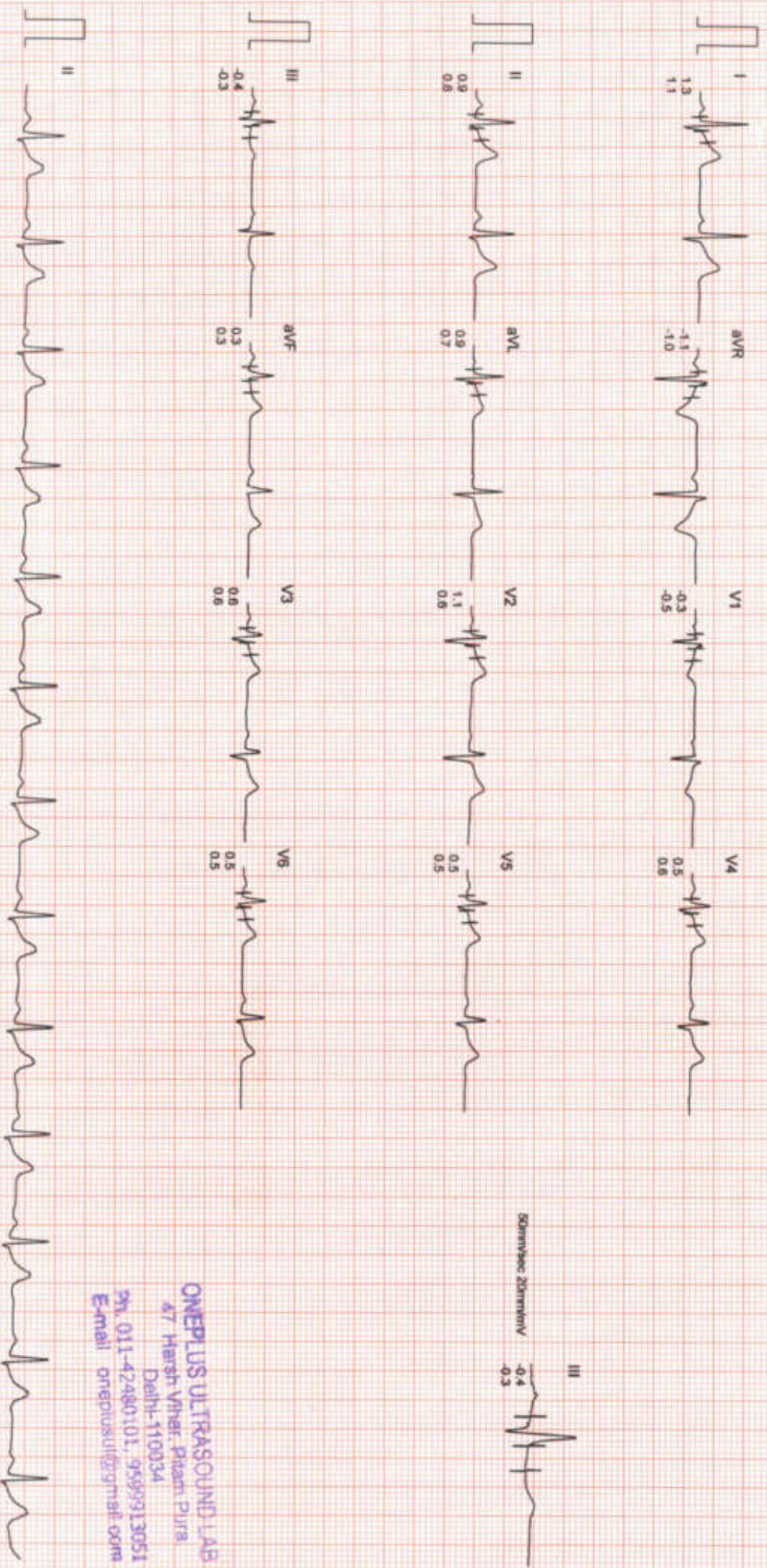
STANDING
PRETEST

ST @ 10mm/mV
80ms PostJ

Mr: ROHIT KUMAR
I.D. : 871
AGE/SEX : 32/M

RATE : 79 BPM
B.P : 130/84 mmHg

LINKED MEDIUM



ONEPLUS ULTRASOUND LAB
A7 Harsh Vihar, Pitam Pura,
Delhi-110034
Ph. 011-42480101, 9599913051
E-mail: oneplusul@gmail.com

Filtered Computer Corrected Baseline

25mm/sec 10mm/mV

CardCom, INDIA Ph. 091-731-2620740, TeleFax: 091-731-2431214

ONEPLUS ULTRASOUND LAB

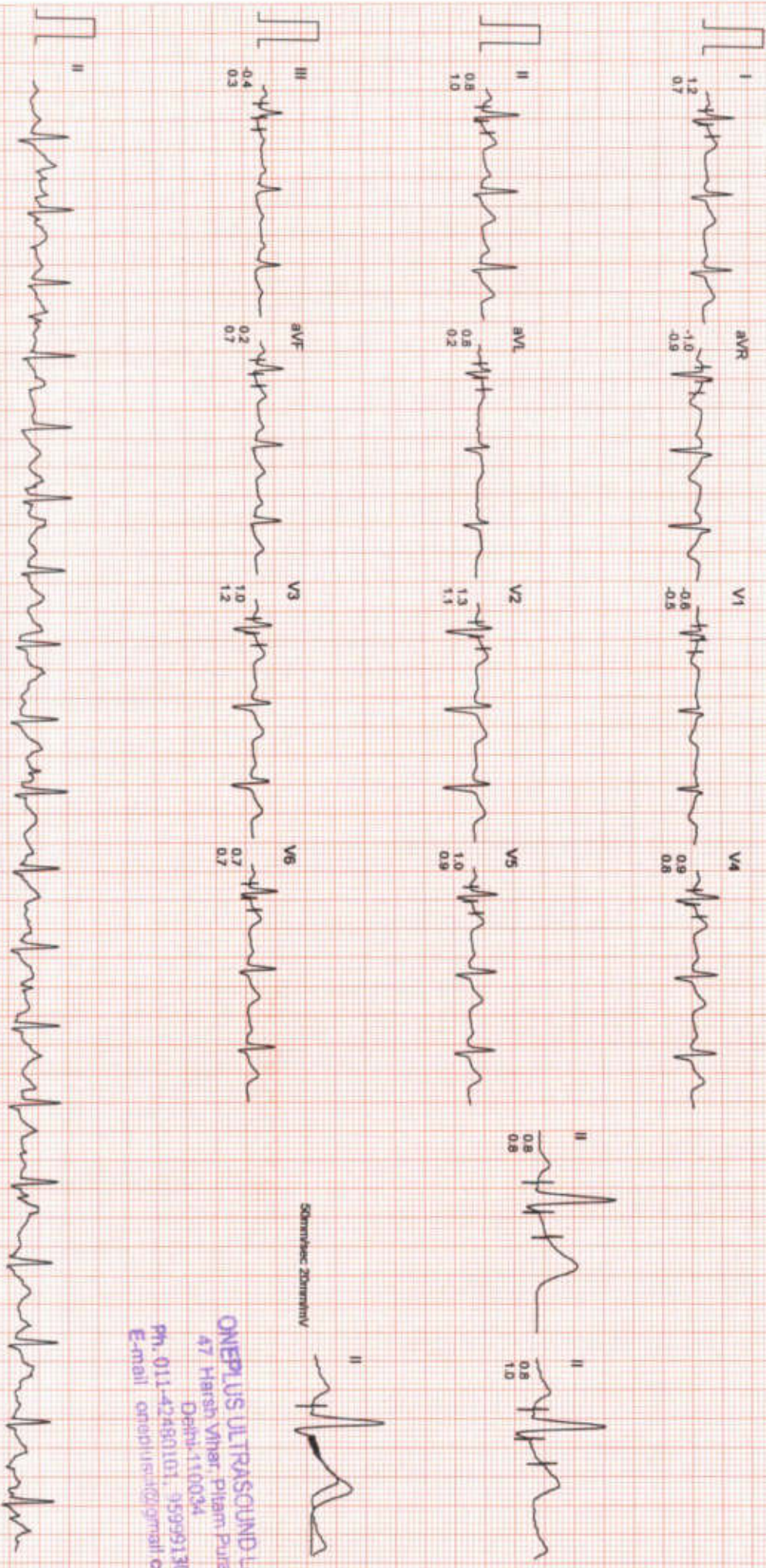
Mr. ROHIT KUMAR
I.D. : 871
AGE/SEX : 32/M
RECORDED : 25-11-2023 10:46

RATE : 116 BPM
B.P. : 130/84 mmHg

BRUCE
EXERCISE 1
PHASE TIME : 2:59
STAGE TIME : 2:59

ST @ 10mm/mV
80ms PostJ
SPEED : 2.7 Km./Hr.
GRADE : 10.0 %

LINKED MEDIAN



ONEPLUS ULTRASOUND LAB
47 Harsih Vihar, Pitampura,
Delhi-110034
Ph. 011-42481101, 9599913051
E-mail onedpl@rediffmail.com

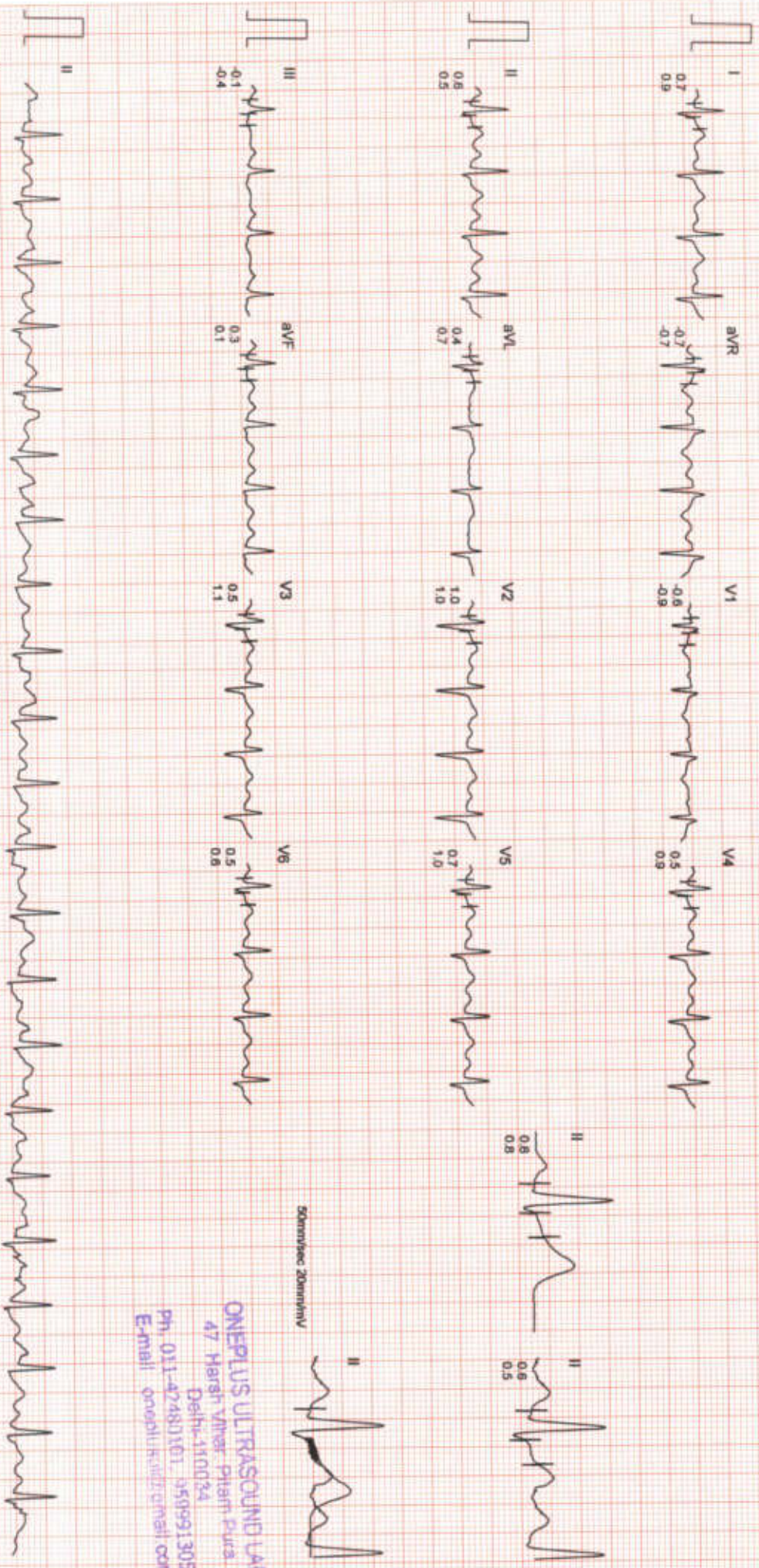
ONEPLUS ULTRASOUND LAB

Mr. ROHIT KUMAR
I.D. : 871
AGE/SEX : 32/M
RECORDED : 25-11-2023 10:46

BRUCE
EXERCISE 2
PHASE TIME : 5:59
STAGE TIME : 2:59

ST @ 10mm/mV
80ms PostJ
SPEED : 4.0 Km./Hr.
GRADE : 12.0 %

LINKED MEDIAN



30mm/sec 20mm/mV

ONEPLUS ULTRASOUND LAB
47 Harsh Vihar Phase Pura
Delhi-110034
Ph. 011-42480101, 9609913051
Email: onepplusul@gmail.com

ONEPLUS ULTRASOUND LAB

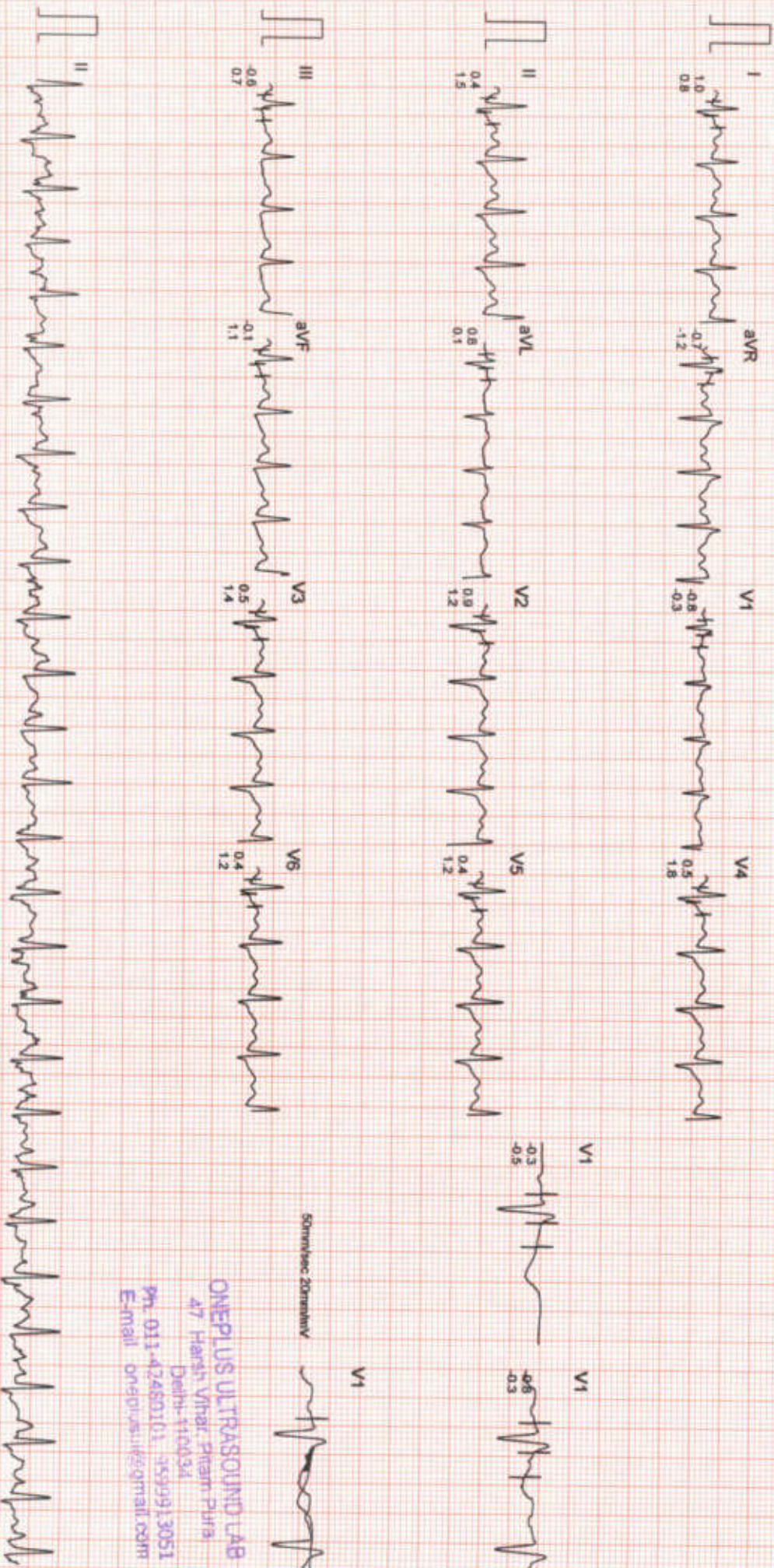
Mr. ROHIT KUMAR
I.D. : 871
AGE/SEX : 32M
RECORDED : 25-11-2023 10:46

RATE : 166 BPM
B.P. : 160/90 mmHg

BRUCE
EXERCISE 3
PHASE TIME : 7:14
STAGE TIME : 1:14

ST @ 10mm/mV
80ms PostJ
SPEED : 5.4 Km/Hr.
GRADE : 14.0 %

LINKED MEDIUM



ONEPLUS ULTRASOUND LAB
47 Hansh Vihar Pitam Pura,
Delhi-110034
Ph: 011-42480101-3599913051
E-mail: onepplusul@gmail.com

ONEPLUS ULTRASOUND LAB

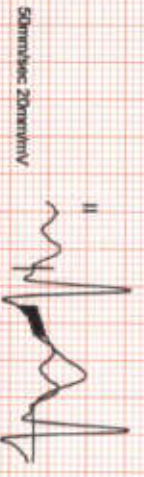
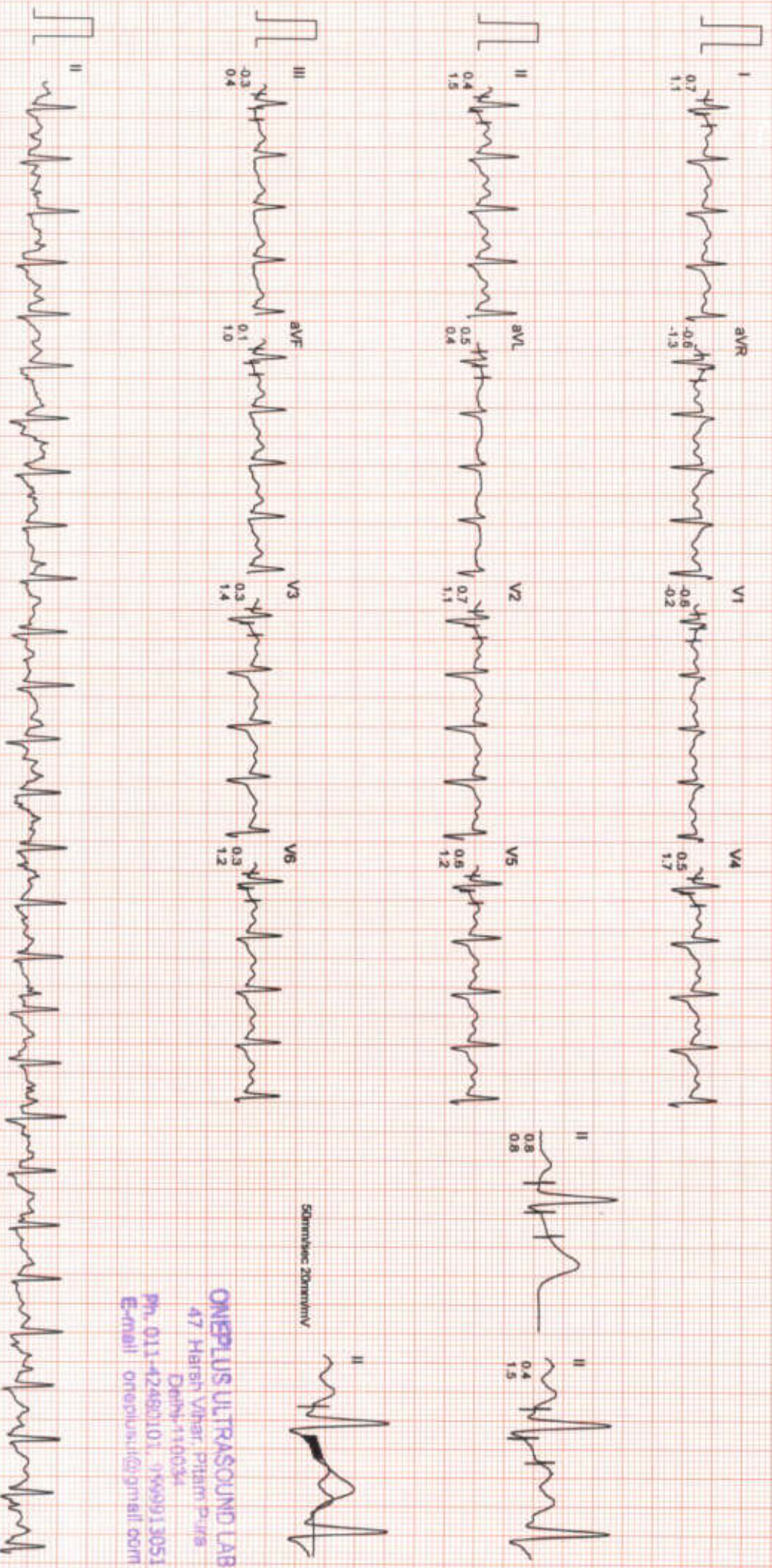
Mr. ROHIT KUMAR
 I.D. : 871
 AGE/SEX : 32/M
 RECORDED : 25-11-2023 10:46

RATE : 168 BPM
 B.P. : 160/90 mmHg

BRUCE
 PEAK EXER
 PHASE TIME : 7:27
 STAGE TIME : 1:27

ST @ 10mm/mV
 80ms PostJ
 SPEED : 5.4 Km./Hr.
 GRADE : 14.0 %

LINKED MEDIAN



50mm/sec 20mm/mV

ONEPLUS ULTRASOUND LAB
 47 Harish Vihar, Pitam Pura
 Delhi-110034
 Ph: 011-42480101, 0999913051
 E-mail: oneplus1@gmail.com

ONEPLUS ULTRASOUND LAB

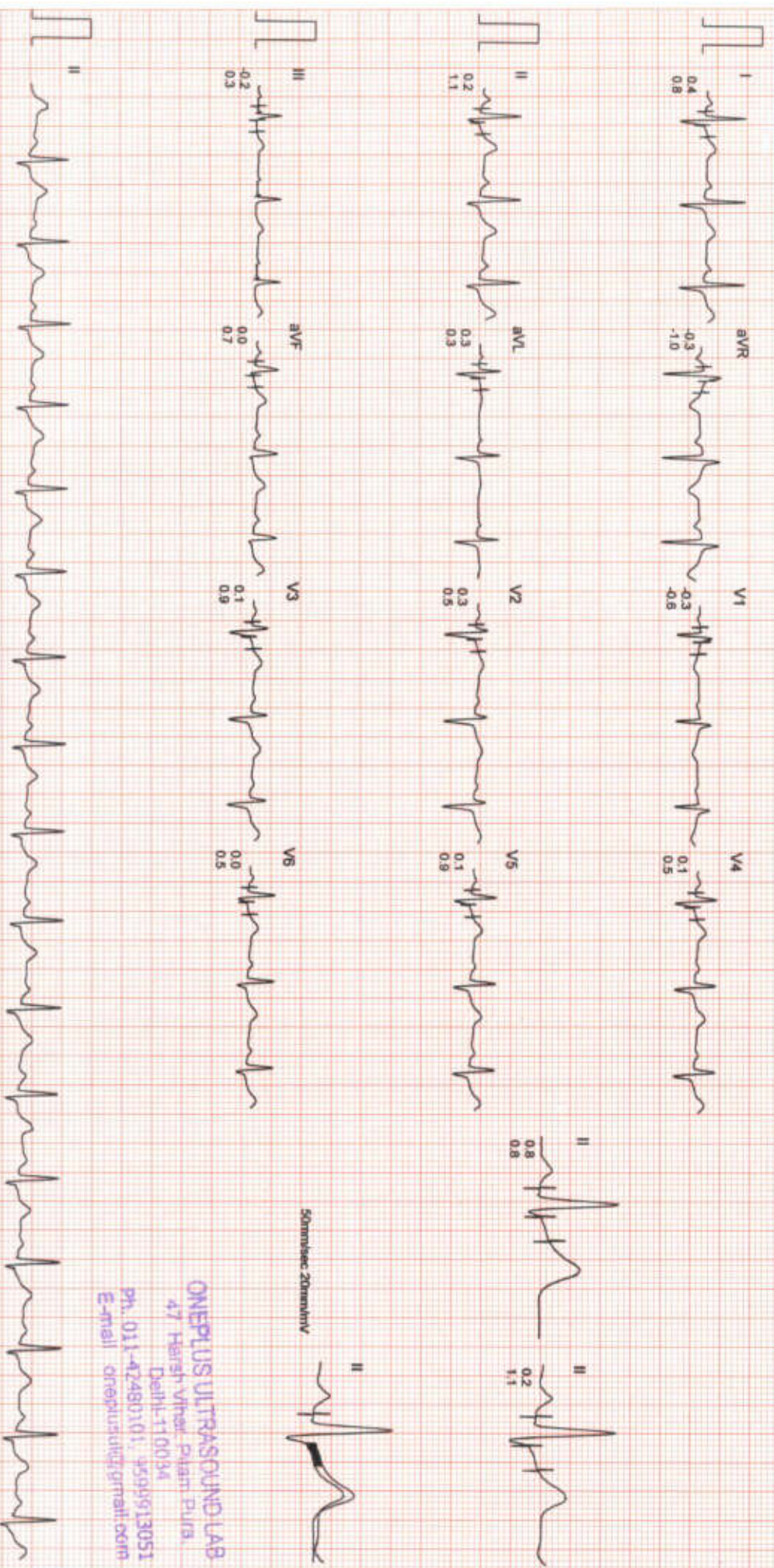
Mr. ROHIT KUMAR
I.D. : 871
AGE/SEX : 32/M
RECORDED : 25-11-2023 10:46

RATE : 105 BPM
B.P. : 134/84 mmHG

BRUCE
RECOVERY
PHASE TIME : 2:59

ST @ 10mm/mV
80ms PostJ
SPEED : 0.0 Km./Hr.
GRADE : 0.0 %

LINKED MEDIAN



ONEPLUS ULTRASOUND LAB
47 Harsih Vihar, Pujan Pura,
Delhi-110034
Ph. 011-47480101, 4599913051
E-mail oneplusul@gmail.com

Filtered Computer Connected Baseline




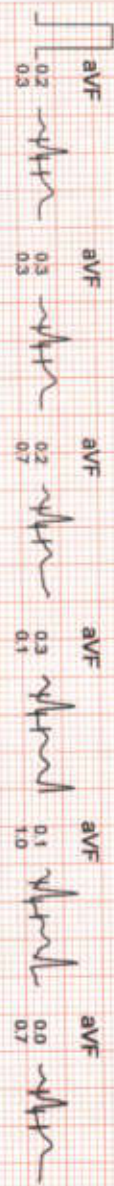
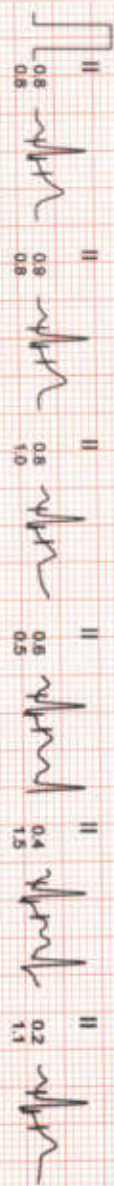
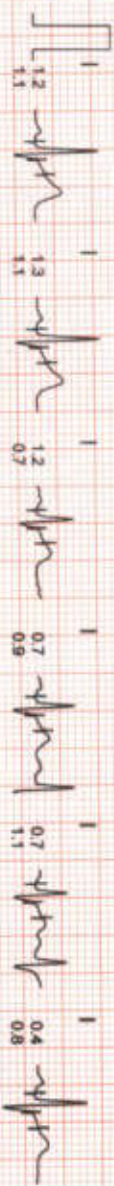
25mm/sec 10mm/mV

CardiCom, INDIA Ph.-091-731-2620740, TeleFax:091-731-2431214

ONEPLUS ULTRASOUND LAB

AVG E.C.G.

STAGE	HR	BP	SpO2
SUPINE	80 bpm	130/84	98%
STANDING	79 bpm	130/84	98%
STAGE 1	116 bpm	130/84	98%
STAGE 2	139 bpm	144/96	98%
PEAK EXERCISE	168 bpm	160/90	98%
RECOVERY	105 bpm	134/84	98%



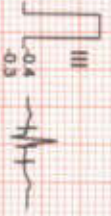
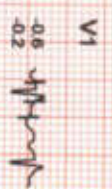
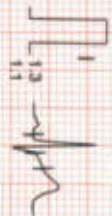




ONEPLUS ULTRASOUND LAB
 47 HARIJAN VIHAR PHASE PURE,
 DELHI-110034
 Ph. 011-42480101, 9599913051
 E-mail onepplus@icd@gmail.com

STANDING
0.0kmph
0.0%
79 bpm
B.P. 130/84
80mm Postu

PEAK EXERCISE
5.4kmph
14.0%
168 bpm
B.P. 160/90
80mm Postu

STANDING
0.0kmph
0.0%
79 bpm
B.P. 130/84
80mm Postu

PEAK EXERCISE
5.4kmph
14.0%
168 bpm
B.P. 160/90
80mm Postu



ONEPLUS ULTRASOUND LAB
A7 HSRNH Vihar Pitam Purva,
Gurgaon-110034
Ph: 011-42480101, 9539913051
Email: onepplus@gmail.com

Name - Rohit Kumar Age - 39Y IM 25/11/2023

I Report among not submitted
Steel leg Health check up.

gk

ONEPLUS ULTRASOUND LAB
47, Harsh Vihar, Pitampura,
Delhi-110034
Ph. 011-42480101, 9599913051
E-mail: oneplusul@gmail.com





OnePLUS Ultrasound Lab

Dr. Nitin Agarwal

Pathologist & Director
Ex. Sr. Res. MAMC
& Lok Nayak Hospital
Ex. Chief of Lab Dr. Lal Path labs.

Dr. Pooja (Garg) Agarwal

Radiologist & Director
MBBS(MAMC) DMRC (MAMC)
Imaging Expert in Fetal and Maternal Medicine,
University of Barcelona, Spain
Fetal Medicine Foundation, (UK) Accreditation



NAME:QUALITY FIRST... ALVY ROHIT KUMAR	Barcode No	:10158928
AGE/GENDER :32 YRS/Male	SPECIMEN DATE	:25/Nov/2023 10:14AM
PATIENT ID :125298	SPECIMEN RECEIVED	:25/Nov/2023 10:45AM
REFERRED BY :Dr. MEDIWHEEL	REPORT DATE	:25/Nov/2023 01:01PM
CENTRE NAME :ONEPLUS ULTRASOUND LAB	LAB NO.	:012311250015

Test Name	Result	Unit	Ref. Range
-----------	--------	------	------------

HAEMATOLOGY

MediWheel Health checkup < 40 Male

Sample Type:EDTA Blood

ESR Modified Westergrens Method	10	mm in 1st hr	upto 10.4
---	----	--------------	-----------

Comments:

Increased

- In most infections, anaemias, injection of foreign proteins, auto-immune disorders, conditions accompanied by hyperglobunemia and hypercholesterolaemia.
- A rising ESR suggests a progressive disease.

Decreased

- In polycythemia, congestive heart failure.

Glycosylated Hemoglobin (HbA1c) HPLC	5.3	%	Non Diabetic adults <5.7 Prediabetic (at risk) 5.7-6.4 Diabetes >6.4
--	-----	---	--

Estimated average blood glucose (eag) CALCULATED	105		
--	-----	--	--

Reference range (mg/dl):

90 - 120:Excellent control, 121 - 150:Good Control, 151 - 180:Average Control, 181 - 210:Action Suggested

>211:Panic value

BLOOD GROUP (ABO)

Forward and Reverse grouping (Slide & Tube)

Rh typing	POSITIVE
------------------	----------

NOTE :

- * Apart from major A,B,H antigens which are used for ABO grouping and Rh typing, many minor blood group antigens exist. Agglutination may also vary according to titre of antigen and antibody.
- * So before transfusion, reconfirmation of blood group as well as cross-matching is needed.
- * Presence of maternal antibodies in newborns, may interfere with blood grouping.
- * Auto agglutination (due to cold antibody, falciparum malaria, sepsis, internal malignancy etc.) may also cause erroneous result.

CBC

Haemoglobin	15.5	g/dl	13.0-17.0
-------------	------	------	-----------

Checked By.

DR. NITIN AGARWAL
MBBS,MD(PATHOLOGIST)

Dr. NITIN AGARWAL
M B B S . MD (Path)
DMC/R/01436

47, Harsh Vihar, Pitampura, Delhi-34 ☎ 011-4248 0101, 9599913051

✉ Email: oneplusul@gmail.com 🌐 www.oneplusul.in

- Clinical correlation is essential for final diagnosis. • If test results are unsatisfactory please contact personally or on phone.
- This report is for perusal of doctors only. • All disputes are subject to Delhi jurisdiction only. • Not for medico legal case.
- All congenital anomalies in a foetus may not be diagnosed in routine obstetric ultrasound.



OnePLUS Ultrasound Lab

Dr. Nitin Agarwal

Pathologist & Director
Ex. Sr. Res. MAMC
& Lok Nayak Hospital
Ex. Chief of Lab Dr. Lal Path labs.

Dr. Pooja (Garg) Agarwal

Radiologist & Director
MBBS(MAMC) DMRC (MAMC)
Imaging Expert in Fetal and Maternal Medicine,
University of Barcelona, Spain
Fetal Medicine Foundation, (UK) Accreditation



NAME/QUALITY FIRST... AL	MYROHIT KUMAR	Barcode No	:10158928
AGE/GENDER	:32 YRS/Male	SPECIMEN DATE	:25/Nov/2023 10:14AM
PATIENT ID	:125298	SPECIMEN RECEIVED	:25/Nov/2023 10:45AM
REFERRED BY	:Dr. MEDIWHEEL	REPORT DATE	:25/Nov/2023 01:01PM
CENTRE NAME	:ONEPLUS ULTRASOUND LAB	LAB NO.	:012311250015

Test Name	Result	Unit	Ref. Range
Non cyanide Hb analysis			
Total Leucocyte Count	9900	/cumm	4000-10000
Electrical Impedance			
Differential leucocyte count			
Neutrophils	60.6	%	40-80
Electrical Impedance & Microscopic			
Lymphocyte	34.60	%	20-40
Electrical Impedance & Microscopic			
Monocytes	2.00	%	2-10
Electrical Impedance & Microscopic			
Eosinophils	2.0	%	1-6
Electrical Impedance & Microscopic			
Basophils	0.8	%	0-2
Electrical Impedance & Microscopic			
RBC Count	5.10	million/cumm	4.5 - 5.5
Electrical Impedance			
Hematocrit(PCV)	45.7	%	40-50
Flow Cytometry			
MCV	90.3	fl	83-101
Calculated			
MCH	30.6	pg	27-32
Calculated			
MCHC	33.9	g/dL	31.5-34.5
Calculated			
RDW-CV	14.7	%	11.4-14.0
Calculated			
Platelet count	178000	/cumm	150000-410000
Electrical Impedance			

BIOCHEMISTRY

Sample Type:Fluoride F

Blood sugar fasting	95	mg/dl	70-100 mg/dl
----------------------------	----	-------	--------------

GOD-POD

Sample Type:Serum

Bun (blood urea nitrogen)	10.70	mg/dl	8.9-21.6
-----------------------------------	-------	-------	----------

CALCULATED

Uric Acid, serum	4.6	mg/dl	3.5-7.2
-------------------------	-----	-------	---------

Uricase- PAP

Checked By.

DR. NITIN AGARWAL
MBBS, MD(PATHOLOGIST)
DMC/R/01436



OnePLUS Ultrasound Lab

Dr. Nitin Agarwal

Pathologist & Director
Ex. Sr. Res. MAMC
& Lok Nayak Hospital
Ex. Chief of Lab Dr. Lal Path labs.

Dr. Pooja (Garg) Agarwal

Radiologist & Director
MBBS(MAMC) DMRC (MAMC)
Imaging Expert in Fetal and Maternal Medicine,
University of Barcelona, Spain
Fetal Medicine Foundation (UK) Accreditation



NAME QUALITY FIRST... AL... NAME	ALYAS ROHT KUMAR	Barcode No	:10158928
AGE/GENDER	:32 YRS/Male	SPECIMEN DATE	:25/Nov/2023 10:14AM
PATIENT ID	:125298	SPECIMEN RECEIVED	:25/Nov/2023 10:45AM
REFERRED BY	:Dr. MEDIWHEEL	REPORT DATE	:25/Nov/2023 01:01PM
CENTRE NAME	:ONEPLUS ULTRASOUND LAB	LAB NO.	:012311250015

Test Name	Result	Unit	Ref. Range
Creatinine, serum Enzymatic	0.9	mg/dl	0.71-1.16
LFT(LIVER FUNCTION TEST)			
Bilirubin Total Modified tab	0.41	mg/dl	0.2-1.1
Bilirubin Conjugated	0.21	mg/dL	0.11-0.42
Bilirubin Unconjugated Calculated	0.2	mg/dl	up to 0.7
SGOT (AST) Tris buffer	34	U/L	0-46
SGPT (ALT) Tris buffer	56	U/L	0-49
Alkaline phosphatase Amp buffer	86	U/L	40-129
GAMMA GT Szasz Method	27	U/L	10-45
Total Protein Biuret	6.7	gm/dl	6.60 - 8.70
Albumin serum BCG	3.8	g/dL	3.0-5.2
Globulin Calculated	2.90	gm/dl	1.8-3.4
Albumin/Globulin Ratio Calculated	1.31		1.10 - 2.50
LIPID PROFILE			
Cholesterol CHOD-PAP	216	mg/dl	50-200
Triglycerides GPO-PAP	106	mg/dL	25-150
HDL Cholesterol Selective Inhibition	47	mg/dL	40 - 60
LDL cholesterol Calculated	148	mg/dL	<100
VLDL cholesterol Calculated	21.2	mg/dL	5-40
Cholesterol/HDL Ratio Calculated	4.6		Low Risk 3.3-4.97 Average Risk 4.4-7.1

Checked By.

DR. NITIN AGARWAL
MBBS, MD (PATHOLOGIST)
M B B S . MD (Path)
DMC/R/01436

Page 3 of 6

47, Harsh Vihar, Pitampura, Delhi-34 ☎ 011-4248 0101, 9599913051

✉ Email: oneplusul@gmail.com 🌐 www.oneplusul.in

- Clinical correlation is essential for final diagnosis. • If test results are unsatisfactory please contact personally or on phone.
- This report is for perusal of doctors only. • All disputes are subject to Delhi jurisdiction only. • Not for medico legal case.
- All congenital anomalies in a foetus may not be diagnosed in routine obstetric ultrasound.



OnePLUS Ultrasound Lab

Dr. Nitin Agarwal

Pathologist & Director
Ex. Sr. Res. MAMC
& Lok Nayak Hospital
Ex. Chief of Lab Dr. Lal Path labs.

Dr. Pooja (Garg) Agarwal

Radiologist & Director
MBBS(MAMC) DMRC (MAMC)
Imaging Expert in Fetal and Maternal Medicine,
University of Barcelona, Spain
Fetal Medicine Foundation, (UK) Accreditation



NAME	QUALITY FIRST... AL... NITIN ROHIT KUMAR	Barcode No	:10158928
AGE/GENDER	:32 YRS/Male	SPECIMEN DATE	:25/Nov/2023 10:14AM
PATIENT ID	:125298	SPECIMEN RECEIVED	:25/Nov/2023 10:45AM
REFERRED BY	:Dr. MEDIWHEEL	REPORT DATE	:25/Nov/2023 01:01PM
CENTRE NAME	:ONEPLUS ULTRASOUND LAB	LAB NO.	:012311250015

Test Name	Result	Unit	Ref. Range
LDL/HDL Ratio Calculated	3.1		Moderate Risk 7.1-11.0 High Risk >11.0 0 - 3.55

LDL Cholesterol	Total Cholesterol	HDL Cholesterol
<100 Optimal	<200 Desirable	<40 Low
100-129 Near optimal	200-239 Borderline high	>60 High
130-159 Borderline high	>240 High	
160-189 High		
>190 Very high		

According to NCEP, ATP-III Guidelines

	BUN/Creatinine ratio		
UREA UREASE-GLDH	23.00	mg/dl	15-45
Bun (blood urea nitrogen) CALCULATED	10.75	mg/dl	8.9-21.6
CREATININE ENZYMATIC	0.90	mg/dl	0.30-1.10
Bun/Creatinine Ratio CALCULATED	11.94		10.0 - 20.0

ENDOCRINOLOGY

THYROID PROFILE(T3,T4,TSH)

Triiodothyronine total [t3] ECLIA	0.78	ng/dl	0.52-1.9
Thyroxine total [t4] ECLIA	6.40	µg/dl	4.4 - 10.8
TSH (Thyroid Stimulating Hormone) Enzyme linked fluorescent assay	4.10	µIU/ml	0.25-5.0

AGE WISE VARIATION IN TSH

AGE	TSH(µIU/ml)	AGE	TSH(µIU/ml)
1-4 weeks	1.00 - 19.0	16-20 yrs	0.25 - 5.0

Checked By.

DR. NITIN AGARWAL
MBBS,MD(PATHOLOGIST)

Dr. NITIN AGARWAL
M B B S . MD (Path)
DMC/R/01436

47, Harsh Vihar, Pitampura, Delhi-34 ☎ 011-4248 0101, 9599913051

✉ Email: oneplusul@gmail.com 🌐 www.oneplusul.in

- Clinical correlation is essential for final diagnosis. • If test results are unsatisfactory please contact personally or on phone.
- This report is for perusal of doctors only. • All disputes are subject to Delhi jurisdiction only. • Not for medico legal case.
- All congenital anomalies in a foetus may not be diagnosed in routine obstetric ultrasound.



OnePLUS
Ultrasound Lab

Dr. Nitin Agarwal

Pathologist & Director
Ex. Sr. Res. MAMC
& Lok Nayak Hospital
Ex. Chief of Lab Dr. Lal Path labs.

Dr. Pooja (Garg) Agarwal

Radiologist & Director
MBBS(MAMC) DMRC (MAMC)
Imaging Expert in Fetal and Maternal Medicine,
University of Barcelona, Spain
Fetal Medicine Foundation (UK) Accreditation



NAME: QUALITY FIRST... ALW... VIROH KUMAR	Barcode No	:10158928
AGE/GENDER :32 YRS/Male	SPECIMEN DATE	:25/Nov/2023 10:14AM
PATIENT ID :125298	SPECIMEN RECEIVED	:25/Nov/2023 10:45AM
REFERRED BY :Dr. MEDIWHEEL	REPORT DATE	:25/Nov/2023 01:01PM
CENTRE NAME :ONEPLUS ULTRASOUND LAB	LAB NO.	:012311250015

Test Name	Result	Unit	Ref. Range
1-12 mths	1.70 - 9.1	21 - 80 yrs	0.25 - 5.0
1-5 yrs	0.80 - 8.2	I st trimester	0.25 - 5.0
6-10 yrs	0.25 - 5.0	II nd trimester	0.50 - 5.0
11-15 yrs	0.25 - 5.0	II rd trimester	0.4 - 6.0

Reference ranges - Interpretation of Diagnostic tests - (Jacques Wallach)

1. Primary hypothyroidism is accompanied by depressed serum T3 and T4 values and elevated serum TSH level.
2. Primary hyperthyroidism is accompanied by elevated serum T3 and T4 levels along with depressed TSH values.
3. Slightly elevated T3 levels may be found in pregnancy and estrogen therapy, while depressed levels may be encountered in severe illness, renal failure and during therapy with drugs like propranolol and propyl thiouracil.
4. Although elevated TSH levels are nearly always indicative of primary hypothyroidism, and may be seen in secondary thyrotoxicosis

CLINICAL PATHOLOGY

URINE ROUTINE (Strip/microscopy)

Sample Type: Urine

Physical examination

Colour	PALE YELLOW	PALE YELLOW
Transparency	CLEAR	CLEAR
Sp.gravity	1.015	1.005-1.030
BROMOTHYMOL BLUE		
pH	6.00	5.0-8.0
Double Indicators Test		
Reaction	ACIDIC	ACIDIC

Chemical examination

Urine protein	NIL	NIL
Protein Ionization		
Urine sugar	NIL	NIL
Oxidation Reaction		
Bilirubin, urine	NEGATIVE	NEGATIVE
Urobilinogen	NORMAL	NORMAL
P-Aminobenzoic Acid and Phenazopyridine Reaction		
Ketones	NEGATIVE	NEGATIVE
Acetoacetalde and Dichlorobenzene Reaction		

Checked By.

DR. NITIN AGARWAL
MBBS, MD (PATHOLOGIST)

NITIN AGARWAL
M B B S . MD (Path)
DMC/R/01436

Page 5 of 6

47, Harsh Vihar, Pitampura, Delhi-34 ☎ 011-4248 0101, 9599913051

✉ Email: oneplusul@gmail.com 🌐 www.oneplusul.in

- Clinical correlation is essential for final diagnosis. • If test results are unsatisfactory please contact personally or on phone.
- This report is for perusal of doctors only. • All disputes are subject to Delhi jurisdiction only. • Not for medico legal case.
- All congenital anomalies in a foetus may not be diagnosed in routine obstetric ultrasound.



OnePLUS Ultrasound Lab

Dr. Nitin Agarwal

Pathologist & Director
Ex. Sr. Res. MAMC
& Lok Nayak Hospital
Ex. Chief of Lab Dr. Lal Path labs.

Dr. Pooja (Garg) Agarwal

Radiologist & Director
MBBS(MAMC) DMRC (MAMC)
Imaging Expert in Fetal and Maternal Medicine,
University of Barcelona, Spain
Fetal Medicine Foundation, (UK) Accreditation



NAME	QUALITY FIRST... ALISHA ROHIT KUMAR	Barcode No	:10158928
AGE/GENDER	:32 YRS/Male	SPECIMEN DATE	:25/Nov/2023 10:14AM
PATIENT ID	:125298	SPECIMEN RECEIVED	:25/Nov/2023 10:45AM
REFERRED BY	:Dr. MEDIWHEEL	REPORT DATE	:25/Nov/2023 01:01PM
CENTRE NAME	:ONEPLUS ULTRASOUND LAB	LAB NO.	:012311250015

Test Name	Result	Unit	Ref. Range
Microscopic examination			
Pus cells. Microscopy	1-2	/HPF	0-2
Epithelial cells Microscopy	1-2	/HPF	NIL
R.B.C. Microscopy	NIL	/HPF	NIL
Casts Microscopy	NIL	/HPF	NIL
Crystals Microscopy	NIL	/HPF	NIL
Bacteria Microscopy	NIL	/HPF	NIL
Others.	NIL	NIL	NIL

*** End Of Report ***

Checked By.

DR. NITIN AGARWAL
MBBS,MD(PATHOLOGIST)

Dr NITIN AGARWAL
M B B S . MD (Path)
DMG(R/01436)

47, Harsh Vihar, Pitampura, Delhi-34 ☎ 011-4248 0101, 9599913051

✉ Email: oneplusul@gmail.com 🌐 www.oneplusul.in

- Clinical correlation is essential for final diagnosis. • If test results are unsatisfactory please contact personally or on phone.
- This report is for perusal of doctors only. • All disputes are subject to Delhi jurisdiction only. • Not for medico legal case.
- All congenital anomalies in a foetus may not be diagnosed in routine obstetric ultrasound.



OnePLUS
Ultrasound Lab

Dr. Nitin Agarwal

Pathologist & Director
Ex. Sr. Res. MAMC
& Lok Nayak Hospital
Ex. Chief of Lab Dr. Lal Path labs.

Dr. Pooja (Garg) Agarwal

Radiologist & Director
MBBS(MAMC) DMRC (MAMC)
Imaging Expert in Fetal and Maternal Medicine,
University of Barcelona, Spain
Fetal Medicine Foundation ,(UK) Accreditation



QUALITY FIRST... ALWAYS!			
NAME	:Mr. ROHIT KUMAR	Barcode No	:10158928
AGE/GENDER	:32 YRS/Male	SPECIMEN DATE	:25/Nov/2023 10:14AM
PATIENT ID	:125298	SPECIMEN RECEIVED	:25/Nov/2023 03:48PM
REFERRED BY	:Dr. MEDIWHEEL	REPORT DATE	:25/Nov/2023 04:47PM
CENTRE NAME	:ONEPLUS ULTRASOUND LAB	LAB NO.	:012311250015

Test Name	Result	Unit	Ref. Range
-----------	--------	------	------------

BIOCHEMISTRY


MediWheel Health checkup < 40 Male

Sample Type:Fluoride PP

Blood sugar pp GOD-POD	110	mg/dL	70.0-140.0
----------------------------------	-----	-------	------------

*** End Of Report ***

Checked By.


DR. NITIN AGARWAL
MBBS,MD(PATHOLOGIST)
Dr. NITIN AGARWAL
MBBS, MD
Regn. No. DMC-R-1436

Page 1 of 1

Page 3 of 3

47, Harsh Vihar, Pitampura, Delhi-34 ☎ 011-4248 0101, 9599913051

✉ Email: oneplusul@gmail.com 🌐 www.oneplusul.in

- Clinical correlation is essential for final diagnosis. • If test results are unsatisfactory please contact personally or on phone.
- This report is for perusal of doctors only. • All disputes are subject to Delhi jurisdiction only. • Not for medico legal case.
- All congenital anomalies in a foetus may not be diagnosed in routine obstetric ultrasound.

Name	: Mr. ROHIT KUMAR	Age/Sex	: 32 YRS/Male
Ref. By	: Dr. MEDIWHEEL	Lab No	: 012311250015
Date	: 25-Nov-2023	Patient ID	: LSHHI125298

X-ray-Chest PA view

Bony cage and soft tissues are normal.
Cardiothoracic ratio is normal.
Mediastinum is normal.
Both hila are normal.
Both costophrenic angles are clear.
Both domes of diaphragm are normal.
Lung fields are clear. No parenchymal lesion seen.

IMPRESSION: Normal Study.

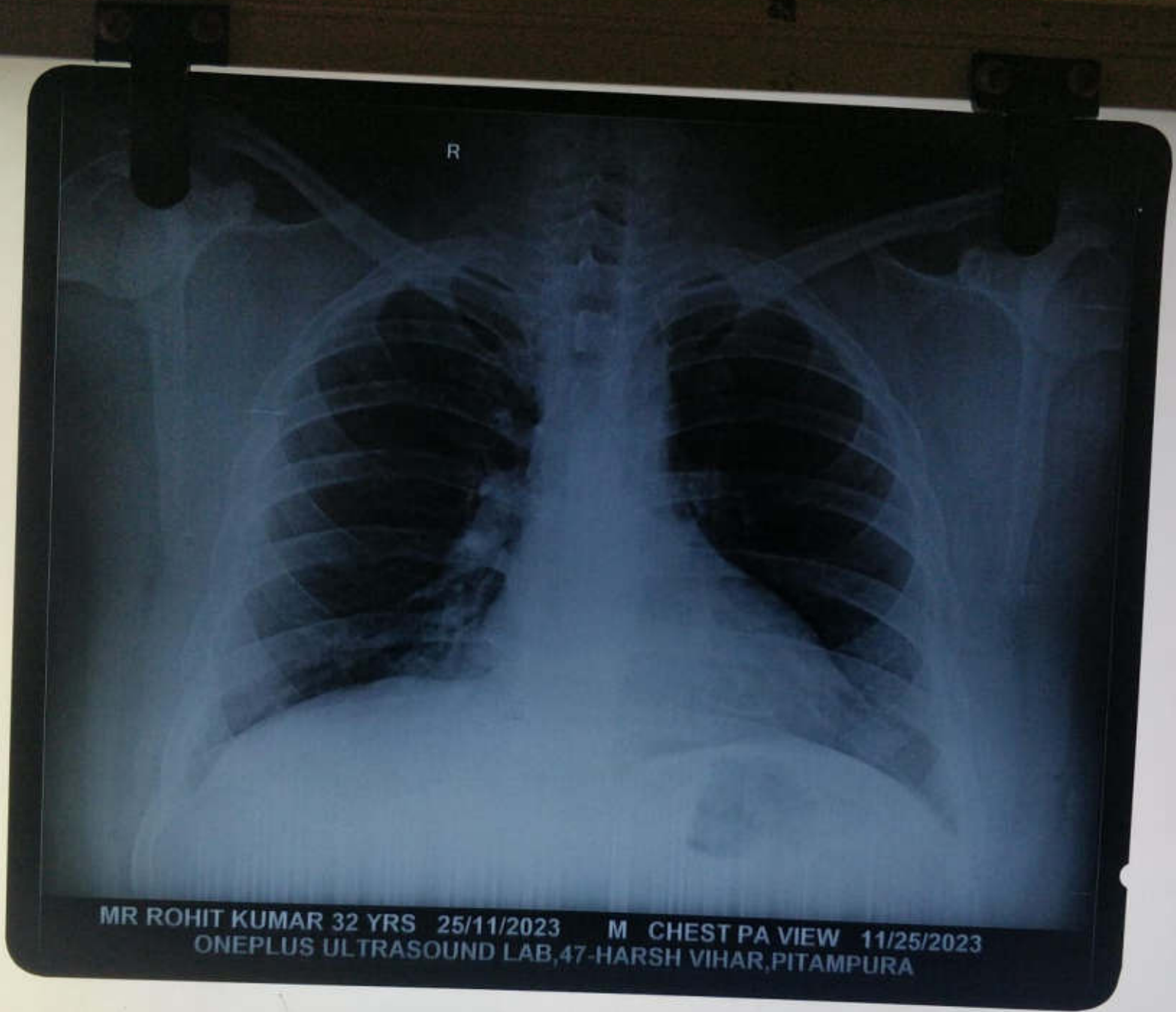

DR. POOJA GARG
RADIOLOGIST
REG NO- DMC/R/03398

Type By : pooja

47, Harsh Vihar, Pitampura, Delhi-34 ☎ 011-4248 0101, 9599913051

✉ Email: oneplusul@gmail.com 🌐 www.oneplusul.in

- Clinical correlation is essential for final diagnosis. • If test results are unsatisfactory please contact personally or on phone.
- This report is for perusal of doctors only. • All disputes are subject to Delhi jurisdiction only. • Not for medico legal case.
- All congenital anomalies in a foetus may not be diagnosed in routine obstetric ultrasound.



R

MR ROHIT KUMAR 32 YRS 25/11/2023 M CHEST PA VIEW 11/25/2023
ONEPLUS ULTRASOUND LAB, 47-HARSH VIHAR, PITAMPURA