



BHAILAL AMIN  
GENERAL HOSPITAL



### CONCLUSION OF HEALTH CHECKUP

ECU Number : 1162

Age : 51

Weight : 37

Date : 07/01/2023

MR Number : 23198140

Sex : Female

Ideal Weight : 57

Patient Name: KAMALABEN M BAMANIA

Height : 157

BMI : 15.01

Dr. Manish Mittal

Internal Medicine

Note : General Physical Examination & routine Investigations included in the Health Checkup have certain limitations and may not be able to detect all the latent and asymptomatic diseases.



**BHAILAL AMIN  
GENERAL HOSPITAL**



ECU Number : 1162  
Age : 51  
Weight : 37  
Date : 07/01/2023

MR Number : 23198140  
Sex : Female  
Ideal Weight : 57

Patient Name: KAMALABEN M BAMANIA  
Height : 157  
BMI : 15.01

Past H/O : NO P/H/O ANY MAJOR ILLNESS.

Present H/O : NO MEDICAL COMPLAINTS AT PRESENT.

Family H/O : NO F/H/O ANY MAJOR ILLNESS.

Habits : NO HABITS.

Gen.Exam. : G.C. GOOD  
B.P : 110/70 mm Hg  
Pulse : 88/MIN REG.  
Others : SPO2 : 98 %  
C.V.S : NAD  
R.S. : NAD  
Abdomen : NP  
Spleen : NP  
Skin : NAD  
C.N.S : NAD  
Advice :

ECU Number : 1162  
Age : 51  
Weight : 37  
Date : 07/01/2023

MR Number : 23198140  
Sex : Female  
Ideal Weight : 57

Patient Name: KAMALABEN M BAMANIA  
Height : 157  
BMI : 15.01

Ophthalmic Check Up :	Right	Left
Ext Exam		NIL
Vision Without Glasses	6/6	6/6
Vision With Glasses	N.5 WITH + 2.25 D SPH	
Final Correction	NORMAL	NORMAL
Fundus	NORMAL	
Colour Vision	NORMAL	
Advice	NIL	

**Orthopaedic Check Up :**

Ortho Consultation

Ortho Advice

**ENT Check Up :**

Ear

Nose

Throat

Hearing Test

ENT Advice

**General Surgery Check Up :**

General Surgery

Abdominal Lump

Hernia

External Genitals

PVR

Proctoscopy

Any Other

Surgical Advice



**BHAILAL AMIN**  
**GENERAL HOSPITAL**

ESTD. 1964



H-2015-0297



MC-3004



E-2021-0037



ECU Number : 1162  
Age : 51  
Weight : 37  
Date : 07/01/2023

MR Number : 23198140  
Sex : Female  
Ideal Weight : 57

Patient Name: KAMALABEN M BAMANIA  
Height : 157  
BMI : 15.01

**Gynaec Check Up :**

OBSTETRIC HISTORY	2 FTND
MENSTRUAL HISTORY	LMP : 06/09/2022
PRESENT MENSTRUAL CYCLE	IRREGULAR CYCLES
PAST MENSTRUAL CYCLE	REGULAR
PIEF COMPLAINTS	NIL
PA	SOFT
PS	Cx - (N) Vg SENILE VAGINITIS
PV	UT NS Fx CLEAR
BREAST EXAMINATION RIGHT	NORMAL
BREAST EXAMINATION LEFT	NORMAL
PAPSMEAR	TAKEN
BMD	
MAMMOGRAPHY	
ADVICE	FOLLOWUP WITH REPORTS.



**DEPARTMENT OF DIAGNOSTIC RADIOLOGY**

- Computer Radiography
- Ultra Sensitive Colour Doppler
- Ultra High Resolution Sonography
- Multi-Detector CT Scan
- Mammography
- Interventional Radiology
- Digital Subtraction Angiography
- Foetal Echocardiography
- Echocardiography

Patient No. : 23198140      Report Date : 07/01/2023  
Request No. : 190048103      07/01/2023 9.30 AM  
Patient Name : Mrs. KAMALABEN M BAMANIA  
Gender / Age : Female / 51 Years 7 Days

**USG : Screening for Abdomen (excluding Pelvis) Or Upper Abdomen**

Liver is normal in size and echopattern. No mass lesion identified. The hepatic veins are clear and patent. PV patent. No dilated IHBR.  
Gall bladder is well distended and shows no obvious abnormality. Common bile duct measures 3.5 mm in diameter.  
Pancreas shows no obvious abnormality. Tail obscured.  
Spleen is normal size and echo pattern.

~~Both kidneys are normal in shape and position. Normal echogenicity and cortico-medullary differentiation is noted. No right hydronephrosis seen. Mild left hydronephrosis is seen.~~

	RIGHT	LEFT
Renal length :	82 mm.	80 mm.
A.P. :	31 mm.	38 mm.

Uterus is anteverted, normal in size and echo pattern. Endometrium thickness is about 6 mm. No obvious mass lesion seen.  
Uterine length : 56 mm.  
A.P. : 23 mm.

No adnexal mass seen.  
Urinary bladder is well distended and appears normal.  
No ascites.

**COMMENT:**

**Mild left hydronephrosis.**

*Kindly correlate clinically*

• ULTRA SONOGRAPHY CANNOT DETECT ALL ABNORMALITIES  
 • NOT VALID FOR MEDICO-LEGAL PURPOSES  
 • CLINICAL CORRELATION RECOMMENDED

**Dr. Priyanka Patel, MD**  
Consultant Radiologist





**DEPARTMENT OF DIAGNOSTIC RADIOLOGY**

- Computer Radiography
- Ultra Sensitive Colour Doppler
- Ultra High Resolution Sonography
- Multi-Detector CT Scan
- Mammography
- Interventional Radiology
- Digital Subtraction Angiography
- Foetal Echocardiography
- Echocardiography

Patient No. : 23198140                      Report Date : 07/01/2023  
Request No. : 190048125              07/01/2023 9.30 AM  
Patient Name : **Mrs. KAMALABEN M BAMANIA**  
Gender / Age : Female / 51 Years 7 Days

**Mammography (Both Breast)**

Both side mammogram has been obtained in mediolateral oblique (MLO) as well as craniocaudal (CC) projections.

Both breasts show scattered fibro glandular parenchyma.  
No obvious focal mass seen on either side.  
No obvious micro/cluster calcification seen. Bilateral benign specks of calcifications are seen.  
No obvious skin thickening or nipple retraction seen.  
No enlarged axillary lymph nodes seen.

**IMPRESSION:**

No obvious focal mass in breasts. BI-RADS category 2.  
Kindly correlate clinically /Follow up

**BIRADS:** 0- needs additional imaging, 1- negative, 2- benign, 3- probably benign (require short term follow up), 4- suspicious (require further evaluation with biopsy), 5- highly suspicious for malignancy, 6- biopsy proven malignancy.

**INFORMATION REGARDING MAMMOGRAMS:**

- A REPORT THAT IS NEGATIVE FOR MALIGNANCY SHOULD NOT DELAY BIOPSY IF THERE IS A DOMINANT OR CLINICALLY SUSPICIOUS MASS.
- IN DENSE BREASTS, AN UNDERLYING MASS LESION MAY BE OBSCURED.
- FALSE POSITIVE DIAGNOSIS OF CANCER MAY OCCURE IN SMALL PERCENTAGE OF CASES.

• ULTRA SONOGRAPHY CANNOT DETECT ALL ABNORMALITIES  
 • NOT VALID FOR MEDICO-LEGAL PURPOSES  
 • CLINICAL CORRELATION RECOMMENDED

*Hasani*

**Dr.Perna C Hasani, MD**  
Consultant Radiologist



365 Days / 24 Hours Laboratory Services

Home Collection Facility Available  
(Mon To Sat 8:00 am to 5:00 pm)



BHAILAL AMIN  
GENERAL HOSPITAL

📍 Bhailal Amin Marg, Gorwa, Vadodara, Gujarat 390003.

🌐 www.baghospital.com | 📞 0265-677 6222, 255 6222 | Follow us : 📱

DEPARTMENT OF LABORATORY MEDICINE

Patient Name : Mrs. KAMALABEN M BAMANIA  
Gender / Age : Female / 51 Years 7 Days  
MR No / Bill No. : 23198140 / 231059501  
Consultant : Dr. Manish Mittal  
Location : OPD

Type : OPD  
Request No. : 98720  
Request Date : 07/01/2023 09:30 AM  
Collection Date : 07/01/2023 10:39 AM  
Approval Date : 07/01/2023 02:55 PM

**Post-Lunch (PP2BS)**

<u>Test</u>	<u>Result</u>	<u>Units</u>	<u>Biological Ref. Range</u>
Post Prandial 2 Hr. Plasma Glucose	118	mg/dL	70 - 140

By Hexokinase method on RXL Dade Dimension

---- End of Report ----

Dr. Rakesh Vaidya  
MD (Path). DCP.

Test Results are dependent on a number of variables & technical limitations. Hence, it is advised to correlate with clinical findings and other related investigations before any firm opinion is made. Recheck / retest may be requested.



Patient Name : Mrs. KAMALABEN M BAMANIA  
 Gender / Age : Female / 51 Years 7 Days  
 MR No / Bill No. : 23198140 / 231059501  
 Consultant : Dr. Manish Mittal  
 Location : OPD

Type : OPD  
 Request No. : 98703  
 Request Date : 07/01/2023 09:30 AM  
 Collection Date : 07/01/2023 10:09 AM  
 Approval Date : 07/01/2023 03:52 PM

**Urine routine analysis (Auto)**

Test	Result	Units	Biological Ref. Range
<b>Physical Examination</b>			
Quantity	30	mL	
Colour	Pale Yellow		
Appearance	Clear		
<b>Chemical Examination (By Reagent strip method)</b>			
pH	6.0		
Specific Gravity	>=1.030		
Protein	Negative	gm/dL	0 - 5
Glucose	Negative	mg/dL	0 - 5
Ketones	Negative		0 - 5
Bilirubin	Negative		Negative
Urobilinogen	Negative		Negative (upto 1)
Blood	Negative		Negative
Leucocytes	Negative		Negative
Nitrite	Negative		Negative
<b>Microscopic Examination (by Microscopy after Centrifugation at 2000 rpm for 10 min or on fully automated Sysmex urine sedimentation analyzer UF4000)</b>			
Red Blood Cells	0 - 1	/hpf	0 - 2
Leucocytes	0 - 1	/hpf	0 - 5
Epithelial Cells	1 - 5	/hpf	0 - 5
Casts	Nil	/lpf	Nil
Crystals	Nil	/hpf	Nil
Mucus	Absent	/hpf	Absent
Organism	Absent		

--- End of Report ---

Dr. Rakesh Vaidya  
MD (Path). DCP.



365 Days / 24 Hours Laboratory Services

Home Collection Facility Available  
(Mon To Sat 8:00 am to 5:00 pm)



BHAILAL AMIN  
GENERAL HOSPITAL

Bhailal Amin Marg, Gorwa, Vadodara, Gujarat 390003.

www.baghospital.com | 0265-677 6222, 255 6222 | Follow us : f @

DEPARTMENT OF LABORATORY MEDICINE

Patient Name : Mrs. KAMALABEN M BAMANIA  
Gender / Age : Female / 51 Years 7 Days  
MR No / Bill No. : 23198140 / 231059501  
Consultant : Dr. Manish Mittal  
Location : OPD

Type : OPD  
Request No. : 98703  
Request Date : 07/01/2023 09:30 AM  
Collection Date : 07/01/2023 10:09 AM  
Approval Date : 07/01/2023 02:09 PM

**Pap Smear**

Test	Result	Units	Biological Ref. Range
------	--------	-------	-----------------------

Pap Smear

Pap Smear Screening Report / Cervico-Vaginal Cytology...

Cyto No : P/34/23  
Received at 1:00 pm.

Clinical Details : No complain  
P/V findings : Cx.- NAD. / Vg. - Senile vaginitis  
LMP : 06/09/2022

TBS Report / Impression :

- \* Satisfactory for evaluation, transformation zone components identified.
- \* Mild inflammatory cellularity (Neutrophils rich).
- \* Benign cellular changes, reparative changes.
- \* No epithelial cell abnormality favouring squamous intraepithelial lesion or frank malignancy ( NILM ).

Note / Method :

The material received in LBC container, cytosmear was stained by rapid pap method and reported with due consideration to The Bethesda system (Modified 2014)

---- End of Report ----

Dr. Rakesh Vaidya  
MD (Path). DCP.

Test Results are dependent on a number of variables & technical limitations. Hence, it is advised to correlate the clinical findings and other related investigations before any firm opinion is given. Recheck / retest may be requested.



**BHAILAL AMIN**  
GENERAL HOSPITAL

📍 Bhaikal Amin Marg, Gorwa, Vadodara, Gujarat 390003.

🌐 www.baghospital.com | 📞 0265-677 6222, 255 6222 | Follow us : 📱 @

**DEPARTMENT OF DIAGNOSTIC RADIOLOGY**

**ADVANCED DIGITAL SOLUTIONS**

- Computer Radiography
- Ultra Sensitive Colour Doppler
- Ultra High Resolution Sonography
- Multi-Detector CT Scan
- Mammography
- Interventional Radiology
- Digital Subtraction Angiography
- Foetal Echocardiography
- Echocardiography

Patient No. : 23198140      Report Date : 07/01/2023  
 Request No. : 190048059      07/01/2023 9.30 AM  
 Patient Name : Mrs. KAMALABEN M BAMANIA  
 Gender / Age : Female / 51 Years 7 Days

**X-Ray Chest AP**

Both lung fields are clear.  
 Both costophrenic sinuses appear clear.  
 Heart size is normal.  
 Hilar shadows show no obvious abnormality.  
 Aorta is normal.

• ULTRA SONOGRAPHY CANNOT DETECT ALL ABNORMALITIES  
 • NOT VALID FOR MEDICO-LEGAL PURPOSES  
 • CLINICAL CORRELATION RECOMMENDED

*Priyanka Patel*  
**Dr. Priyanka Patel, MD**  
 Consultant Radiologist




Patient No. : 23198140      Report Date : 07/01/2023  
Request No. : 190048154      07/01/2023 9.30 AM  
Patient Name : **Mrs. KAMALABEN M BAMANIA**  
Gender / Age : Female / 51 Years 7 Days

**Echo Color Doppler**

MITRAL VALVE : NORMAL, NO MS, MILD MR  
AORTIC VALVE : TRILEAFLET, NO AS, NO AR  
TRICUSPID VALVE : NORMAL, TRIVIAL TR, NO PAH  
PULMONARY VALVE : NORMAL, NO PR, NO PS  
LEFT ATRIUM : NORMAL SIZE  
AORTA : NORMAL  
LEFT VENTRICLE : NORMAL LVEF – 60%, NO RWMA AT REST  
RIGHT ATRIUM : NORMAL SIZE  
RIGHT VENTRICLE : NORMAL SIZE  
I.V.S. : INTACT  
I.A.S. : INTACT  
PULMONARY ARTERY : NORMAL  
PERICARDIUM : NO EFFUSION  
COLOUR/DOPPLER FLOW MAPPING : MILD MR, TRIVIAL TR, NO PAH

**FINAL CONCLUSION:**

1. NORMAL SIZED ALL CARDIAC CHAMBERS, NO LVH
2. NORMAL LV SYSTOLIC FUNCTION LVEF – 60%
3. NO RESTING REGIONAL WALL MOTION ABNORMALITY
4. NORMAL DIASTOLIC FUNCTION
5. NORMAL RIGHT HEART SIZE AND RV PRESSURES
6. NO PERICARDIAL EFFUSION, CLOT OR VEGETATION SEEN, SR+.

  
DR. KILLOL KANERIA, M.D., D.M., CARD.

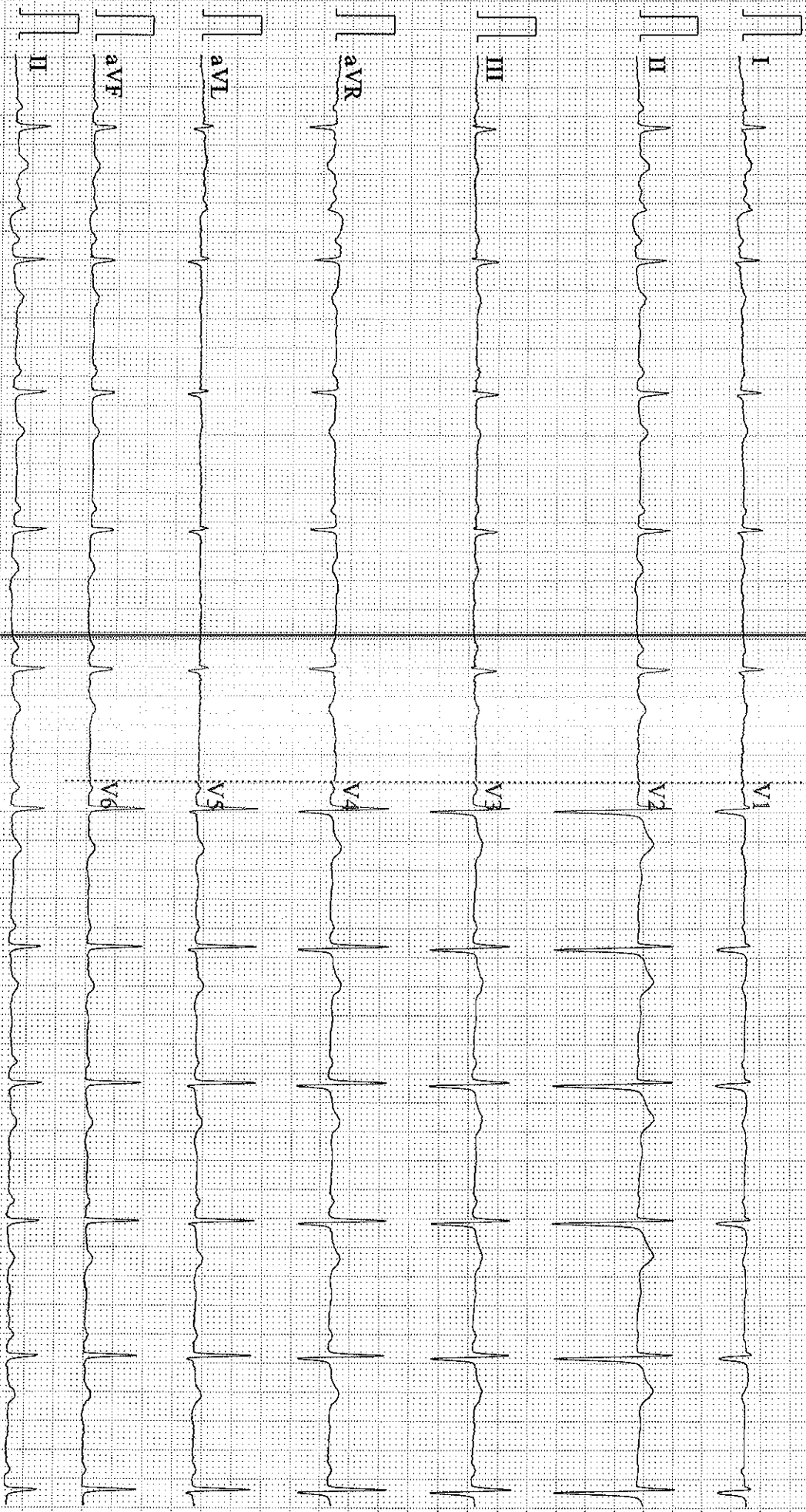
ID: 23198140  
MRS. KAMALA M. BAMANIA  
Female 51 years

HR : 63 bpm  
P : 106 ms  
PR : 161 ms  
QRS : 83 ms  
QT/QTc : 399/411 ms  
P/QRS/T : 62/69/52 °  
RV5/SV1 : 1.040/0.493 mV

Diagnosis Information:  
Sinus Rhythm  
\*\*\*Normal ECG\*\*\*

Report Confirmed by:

*Dr. M. S.*



0.67~25Hz AC50 25mm/s 10mm/mV 2\*5s+1r 63

V1.93 SEMIP V1.7

# Dr. Sonica Peshin

Cosmetic Dentist & Implantologist

Reg. No. : 6966-A

M. : 9586867301



BHAILAL AMIN  
GENERAL HOSPITAL

## Dental assessment form

06/01/2023

Name: Kamala M Bamania

Age/ Sex: 51 years/Female

Patient has come for an oral hygiene check up

### On Examination:

- Stains++ Calculus++
- History of horizontal brushing
- Generalised attrition, recession
- Grossly destructed tooth with respect to 36

### Provisional diagnosis:

- Chronic generalised gingivitis

### Treatment plan:

- Scaling and polishing
- Extraction of 36 followed by prosthesis with respect to 36

### Advised:

- Brush your teeth twice daily.
- Salt water rinses atleast once a day.
- Clean your tongue and floss in between everyday.
- Follow vertical brushing technique.

  
Dr Sonica Peshin

ITEM CODE:SMD066

HEART CARE | BRAIN & SPINE | BONE & JOINT | MINIMAL ACCESS SURGERY  
24X7 EMERGENCY | DIAGNOSTICS | PHARMACY | BLOOD BANK

www.baghospital.com (0265) 677 6222, 255 6222

Bhaikal Amin Marg, Gorwa, Vadodara, Gujarat - 390003

Follow us

