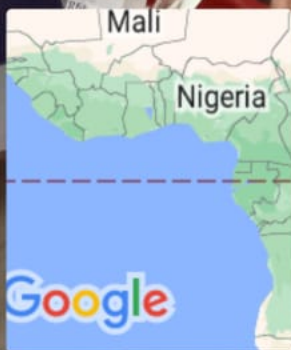




 GPS Map Camera



Jodhpur, Rajasthan, India

72M8+GHP, Eidgah Rd, Jalori Bari, Sardarpura,

Jodhpur, Rajasthan 342003, India

Lat 26.28378°

Long 73.016488°

13/11/22 03:34 PM GMT +05:30

आयकर विभाग

INCOME TAX DEPARTMENT



सत्यमेव जयते

भारत सरकार

GOVT. OF INDIA

MANEESH PANWAR


LAXMAN SINGH PANWAR

10/10/1990

Permanent Account Number

AWZPP0010A




Sudhakar Singh Thakur, Representative
Aayal, 1001, 10/10/1990, 10/10/1990

Signature

आयकर विभाग

INCOME TAX DEPARTMENT



भारत सरकार

GOVT. OF INDIA

MANEESH PANWAR

LAXMAN SINGH PANWAR

10/10/1990

Permanent Account Number

AWZPP0010A

Handwritten signature

Signature

द्विस्तुत



Dr. Nand Kishore Chh ngani
MB-Physician & Co. Jodhpur
RMC No.-20
JODHPUR



Client Name	Mr MANEESH PANWAR	Sex/Age	32 Year / Male
C Name	REF By.	TPA Name	
Date	13 Nov 2022	Lab No.	18054
Reporting Date	13 Nov 2022	Remark	

Test Name	Result	Unit	Ref-Range
-----------	--------	------	-----------

HEMATOLOGY

COMPLETE BLOOD COUNT

HAEMOGLOBIN	13.0	GM%	13-18 GM%
TOTAL LEUCOCYTE COUNT	6800	/Cumm	4000-11000 /Cumm
DIFFERENTIAL LEUCOCYTE COUNT			
PLOYMORPHS	54.9	%	40-70 %
LYMPHOCYTES	H 40.8	%	20-40 %
EOSINOPHILS	2.3	%	0-6 %
MONOCYTES	2.0	%	0-8 %
BASOPHILES	00	%	0-2 %
RBC	4.36	Lakh/Cumm/	3.5-5.5 Lakh/Cumm/
PLATELETS COUNT	2.39	Lakh/Cumm	1.5-4 Lakh/Cumm
HCT	40	%	34-48 %
MCV	91.74	fl	30-100 fl
MCH	29.82	pg	27-32 pg
MCHC	32.50	g/dl	32-36 g/dl
ESR	16	mm/1Hrs	0-20 mm/1Hrs
ABO RH-FACTOR	O (+) POSITIVE		-

*****End Of Reports*****

Complete Diagnostic Solution

TECHNOLOGIST	Lab. INCHARGE	PATHOLOGIST
--------------	---------------	-------------

Dr. V. Mahotra
MD - Pathology
RMC No.: 977

ई.सी.जी. | डिजिटल एक्सरे | टी. एम. टी. | ई. ई. जी. | ई. एम. जी. | एन. सी. वी. | बेरा | पी. एफ. टी. | ऑडियोलॉजिस्ट

ब्रह्म बाग, पुष्पक कोरियर के पास, इंदगाह रोड, जालोरी गेट, जोधापुर (राज.)

फोन : 0291-2620214 E-mail : srdmedical@gmail.com

THIS REPORT IS NOT VALID FOR MEDICO LEGAL PURPOSES



Client Name	Mr MANEESH PANWAR	Sex/Age	32 Year / Male
C Name	REF By.	TPA Name	.
Date	13 Nov 2022	Lab No.	18054
Reporting Date	13 Nov 2022	Remark	

Test Name	Result	Unit	Ref-Range
-----------	--------	------	-----------

HEMATOLOGY

Glycosylated Hemoglobin (HbA1C)	5.1	%	- %
ABG(Average Blood Glucose)	99.67	MG/DL	- MG/DL

Methodology: Ion exchange H.P.L.C. Using instrument: D-10 with EDTA


Hemoglobin A1C % Degree of Glucose Control

> 8	Action suggested
<7	Goal
< 6	Non – Diabetic level

Clinical Information:

Glycated hemoglobin testing is recommended for both (a) checking blood sugar control in people who might be pre-diabetic and (b) monitoring blood sugar control in patients with more elevated levels, termed diabetes mellitus. The American diabetes association guidelines suggest that the Glycosylated hemoglobin test be performed at least two times a year in patients with diabetes that are meeting treatment goals (and that have stable glycemic control) and quarterly in patients with diabetes whose therapy has changed or that are not meeting glycemic goals. Glycated hemoglobin measurement is not appropriate where there has been a change in diet or treatment within 6 weeks. Hence, people with recent blood loss, hemolytic anemia, or genetic differences in the hemoglobin molecule (hemoglobinopathy) such as sickle-cell disease and other conditions, as well as those that have donated blood recently are not suitable for this test.

*****End Of Reports*****



	Lab. INCHARGE	
--	---------------	--

Dr. V. Malhotra
MD & Micro.
RMC No. 1377

ई.सी.जी. | डिजिटल एक्सरे | टी. एम. टी. | ई. ई. जी. | ई. एम. जी. | एन. सी. वी. | बेरा | पी. एफ. टी. | ऑडियोमैट्री

ब्रह्म बाग, पुष्पक कोरियर के पास, इंदगाह रोड़, जालोरी गेट, जोधपुर (राज.)

फोन : 0291-2620214 E-mail : srdmedical@gmail.com

THIS REPORT IS NOT VALID FOR MEDICO LEGAL PURPOSES



Client Name	Mr MANEESH PANWAR	Sex/Age	32 Year / Male
C Name	REF By.	TPA Name	
Date	13 Nov 2022	Lab No.	18054
Reporting Date	13 Nov 2022	Remark	

Test Name	Result	Unit	Ref-Range
-----------	--------	------	-----------

BIO-CHEMISTRY

BLOOD SUGAR (F)	93.7	mg/dl	60-110 mg/dl
BLOOD SUGAR	124.0	mg/dl	60-160 mg/dl
LIPID PROFILE			
CHOLESTEROL	174.6	mg/dl	130-250 mg/dl
TRIGLYCERIDES	159.3	mg/dl	60-170 mg/dl
HDL-CHOLESTEROL	43.50	mg/dl	30-70 mg/dl
LDL-CHOLESTEROL	99.24001	mg/dl	65-160 mg/dl
VLDL	31.86	mg/dl	0-35 mg/dl
CHO/HDL RATIO	4.01	mg/dl	3.8-5.8 mg/dl
LDL/HDL RATIO	2.28	Ratio	1.5-3.5 Ratio

LIVER FUNCTION TEST

BILIRUBIN (TOTAL)	0.57	mg/dl	0.3-1.3 mg/dl
BILIRUBIN (DIRECT)	0.18	mg/dl	0-0.3 mg/dl
BILIRUBIN (IN-DIRECT)	0.39	mg/dl	0.1-0.9 mg/dl
SGOT (AST)	35.8	Units/Lit	5-40 Units/Lit
SGPT (ALT)	33.9	Units/Lit	5-40 Units/Lit
ALKALINE PHOSPHATSE	86.1	Units/Lit	65-306 Units/Lit
TOTAL PROTEIN	7.01	g/dl	6.1-8.6 g/dl
ALBUMIN	4.10	g/dl	3.5-5 g/dl
GLOBULIN	2.91	mg/dl	2.3-3.5 mg/dl
A/G RATIO	1.41 : 1	mg/dl	1-2.3 mg/dl
GGT	28	IU/L	4-54 IU/L

KIDNEY FUNCTION TEST

BLOOD UREA	23.1	mg/dl	12-50 mg/dl
S.CREATININE	0.99	mg/dl	0.6-1.4 mg/dl
S.URIC ACID	4.9	mg/dl	3.5-7.2 mg/dl
BUN	18	mg/dl	12-40 mg/dl

*****End Of Reports*****

TECHNOLOGIST

Lab. INCHARGE

PATHOLOGIST

Dr. V. K. Mahnotra
MD - Path & Lab
RMC No.: 977

ई.सी.जी. | डिजिटल एक्सरे | टी. एम. टी. | ई. ई. जी. | ई. एम. जी | एन. सी. वी. | बेरा | पी. एफ. टी. | ऑडियोमैट्री

ब्रह्म बाग, पुष्पक कोरियर के पास, इंदगाह रोड़, जालोरी गेट, जोधपुर (राज.)

फोन : 0291-2620214 E-mail : srdmedical@gmail.com

THIS REPORT IS NOT VALID FOR MEDICO LEGAL PURPOSES



Client Name	Mr MANEESH PANWAR	Sex/Age	32 Year / Male
C Name	REF By.	TPA Name	
Date	13 Nov 2022	Lab No.	18054
Reporting Date	13 Nov 2022	Remark	

Test Name	Result	Unit	Ref-Range
-----------	--------	------	-----------

URINE EXAMINATION REPORT

PHYSICAL EXAMINATION

COLOUR	YELLOW	-
REACTION	ACIDIC	-
PH	6.0	-
DEPOSITE	ABSENT	-
APPEARANCE	CLEAR	-

CHEMICAL EXAMINATION

ALBUMIN	ABSENT	-
SUGAR	ABSENT	-
BILE SALTS	ABSENT	-
KITONES	ABSENT	-
SPEC GRAV	1.030	-

MICROSCOPIC EXAMINATION

PUS CELLS	NIL	-
RBCs CELLS	NIL	-
EPITHELIAL CELLS	NIL	-
CASTs	NIL	-
CRYSTAL :-	NIL	-
BACTERIA	NIL	-

*****End Of Repons*****

Complete Diagnostic Solution

TECHNOLOGIST

Lab. INCHARGE

PATHOLOGIST

Dr. V. K. Malhotra
MD - Path & Micro.
RMC No.: 977

ई.सी.जी. | डिजीटल एक्सरे | टी. एम. टी. | ई. ई. जी. | ई. एम. जी. | एन. सी. वी. | बेरा | पी. एफ. टी. | ऑडियोमैट्री

ब्रह्म बाग, पुष्पक कोरियर के पास, ईदगाह रोड़, जालोरी गेट, जोधापुर (राज.)

फोन : 0291-2620214 E-mail : srdmedical@gmail.com

THIS REPORT IS NOT VALID FOR MEDICO LEGAL PURPOSES



Complete Diagnostic Solution

Client Name	Mr MANEESH PANWAR	Sex/Age	32 Year / Male
C Name	REF By.	TPA Name	
Date	13 Nov 2022	Lab No.	18054
Reporting Date	13 Nov 2022	Remark	

Test Name	Result	Unit	Ref-Range
-----------	--------	------	-----------

HARMONES

THYROID PROFILE

T3	0.86	ng/ml	0.6-1.81 ng/ml
T4	7.20	ug/dl	4.5-12.6 ug/dl
TSH	2.15	uIU/ml	0.35-5.5 uIU/ml

Interpretation of TSH :

Kindly correlate with age & clinical findings.

Biological reference range:

Children: Pregnancy:

1 - 2 days 3.20 - 34.6 uIU/ml 1st Trimester : 0.10 - 2.50

3 - 4 days 0.70 - 15.4 uIU/ml 2nd Trimester : 0.20 - 3.00

15 days - 5 mths 1.70 - 9.10 uIU/ml 3rd Trimester : 0.30 - 3.00

5 mths - 20 yrs 0.70 - 6.40 uIU/ml

Primary malfunction of the thyroid gland may result in excessive (hyper) or low(hypo) release of T3 or T4.

In additional, as

TSH directly affect thyroid function,malfunction of the pituitary or the hypothalamus influences the thyroid gland

activity.Disease in any portion of the thyroid-pituitary-hypothalamus system may influence the level of T3 and T4 in the

blood,in Primary hypothyroidism,TSH levels are significantly elevated,while in secondary and tertiary

hypothyroidism,TSH

levels may be low.IN addition,In Euthyroid sick Syndrom,multiple alterations in serum thyroid function test

findings have

been recognized.

*****End Of Reports*****

Complete Diagnostic Solution

TECHNOLOGIST	Lab. INCHARGE	PATHOLOGIST:
--------------	---------------	--------------

Dr. K. Malhotra
MD - Pathology & Micro.
RMC No. 977

ई.सी.जी. | डिजीटल एक्सरे | टी. एम. टी. | ई. ई. जी. | ई. एम. जी. | एन. सी. वी. | बेरा | पी. एफ. टी. | ऑडियोमैट्री

ब्रह्म बाग, पुष्पक कोरियर के पास, इंदगाह रोड़, जालोरी गेट, जोधापुर (राज.)

फोन : 0291-2620214 E-mail : srdmedical@gmail.com

THIS REPORT IS NOT VALID FOR MEDICO LEGAL PURPOSES



Pt Name : MANEESH PANWAR
Ref By. : Dr.
Serial No : 15845

Age : 32 Yrs.
Sex : Male
Date : 13/11/2022

URINE EXAMINATION REPORT

Test	Result(s)
CHEMICAL	
SUGAR - (F)	NIL
SUGAR - (PP)	NIL

[TECHNOLOGIST]

____ END OF REPORT ____

[PATHOLOGIST]

Dr. V. K. Malhotra
MD - Path & Micro.
RMC No. : 977



ई.सी.जी. | डिजिटल एक्सरे | टी. एम. टी. | ई. ई. जी. | ई. एम. जी. | एन. सी. वी. | बेरा | पी. एफ. टी. | ऑडियोलॉजी

ब्रह्म बाग, पुष्पक कोरियर के पास, इंदगाह रोड, जालोरी गेट, जोधापुर (राज.)

फोन : 0291-2620214 E-mail : srdmedical@gmail.com

THIS REPORT IS NOT VALID FOR MEDICO LEGAL PURPOSES



Pt Name : MANEESH PANWAR
Ref By. : Dr.
Serial No : 15845

Age : 32 Yrs.
Sex : Male
Date : 13/11/2022

STOOL EXAMINATION REPORT

Test	Result
PHYSICAL	
COLOUR	BROWN
CONSISTENCY	SOLID
MICROSCOPIC	
PUS CELLS	NIL
RED BLOOD CELLS	NIL
EPITHELIAL CELLS	NIL
BACTERIAL FLORA	NORMAL
HELMINTHIC OVA	NIL
PROTOZOA	NIL

[TECHNOLOGIST] _____ END OF REPORT _____

[PATHOLOGIST]

Dr. V. K. Malhotra
MD - Pain & Spine
RMC No.: 977

Complete Diagnostic Solution

ई.सी.जी. | डिजिटल एक्सरे | टी. एम. टी. | ई. ई. जी. | ई. एम. जी. | एन. सी. वी. | बेरा | पी. एफ. टी. | ऑडियोमैट्री

ब्रह्म बाग, पुष्पक कोरियर के पास, ईदगाह रोड, जालोरी गेट, जोधापुर (राज.)

फोन : 0291-2620214 E-mail : srdmedical@gmail.com

THIS REPORT IS NOT VALID FOR MEDICO LEGAL PURPOSES



MEDICAL CERTIFICATE

NAME : MANEESH PANWAR
AGE/SEX: 32Yrs/MALE

DATE-13-11-2022

HEIGHT-174CMS
BP-122/82

WEIGHT-77KG
PULSE- 74

BMI- 25.43

EYE SIGHT- BOTH EYESIGHT

RIGHT EYE: 6'6

LEFT EYE: -1.0

TEETH AND GUMS ARE HEALTHY.

THIS IS TO CERTIFY THAT MR.MANEESH PANWAR IS MEDICALLY & PHYSICALLY FIT & FINE FOR PERFORMING ALL TYPE OF PROFESSIONAL WORK.

Dr. Nand Kishore Chh. Singh
MD-Physician & Cardiologist
RMC No.-2017/haryani
JOURNUR

ई.सी.जी. | डिजीटल एक्सरे | टी. एम. टी. | ई. ई. जी. | ई. एम. जी | एन. सी. वी. | बेरा | पी. एफ. टी. | ऑडियोमैट्री

ब्रह्म बाग, पुष्पक कोरियर के पास, ईदगाह रोड, जालोरी गेट, जोधापुर (राज.)

फोन : 0291-2620214 E-mail : srdmedical@gmail.com

THIS REPORT IS NOT VALID FOR MEDICO LEGAL PURPOSES

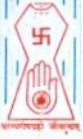

AMIT CAT SCAN CENTRE PVT. LTD.

C-16-A, Shastri Nagar, Opp. M.D.M Hospital
Jodhpur, Ph. : 0291-2614194

DR. AMIT JAIN

M.D. Radiodiagnosis
D.A. Anaesthesia
Consultant Radiologist
Reg. No. 30845/11249



NAME: MR. MANEESH PANWAR **AGE: YRS/M**

REF BY: DR. N.K. CHHANGANI **DATE: 13/11/22** **R.NO:987**

SONOGRAPHY OF ABDOMEN & PELVIS

LIVER:

NORMAL IN SIZE, SHAPE AND CONTOUR AND HAVING SMOOTH MARGINS. HEPATIC PARENCHYMAL ECHOTEXTURE IS NORMAL HOMOGENOUS AND UNIFORM. HEPATIC VEINS ARE NORMAL IN DISTRIBUTION AND CALIBER. NO FOCAL PARENCHYMAL LESION IS SEEN. INTRAHEPATIC BILIARY RADICLES ARE NORMAL.

PORTAL VEIN:

PORTAL VEIN IS NORMAL IN DIAMETER . PORTAL VEIN AND ITS RAMIFICATION IS NORMAL. NO INTRALUMINAL ECHOES ARE SEEN.

GALL BLADDER:

SEEN IN NORMAL DISTENTION. WALLS ARE SMOOTH AND NORMAL IN THICKNESS. LUMEN IS ANECHOIC.

COMMON BILE DUCT:

COMMON BILE DUCT IS NORMAL IN DIAMETER . CBD IS NORMAL IN COURSE AND CALIBER. NO INTRALUMINAL MASS LESION OR CALCULI ARE SEEN.

PANCREAS:

HEAD, BODY AND TAIL ARE NORMAL IN DIMENSION AND ECHOTEXTURE.PANCREATIC DUCT IS NORMAL IN CALIBER.

SPLEEN:

NORMAL IN SIZE, SHAPE AND CONTOUR. PARENCHYMAL ECHOTEXTURE IS NORMAL. SPLENIC VEIN IS NORMAL IN COURSE AND CALIBER.

RIGHT KIDNEY:

RT. KIDNEY: - 113 X 53 MM.

RIGHT KIDNEY IS NORMAL IN SIZE, SHAPE AND CONTOUR. PARENCHYMAL ECHOTEXTURE IS NORMAL. CORTICO-MEDULLARY DIFFERENTIATION IS MAINTAINED. CENTRAL ECHO-COMPLEXES IS NORMAL.

CONT.PAGE NO. 2



NOT VALID FOR MEDICOLEGAL CASES

भ्रण लिंग परीक्षण की शिकायत
104 टोल फ्री सेवा पर की जा सकती है।



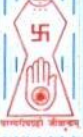

AMIT CAT SCAN CENTRE PVT. LTD.

C-16-A, Shastri Nagar, Opp. M.D.M Hospital
Jodhpur, Ph. : 0291-2614194

DR. AMIT JAIN

M.D. Radiodiagnosis
D.A. Anaesthesia
Consultant Radiologist
Reg. No. 30845/11249



:: 2::

LEFT KIDNEY:

LT. KIDNEY: - 113 X 52 MM.

LEFT KIDNEY IS NORMAL IN SIZE, SHAPE AND CONTOUR. PARENCHYMAL ECHOTEXTURE IS NORMAL. CORTICO-MEDULLARY DIFFERENTIATION IS MAINTAINED. CENTRAL ECHO-COMPLEXES IS NORMAL.

URINARY BLADDER:

SEEN IN FULL DISTENTION. WALLS ARE SMOOTH AND NORMAL IN THICKNESS. LUMEN IS ANECHOIC.

PROSTATE:

NORMAL IN SIZE MEASURING 33 X 31 X 30 MM. NORMAL ECHOTEXTURE. NORMAL CAPSULE. NO MASS SEEN. VOL.16 ML.

RETROPERITONEUM:

NO MASS LESION OR LYMPHNODES IS SEEN IN RETROPERITONEUM. ABDOMINAL AORTA AND INFERIOR VENA CAVA IS NORMAL IN COURSE AND CALIBER.

PERITONEUM:

NO ASCITES IS SEEN.

OPINION:

U.S.G FINDINGS SUGGESTIVE OF

- **NORMAL: - LIVER, G.B, PANCREAS, SPLEEN, KIDNEYS, URINARY BLADDER, PROSTATE & RETROPERITONEUM.**

- SUGGESTED CLINICAL CORRELATION.

- THIS IS ONLY PROFESSIONAL OPINION BASED ON IMAGING FINDINGS AND NOT THE DIAGNOSIS.

- IT SHOULD BE CORRELATED CLINICALLY TO ARRIVE AT PROPER CONCLUSION.

DR. AMIT JAIN.

MD.

(CONSULTANT RADIOLOGIST)

Dr. AMIT JAIN

M.D. Consultant Radiologist

Reg. No. 30845/11249

NOT VALID FOR MEDICOLEGAL CASES

भ्रण लिंग परीक्षण की शिकायत
104 टोल फ्री सेवा पर की जा सकती है।



