

Transport Department Government of Delhi
 Licence to Drive Vehicles Throughout India

Licence No. : DL-1320100052656 (P) N
 Name : SHUBHAM SINGHAL
 S/W/D : PARDEEP KUMAR SINGHAL
 DOB : 15/08/1991 BG : U
 Address : 299/OLD POST OFFICE STREET
 CIRCULAR ROAD SHAHDARA DELHI
 110032

Authorisation to Drive : M.CYL.
 LHV-NT

Date of Issue : 24/04/2010
 24/04/2010

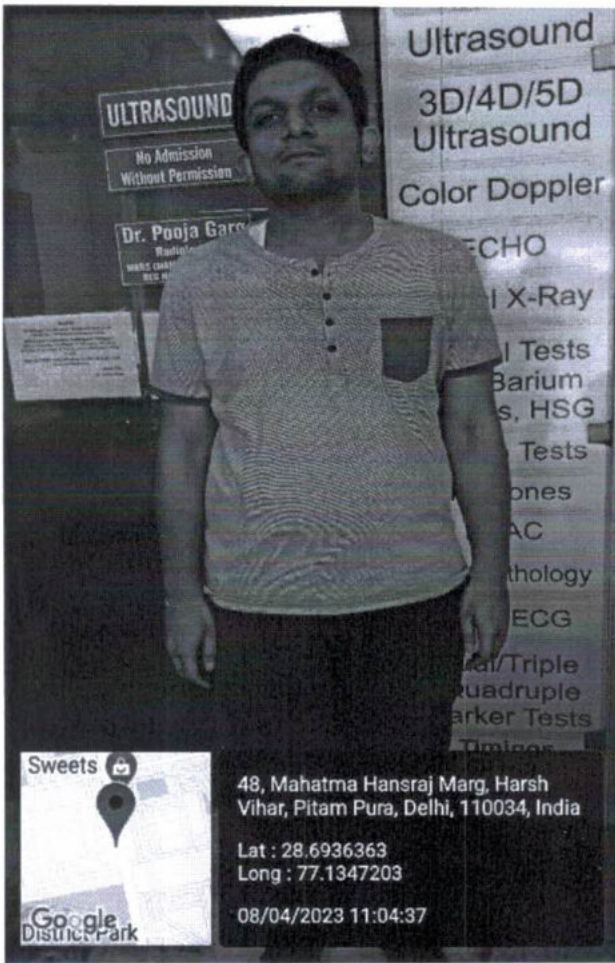
Issue Date : 24/04/2010
 Validity : 23/04/2030
 Inv Carr No : NA

(Holder's Signature)
 Issuing Authority (EZ-II)


Dr. NITIN AGARWAL
 MBBS, MD
 Regn. No. DMC-R-1436

for lab test
 use only
 Shubham

ONEPLUS ULTRASOUND LAB
 47, Harsh Vihar, Pitam Pura,
 Delhi-110034
 Ph. 011-42480101, 9599913051
 E-mail: oneplusul@gmail.com



Shubham

[Signature]

Dr. NITIN AGARWAL
MBBS, MD
Regn. No. DMC-R-1436

ONEPLUS ULTRASOUND LAB
47, Harsh Vihar, Pitam Pura,
Delhi-110034
Ph. 011-42480101, 9599913051
E-mail: oneplusul@gmail.com





OnePLUS
Ultrasound Lab

QUALITY FIRST... ALWAYS!

Dr. Nitin Agarwal

Pathologist & Director
Ex. Sr. Res. MAMC
& Lok Nayak Hospital
Ex. Chief of Lab Dr. Lal Path Labs.

Dr. Pooja (Garg) Agarwal

Radiologist & Director
MAMC & Lok Nayak Hospital

To
The oneplus ultrasound lab

8/4/2023

Re: Unwillingness to go for stool test

I don't want my stool test to be conducted

Thanks & regards

Shrestha Singh

Shrestha

9582555115

Do's corporate health checking

Dr. NITIN AGARWAL
MBBS, MD
Regn. No. DMC-R-1436

ONEPLUS ULTRASOUND LAB
47, Harsh Vihar, Pitam Pura,
Delhi-110034
Ph. 011-42480101, 9599913051
E-mail: oneplusul@gmail.com

47, Harsh Vihar, Pitampura, New Delhi-110034 | Ph.: 011-42480101, 9599913051
E-mail: oneplusul@gmail.com | Web.: www.oneplusul.in

Clinical correlation is essential for final diagnosis. • If test results are unsatisfactory please contact personally or on phone. • This report is for perusal of doctors only.
• All disputes Subject to Delhi Jurisdiction only. • Not for medicolegal purposes. • All congenital anomalies in a foetus may not be diagnosed in routine obstetric ultrasound.

ONEPLUS ULTRASOUND LAB

47, HARSH VIHAR PITAMPURA DELHI 110034

Mr. SHUBHAM SINGHAL

ID : 999

H/Wt : 176/96

Recorded : 8-4-2023 10:36

TREADMILL TEST SUMMARY REPORT

Protocol: BRUCE

History:

Medication 1 :

Medication 2 :

Medication 3 :

PHASE	PHASE TIME	STAGE TIME	SPEED (Km./Hr.)	GRADE (%)	H.R. (BPM)	B.P. (mmHg)	RPP X100	II	ST LEVEL (mm) V2	V5	METS
SUPINE											
STANDING											
STAGE 1	2:59	2:59	2.70	10.00	91	134/84	100	1.7	2.6	2.3	4.80
STAGE 2	5:59	2:59	4.00	12.00	73	144/86	105	1.1	0.0	0.8	7.10
STAGE 3	8:59	2:59	5.40	14.00	128	156/88	199	1.0	-0.2	0.6	10.00
STAGE 4	11:59	2:59	6.70	16.00	158	164/90	259	2.8	-0.1	2.1	14.00
STAGE 5	12:14	0:14	8.00	18.00	161	170/92	273	2.3	0.2	1.7	14.47
PEAK EXER	12:23	0:23			165	170/92	280	2.4	0.1	2.1	14.77
RECOVERY	2:59	2:59	0.00	0.00	91	136/84	123	1.7	0.7	1.3	

RESULTS

Exercise Duration : 12.23 Minutes
 Max Heart Rate : 165 bpm 87 % of target heart rate 189 bpm
 Max Blood Pressure : 170/92 mmHg
 Max Work Load : 14.77 METS
 Reason of Termination :

IMPRESSIONS

negative for ischemic change

DIPANK GUPTA
 Cardiologist
 Room No. 100

ONEPLUS ULTRASOUND LAB
 47, Harsh Vihar, Pitam Pura,
 Delhi-110034
 Ph: 011-42480101, 9599913051
 E-mail: oneplusul@gmail.com

Shubham

ONEPLUS ULTRASOUND LAB

47, HARSH VIHAR, PITAMPURA, DELHI- 110034

Mr. SHUBHAM SINGHAL
Age : 31M
Ref. by : MEDIVHEEL
Indication1 :
Indication2 :
Indication3 :
COMMENTS : Sinus Rhythm.

ID : 2210
HWM : 176/96
Recorded : 8-4-2023 10:34
Medication1 :
Medication2 :
Medication3 :

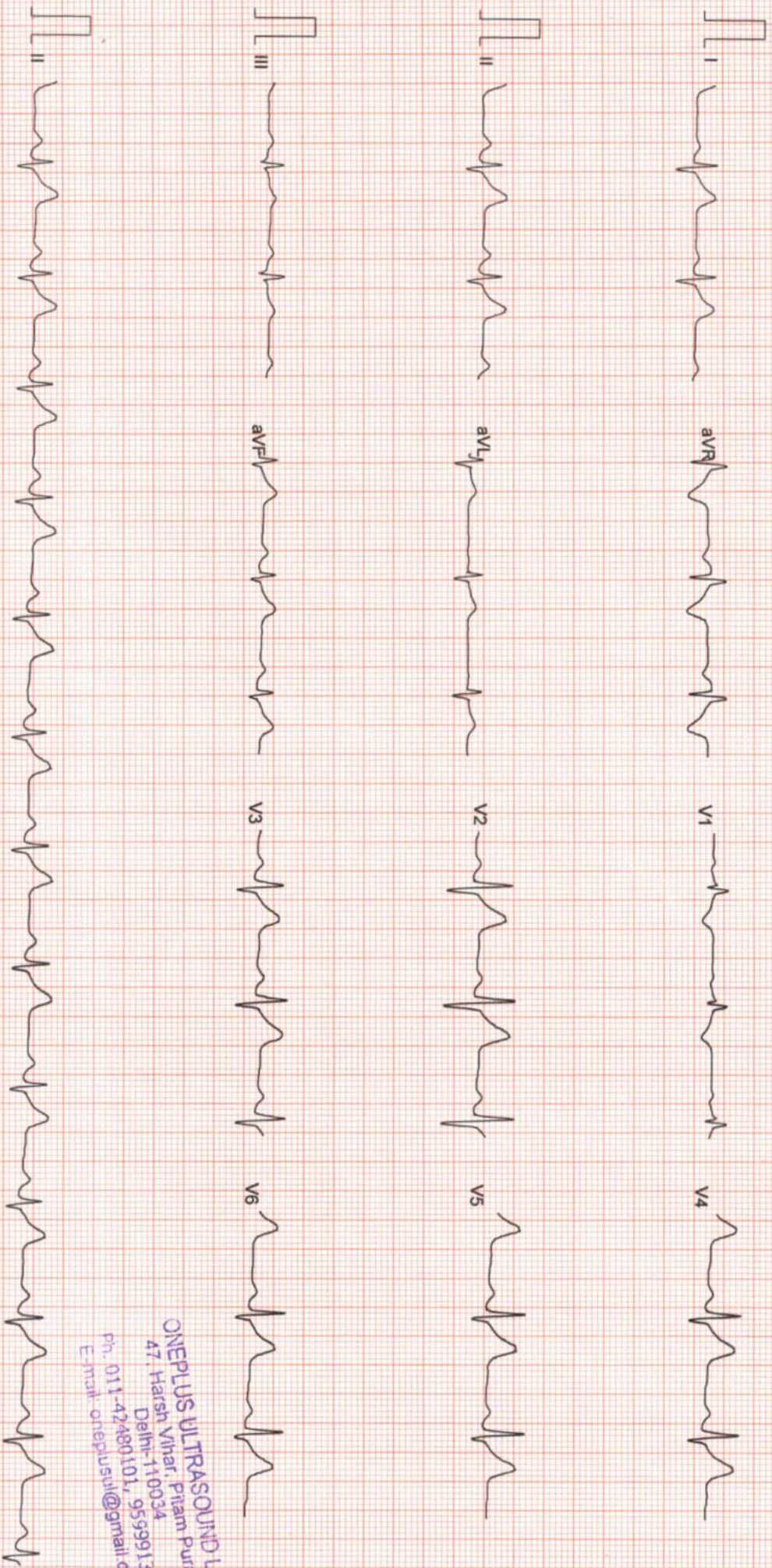
BPM : 78
BP : 134/84
P Axis : 62 deg
QRS Axis : 68 deg
T Axis : 46 deg

P duration : 123 msec
PR duration : 186 msec
QRS duration : 113 msec
QT interval : 316 msec
QTc interval : 347 msec

Raw E.C.G.(Seq)

Unconfirmed Report Reviewed By:

Cardiologist



Filtered

25mm/sec 10mm/mV

CardiCom, INDIA

ONEPLUS ULTRASOUND LAB
47, Harsh Vihar, Pitam Pura,
Delhi-110034
Ph: 011-42480101, 9599913051
E-mail: oneplusul@gmail.com

ONEPLUS ULTRASOUND LAB

SUPINE
PRETEST

ST @ 10mm/mV
80ms PostJ

Mr. SHUBHAM SINGHAL

I.D. : 999

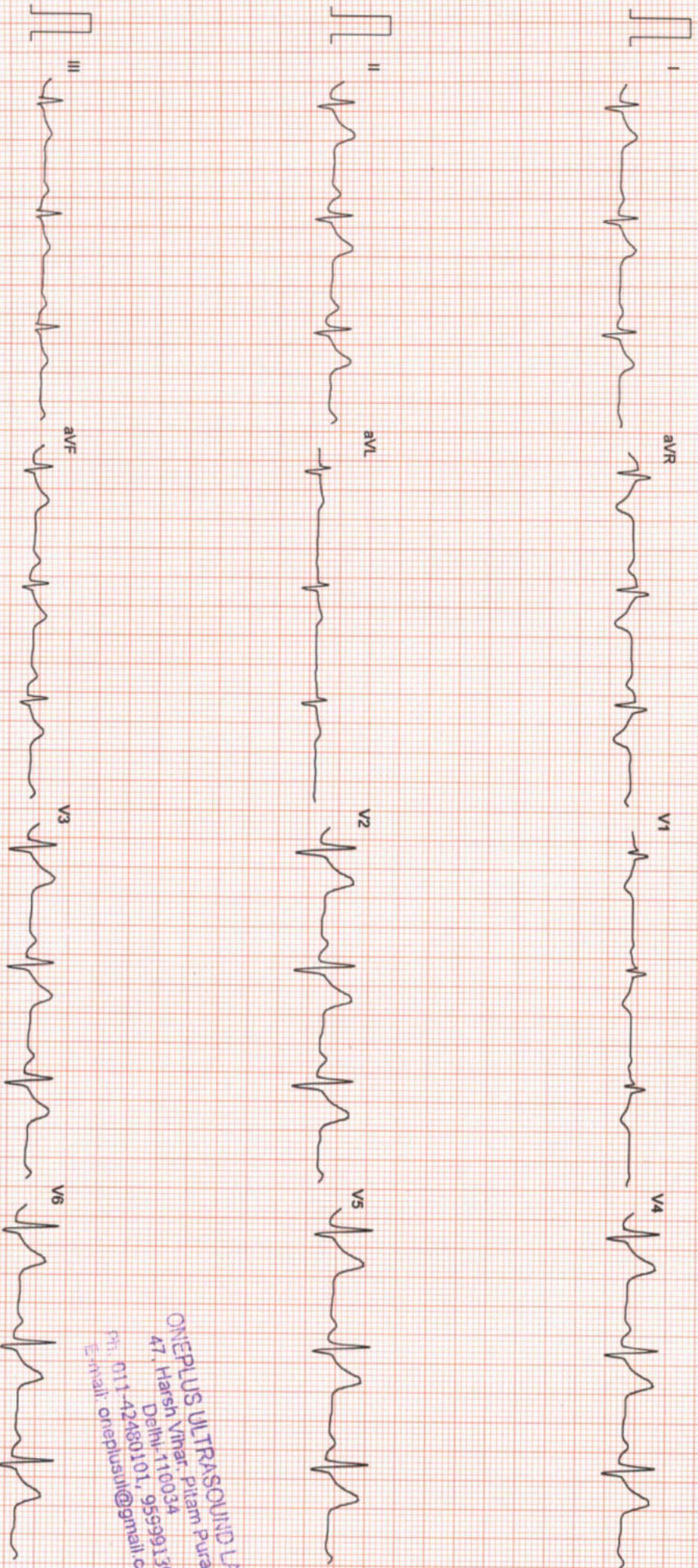
AGE/SEX : 31/M

RECORDED : 8-4-2023 10:36

RATE : 75 BPM

B.P. : 134/84 mmHg

RAW E.C.G.



ONEPLUS ULTRASOUND LAB
47, Harsh Vihar, Pitam Pura,
Delhi-110034
Ph: 011-42480101, 9559913051
E-mail: onepusult@gmail.com

Mr. SHUBHAM SINGHAL
I.D. : 999
AGE/SEX : 31/M

RECORDED : 8-4-2023 10:36

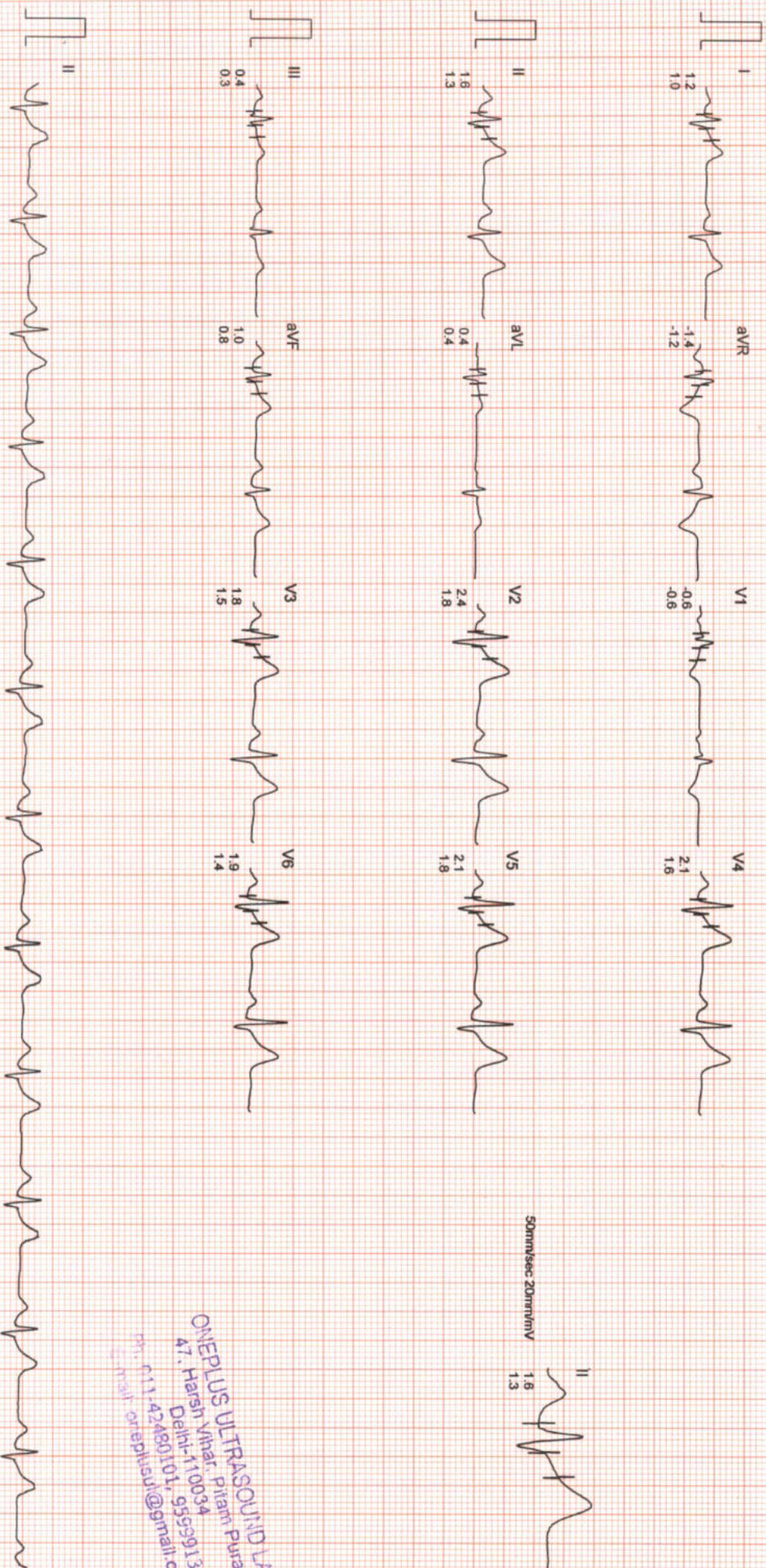
RATE : 73 BPM
B.P. : 134/84 mmHg

ONEPLUS ULTRASOUND LAB

STANDING
PRETEST

ST @ 10mm/mV
80ms PostJ

LINKED MEDIUM



ONEPLUS ULTRASOUND LAB
47, Harsh Vihar, Pitam Pura,
Delhi-110034
Delhi-110034, 9559913051
Dr. r.r. 42460101, 9559913051
Email: oneplusul@gnmail.com

ONEPLUS ULTRASOUND LAB

Mr. SHUBHAM SINGHAL

I.D. : 999

AGE/SEX : 31/M

RECORDED : 8-4-2023 10:36

RATE : 91 BPM
B.P. : 134/84 mmHg

BRUCE

EXERCISE 1

PHASE TIME : 2:59

STAGE TIME : 2:59

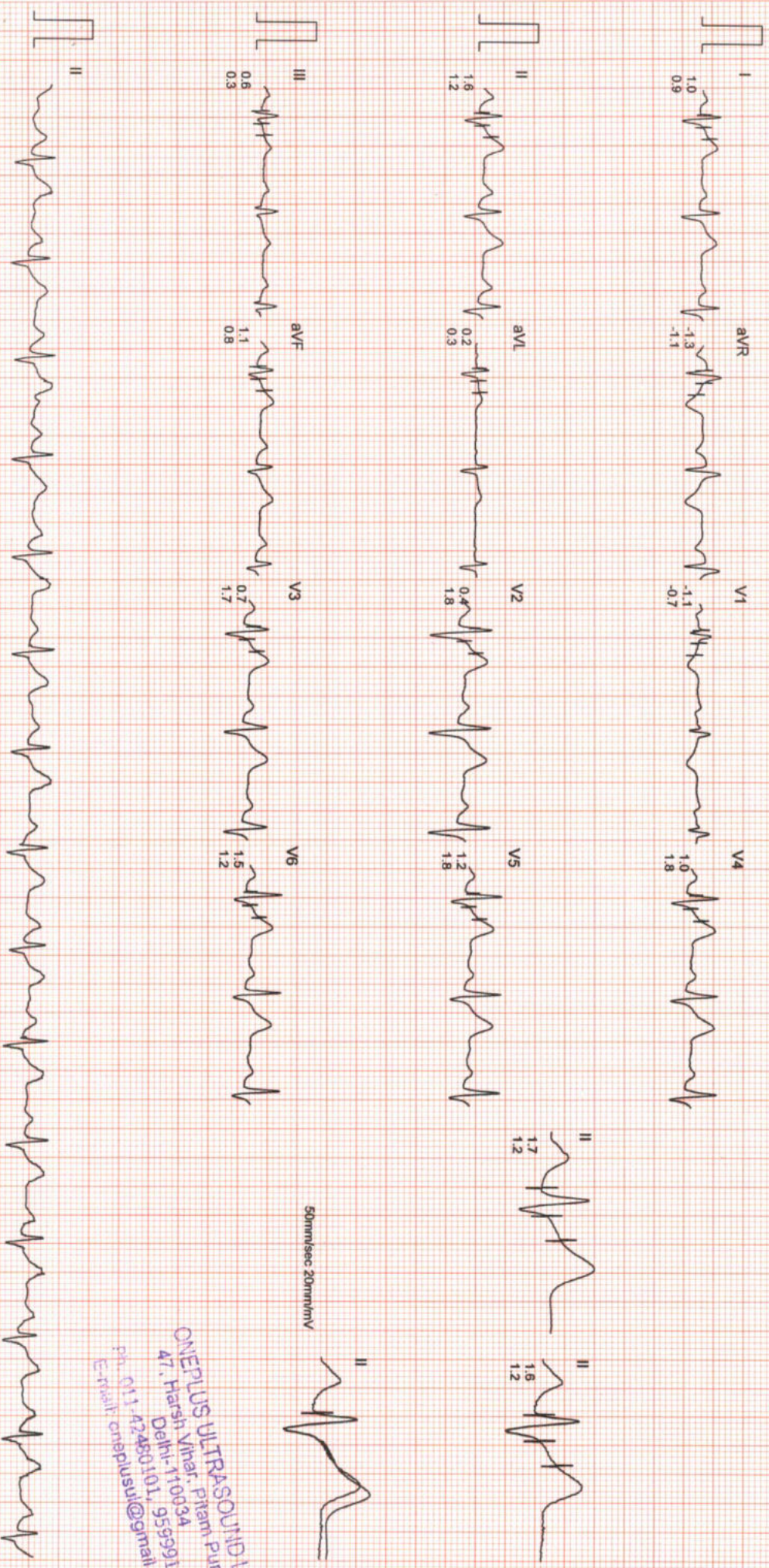
ST @ 10mm/mV

80ms PostJ

SPEED : 2.7 Km./Hr.

GRADE : 10.0 %

LINKED MEDIUM



ONEPLUS ULTRASOUND LAB
47, Harsh Vihar, Pitam Pura,
Delhi-110034
Ph: 011-42480101, 9599913051
E-mail: oneplusul@gmail.com

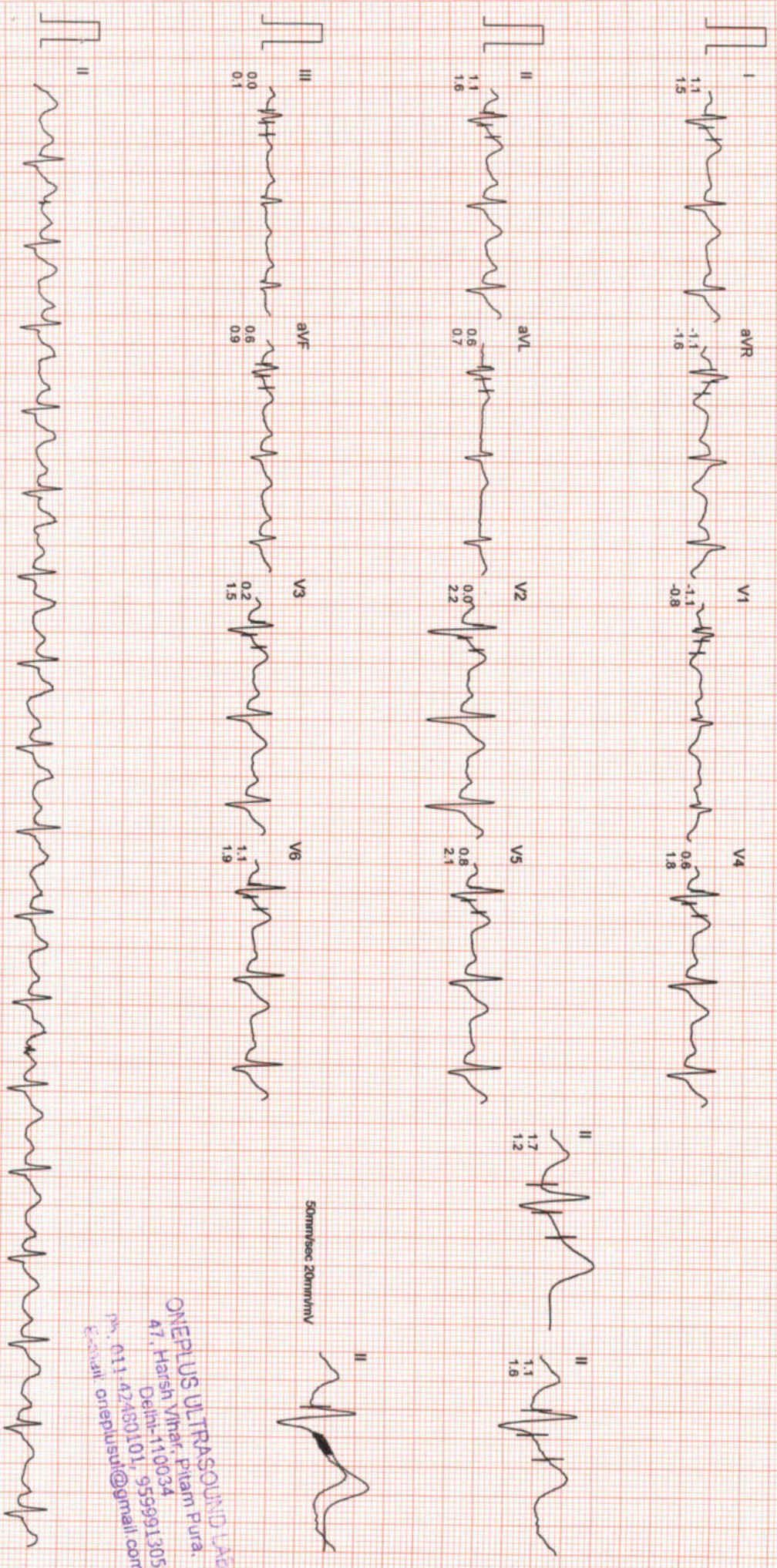
ONEPLUS ULTRASOUND LAB

Mr. SHUBHAM SINGHAL
 I.D. : 999
 AGE/SEX : 31/M
 RECORDED : 8-4-2023 10:36

RATE : 73 BPM
 B.P. : 144/86 mmHg

BRUCE
 EXERCISE 2
 PHASE TIME : 5:59
 STAGE TIME : 2:59

ST @ 10mm/mV
 80ms PostJ
 SPEED : 4.0 Km./Hr.
 GRADE : 12.0 %
 LINKED MEDIAN



Filtered Computer Corrected Baseline 25mm/sec - 10mm/mV Cardiacom, INDIA Ph.:091-731-2620740, TeleFax:091-731-2431214

ONEPLUS ULTRASOUND LAB
 47, Harsh Vihar, Pitam Pura,
 Delhi-110034
 Ph.: 011-42480101, 9599913051
 E-mail: oneplusul@gmail.com

ONEPLUS ULTRASOUND LAB

MR. SHUBHAM SINGHAL

I.D. : 999

AGE/SEX : 31/M

RECORDED : 8-4-2023 10:36

RATE : 128 BPM

B.P. : 156/88 mmHg

BRUCE

EXERCISE 3

PHASE TIME : 8:59

STAGE TIME : 2:59

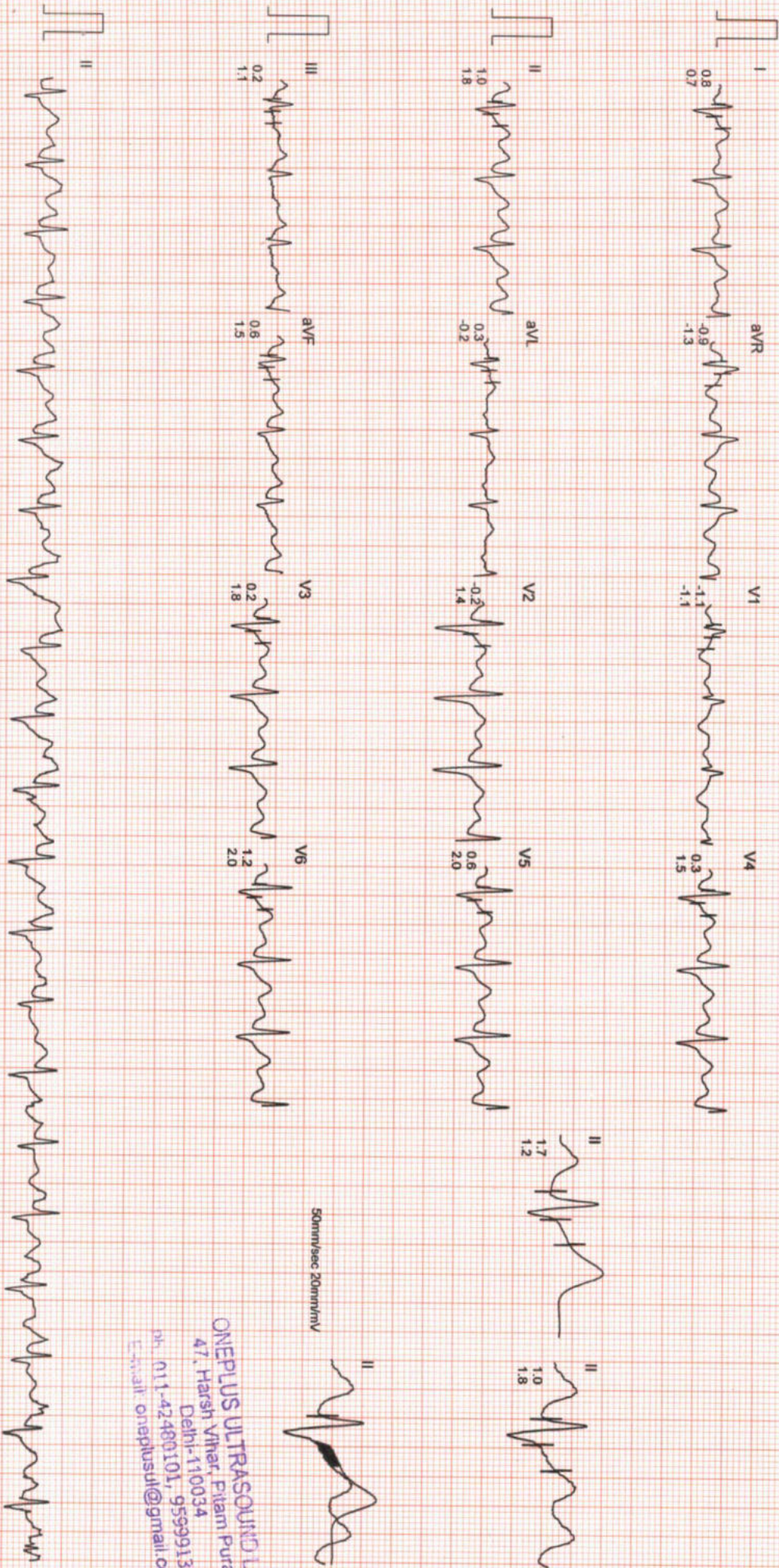
ST @ 10mm/mV

80ms PostJ

SPEED : 5.4 Km./Hr.

GRADE : 14.0 %

LINKED MEDIAN



Filtered Computer Corrected Baseline

25mm/sec 10mm/mV

CardiCom, INDIA Ph.:091-731-2620740, Telefax:091-731-2431214

ONEPLUS ULTRASOUND LAB
47, Harsh Vihar, Pitam Pura,
Delhi-110034
Ph. 011-42480101, 9599913051
E-mail: onepplusul@gmail.com

ONEPLUS ULTRASOUND LAB

Mr. SHUBHAM SINGHAL

I.D. : 999

AGE/SEX : 31/M

RECORDED : 8-4-2023 10:36

RATE : 158 BPM
B.P. : 164/90 mmHg

BRUCE

EXERCISE 4

PHASE TIME : 11:59

STAGE TIME : 2:59

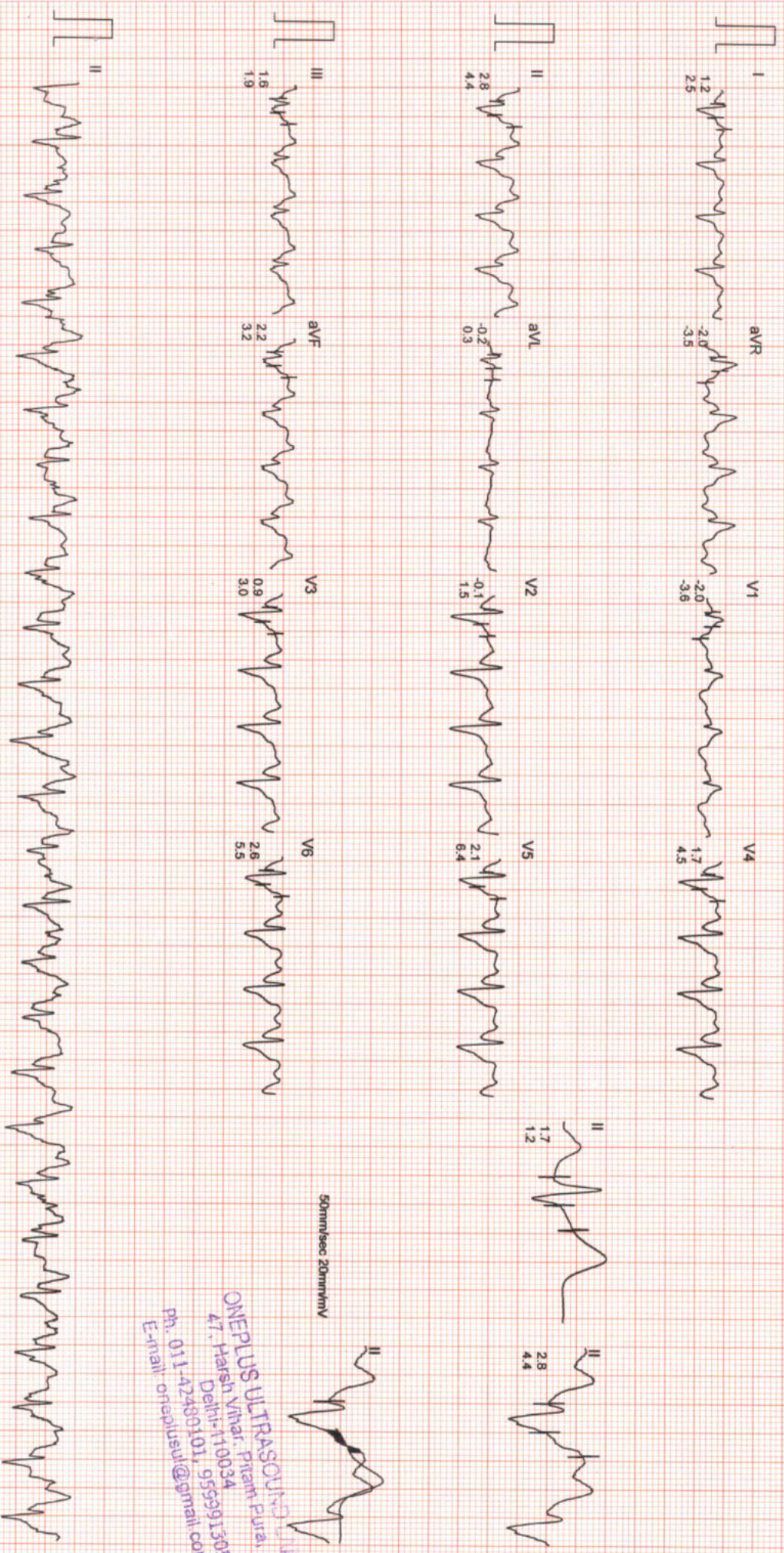
ST @ 10mm/mV

80ms PostJ

SPEED : 6.7 Km./HR

GRADE : 16.0 %

LINKED MEDIAN



50mm/Sec 20mm/mV

ONEPLUS ULTRASOUND LLP
47, Harsh Vihar, Pitam Pura,
Delhi-110034
Ph: 011-42480101, 9593913051
E-mail: oneplusul@gmail.com

Filtered Computer Corrected Baseline

25mm/Sec 10mm/mV

CardiCom, INDIA Ph.:091-731-2620740, Telefax:091-731-2431214

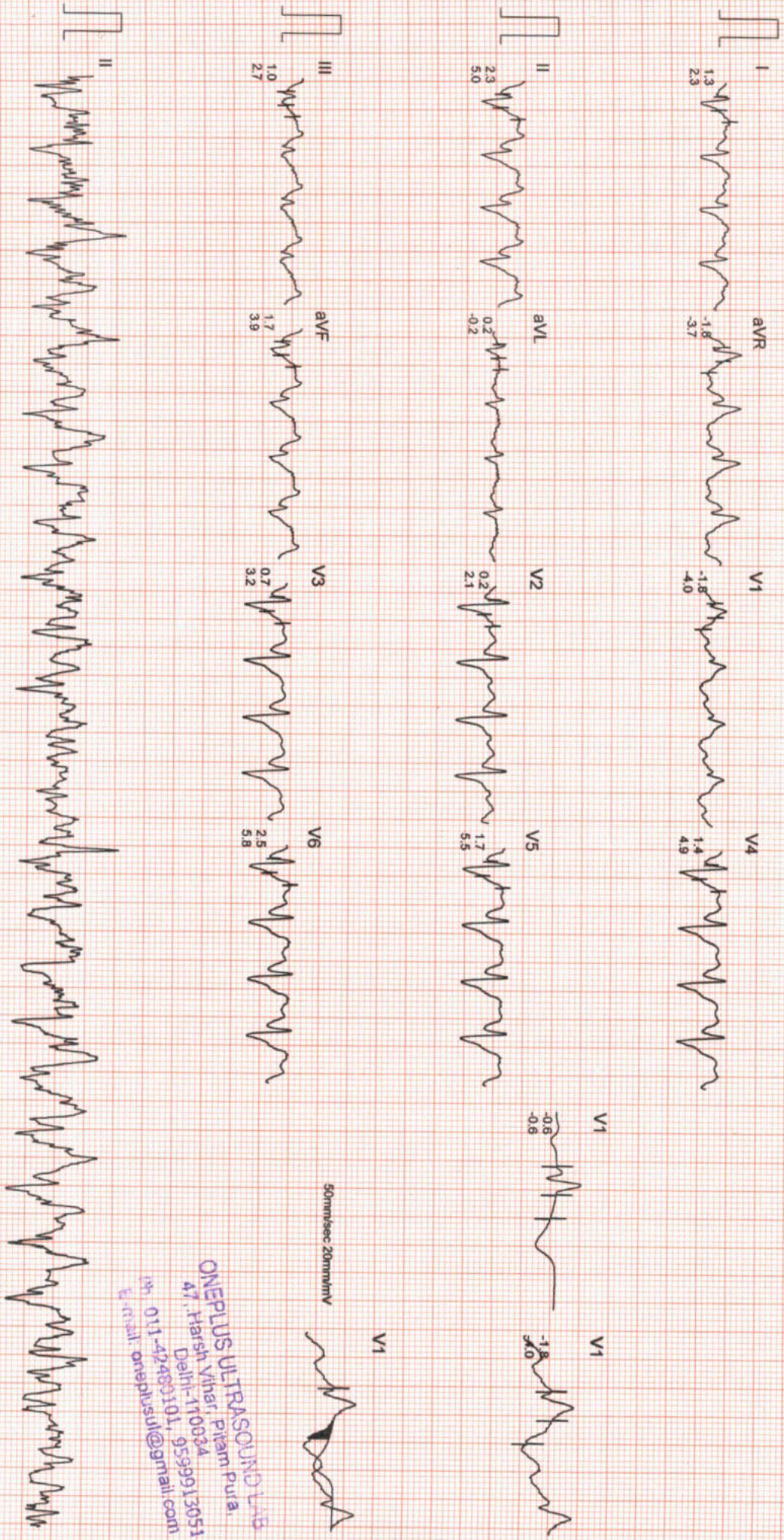
ONEPLUS ULTRASOUND LAB

Mr. SHUBHAM SINGHAL
I.D. : 999
AGE/SEX : 31/M
RECORDED : 8-4-2023 10:36

RATE : 161 BPM
B.P. : 170/92 mmHg

BRUCE
EXERCISE 5
PHASE TIME : 12:14
STAGE TIME : 0:14

ST @ 10mm/mV
80ms PostJ
SPEED : 8.0 Km./Hr
GRADE : 18.0 %
LINKED MEDIAN



ONEPLUS ULTRASOUND LAB
47, Harsh Vihar, Pitam Pura,
Delhi-110034
Ph: 011-42483101, 9599913051
E-mail: oneplusul@gmail.com

ONEPLUS ULTRASOUND LAB

Mr. SHUBHAM SINGHAL

I.D. : 999

AGE/SEX : 31/M

RECORDED : 8-4-2023 10:36

RATE : 165 BPM

B.P. : 170/92 mmHg

BRUCE

PEAK EXER

PHASE TIME : 12:23

STAGE TIME : 0:23

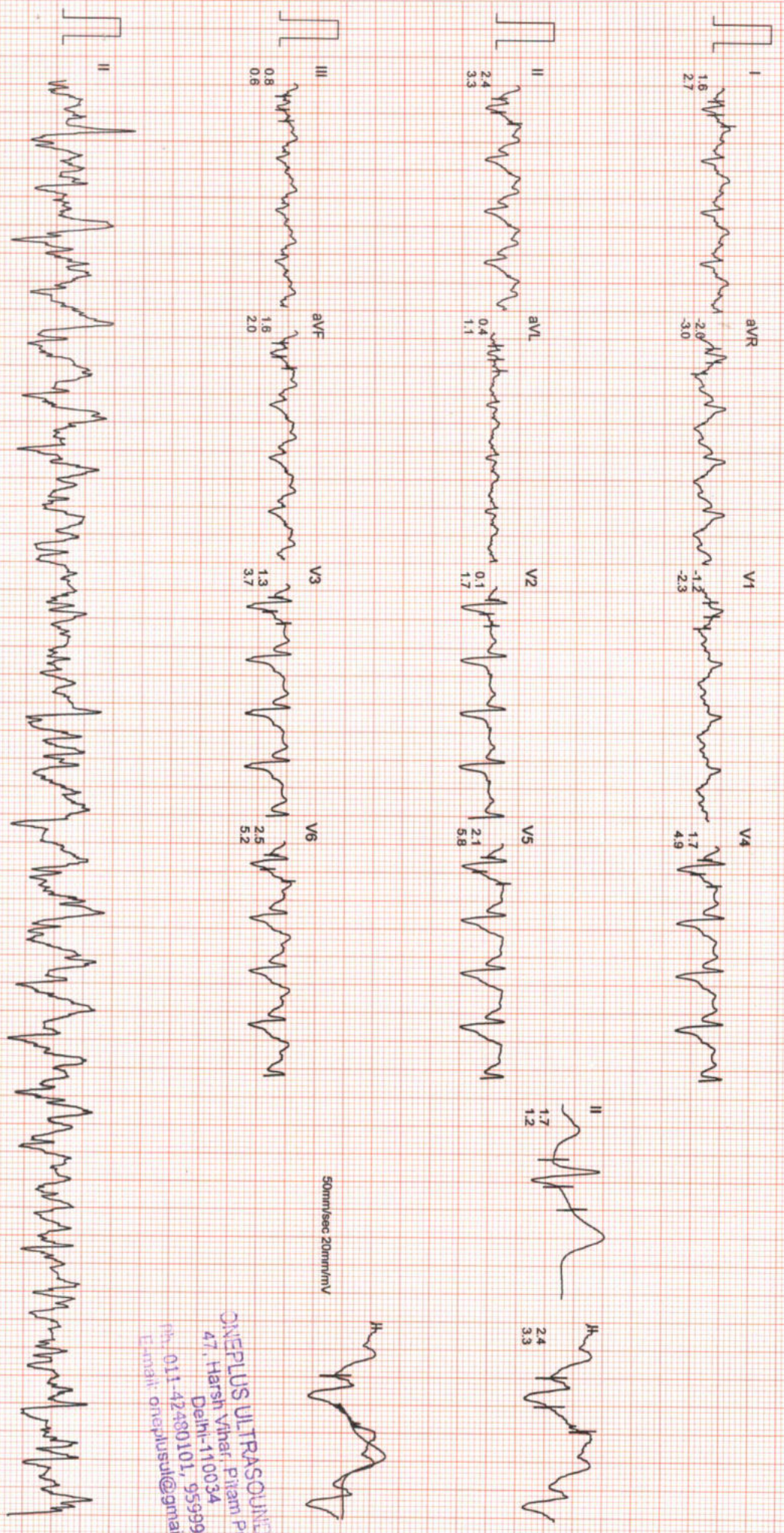
ST @ 10mm/mV

80ms PostJ

SPEED : 8.0 Km./Hr.

GRADE : 18.0 %

LINKED MEDIUM



Filtered Computer Corrected Baseline 25mm/sec - 10mm/mV CardCom, INDIA Ph.:091-731-2620740, Telefax:091-731-2431214

ONEPLUS ULTRASOUND LAB
 47, Harsh Vihar, Pitam Pura,
 Delhi-110034
 Ph: 011-42480101, 9599913051
 Email: onepusul@gmail.com

ONEPLUS ULTRASOUND LAB

Mr. SHUBHAM SINGHAL

I.D. : 999

AGE/SEX : 31/M

RECORDED : 8-4-2023 10:36

RATE : 91 BPM

B.P. : 136/84 mmHg

BRUCE

RECOVERY

PHASE TIME : 2:59

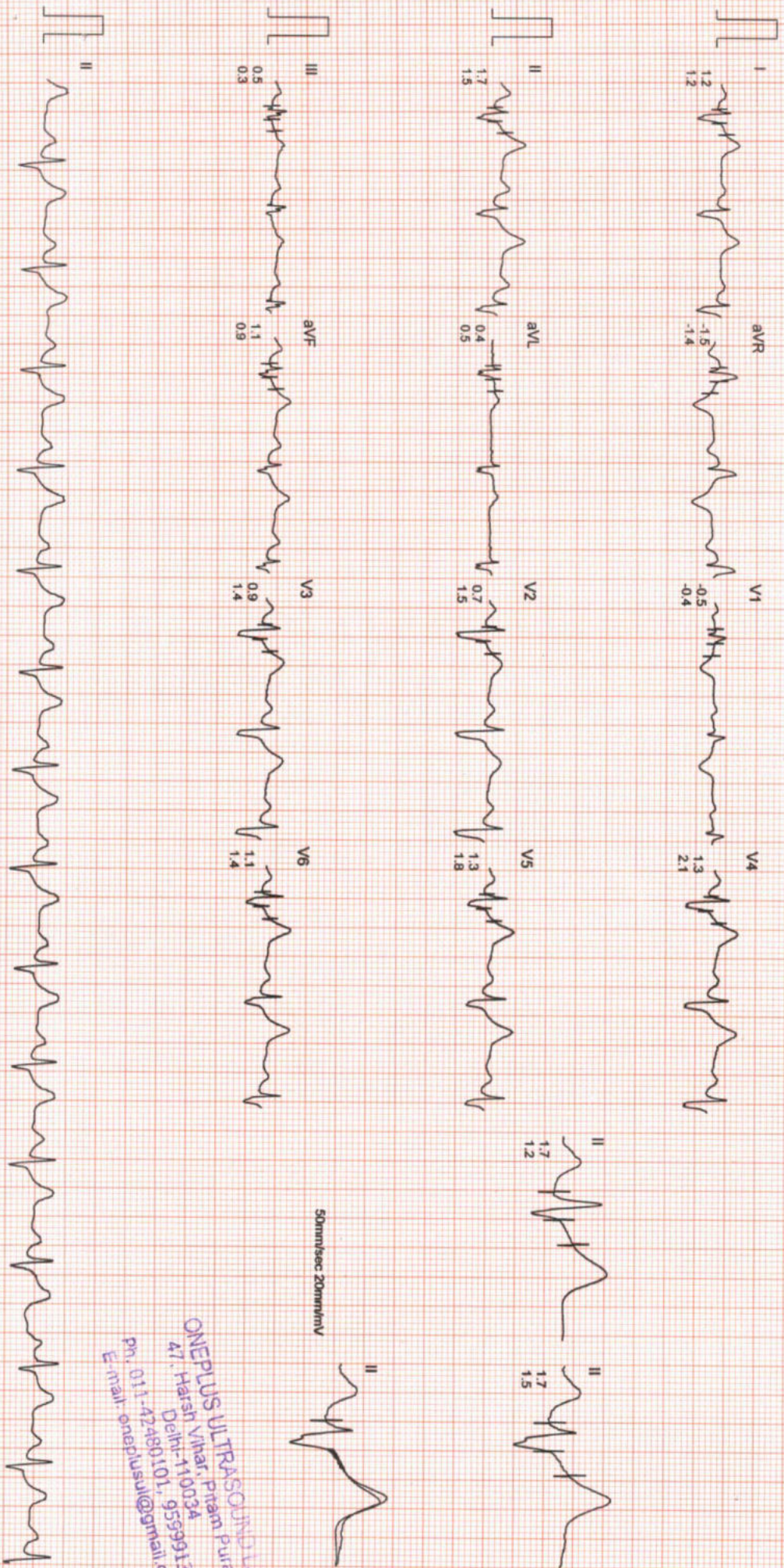
ST @ 10mm/mV

80ms PostJ

SPEED : 0.0 Km./Hr.

GRADE : 0.0 %

LINKED MEDIAN

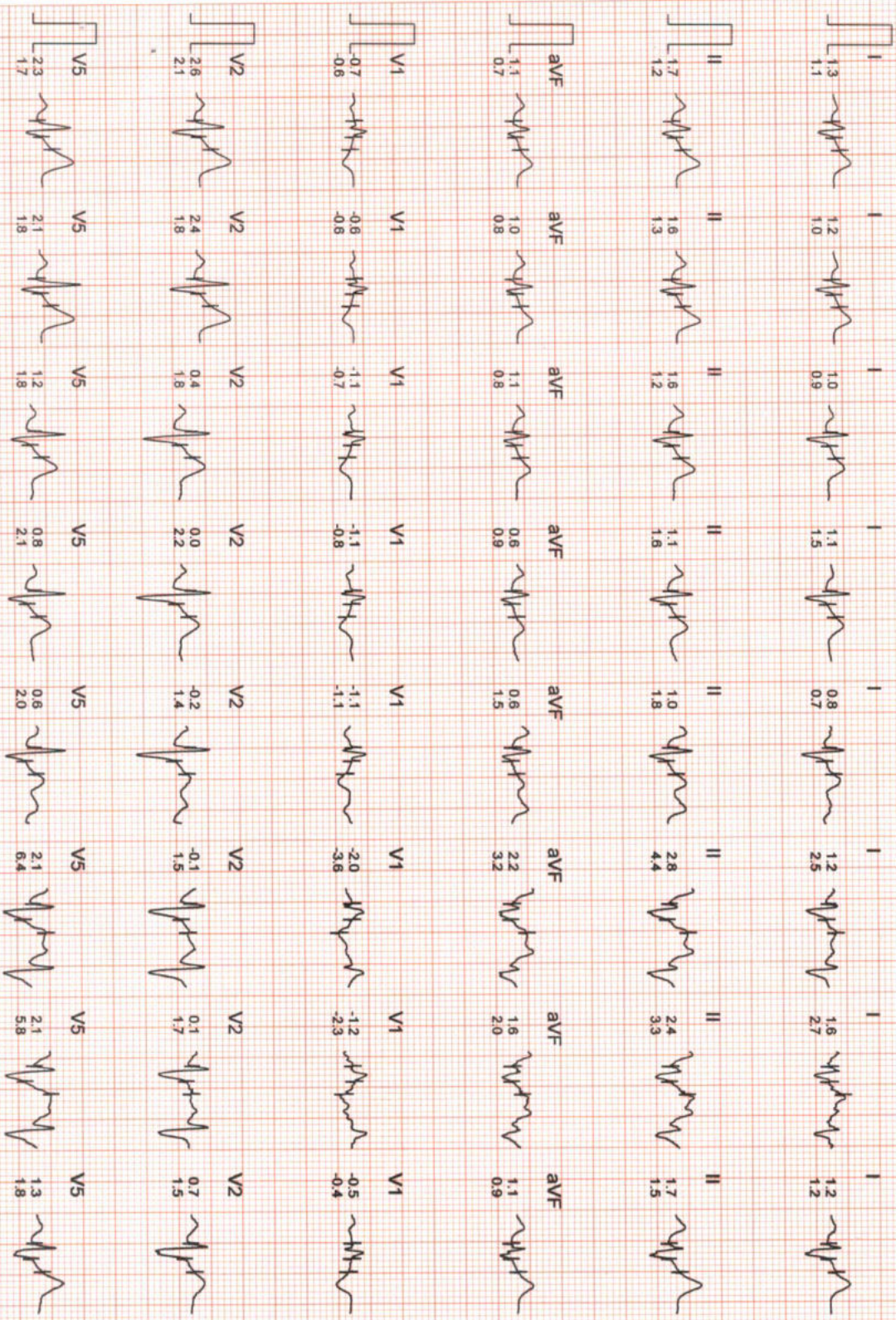


ONEPLUS ULTRASOUND LAB
 47, Harsh Vihar, Pitampura,
 Delhi-110034
 Ph. 011-42480101, 95599915051
 E-mail: oneplusul@gnail.com

ONEPLUS ULTRASOUND LAB

AVG E.C.G

STAGE	TIME	HR	BP	SpO2
SUPINE	0:00	75 bpm	134/84	80% PostU
STANDING	0:00	73 bpm	134/84	80% PostU
STAGE 1	2:50	2:59	2.7Kmph	10.0%
STAGE 2	5:50	2:59	4.0Kmph	12.0%
STAGE 3	8:50	2:59	5.4Kmph	14.0%
STAGE 4	11:50	2:59	6.7Kmph	18.0%
PEAK EXERCISE	12:23	0:23	8.0Kmph	18.0%
RECOVERY	2:39	0:00	0.0Kmph	0.0%



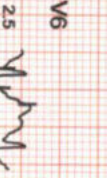
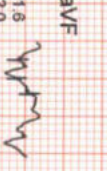
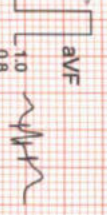
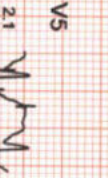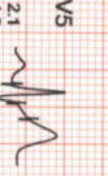
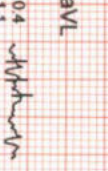
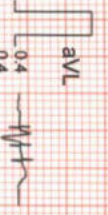

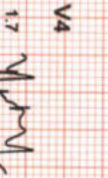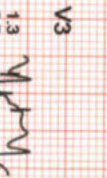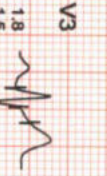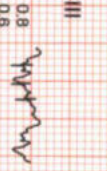
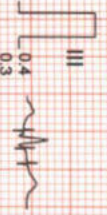
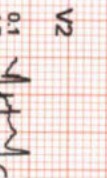
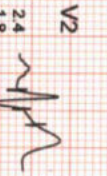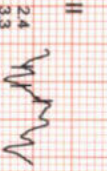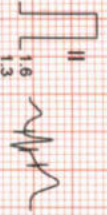
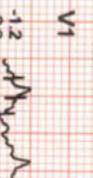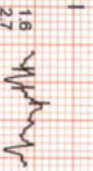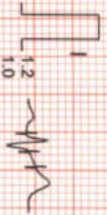
ONEPLUS ULTRASOUND LAB
 47, Hareh Vihar, Piam Pura,
 Delhi-110034
 Ph. 011-42480101, 9559913051
 E-mail: oneplusul@gmail.com

STANDING
0.0Kmph
0.0%
73 bpm
B.P. 134/84
80ms PostJ

PEAK EXERCISE
12.23
0.23
8.0Kmph
18.0%
165 bpm
B.P. 170/92
80ms PostJ

STANDING
0.0Kmph
0.0%
73 bpm
B.P. 134/84
80ms PostJ

PEAK EXERCISE
12.23
0.23
8.0Kmph
18.0%
165 bpm
B.P. 170/92
80ms PostJ



ONEPLUS ULTRASOUND LAB
47, Hansh Vihar, Pitam Pura,
Delhi-110034
Ph. 011-42480101, 9553913053
Email: onepusul@gmail.com



OnePLUS Ultrasound Lab

QUALITY FIRST... ALWAYS!

Dr. Nitin Agarwal
Pathologist & Director
Ex. Sr. Res. MAMC
& Lok Nayak Hospital
Ex. Chief of Lab Dr. Lal Path Labs.

Dr. Pooja (Garg) Agarwal
Radiologist & Director
MAMC & Lok Nayak Hospital



NAME	:Mr. SHUBHAM SINGHAL	Barcode No	:10142002
AGE/GENDER	:31 YRS/Male	SPECIMEN DATE	:08/Apr/2023 09:28AM
PATIENT ID	:112206	SPECIMEN RECEIVED	:08/Apr/2023 09:34AM
REFERRED BY	:Dr. MEDIWHEEL	REPORT DATE	:08/Apr/2023 02:09PM
CENTRE NAME	:ONEPLUS ULTRASOUND LAB	LAB NO.	:012304080015

Test Name	Result	Unit	Ref. Range
-----------	--------	------	------------

HAEMATOLOGY

Medi Wheel Health checkup < 40 Male

<u>Glycosylated Hemoglobin (HbA1c)</u>	5.2	%	Non Diabetic adults <5.7 Prediabetic (at risk) 5.7-6.4 Diabetes >6.4
--	-----	---	--

<u>Estimated average blood glucose (eag)</u>	103
Reference range (mg/dl):	

90 - 120:Excellent control, 121 - 150:Good Control, 151 - 180:Average Control, 181 - 210:Action Suggested

>211:Panic value

<u>BLOOD GROUP (ABO)</u>	B
<u>Rh typing</u>	POSITIVE

NOTE :

- * Apart from major A,B,H antigens which are used for ABO grouping and Rh typing, many minor blood group antigens exist. Agglutination may also vary according to titre of antigen and antibody.
- * So before transfusion, reconfirmation of blood group as well as cross-matching is needed.
- * Presence of maternal antibodies in newborns, may interfere with blood grouping.
- * Auto agglutination (due to cold antibody, falciparum malaria, sepsis, internal malignancy etc.) may also cause erroneous result.

CBC

Haemoglobin	14.5	g/dl	13.0-17.0
Total Leucocyte Count	7600	/cumm	4000-10000
<u>Differential leucocyte count</u>			
Neutrophils	73.3	%	40-80
Lymphocyte	22.10	%	20-40
Monocytes	2.00	%	2-10
Eosinophils	2.0	%	1-6
Basophils	0.6	%	0-2
RBC Count	5.10	million/cumm	4.5 - 5.5

Checked By.

DR. NITIN AGARWAL
MBBS, MD (PATHOLOGIST)
Regn. No. DMC-R-1436

47, Harsh Vihar, Pitampura, New Delhi-110034 | Ph.: 011-42480101, 9599913051

E-mail: oneplusul@gmail.com | Web.: www.oneplusul.in

Page 1 of 5



OnePLUS Ultrasound Lab

QUALITY FIRST... ALWAYS!

Dr. Nitin Agarwal
Pathologist & Director
Ex. Sr. Res. MAMC
& Lok Nayak Hospital
Ex. Chief of Lab Dr. Lal Path Labs.

Dr. Pooja (Garg) Agarwal
Radiologist & Director
MAMC & Lok Nayak Hospital



NAME	:Mr. SHUBHAM SINGHAL	Barcode No	:10142002
AGE/GENDER	:31 YRS/Male	SPECIMEN DATE	:08/Apr/2023 09:28AM
PATIENT ID	:112206	SPECIMEN RECEIVED	:08/Apr/2023 09:34AM
REFERRED BY	:Dr. MEDIWHEEL	REPORT DATE	:08/Apr/2023 02:09PM
CENTRE NAME	:ONEPLUS ULTRASOUND LAB	LAB NO.	:012304080015

Test Name	Result	Unit	Ref. Range
PCV(Hematocrit)	48.5	%	40-50
MCV	95.5	fL	83-101
MCH	28.5	Pg	27-32
MCHC	29.8	G/dL	32-35
RDW-CV	13.8	%	11.4-14.0
Platelet count	370000	/cumm	150000-450000

BIOCHEMISTRY

<u>Blood sugar fasting</u>	98	mg/dL	70-110
<u>Blood sugar pp</u>	90	mg/dL	70.0-140.0
<u>Bun (blood urea nitrogen)</u>	13.20	mg/dl	8.9-21.6
<u>Uric acid, serum</u>	4.6	mg/dl	3.5-7.2
<u>Creatinine, serum</u>	0.7	mg/dl	0.60-1.2

LFT(LIVER FUNCTION TEST)

Bilirubin Total	0.68	mg/dl	0.1-1.2
Bilirubin Conjugated	0.24	mg/dl	0-0.4
Bilirubin Unconjugated	0.44	mg/dl	up to 0.7
SGOT (AST)	37	U/L	0-46
SGPT (ALT)	32	U/L	0-49
Alkaline phosphatase	95	U/L	40-129
Gamma glutamyl transpeptidase	27	U/L	10-45
Total Protein	6.9	gm/dl	6.60 - 8.70
Albumin serum	3.8	g/dL	3.0-5.2
Globulin	3.10	gm/dl	1.8-3.4
Albumin/Globulin Ratio	1.23		1.10 - 2.50

LIPID PROFILE

Cholesterol	161	mg/dl	50-200
Triglycerides	73	mg/dL	25-150
HDL Cholesterol	47	mg/dL	40 - 60

Checked By.

DR. NITIN AGARWAL
MBBS, MD
MBBS, MD(PATHOLOGIST)
Regn. No. DMC-R-1436

47, Harsh Vihar, Pitampura, New Delhi-110034 | Ph.: 011-42480101, 9599913051

E-mail: oneplusul@gmail.com | Web.: www.oneplusul.in

Page 2 of 5

Clinical correlation is essential for final diagnosis. • If test results are unsatisfactory please contact personally or on phone. • This report is for perusal of doctors only. • All disputes Subject to Delhi Jurisdiction only. • Not for medicolegal purposes. • All congenital anomalies in a foetus may not be diagnosed in routine obstetric ultrasound.



OnePLUS Ultrasound Lab

QUALITY FIRST ALWAYS!

Dr. Nitin Agarwal
Pathologist & Director
Ex. Sr. Res. MAMC
& Lok Nayak Hospital
Ex. Chief of Lab Dr. Lal Path Labs.

Dr. Pooja (Garg) Agarwal
Radiologist & Director
MAMC & Lok Nayak Hospital



NAME	:Mr. SHUBHAM SINGHAL	Barcode No	:10142002
AGE/GENDER	:31 YRS/Male	SPECIMEN DATE	:08/Apr/2023 09:28AM
PATIENT ID	:112206	SPECIMEN RECEIVED	:08/Apr/2023 09:34AM
REFERRED BY	:Dr. MEDIWHEEL	REPORT DATE	:08/Apr/2023 02:09PM
CENTRE NAME	:ONEPLUS ULTRASOUND LAB	LAB NO.	:012304080015

Test Name	Result	Unit	Ref. Range
LDL cholesterol	99	mg/dL	<130
VLDL cholesterol	14.6	mg/dL	5-40
Cholesterol/HDL Ratio	3.4		Low Risk 3.3-4.97 Average Risk 4.4-7.1 Moderate Risk 7.1-11.0 High Risk >11.0
LDL/HDL Ratio	2.1		0 - 3.55

According to ATP III and NCEP guidelines

Parameter	Normal	Desirable	Borderline	High
Total cholesterol	<200		200-239	240
Triglycerides	<150	150-199	200-499	500
LDL	Optimal <100 Near Optimal 100-129	130-159	160-180	190
HDL	<40 : LOW 60 : HIGH			

BUN/Creatinine ratio

Bun (blood urea nitrogen)	13.20	mg/dl	8.9-21.6
CREATININE	0.70	mg/dl	0.30-1.10
BUN/Creatinine ratio	18.86		10.0 - 20.0

ENDOCRINOLOGY

THYROID PROFILE(T3,T4,TSH)

Triiodothyronine total [t3]	0.72	ng/dl	0.52-1.9
Thyroxine total [t4]	4.50	µg/dl	4.4 - 10.8
TSH (Thyroid Stimulating Hormone)	12.80	µIU/ml	0.25-5.0

AGE WISE VARIATION IN TSH

AGE	TSH(µIU/ml)	AGE	TSH(µIU/ml)
-----	-------------	-----	-------------

Checked By.

DR. NITIN AGARWAL
MBBS, MD(PATHOLOGIST)
Reg. No. DMC-R-1436

47, Harsh Vihar, Pitampura, New Delhi-110034 | Ph.: 011-42480101, 9599913051
E-mail: oneplusul@gmail.com | Web.: www.oneplusul.in

Page 3 of 5

Clinical correlation is essential for final diagnosis. * If test results are unsatisfactory please contact personally or on phone. * This report is for perusal of doctors only.
* All disputes Subject to Delhi Jurisdiction only. * Not for medicolegal purposes. * All congenital anomalies in a foetus may not be diagnosed in routine obstetric ultrasound.



OnePLUS

Ultrasound Lab

QUALITY FIRST... ALWAYS!

Dr. Nitin Agarwal
Pathologist & Director
Ex. Sr. Res. MAMC
& Lok Nayak Hospital
Ex. Chief of Lab Dr. Lal Path Labs.

Dr. Pooja (Garg) Agarwal
Radiologist & Director
MAMC & Lok Nayak Hospital



NAME	:Mr. SHUBHAM SINGHAL	Barcode No	:10142002
AGE/GENDER	:31 YRS/Male	SPECIMEN DATE	:08/Apr/2023 09:28AM
PATIENT ID	:112206	SPECIMEN RECEIVED	:08/Apr/2023 09:34AM
REFERRED BY	:Dr. MEDIWHEEL	REPORT DATE	:08/Apr/2023 02:09PM
CENTRE NAME	:ONEPLUS ULTRASOUND LAB	LAB NO.	:012304080015

Test Name	Result	Unit	Ref. Range
1-4 weeks	1.00 - 19.0	16-20 yrs	0.25 - 5.0
1-12 mths	1.70 - 9.1	21 - 80 yrs	0.25 - 5.0
1-5 yrs	0.80 - 8.2	I st trimester	0.25 - 5.0
6-10 yrs	0.25 - 5.0	II nd trimester	0.50 - 5.0
11-15 yrs	0.25 - 5.0	III rd trimester	0.4 - 6.0

Reference ranges - Interpretation of Diagnostic tests - (Jacques Wallach)

1. Primary hypothyroidism is accompanied by depressed serum T3 and T4 values and elevated serum TSH level.
2. Primary hyperthyroidism is accompanied by elevated serum T3 and T4 levels along with depressed TSH values.
3. Slightly elevated T3 levels may be found in pregnancy and estrogen therapy, while depressed levels may be encountered in severe illness, renal failure and during therapy with drugs like propranolol and propyl thiouracil.
4. Although elevated TSH levels are nearly always indicative of primary hypothyroidism, and may be seen in secondary thyrotoxicosis

CLINICAL PATHOLOGY

URINE ROUTINE

Physical examination

Quantity	30	ML
Colour	PALE YELLOW	
Transparency	CLEAR	CLEAR
Sp. gravity	1.015	1.010-1.030
pH	5.50	
Reaction	ACIDIC	ACIDIC

Chemical examination

Urine protein	NIL	NIL
Urine sugar	NIL	NIL
Bilirubin, urine	NEGATIVE	NEGATIVE
Urobilinogen	NORMAL	NORMAL
Ketones	NEGATIVE	NEGATIVE

Microscopic examination

Pus cells.	0-1	/HPF	0-2
------------	-----	------	-----

Checked By.

DR. NITIN AGARWAL
MBBS, MD (PATHOLOGIST)

DR. NITIN AGARWAL
MBBS, MD
Regn. No. DMC-R-1436

47, Harsh Vihar, Pitampura, New Delhi-110034 | Ph.: 011-42480101, 9599913051

E-mail: oneplusul@gmail.com | Web.: www.oneplusul.in

Page 4 of 5



OnePLUS Ultrasound Lab

QUALITY FIRST... ALWAYS!

Dr. Nitin Agarwal

Pathologist & Director
Ex. Sr. Res. MAMC
& Lok Nayak Hospital
Ex. Chief of Lab Dr. Lal Path Labs.

Dr. Pooja (Garg) Agarwal

Radiologist & Director
MAMC & Lok Nayak Hospital



NAME	:Mr. SHUBHAM SINGHAL	Barcode No	:10142002
AGE/GENDER	:31 YRS/Male	SPECIMEN DATE	:08/Apr/2023 09:28AM
PATIENT ID	:112206	SPECIMEN RECEIVED	:08/Apr/2023 09:34AM
REFERRED BY	:Dr. MEDIWHEEL	REPORT DATE	:08/Apr/2023 02:09PM
CENTRE NAME	:ONEPLUS ULTRASOUND LAB	LAB NO.	:012304080015

Test Name	Result	Unit	Ref. Range
Epithelial cells	0-1	/HPF	NIL
R.B.C.	NIL	/HPF	NIL
Casts	NIL	/HPF	NIL
Crystals	NIL	/HPF	NIL
Bacteria	NIL	/HPF	NIL
Others.	NIL	NIL	NIL

*** End Of Report ***

Checked By.

DR. NITIN AGARWAL
MBBS,MD(PATHOLOGIST)

NITIN AGARWAL
MBBS, MD
Regn. No. DMC-R-1436

47, Harsh Vihar, Pitampura, New Delhi-110034 | Ph.: 011-42480101, 9599913051

E-mail: oneplusul@gmail.com | Web.: www.oneplusul.in

Page 5 of 5

Clinical correlation is essential for final diagnosis. • If test results are unsatisfactory please contact personally or on phone. • This report is for perusal of doctors only.
• All disputes Subject to Delhi Jurisdiction only. • Not for medicolegal purposes. • All congenital anomalies in a foetus may not be diagnosed in routine obstetric ultrasound.



OnePLUS
Ultrasound Lab

— QUALITY FIRST... ALWAYS! —

Dr. Nitin Agarwal

Pathologist & Director
Ex. Sr. Res. MAMC
& Lok Nayak Hospital
Ex. Chief of Lab Dr. Lal Path Labs.

Dr. Pooja (Garg) Agarwal

Radiologist & Director
MAMC & Lok Nayak Hospital

Name	: Mr. SHUBHAM SINGHAL	Age/Sex	: 31 YRS/Male
Ref. By	: Dr. MEDIWHEEL	Lab No	: 012304080015
Date	: 08-Apr-2023	Patient ID	: LSHHI112206

ULTRASOUND EXAMINATION----WHOLE ABDOMEN

Liver is enlarged in size (16.2 cm) and normal in outline with altered echopattern. Diffuse increase in echogenicity of liver parenchyma is noted, suggestive of fatty infiltration (grade I). Intrahepatic biliary radicles are not dilated. No abscess or mass lesion seen. Hepatic veins, portal vein, IVC and aorta are normal. CBD is normal in caliber.

Gall bladder is well distended with anechoic lumen. Wall thickness is normal.

Both kidneys are normal in size, shape, position, outline and echopattern. Corticomedullary differentiation is maintained. No pelvicalyceal dilation or mass lesion is seen.

Spleen is normal in size and echotexture. No mass lesion seen.

Pancreas is normal in size, outline and echotexture.

Urinary bladder is normal in shape and position. No evidence of intravesical stone or mass seen.

Prostate is normal in size, shape and echopattern.

No abnormal bowel wall thickening seen in right iliac fossa.
No free fluid seen anywhere in abdomen.

IMPRESSION:

- Fatty infiltration of liver (grade I) with mild hepatomegaly.

DR. POOJA GARG
RADIOLOGIST
M.B.B.S., D.M.R.D.
Reg No. DMC/R/03398
Radiologist

Type By : pooja

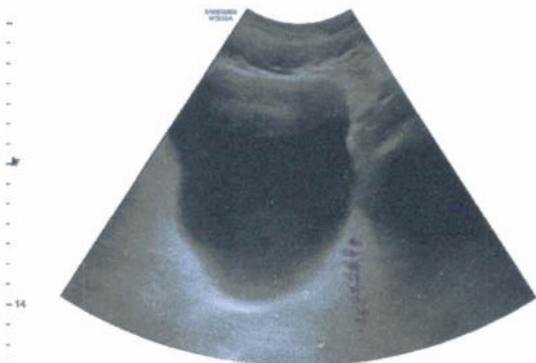47, Harsh Vihar, Pitampura, New Delhi-110034 | Ph.: 011-42480101, 9599913051
E-mail: oneplusul@gmail.com | Web.: www.oneplusul.in

Clinical correlation is essential for final diagnosis. • If test results are unsatisfactory please contact personally or on phone. • This report is for perusal of doctors only.
• All disputes Subject to Delhi Jurisdiction only. • Not for medicolegal purposes. • All congenital anomalies in a foetus may not be diagnosed in routine obstetric ultrasound.

MR SHUBHAM 31/M
OnePlus Ultrasound Lab
CA1-7A / Abdomen / FR 24Hz
MI 1.4 08-04-2023
Tls 0.1 10:21:41 AM

G60 DR135 FAB P90 Frq Gen. 17.0cm

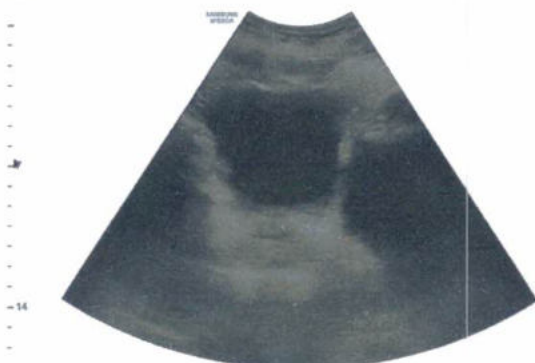MR 310



MR SHUBHAM 31/M
OnePlus Ultrasound Lab
CA1-7A / Abdomen / FR 24Hz
MI 1.4 08-04-2023
Tls 0.1 10:21:44 AM

G60 DR135 FAB P90 Frq Gen. 17.0cm

MR 310

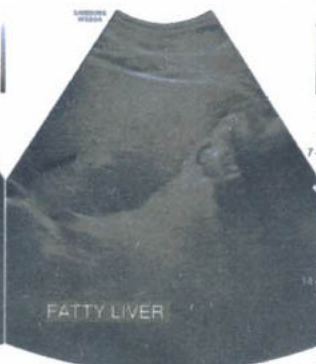
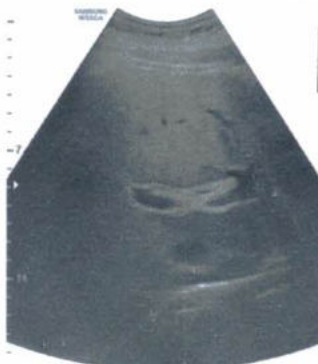

MR SHUBHAM 31/M
OnePlus Ultrasound Lab
CA1-7A / Abdomen / FR 22Hz
MI 1.4 08-04-2023
Tls 0.1 10:22:03 AM

G68 DR135 FAB P90 Frq Gen. 19.0cm

G68 DR135 FAB P90 Frq Gen. 19.0cm

MR 310

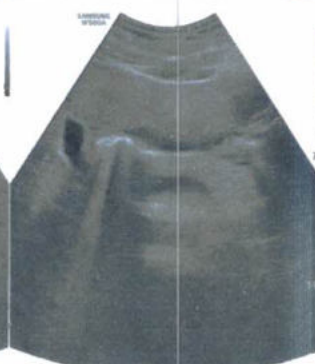

MR SHUBHAM 31/M
OnePlus Ultrasound Lab
CA1-7A / Abdomen / FR 22Hz
MI 1.4 08-04-2023
Tls 0.1 10:22:10 AM

G68 DR135 FAB P90 Frq Gen. 19.0cm

G68 DR135 FAB P90 Frq Gen. 19.0cm

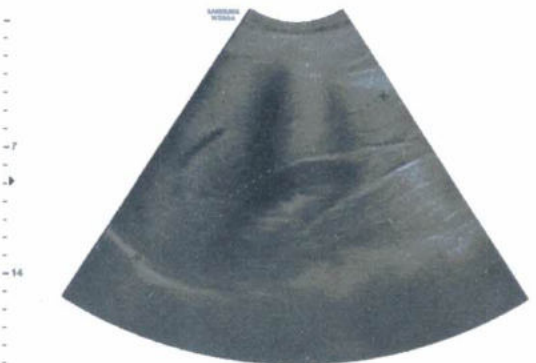MR 310



MR SHUBHAM 31/M
OnePlus Ultrasound Lab
CA1-7A / Abdomen / FR 22Hz
MI 1.4 08-04-2023
Tls 0.1 10:22:23 AM

G68 DR135 FAB P90 Frq Gen. 19.0cm

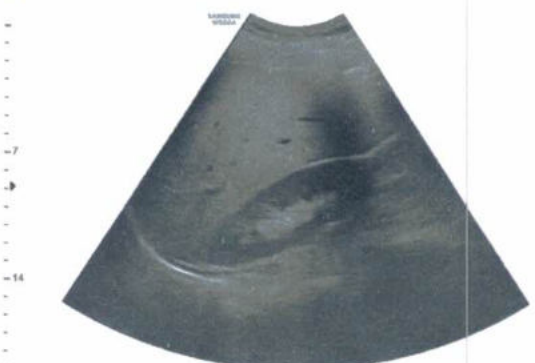MR 310



MR SHUBHAM 31/M
OnePlus Ultrasound Lab
CA1-7A / Abdomen / FR 22Hz
MI 1.4 08-04-2023
Tls 0.1 10:22:32 AM

G68 DR135 FAB P90 Frq Gen. 19.0cm

MR 310



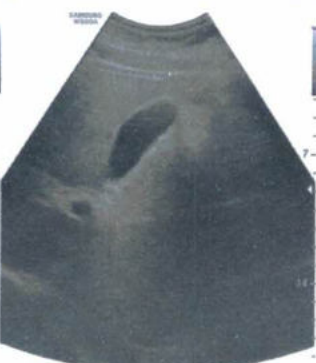Di 16.22 cm

MR SHUBHAM 31/M
OnePlus Ultrasound Lab
CA1-7A / Abdomen / FR 22Hz
MI 1.4 08-04-2023
Tls 0.1 10:22:48 AM

G68 DR135 FAB P90 Frq Gen. 19.0cm

G68 DR135 FAB P90 Frq Gen. 19.0cm

MR 310



MR SHUBHAM 31/M
OnePlus Ultrasound Lab
CA1-7A / Abdomen / FR 22Hz
MI 1.4 08-04-2023
Tls 0.1 10:23:05 AM

G68 DR135 FAB P90 Frq Gen. 19.0cm

G68 DR135 FAB P90 Frq Gen. 19.0cm

MR 310

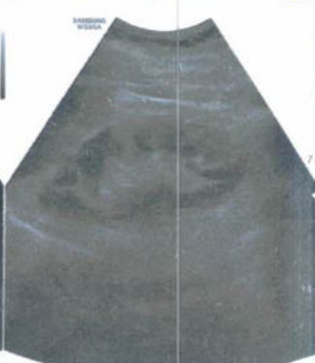
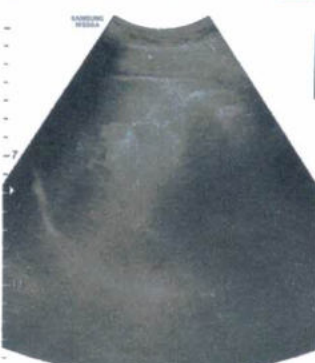


Figure 1
Left: [unreadable] Right: [unreadable]
[unreadable] [unreadable] [unreadable] [unreadable] [unreadable] [unreadable]

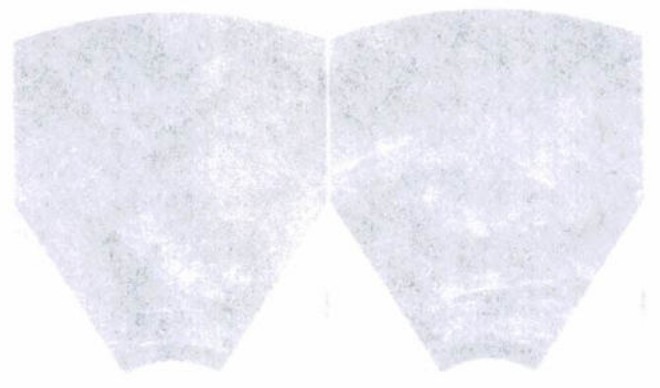


Figure 2
Left: [unreadable] Right: [unreadable]
[unreadable] [unreadable] [unreadable] [unreadable] [unreadable] [unreadable]



Figure 3
Left: [unreadable] Right: [unreadable]
[unreadable] [unreadable] [unreadable] [unreadable] [unreadable] [unreadable]



Figure 4
Left: [unreadable] Right: [unreadable]
[unreadable] [unreadable] [unreadable] [unreadable] [unreadable] [unreadable]

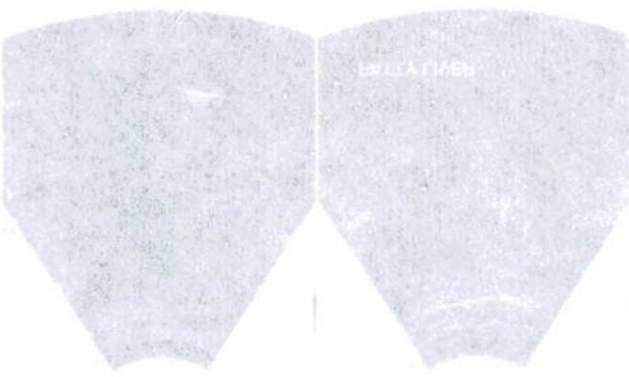

Figure 5
Left: [unreadable] Right: [unreadable]
[unreadable] [unreadable] [unreadable] [unreadable] [unreadable] [unreadable]

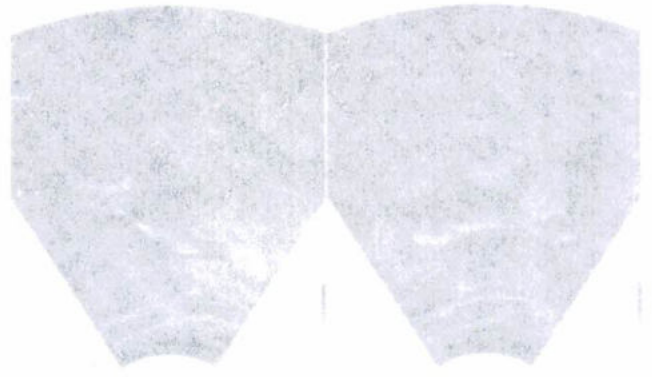

Figure 6
Left: [unreadable] Right: [unreadable]
[unreadable] [unreadable] [unreadable] [unreadable] [unreadable] [unreadable]



Figure 7
Left: [unreadable] Right: [unreadable]
[unreadable] [unreadable] [unreadable] [unreadable] [unreadable] [unreadable]




Figure 8
Left: [unreadable] Right: [unreadable]
[unreadable] [unreadable] [unreadable] [unreadable] [unreadable] [unreadable]



OnePLUS
Ultrasound Lab

— QUALITY FIRST... ALWAYS! —

Dr. Nitin Agarwal

Pathologist & Director
Ex. Sr. Res. MAMC
& Lok Nayak Hospital
Ex. Chief of Lab Dr. Lal Path Labs.

Dr. Pooja (Garg) Agarwal

Radiologist & Director
MAMC & Lok Nayak Hospital

Name	: Mr. SHUBHAM SINGHAL	Age/Sex	: 31 YRS/Male
Ref. By	: Dr. MEDIWHEEL	Lab No	: 012304080015
Date	: 08-Apr-2023	Patient ID	: LSHHI112206

X-ray-Chest PA view

Bony cage and soft tissues are normal.

Cardiothoracic ratio is normal.

Mediastinum is normal.

Both hila are normal.

Both costophrenic angles are clear.

Both domes of diaphragm are normal.

Lung fields are clear. No parenchymal lesion seen.

IMPRESSION: Normal Study.

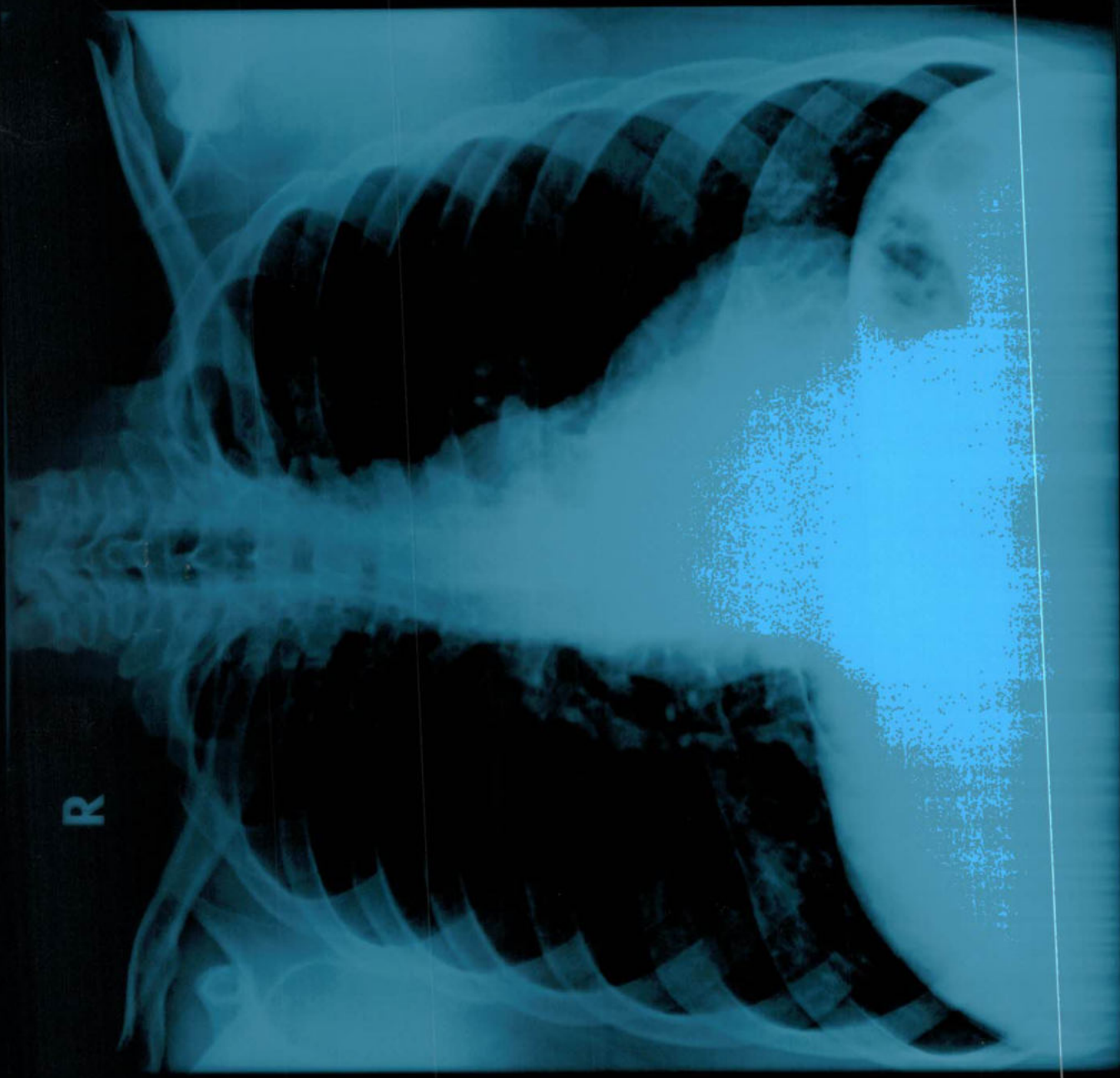
DR. POOJA GARG
RADIOLOGIST
REG NO. DMCR/03398
Reg No. DMCR/03398
Radiologist

Type By : darshita

47, Harsh Vihar, Pitampura, New Delhi-110034 | Ph.: 011-42480101, 9599913051

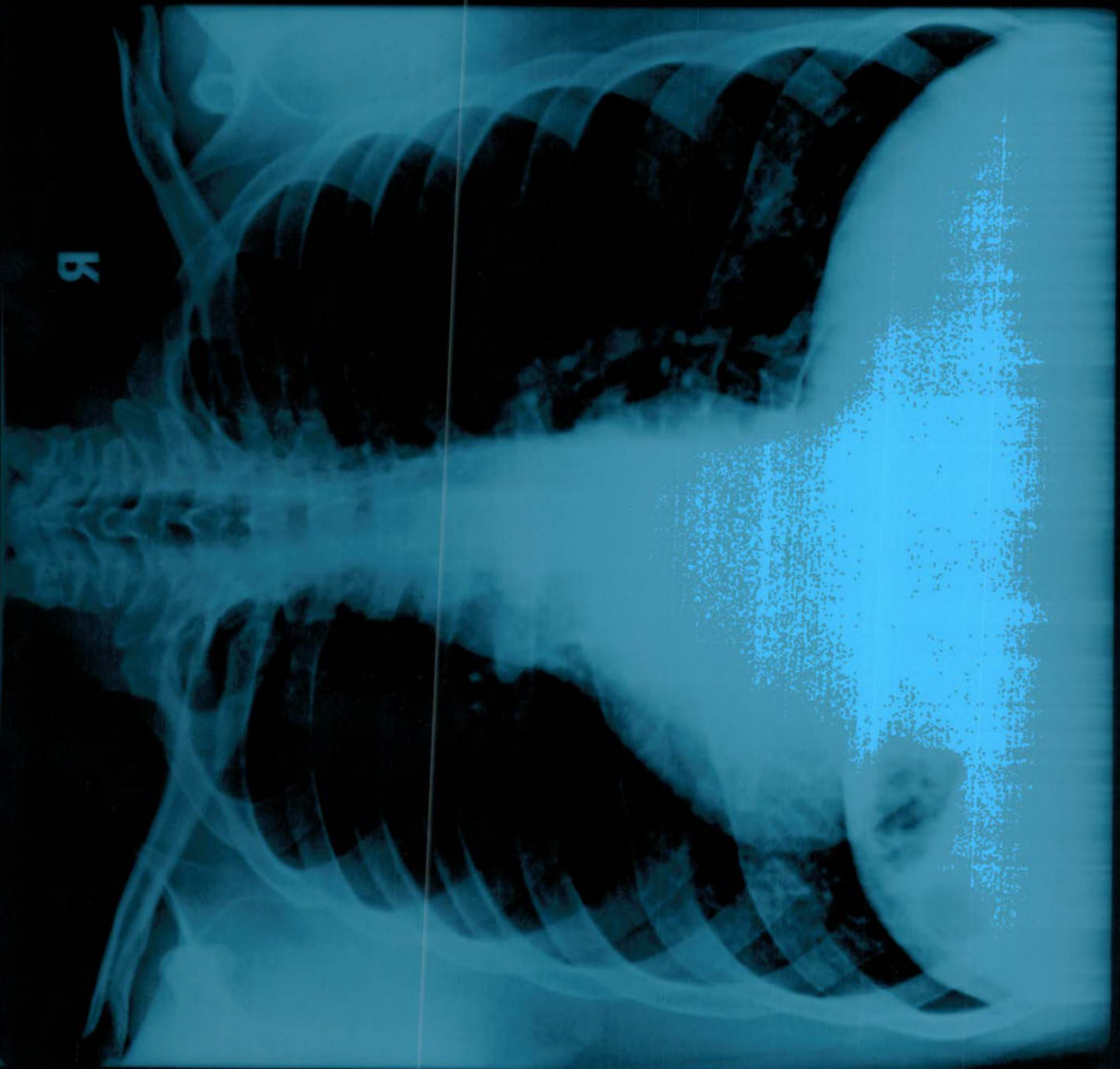
E-mail: oneplusul@gmail.com | Web.: www.oneplusul.in

R



SHUBHAM SINGHAL 31Y/M 8/4/2023 M CHEST PA VIEW 4/8/2023
ONEPLUS UI TRASOUND LAB 47 HARSH VIHAR PITAMPURA

ONEFLUGULTRASOUND LAB AT HARSH VIHAR PITAMPURA
SHUBHAM SINGHA 31/11/18 8/4/5053 M CHEST PA VIEW 4/8/5053



R