

Facilities:
 All clinical Biomedical & Hematology Investigations
 including Bone Marrow Examination
 VPT, Podiascan & Complete Foot Care (First Time in Purvanchal)
 All Hormonal Investigation by Chemiluminescent Method
 Visceral Fat by (AB-140) Ambulatory BP Monitoring
 CGMS & Insulin Pump Available
 PFT, 2D-ECHO (Color Doppler), Holter, TMT, Cardiac-3 available
 VIA, VILI, Colposcopy available
 Special Endocrinological Investigation Protocols.

ISO 9001:2008 Certified
 Mobile: 9389994334, 9554572190, 9453837595



Panacea Pathology

Clinical Reference Lab

Persistence, Preparedness and Precision
 EQAS (CMC Vellore Attached) & IQAS System
 पूर्वांचल की सर्वोत्तम गुणवत्ता वाली पैथोलॉजी

PATIENT NAME : SHIVA PANDEY

AGE/GENDER : 31YRS/FEMALE

REFD BY DR. : ARCO FEMI HEALTHCARE LTD.

RECEIVED DATE : 28-03-2023 (10:00 AM)

SAMPLE : BLOOD & URINE

REPORT DATE : 28-03-2023 (04:00 PM)

PATHOLOGY REPORT

COMPLETE BLOOD COUNT (CBC)

TEST	LAB TEST VALUES	NORMAL RANGE
HEMOGRAM		
HEMOGLOBIN (FLOW CYTOMETRY)	12.5	13 – 16 gm/dl
TOTAL LEUCOCYTE COUNT (TLC)	5,100	4000 – 11000
RBC COUNT	4.46	3.5 – 5.5
PCV (HCT)	39.9	37 – 47
MCV	89.5	80 – 95
MCH	28.0	28 – 34
MCHC	31.5	30 – 36
PLATELET COUNT	1,50,000	1,50,000 – 4,00,000
E.S.R. (WINTROBE FIRST HOURS)	16.0	20 mm/1 st hr
DIFFERENTIAL LEUCOCYTE		
NEUTROPHILS	55	40 – 75%
LYMPHOCYTES	38	20 – 45%
EOSINOPHILS	04	1 – 6%
MONOCYTES	03	2 – 8%
BASOPHILS	00	< 2%

FASTING BLOOD SUGAR

TEST	LAB TEST VALUES	NORMAL RANGE
FBS		
FASTING BLOOD SUGAR	76.0	70-125 mg/dl

GLYCOSYLATED HEMOGLOBIN (HBA1C)

TEST	LAB TEST VALUES	NORMAL RANGE
HBA1C	4.9	Normal : <5.97 % Good Control : 5.97 – 6.81% Fair Control : 6.81 – 7.65% Poor Control : >7.65%

PAGE 1

PANACEA HOSPITAL
 (A UNIT OF AAROH HEALTH CARE PVT. LTD)
 REG. NO. AL-1500
 B.36/44, B-4, KABIR NAGAR
 DURGAKUND, VARANASI
 M.D., Pathology

Lab Technician

Timing : 8.00 a.m. to 9.00 p.m. (Sunday 8.00 a.m. to 3.00 p.m.)

This Report is not valid for medico legal purpose

Note: These tests have technical limitations. Clinico-pathological interpretation is necessary. In case of any disparity test may be repeated immediately.

Address : 36/44 FK Kabir Nagar, Durgakund, Varanasi – 221005

Email: dramishra@gmail.com, drpallaviojha@gmail.com Website: panaceahospital.org

Facilities:

All clinical Biomedical & Hematology Investigations including Bone Marrow Examination
VPT, Podiascan & Complete Foot Care (First Time in Purvanchal)
All Hormonal Investigation by Chemiluminescent Method
Visceral Fat by (AB-140) Ambulatory BP Monitoring
CGMS & Insulin Pump Available
PFT, 2D-ECHO (Color Doppler), Holter, TMT, Cardiac-3 available
VIA, VILI, Colposcopy available
Special Endocrinological Investigation Protocols.

ISO 9001:2008 Certified
Mobile: 9389994334, 9554572190, 9453837595



Panacea Pathology

Clinical Reference Lab

Persistence, Preparedness and Precision
EQAS (CMC Vellore Attached) & IQAS System
पूर्वाचल की सर्वोत्तम गुणवत्ता वाली पैथोलॉजी

PATIENT NAME : SHIVA PANDEY	AGE/GENDER : 31YRS/FEMALE
REFD BY DR. : ARCO FEMI HEALTHCARE LTD.	RECEIVED DATE : 28-03-2023 (10:00 AM)
SAMPLE : BLOOD & URINE	REPORT DATE : 28-03-2023 (04:00 PM)

PATHOLOGY REPORT

LIPID PROFILE, SERUM

TEST	LAB TEST VALUES	NORMAL RANGE
BLOOD CHEMISTRY		
TOTAL CHOLESTEROL (SERUM)	148.0	Desirable:- < 200 mg/dl Borderline:- 200 – 239 mg/dl High:- > 240 mg/dl
TRIGLYCERIDES (SERUM)	136.0	35 – 170 mg/dl
HDL CHOLESTEROL (SERUM)	41.0	35.30 – 79.50 mg/dl
LDL CHOLESTEROL (SERUM)	79.8	< 130 mg/dl
VLDL	27.2	< 40 mg/dl
CHOLESTROL/HDL RATIO	3.60	< 3.0 Low Risk Ratio 3.0 – 5.0 Avg Risk > 5.0 High Risk
LDL/HDL RATIO	1.94	< 3 Ratio

BLOOD GROUP

TEST	LAB TEST VALUES
BLOOD GROUP ABO & RH FACTOR	
BLOOD GROUP	"B"
RH FACTOR	POSITIVE

LIVER PROFILE TEST, SERUM

TEST	LAB TEST VALUES	NORMAL RANGE
BIO CHEMISTRY		
TOTAL BILIRUBIN	0.72	0.0 – 1.1 mg/dl
DIRECT BILIRUBIN	0.26	0.0 – 0.2 mg/dl
INDIRECT BILIRUBIN	0.46	< 0.90 mg/dl
SGOT (AST)	25.0	0 – 52 mg/dl
SGPT (ALT)	22.0	0 – 39 mg/dl
GGT (GYT)	20.0	< 55 U/L

THYROID PROFILE (T3, T4, TSH)

TEST	LAB TEST VALUES	NORMAL RANGE
THYROID FUNCTION TEST		
T3	1.10	0.60 – 1.81 ng/ml
T4	7.56	4.50 – 10.90 ug/dl
TSH	2.74	0.39 – 6.10 uIU/mL

PAGE 2

Lab Technician

PANACEA HOSPITAL

(A UNIT OF AARCHO HEALTH CARE PVT. L.)

REG. NO. AI-1500

M.D. Pathology

B.36/44, B-4, KABIR NAGAR

DURGAKUND, VARANASI

Timing : 8.00 a.m. to 9.00 p.m. (Sunday 8.00 a.m. to 3.00 p.m.)

This Report is not valid for medico legal purpose

Note: These tests have technical limitations. Clinico-pathological interpretation is necessary. In case of any disparity test may be repeated immediately.

Address : 36/44 FK Kabir Nagar, Durgakund, Varanasi – 221005

Email: dramishra@gmail.com, drpallaviojha@gmail.com Website: panaceahospital.org

Facilities:

All clinical Biomedical & Hematology Investigations including Bone Marrow Examination
 VPT, Podiascan & Complete Foot Care (First Time in Purvanchal)
 All Hormonal Investigation by Chemiluminescent Method
 Visceral Fat by (AB-140) Ambulatory BP Monitoring
 CGMS & Insulin Pump Available
 PFT, 2D-ECHO (Color Doppler), Holter, TMT, Cardiac-3 available
 VIA, VILI, Colposcopy available
 Special Endocrinological Investigation Protocols.

ISO 9001:2008 Certified
 Mobile: 9389994334, 9554572190, 9453837595



Panacea Pathology

Clinical Reference Lab

Persistence, Preparedness and Precision
 EQAS (CMC Vellore Attached) & IQAS System
 पूर्वांचल की सर्वोत्तम गुणवत्ता वाली पैथोलॉजी

PATIENT NAME : SHIVA PANDEY	AGE/GENDER : 31YRS/FEMALE
REFD BY DR. : ARCO FEMI HEALTHCARE LTD.	RECEIVED DATE : 28-03-2023 (10:00 AM)
SAMPLE : BLOOD & URINE	REPORT DATE : 28-03-2023 (04:00 PM)

PATHOLOGY REPORT

RENAL & KIDNEY PROFILE, SERUM

TEST	LAB TEST VALUES	NORMAL RANGE
RENAL FUNCTION TESTS		
BLOOD UREA NITROGEN (BUN)	9.5	10 – 50 mg/dl
SERUM CREATININE	0.73	0.60 – 1.60 mg/dl
URIC ACID	4.10	3.60 – 7.70 mg/dl
ALKALINE PHOSPHATASE (ALP)	89.0	142 – 353 mg/dl
TOTAL PROTIENS	7.51	0 – 39 mg/dl
ALBUMIN	4.21	3.8 – 5.4 mg/dl
SERUM GLOBULIN	3.30	2.1 – 3.5 mg/dl
AG RATIO	1.34	-

URINE ROUTINE EXAMINATION

TEST	LAB TEST VALUES	NORMAL RANGE
PHYSICAL EXAMINATION		
QUANTITY	29	ML
COLOUR	STRAW	PALE YELLOW
APPEARANCE	CLEAR	CLEAR
SPECIFIC GRAVITY	1.015	1.01 – 1.03
PH	6.0	4.7 – 7.5
CHEMICAL EXAMINATION		
GLUCOSE	Not Detected	Not Detected
PROTEIN	NIL	Not Detected
MICROSCOPIC EXAMINATION		
PUS CELLS	02-03	0-5
RBC	Not Detected	Not Detected
EPITHELIAL CELLS	01-02	0-5
CASTS	Not Detected	Not Detected
CRYSTALS	Not Detected	Not Detected
BACTERIA	Not Detected	Not Detected

----- End of Report -----

Lab Technician

PANACEA HOSPITAL
 (A UNIT OF AAROH HEALTH CARE PVT. LTD.)
 REG. NO. AL-1500
 B.36/44, B-4 KABIR NAGAR
 DURGAKUND, VARANASI
 M.D. Pathology

Timing : 8.00 a.m. to 9.00 p.m. (Sunday 8.00 a.m. to 3.00 p.m.)

This Report is not valid for medico legal purpose

Note: These tests have technical limitations. Clinico-pathological interpretation is necessary. In case of any disparity test may be repeated immediately.

Address : 36/44 FK Kabir Nagar, Durgakund, Varanasi – 221005

Email: dramishra@gmail.com, drpallaviojha@gmail.com Website: panaceahospital.org



PANACEA HOSPITAL

B 36/44 F.K KABIR NAGAR, DURGAKUND
TOLLFREE NO-18001233070.
Whatsapp No - 8795832852
www.piire.org



Btve.

OP Slip

Print Date : 28-Mar-2023 09:27AM



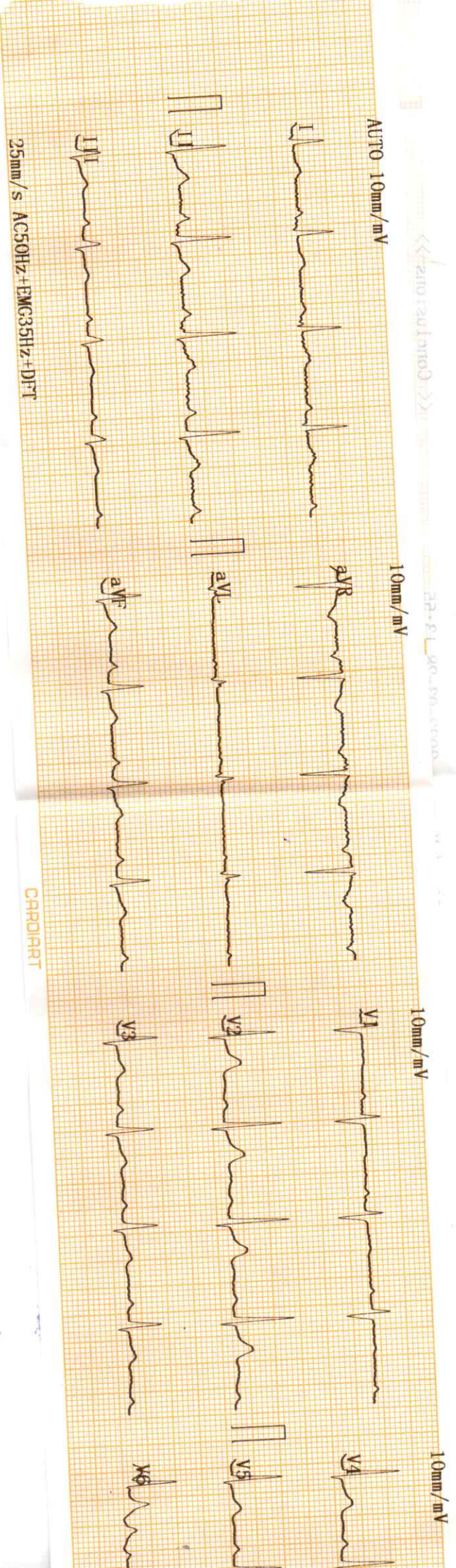
UHID No :- UD-22230004193	OP No :- OP-22230015339	OP Date :- 28 Mar 2023 9:27AM
Patient Name :- Mrs SHIVA PANDEY BOB	Age/Sex :- 31 Y/Female	Mobile No :- 9984215485
Husband :-	Department :- OBST. & GYNAECOLOGY	
Pay Type :- Cash	Consultant :- Dr VANDANA SINGH (MBBS,MS)	
Token No :- NOR. - 2	Paid :- 0.00	
Patient Type :- Normal		
Address :- BOB, varanasi		

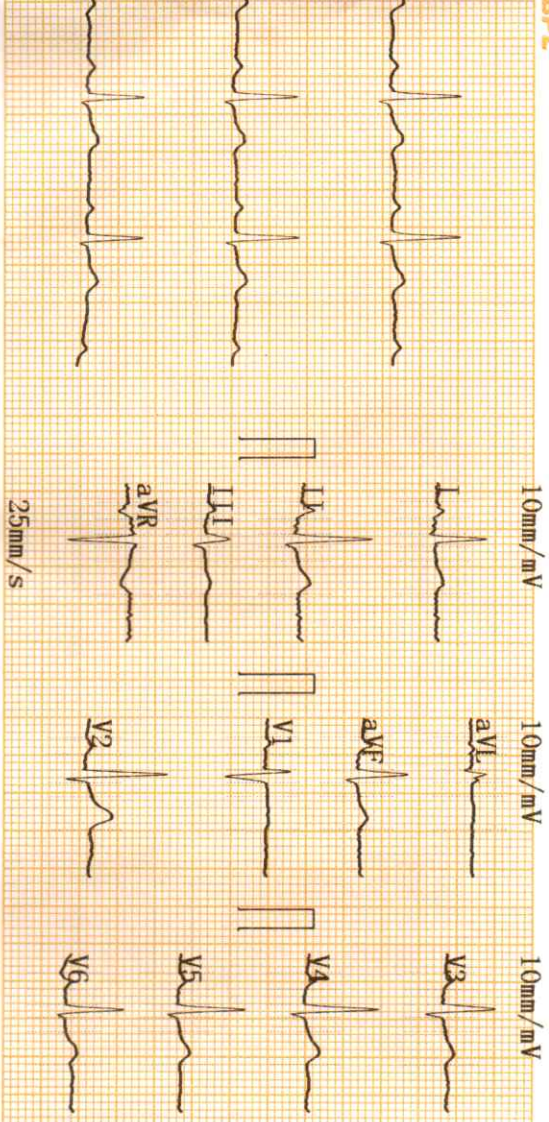
BP :- 100/70
 height :-
 Weight (kg) :- 57.5
 BMI :-
 RBS - 79
~~W -~~

Rx
 c/o - nil
 for routine check up.
 LMP - 8/3/2023.
 Regular.
 P2+0 L2 ← NVD 94y NVD
 LSCS 18m LSCS
 ⊕ oligo i FD
 i LCV
 P/A - soft.
 Ino Pap smear.
 ↓
 Refused by the patient

Vadane

Printed By : Mr NITIN YADAV
Created By : Mr NITIN YADAV





2022-03-28 13:55

ID	:	:
Name	:	:
Sex	:	:
Height	:	:
SYS	:	:
DIA	:	:
HR	:	83 bpm
PR Interval	:	174 ms
P Duration	:	91 ms
QRS Duration	:	71 ms
T Duration	:	174 ms
QT/QTc	:	321/376 ms
P/QRS/T Axis	:	54.7/45.0/40.5 deg
R(V5)/S(V1)	:	0.88/0.52 mV
R(V5)+S(V1)	:	1.40 mV

<< Conclusions >>

Normal Sinus Rhythm;
 Cardiac electric axis normal;
 Report need physician confirm

Physician

CARDIART
 TAD+SH2C9M3-SH020A 2 Vmm2G



PANACEA HOSPITAL

A shelter for many hearts A Home for many lives

(An ISO 9001:2008 Certified Organisation)

Lab Attached with CMC Vellore Under EQAS Scheme

PATIENT'S NAME : MRS: SHIVA PANDEY

AGE/SEX: 30 Y/F

REF. BY : Dr. ASHUTOSH MISHRA(MD)

Tuesday, March 28, 2023

Echo - Cardiography

MITRAL VALVE Doppler	AML - normal morphology MV Flow - E - 1.7 A-0.4 E/A=1.81	PML - normal morphology MVA - 3.0 cm ² Mitral Regurgitation - No
TRICUSPID VALVE Doppler	Normal TV Flow -No	Tricuspid Regurgitation -No
PULMONARY VALVE Doppler	Normal PV Flow -No	Pulmonary Regurgitation - No
AORTIC VALVE Doppler	Trileaflet-No AV Flow - no	Aortic Regurgitation - no
MEASUREMENT	Aorta - 24.0 (20-38) mm IVS ed - 12.6 (6 -12) mm LVID ed -25.1 (35 - 55) mm LVPW ed - 16.0 (6 -12) mm OA - 7 (> 5) mm	LA - 26.3 (24-32) mm IVS es -14.3 (6 - 12) mm LVID es - 13.1 (24 - 40) mm LVPW es - 12.6 (6 -12) mm EPSS - 4 (< 9) mm

CONCLUSION

All cardiac chamber dimensions are WNL
No valvular abnormalities
Good LV systolic function present Modified Simpson's method (4C, 2C) (LVEF=81%)
No diastolic dysfunction present (E/A = 1.81) by tissue Doppler (E/e'=6.2)
No RWMA
No pericardial effusion
Intact IAS / IV
No PAH
No intra cardiac mass /thrombus /vegetation

IMPRESSION

Normal Echocardiogram

Nisha Mishra
Physician Assistant
(MIRE)

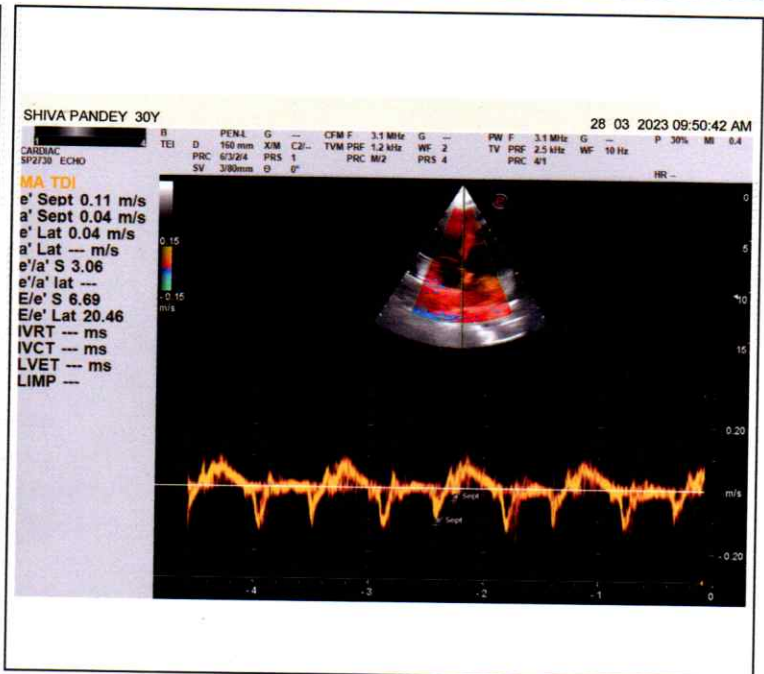
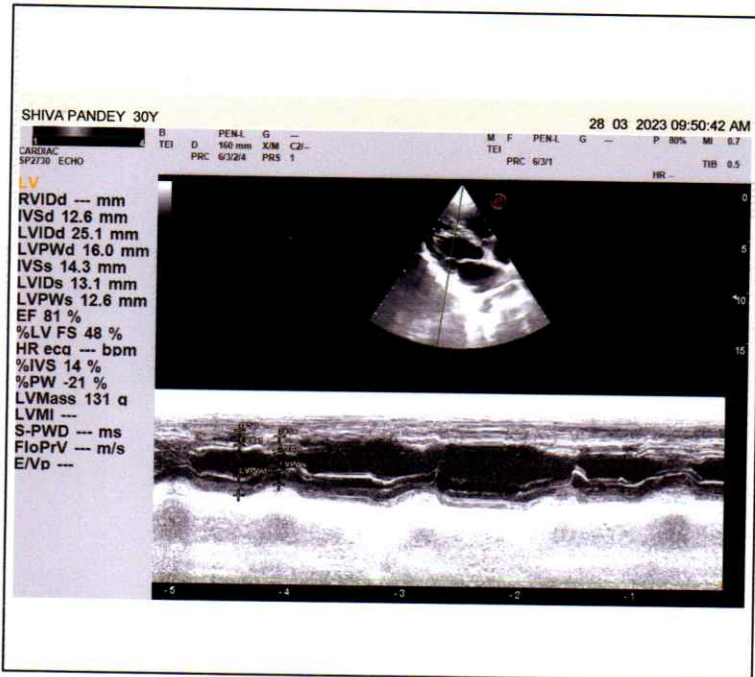
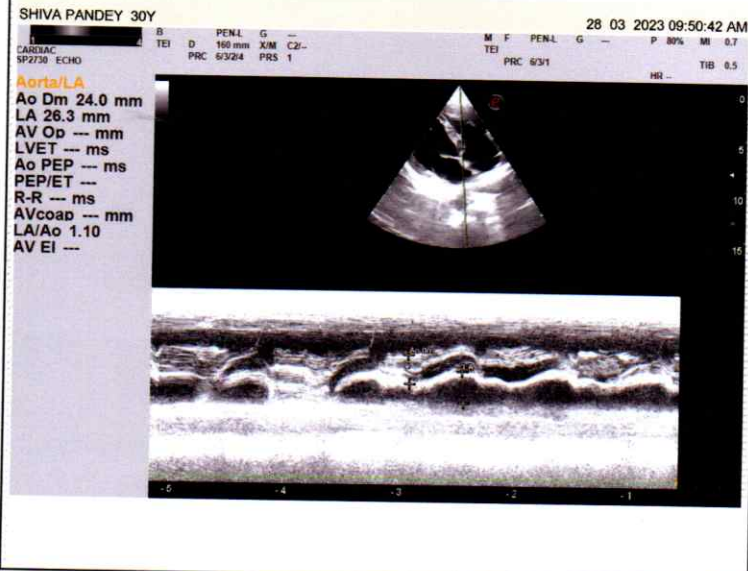
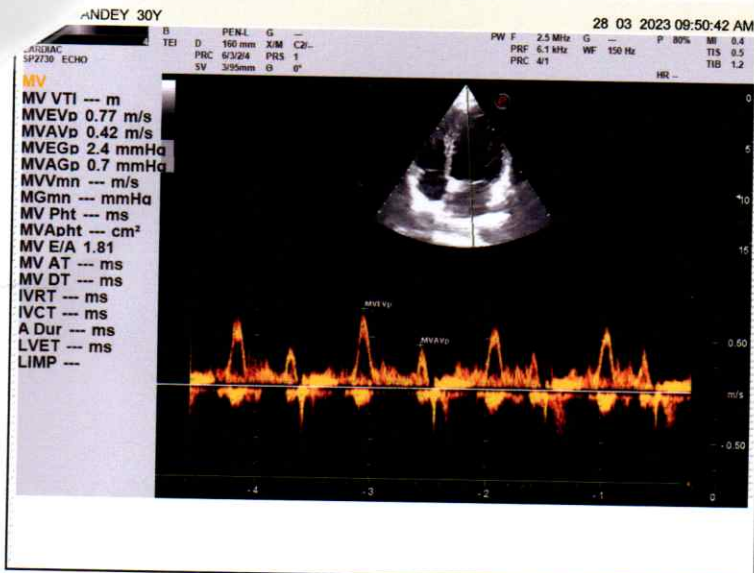
DR. PALLAVI MISHRA
MBBS, MD (GENERAL MEDICINE)
MCI Reg. No. 52033

Dr. Pallavi Mishra
MBBS, MD (MED) Lucknow
Echocardiography Specialist, MIAE
Non-invasive cardiologist
Women Cardiologist
Diabetocardiologist

Address : Kabir Nagar (Near Sanjay Shiksha Niketan), Durgakund, Varanasi

Mobile : 9554572190 / 9453837595 / Recpn. 9389994334

E-mail : dramishra@gmail.com, drpallaviojha@gmail.com, Website: www.piore.org





GPS Map Camera

Varanasi, Uttar Pradesh, India

B36/44BA-4, Durgakund, Bhelupur, Varanasi, Uttar Pradesh 221001, India

Lat 25.288944°

Long 82.993388°

28/03/23 09:36 AM GMT +05:30



Panacea Hospital

Diabetes Care Organisation


Home For Many Hearts
Home For Many Lives



ओ. पी. डी. पंजीकरण
O.P.D. REGISTRATION

HELP YOU

IPD B

 GPS Map Camera

Varanasi, Uttar Pradesh, India

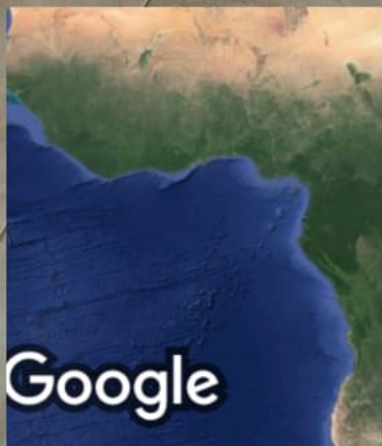B36/44B-3, Padampuri Colony, Durgakund,

Nagwa, Varanasi, Uttar Pradesh 221005, India

Lat 25.289204°

Long 82.993514°

28/03/23 09:14 AM GMT +05:30



Google



Call Now - 1800-123-3070

PANACEA HOSPITAL

A shelter for many hearts A Home for many lives


(An ISO 9001:2008 Certified Organisation)

Lab Attached with CMC Vellore Under EQAS Scheme

PATIENT'S NAME : SHIVA PANDEY AGE/SEX: 30Y/F
REF. BY : Dr. ASHUTOSH MISHRA (MBBS, M.D) Tuesday, March 28, 2023

U/S. WHOLE ABDOMEN

- LIVER** : Liver is normal in size, shape & echotexture. Intra hepatic biliary radicals are normal. Portal venous channels are normal.
- G. B.** : Gall bladder is normal in size, lumen is clear. Wall thickness normal.
- C.B.D.** : C.B.D. is normal in caliber.
- PANCREAS** : Pancreas is normal in size, shape and echotexture. No evidence of any inflammatory disease or mass.
- SPLEEN** : Spleen is normal in size, shape and echotexture.
- Rt. KIDNEY** : Normal in size, shape and echotexture. Renal sinus is normal
Cortico medullary differentiation is normal. P. C. system is normal.
- Lt. KIDNEY** : Normal in size, shape and echotexture. Renal sinus is normal
Cortico medullary differentiation is normal. P. C. system is normal.
- URI. BLADDER** : Urinary bladder is normal in size, position. Wall thickness normal.
No evidence of calculus or mass.
- UTERUS** : Normal in size. shape & echotexture. Endometrial echo is normal.
- OVARIES** : Rt. Ovary:- Normal in size.
Lt. Ovary:-Normal in size.
No free fluid seen in P. O. D.
- IMPRESSION** : **NO OBVIOUS SONOLOGICAL ABNORMALITY SEEN.**

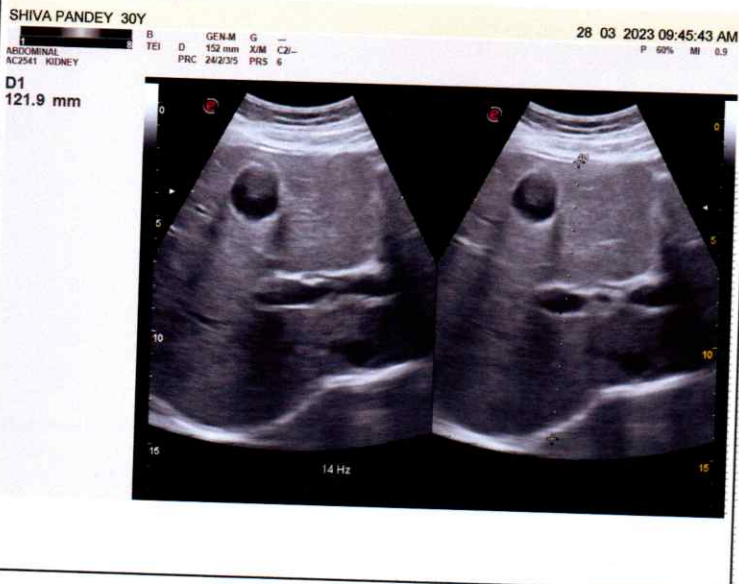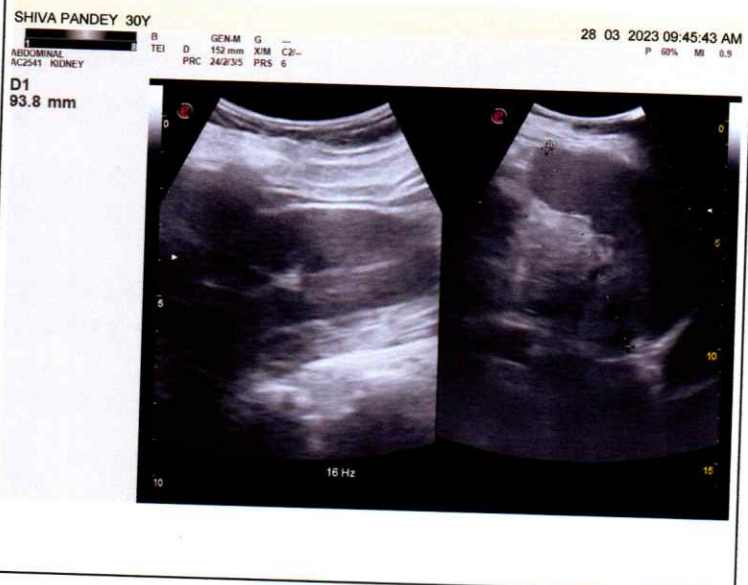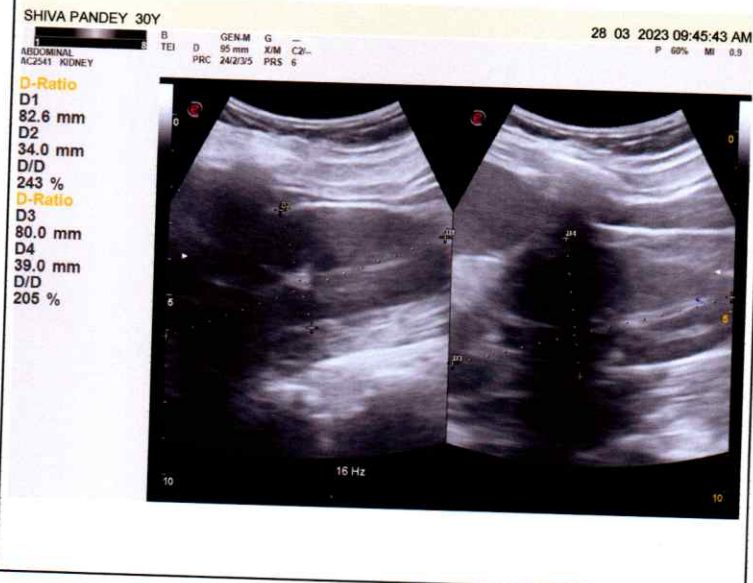
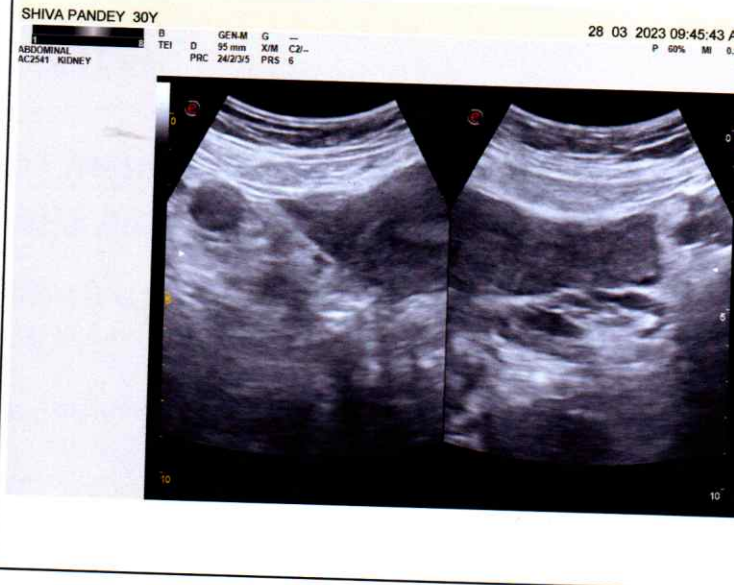

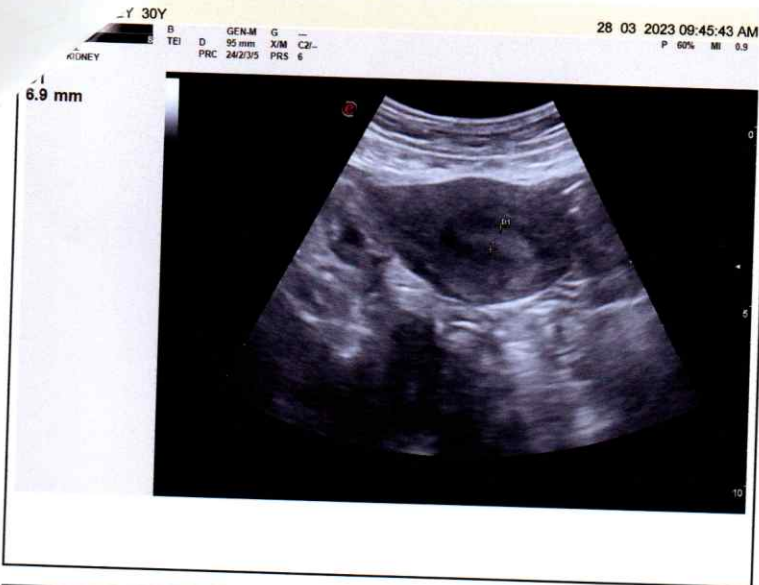DR. R. TIWARI
(M.B.B.S, M.D.(KGMU, LKO)
(RADIODIAGNOSIS).

Thanks for reference.

Address : Kabir Nagar (Near Sanjay Shiksha Niketan), Durgakund, Varanasi

Mobile : 9554572190 / 9453837595 / Recpn. 9389994334

E-mail : dramishra@gmail.com, drpallaviojha@gmail.com, Website: www.piire.org





Call Now - 1800-123-3070

PANACEA HOSPITAL

A shelter for many hearts A Home for many lives

(An ISO 9001:2008 Certified Organisation)

Lab Attached with CMC Vellore Under EQAS Scheme

NAME: MR.SHIVA PANDEY

AGE/SEX: 30 YRS / MALE

REF BY: DR. ASHUTOSH MISHRA (MD)

DATE: 29/03/2023

X-RAY CHEST PA

BOTH LUNG FIELDS AND PLEURAE:

Coarse bronchovascular markings with hyperinflation of lungs suggestive of - COPD.

Right & left hila are normal

There is no evidence of any fluid in the both the pleural cavities.

Both domes of diaphragms are normal in position.

MEDIASTINUM:

Trachea is central in position.

Cardiac silhouette is of normal size and configuration.

No evidence of pericardial effusion.

No significant lymphadenopathy is seen.

Visualized skeleton is normal.


DR. R. K. TIWARI

Consultant radiologist

MBBS MD (GOLD MEDALIST)

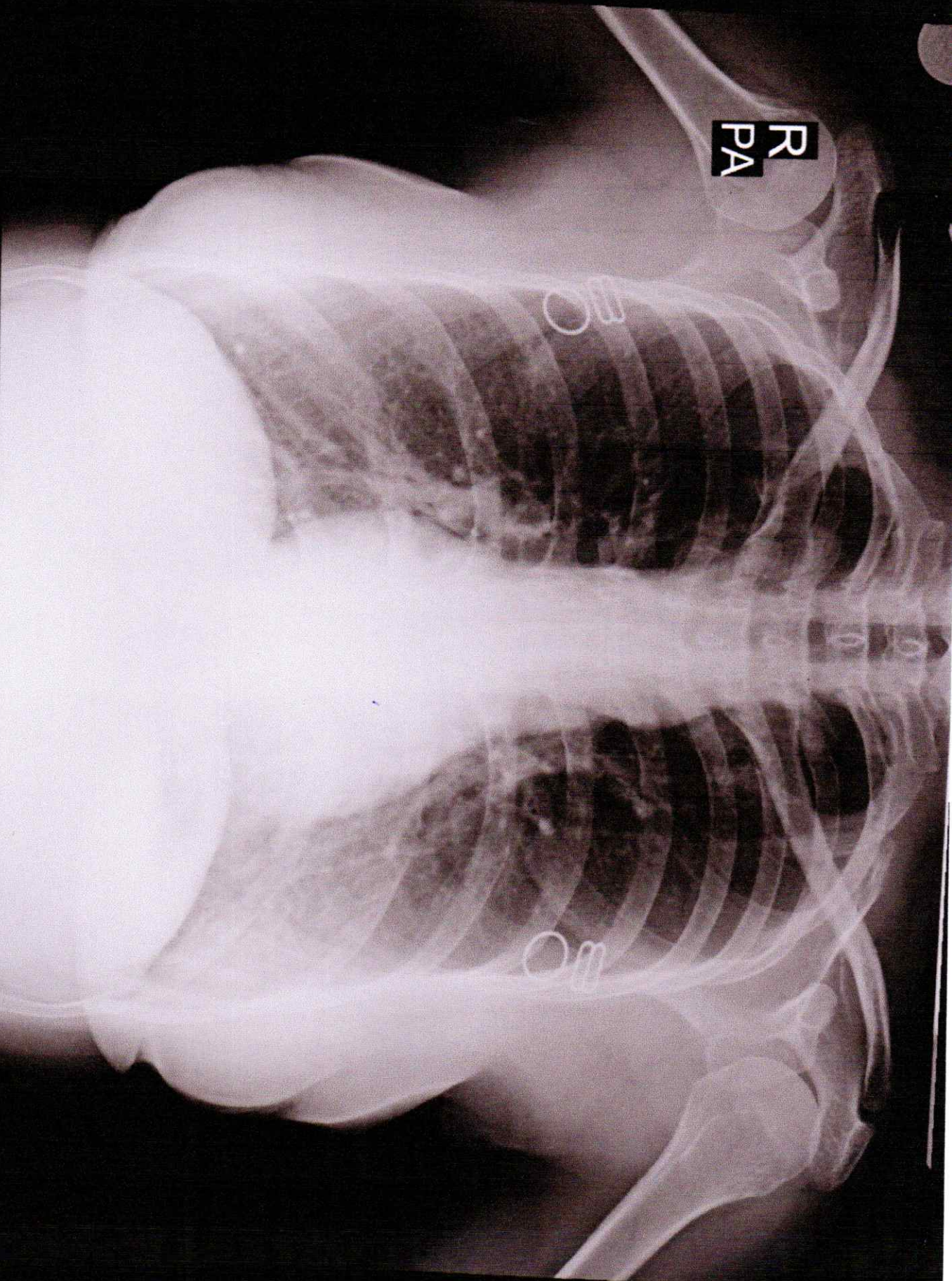
King George Medical University, Lucknow

Thanks for reference.

Address : Kabir Nagar (Near Sanjay Shiksha Niketan), Durgakund, Varanasi

Mobile : 9554572190 / 9453837595 / Recpn. 9389994334

E-mail : dramishra@gmail.com, drpallaviojha@gmail.com, Website: www.piire.org



SHIVA PANDEY 30Y/F 4193 O CHEST P.A. 28-Mar-23 01:35 PM

PANACEA HOSPITAL, KABIR NAGAR, DURGAKUND, VARANASI