



**SENTINI HOSPITALS**  
CENT PERCENT CARE



NABH ACCREDITED HOSPITAL

Gr. Medicine

V. Siva Ram Babu  
Age: 31/M

Date: 24/12/22  
Dr. K. Harish  
Dr. P. Lalitha

Dr. Harish

Patient come fr M.H.C

Kklo DM or Ly

No specific complaints

cus /  
ly /  
ly /

HS



## Department Of Laboratory





Date :

<b>Name</b> : Mr. VUYVALA SIVARAM BABU	<b>Age / Sex</b> : 31 Y(s)/Male
<b>Bill Date</b> : 24-Dec-2022 09:44 AM	<b>UMR No.</b> : UMR2218131
<b>Rept. Dt</b> : 24-Dec-2022 11:30 AM	<b>Bill No.</b> : BIL22027321
<b>Ref By</b> : Dr.GENERAL HEALTH CHECK UP	<b>Result No</b> : 0 / RES22028390

2022/12/24 16:35

Parameter	Result	Normal Values
<b>LFT(LIVER FUNCTION TEST)</b>		
Total Bilirubin	: 0.6 mg/dl	0.1 - 1.2 mg/dl
Direct Bilirubin	: 0.2 mg/dl	0.0 - 0.3 mg/dl
Indirect Bilirubin	: 0.4 mg/dl	
SGOT	: 20 IU/L	5 - 55 IU/L
SGPT	: 17 IU/L	5 - 55 IU/L
Alkaline Phosphatase	: 84 IU/L	Adult : 35 - 125 IU/L Children : 125 - 330 IU/L
Total Protein	: 6.7 gm/dl	6.0 - 8.3 gm/dl
Albumin	: 3.7 gm/dl	3.2 - 5.0 gm/dl
Globulin	: 3.0 gm/dl	2.5 - 3.0 gm/dl
A / G RATIO	:* 1.2	1.51 - 1.81
<b>CBC (COMPLETE BLOOD COUNT)</b>		
HAEMOGLOBIN	: 16.2 g/dl	12.0 - 17.0 g/dl
Total WBC Count	: 4,500 cells/cumm	4000 - 11000 cells/cumm
<b>DC COUNT</b>		
Neutrophils	: 55 %	50 - 70 %
Lymphocytes	: 40 %	15 - 40 %
Eosinophils	: 03 %	0 - 7 %
Monocytes	: 02 %	0 - 4 %
Basophils	: 00 %	0 - 1 %
RBC COUNT	: 5.4 millions/cumm	4.5 - 6.5 millions/cumm
PLATELET COUNT	: 2.47 lakhscells/cumm	1.5 - 4.0 lakhscells/cumm

\*\*\* End Of Report \*\*\*

 **Lab Tech.**     
  **Bio-Chemist**     
  **Lab In-Charge**     
  **Incharge Pathologist**

Correlate Clinically, We use only sterilised disposable syringes & needles.  
 Discrepancies due to technical or typing errors should be reported within 3 days for correction.  
 This report is to help you for better management of patient and not valid for medicolegal purpose.



## Department Of Laboratory

Date :


<b>Name</b> : Mr. VUYYALA SIVARAM BABU	<b>Age /Sex</b> : 31 Y(s)/Male
<b>Bill Date</b> : 24-Dec-2022 09:44 AM	<b>UMR No.</b> : UMR2218131
<b>Rept. Dt</b> : 24-Dec-2022 11:30 AM	<b>Bill No.</b> : BIL22027321
<b>Ref By</b> : Dr.GENERAL HEALTH CHECK UP	<b>Result No</b> : 0 / RES22028390

Parameter	Result	Normal Values
<b>RFT (RENAL FUNCTION TEST)</b>		
BLOOD UREA	: 18 mg/dl	13 - 45 mg/dl
Serum Creatinine	: 0.7 mg/dl	0.7 - 1.4 mg/dl
<b>LIPID PROFILE</b>		
Fasting Blood Sugar	:* 133 mg/dl	70 - 110 mg/dl
Total Cholesterol	: 165 mg/dl	150 - 240 mg/dl
Triglycerides	: 132 mg/dl	50 - 200 mg/dl
HDL Cholesterol	: 37 mg/dl	35 - 80 mg/dl
LDL Cholesterol	: 102 mg/dl	80 - 150 mg/dl
VLDL	: 26 mg/dl	10 - 50 mg/dl
Cholesterol / HDL ratio	: 4.4	< 6
LDL / HDL	: 2.7	< 4
<b>URINE ROUTINE EXAMINATION</b>		
Sugar	: Nil	
Albumin	: Nil	
<b>Microscopic Examination</b>		
Pus cells	: 3-4 /HPF	
Epithelial cells	: 1-2 /HPF	
RBC	: Nil /HPF	

\*\*\* End Of Report \*\*\*

  
Lab Tech.

Bio-Chemist

  
Lab In-Charge

Incharge Pathologist

Correlate Clinically, We use only sterilized disposable syring & needles.

Discrepancies due to technical or typing errors should be reported within 3 days for correction.

This report is to help you for better management of patient and not valid for medicolegal purpose.





## Department Of Laboratory

Date :

<b>Name</b> : Mr. VUYYALA SIVARAM BABU	<b>Age /Sex</b> : 31 Y(s)/Male
<b>Bill Date</b> : 24-Dec-2022 09:44 AM	<b>UMR No.</b> : UMR2218131
<b>Rept. Dt</b> : 24-Dec-2022 12:37 PM	<b>Bill No.</b> : BIL22027321
<b>Ref By</b> : Dr.GENERAL HEALTH CHECK UP	<b>Result No</b> : 0 / RES22028409

<u>Parameter</u>	<u>Result</u>	<u>Normal Values</u>
HB A1C	: 6.1 %	Non Diabetic : < 6.0 % Good Control : 6.0 - 7.5 % Fair control : 7.5 - 8.5 % Poor Control : > 8.5 %
Post Prandial Blood Sugar	: 179 mg/dl	80 - 199 mg/dl
<b>TFT (THYROID FUNCTION TEST)</b>		
T3 (TRI IODO THYRONINE)	: 100 ng/dl	80 - 200 ng/dl
T4 (THYROXINE)	: 8.10 ug/dl	5.1 - 14.1 ug/dl
TSH (THYROID STIMULATING HORMONE)	: 1.1 mIU/l	0.3 - 4.2 mIU/l
Blood Grouping & Rh Typing	: "O" POSITIVE	

\*\*\* End Of Report \*\*\*

Lab Tech.

Bio-Chemist

Lab In-Charge

Incharge Pathologist



V. SIVARAM BABU	Date: 24/12/2022	Date : UMR : 2218131
Age/Sex: 31Y/M	Ref :GENERAL	

### REAL TIME ULTRASONOGRAPHY OF THE ABDOMEN

**LIVER:** Normal in size, shape and outline. Parenchymal texture normal. No focal cystic or solid mass lesion. No intrahepatic biliary dilatation. Intrahepatic portion of IVC is normal.  
Portal vein is normal. Porta hepatis is normal.

**G. B:** Normal.  
**C.B.D:** Not dilated.

**PANCREAS:** Parenchymal texture normal. No ductal dilatation. No calculi.

**SPLEEN:** Normal in size & echotexture.

**AORTA:** Normal.

**KIDNEYS:** **Right kidney** measures 9.0 x 4.2cm .  
Normal in size, shape and outline. Parenchymal texture normal.  
Corticomedullary differentiation is well made out and is normal.  
No evidence of calculi/ Hydronephrosis.

**Left kidney** measures 9.5 x 4.3cm  
Normal in size, shape and outline. Parenchymal texture normal.  
Corticomedullary differentiation is well made out and is normal.  
Calculus measuring 2 mm noted in lower polar region  
No evidence of Hydronephrosis.

**U.B:** Normal.  
**Prostate** : Normal in size & echotexture.

\* No evidence of free fluid / lymphadenopathy.

### IMPRESSION:

➤ TINY LEFT RENAL CALCULUS.

- For clinical correlation & follow up.

**Dr. P.JAYA RAM MD RD.,**  
[Consultant Radiologist]



# Sentini Hospitals (P) Limited

Cardiology Department

## ECHOCARDIOGRAM REPORT

Name : MR V.SIVA RAMBABU  
 Age : 31 Years  
 Date : 24 /12/2022  
 Technician: Praveen/Srinivas

UMR/OP/IP No : 2218131  
 Sex : M  
 Echo No : 463

MITRAL VALVE : Normal  
 AORTIC VALVE : Normal  
 TRICUSPID VALVE : Normal  
 PULMONARY VALVE : Normal  
 AORTA : 29 mm  
 LEFT ATRIUM : 36 mm  
 LEFT VENTRICLE : Normal  
 RWMA : No LV RWMA  
 IVS : 12 mm LV IDd : 40 mm  
 PW : 12 mm LVIDs : 26 mm  
 LV EF : 60 %  
 RIGHT ATRIUM : Normal  
 RIGHT VENTRICLE : Normal  
 PULMONARY ARTERY : Normal  
 PULMONARY VEINS : Normal  
 IAS : Intact  
 IVS : Intact  
 PERICARDIUM : Normal  
 PERICARDIAL EFFUSION : No Effusion

### DOPPLER STUDY

MITRAL FLOW : E>A  
 TRICUSPID FLOW : TRJV- m/s TR Gr : mmHg RVSP: mmHg  
 AORTIC JET VELOCITY : 1.4 m/s AV Gr: mmHg  
 PULMONARY JET VELOCITY : 0.9 m/s  
 COLOUR DOPPLER : 1+MR 1+TR No AR No PR  
 IVC : Normal  
 SVC : Normal  
 OTHERS :  
 CONCLUSION :

Normal sized Cardiac Chambers  
 No LV RWMA  
 Trivial MR, Trivial TR,  
 No AR, No PAH  
 Normal LV Systolic Function,  
 No Pericardial Effusion,  
 No Clot /Vegetation/Masses

DR MADHURI MD.DMDRRAGHURAM MD.DM DR K. KRISHNA CHAND MD.DM DR A. RAVI KUMAR MD.DM  
 CONSULTANT CARDIOLOGIST CONSULTANT CARDIOLOGIST CONSULTANT CARDIOLOGIST CONSULTANT CARDIOLOGIST



ID : 1169

Name :

Age :

Years

Gender :

Male

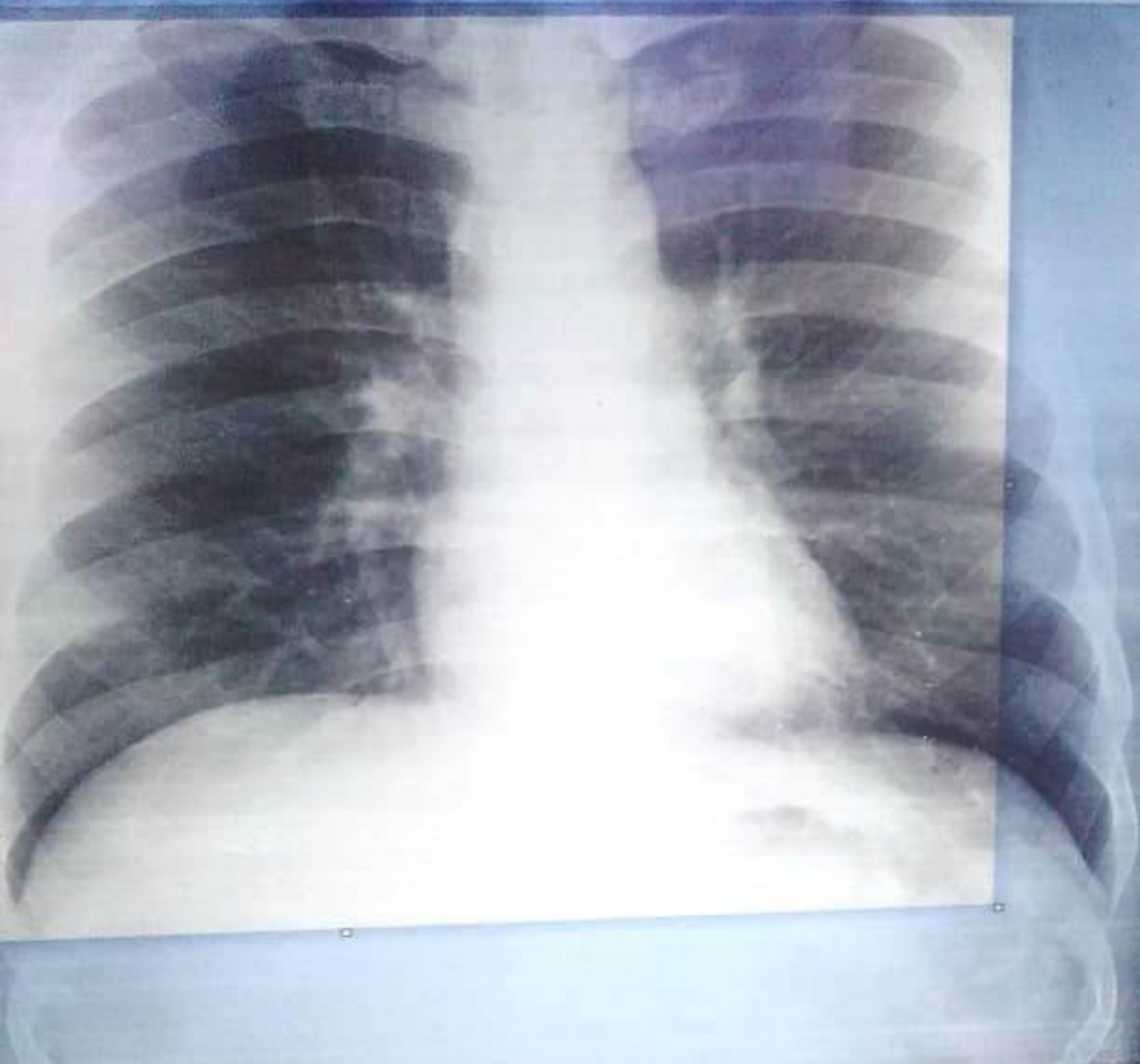
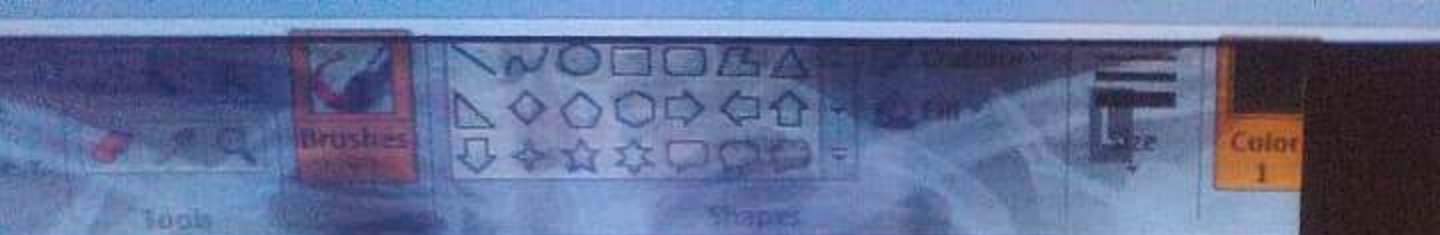
HR	79	BPM
P Dur	108	ms
PR int	171	ms
QRS Dur	95	ms
QT/QTc int	371/426	ms
P-QRS-T axis	67/91	-
RV5-SV1 amp	0.918/0.701	mV
RV3+SV1 amp	1.019	mV
RV6-SV2 amp	0.690/0.823	mV

Diagnosis Information  
 Sinus Rhythm  
 "Normal ECG"

V- Siva Babu Babu

Report Confirmed by:





V SIVA RAM BABU 31Y/M  
2218131

Chest PA  
Male

24-Dec-22 11:12:22 AM  
DR. GENERAL HEALTH CHEKUP

SENTINI HOSPITALS, VIJAYAWADA.