

Deep Biswas

CHECK LIST		
NAME		PATHOLOGY/PP
OP		ECG/PFT
AGE		ECHO/TMT
DATE	11/03/23	USG / CXR
PACKAGE		URINE / STOOL
REFERRED BY		MAMMO/ PAP
HT	154.4cm	EYE/ DENTAL
WT	56 kg	GP CONSULTATION
BP	110/70 mmHg	DIETITION
PULSE	86 bpm	CARDIOLOGIST
WAIST	82 cm	GYNECOLOGIST
HIP	87 cm	DENTAL
RESPIRATORY RATE		
CHEST (INHALE)	92 cm	
CHEST (EXHALE)	97 cm	
ABDOMEN	86 cm	

SpO2 — 99 %

Good night



LABORATORY INVESTIGATION REPORT

Patient Name : Mr. DEEP BISWAS
UHID : NMHK.2305848
Episode : OP
Ref. Doctor : NMH
Address : 57/7 R.N TAGORE ROAD , THAKURPUKUR ,Kolkata
a,West Bengal ,700063

Age/Sex : 36 Year(s)/Male
Order Date : 11/03/2023 09:23
Mobile No : 9088366178
DOB : 25/03/1986
Facility : NARAYAN MEMORIAL HOSPITAL

Biochemistry

INVESTIGATION	RESULTS	UNITS	BIOLOGICAL REF RANGE
Sample No : 07H0106057	Collection Date : 11/03/23 09:34	Ack Date : 11/03/2023 11:02	Report Date : 11/03/23 16:09

SERUM CREATININE

SAMPLE : SERUM

SERUM CREATININE 0.8 mg/dl 0.7 - 1.2
Jaffe Gen2 Compensated

BLOOD UREA NITROGEN

BLOOD UREA NITROGEN 10 mg/dl 6 - 20
Calculated

URIC ACID

SAMPLE : SERUM

URIC ACID 5.2 mg/dl 3.4 - 7
Enzymatic Colorimetric

SAMPLE : SERUM

RESULT 12.5

Sample No : 07H0106057B	Collection Date : 11/03/23 09:34	Ack Date : 11/03/2023 11:01	Report Date : 11/03/23 16:09
-------------------------	----------------------------------	-----------------------------	------------------------------

BLOOD SUGAR(F)

SAMPLE : PLASMA

BLOOD SUGAR FASTING 95 mg/dl 70 - 109
Hexokinase

Sample No : 07H0106118B	Collection Date : 11/03/23 13:26	Ack Date : 11/03/2023 14:34	Report Date : 11/03/23 16:09
-------------------------	----------------------------------	-----------------------------	------------------------------

BLOOD SUGAR(PP)

SAMPLE : PLASMA

BLOOD SUGAR PP 101 mg/dl 70.00 - 140.00
Hexokinase

End of Report





LABORATORY INVESTIGATION REPORT

Patient Name : Mr. DEEP BISWAS	Age/Sex : 36 Year(s)/Male
UHID : NMHK.2305848	Order Date : 11/03/2023 09:23
Episode : OP	
Ref. Doctor : NMH	Mobile No : 9088366178
	DOB : 25/03/1986
Address : 57/7 R.N TAGORE ROAD , THAKURPUKUR ,Kolkata a,West Bengal ,700063	Facility : NARAYAN MEMORIAL HOSPITAL

Dr.S. Chatterjee
MD, MBBS, FAAC
(CONSULTANT BIOCHEMIST)

Checked By



LABORATORY INVESTIGATION REPORT

Patient Name : Mr. DEEP BISWAS	Age/Sex : 36 Year(s)/Male
UHID : NMHK.2305848	Order Date : 11/03/2023 09:23
Episode : OP	
Ref. Doctor : NMH	Mobile No : 9088366178
	DOB : 25/03/1986
Address : 57/7 R.N TAGORE ROAD , THAKURPUKUR ,Kolkata a,West Bengal ,700063	Facility : NARAYAN MEMORIAL HOSPITAL

Biochemistry

INVESTIGATION	RESULTS	UNITS	BIOLOGICAL REF RANGE
Sample No : 07H0106057	Collection Date : 11/03/23 09:34	Ack Date : 11/03/2023 11:02	Report Date : 11/03/23 16:09

LIVER FUNCTION TEST (LFT)

SAMPLE : SERUM

TOTAL BILIRUBIN <i>Diazo Method</i>	0.5	mg/dl	0 - 1.1
DIRECT BILIRUBIN <i>Diazo Method</i>	0.2	mg/dl	0 - 0.2
INDIRECT BILIRUBIN <i>Calculated</i>	0.3	mg/dl	0.2 - 0.9
SGPT (ALT) <i>IFCC Without Pyridoxal Phosphate</i>	49 ▲	U/L	0 - 34
SGOT (AST) <i>IFCC Without Pyridoxal Phosphate</i>	28	U/L	0 - 31
ALKALINE PHOSPHATASE <i>IFCC</i>	74	U/L	53 - 128
TOTAL PROTEIN <i>Biuret</i>	7.4	g/dl	6.4 - 8.2
ALBUMIN <i>Bromocresol Green</i>	4.7	gm/dl	3.5 - 5.2
GLOBULIN <i>Calculated</i>	2.7	g/dl	2 - 3.5
ALBUMIN:GLOBULIN <i>Calculated</i>	1.7	-	1.1 - 2.5
GGT <i>Enzymatic colorimetric assay</i>	27	U/L	8 - 61





LABORATORY INVESTIGATION REPORT

Patient Name : Mr. DEEP BISWAS	Age/Sex : 36 Year(s)/Male
UHID : NMHK.2305848	Order Date : 11/03/2023 09:23
Episode : OP	Mobile No : 9088366178
Ref. Doctor : NMH	DOB : 25/03/1986
Address : 57/7 R.N TAGORE ROAD , THAKURPUKUR ,Kolkata a,West Bengal ,700063	Facility : NARAYAN MEMORIAL HOSPITAL

End of Report

Dr.S. Chatterjee
MD, MBBS, FAACC
(CONSULTANT BIOCHEMIST)

Checked By



LABORATORY INVESTIGATION REPORT

Patient Name : Mr. DEEP BISWAS	Age/Sex : 36 Year(s)/Male
UHID : NMHK.2305848	Order Date : 11/03/2023 09:23
Episode : OP	
Ref. Doctor : NMH	Mobile No : 9088366178
	DOB : 25/03/1986
Address : 57/7 R.N TAGORE ROAD , THAKURPUKUR ,Kolkata a,West Bengal ,700063	Facility : NARAYAN MEMORIAL HOSPITAL

Biochemistry

INVESTIGATION	RESULTS	UNITS	BIOLOGICAL REF RANGE
Sample No : 07H0106057	Collection Date : 11/03/23 09:34	Ack Date : 11/03/2023 11:02	Report Date : 11/03/23 16:09

LIPID PROFILE

SAMPLE : SERUM

TOTAL CHOLESTEROL	164	mg/dl	Desirable <200 Borderline 200-239 High >=240
<i>CHOD-PAP</i>			
HDL CHOLESTEROL	41	mg/dl	40 - 60
<i>Homogenous Enzymatic Colorimetric</i>			
LDL CHOLESTEROL	111	mg/dl	Optimal < 100 Borderline 130
<i>Homogenous Enzymatic Colorimetric</i>			
VLDL	12	mg/dl	0 - 30
<i>CALCULATED</i>			
CHOLESTEROL-HDL RATIO	4.00	-	
LDL-HDL RATIO	2.71	-	
TRIGLYCERIDES	97	mg/dl	Desirable <150 Borderline 150 - 200 High >200
<i>Enzymatic Colorimetric</i>			

End of Report

Dr.S. Chatterjee
MD, MBBS, FAACC
(CONSULTANT BIOCHEMIST)

Checked By



LABORATORY INVESTIGATION REPORT

Patient Name : Mr. DEEP BISWAS **Age/Sex** : 36 Year(s)/Male
UHID : NMHK.2305848 **Order Date** : 11/03/2023 09:23
Episode : OP
Ref. Doctor : NMH **Mobile No** : 9088366178
Address : 57/7 R.N TAGORE ROAD , THAKURPUKUR ,Kolkata **DOB** : 25/03/1986
a,West Bengal ,700063 **Facility** : NARAYAN MEMORIAL HOSPITAL

Hematology

INVESTIGATION	RESULTS	UNITS	BIOLOGICAL REF RANGE
Sample No : 07H0106057	Collection Date : 11/03/23 09:34	Ack Date : 11/03/2023 11:07	Report Date : 11/03/23 13:25

COMPLETE HAEMOGRAM (CBC)

SAMPLE : EDTA BLOOD

HAEMOGLOBIN (HB) <i>Colorimetric method (Cyn Meth)</i>	15.1	gm/dl	13 - 17
RBC COUNT <i>Electrical Impedance Method</i>	5.3	$\times 10^6/\text{ul}$	4.5 - 5.5
TOTAL WBC COUNT <i>Electrical Impedance Method</i>	5.6	$10^3/\text{cmm}$	4 - 10
PLATELET COUNT <i>Electrical Impedance Method</i>	280	$10^3/\text{cmm}$	150 - 410
PCV <i>RBC pulse ht. detection method</i>	45	%	40 - 50
MCV <i>calculated</i>	85	fl	83 - 101
MCH <i>Calculated</i>	29	pg	27 - 32
MCHC <i>Calculated</i>	33	gm/dl	31.5 - 34.5
ESR <i>Modified Westergren Method</i>	08	%	0 - 10
<u>DIFFERENTIAL COUNT</u>			
NEUTROPHILS <i>Microscopy</i>	54	%	40 - 80
LYMPHOCYTES <i>Microscopy</i>	40	%	20 - 40
MONOCYTES <i>Microscopy</i>	04	%	2 - 10





LABORATORY INVESTIGATION REPORT

Patient Name : Mr. DEEP BISWAS	Age/Sex : 36 Year(s)/Male
UHID : NMHK.2305848	Order Date : 11/03/2023 09:23
Episode : OP	
Ref. Doctor : NMH	Mobile No : 9088366178
	DOB : 25/03/1986
Address : 57/7 R.N TAGORE ROAD , THAKURPUKUR ,Kolkata a,West Bengal ,700063	Facility : NARAYAN MEMORIAL HOSPITAL

EOSINOPHILS 02 % 1 - 6
Microscopy

BASOPHILS 00 % 0 - 2
Microscopy

PERIPHERAL BLOOD SMEAR

RBC Normocytic normochromic.
WBC Within normal limits.
PLATELET Adequate.

End of Report

Angkita K. Ghosh

Dr. ANGKITA K. GHOSH
MBBS, MD(PATH)
(CONSULTANT PATHOLOGIST)

RegNo: 82734

Checked By





LABORATORY INVESTIGATION REPORT

Patient Name : Mr. DEEP BISWAS
UHID : NMHK.2305848
Episode : OP
Ref. Doctor : NMH
Address : 57/7 R.N TAGORE ROAD , THAKURPUKUR ,Kolkata
a,West Bengal ,700063

Age/Sex : 36 Year(s)/Male
Order Date : 11/03/2023 09:23
Mobile No : 9088366178
DOB : 25/03/1986
Facility : NARAYAN MEMORIAL HOSPITAL

Immunology

INVESTIGATION	RESULTS	UNITS	BIOLOGICAL REF RANGE
Sample No : 07H0106057	Collection Date : 11/03/23 09:34	Ack Date : 11/03/2023 11:07	Report Date : 11/03/23 15:41

BLOOD GROUPING & Rh TYPING

SAMPLE : EDTA BLOOD

BLOOD GROUP

Agglutination forward & Reverse

' B '

RH TYPE

POSITIVE


End of Report

Angkita K. Ghosh

Dr. ANGKITA K. GHOSH
MBBS, MD(PATH)
(CONSULTANT PATHOLOGIST)

RegNo: 82734

Checked By



LABORATORY INVESTIGATION REPORT

Patient Name : Mr. DEEP BISWAS
UHID : NMHK.2305848
Episode : OP
Ref. Doctor : NMH
Address : 57/7 R.N TAGORE ROAD , THAKURPUKUR ,Kolkata
a,West Bengal ,700063

Age/Sex : 36 Year(s)/Male
Order Date : 11/03/2023 09:23
Mobile No : 9088366178
DOB : 25/03/1986
Facility : NARAYAN MEMORIAL HOSPITAL

Immunology

INVESTIGATION	RESULTS	UNITS	BIOLOGICAL REF RANGE
Sample No : 07H0106057	Collection Date : 11/03/23 09:34	Ack Date : 11/03/2023 11:02	Report Date : 13/03/23 13:10

THYROID FUNCTION TEST

SAMPLE : SERUM

T3 ECLIA	1.43	ng/ml	0.6 - 1.8
T4 ECLIA	9.15	ug/dL	5.4 - 11.7
TSH ECLIA	2.85	uIU/ml	Adult Male – 0.27-5.50 Adult Female – 0.27-5.50 Newborns - <25 Upto 12 years – 0.3-5

ECLIA

Interpretations:


- For diagnostic purposes, the result should always be assessed in conjunction with the patient's medical history, clinical examinations and other findings.
- The assay is unaffected by icterus (Bilirubin < 701 $\mu\text{mol/L}$ or < 41 mg/dL), hemolysis (Hb < 0.621 mmol/L or < 1 g/dL), lipemia (intralipid < 1500 mg/dL), biotin (< 102 nmol/L or < 25 ng/ml), IgG < 2 g/dL and IgM < 0.5 g/dL).
- There is no high dose hook effect at TSH concentrations upto 1000 $\mu\text{mol/ml}$.
- TSH values may be transiently altered because of non thyroidal illness like several infections, liver disease, renal and heart failure, several burns, trauma and surgery etc. Drugs that decrease TSH values e.g. L-dopa, Glucocorticoid drugs that increase TSH values e.g. Iodine, Lithium, Amiodarone.
- The assay is unaffected by icterus (bilirubin < 633 $\mu\text{mol/L}$ or < 37 mg/dl), hemolysis (Hb < 1.4 mmol/L or < 2.3 g/dl), lipemia (triglycerid es < 28.5 mmol/L or 2500 mg/dl) and biotin (< 409 nmol or < 100 ng/ml).
- The assay is unaffected by icterus (bilirubin < 599 $\mu\text{mol/L}$ or < 35 mg/dl), hemolysis (Hb < 1.2 mmol/L or < 2.0 g/dl), lipemia (Intralipid < 1800 mg/dl) and biotin (< 123 nmol or < 30 ng/ml).

End of Report



Dr.S. Chatterjee
MD, MBBS, FAACC
(CONSULTANT BIOCHEMIST)

Checked By





LABORATORY INVESTIGATION REPORT

Patient Name : Mr. DEEP BISWAS **Age/Sex** : 36 Year(s)/Male
UHID : NMHK.2305848 **Order Date** : 11/03/2023 09:23
Episode : OP
Ref. Doctor : NMH **Mobile No** : 9088366178
Address : 57/7 R.N TAGORE ROAD , THAKURPUKUR ,Kolkata **DOB** : 25/03/1986
a,West Bengal ,700063 **Facility** : NARAYAN MEMORIAL HOSPITAL

Clinical Pathology

INVESTIGATION	RESULTS	UNITS	BIOLOGICAL REF RANGE
Sample No : 07H0106057	Collection Date : 11/03/23 09:34	Ack Date : 11/03/2023 12:37	Report Date : 13/03/23 10:41

URINE FOR R/E

SAMPLE : URINE

PHYSICAL EXAMINATION

VOLUME	15	ml	
COLOUR	PALE YELLOW		
APPEARANCE	SLIGHTLY HAZY		
SPECIFIC GRAVITY	1.010		1.010 - 1.030
REACTION(pH)	ACIDIC (pH-6.0)		

CHEMICAL EXAMINATION

SUGAR	ABSENT		ABSENT
ALBUMIN.	ABSENT		ABSENT
BLOOD	ABSENT		ABSENT
KETONE	ABSENT		ABSENT
BILE SALT	ABSENT		ABSENT
BILE PIGMENTS	ABSENT		ABSENT


MICROSCOPIC EXAMINATION

PUS CELLS	1-2/HPF		<5/HPF
EPITHELIAL CELLS	1-2/HPF		<20/HPF
RBC	ABSENT		ABSENT
CAST	ABSENT		ABSENT
CRYSTAL	ABSENT		ABSENT

Please correlate clinically.

End of Report

Dr. MAINAK CHAKRABORTY
MBBS, MD(PATH)





LABORATORY INVESTIGATION REPORT

Patient Name : Mr. DEEP BISWAS **Age/Sex** : 36 Year(s)/Male
UHID : NMHK.2305848 **Order Date** : 11/03/2023 09:23
Episode : OP
Ref. Doctor : NMH **Mobile No** : 9088366178
Address : 57/7 R.N TAGORE ROAD , THAKURPUKUR ,Kolkata **DOB** : 25/03/1986
a,West Bengal ,700063 **Facility** : NARAYAN MEMORIAL HOSPITAL

Clinical Pathology

INVESTIGATION	RESULTS	UNITS	BIOLOGICAL REF RANGE
Sample No : 07H0106057	Collection Date : 11/03/23 09:34	Ack Date : 11/03/2023 13:42	Report Date : 13/03/23 10:41

STOOL FOR R/E

SAMPLE : STOOL

PHYSICAL EXAMINATION

COLOUR. BROWNISH
CONSISTENCY SOFT
MUCUS PRESENT
VISIBLE BLOOD NOT FOUND
ADULT PARASITE NOT FOUND

CHEMICAL EXAMINATION

REACTION ACIDIC

MICROSCOPIC EXAMINATION

PUS CELLS 1-2 <5/HPF
VEG CELL PRESENT
RBC ABSENT
OVA NOT FOUND
PARASITES NOT FOUND
CYSTS NOT FOUND
BACTERIAL FLORA ABSENT
FAT GLOBULES ABSENT
STARCH GRANULES PRESENT

Please correlate clinically.

End of Report

Dr. MAINAK CHAKRABORTY
MBBS, MD(PATH)
(CONSULTANT PATHOLOGIST)



DIAGNOSTICS REPORT

Patient Name	: Mr. DEEP BISWAS	Order Date	: 11/03/2023 09:23
Age/Sex	: 36 Year(s)/Male	Report Date	: 11/03/2023 17:34
UHID	: NMHK.2305848	IP No	:
Ref. Doctor	: NMH	Facility	: NARAYAN MEMORIAL HOSPITAL
Address	: 57/7 R.N TAGORE ROAD, THAKURPUKUR,Kolkata, West Bengal, 700063	Mobile	: 9088366178

USG REPORT OF WHOLE ABDOMEN (SCREENING)

LIVER : Liver is normal in size. **Parenchymal echogenicity is raised.** Intrahepatic biliary radicles are not dilated. No focal mass lesion is seen.

PORTA :PV : Normal. PV measures 0.9 cm.

CD : Normal . CD measures 0.3 cm.

GALL BLADDER :Gall bladder is normal in size, contour, outline and position. No calculus is seen. Wall thickness is normal.

PANCREAS :Pancreas is normal in size and parenchymal echogenicity. Pancreatic duct is not dilated.

SPLEEN :Spleen is not enlarged and parenchyma shows normal homogeneous pattern.

KIDNEYS :Both kidneys are normal in size, shape, outline, position and parenchymal echogenicity. Corticomedullary differentiation maintained. No evidence of any calculus/ mass / hydronephrosis is seen. Right kidney measures : 9.0 cm & Left kidney measures : 9.4 cm.

URINARY BLADDER : Urinary bladder is normal in contour, outline and distension. No vesical lesion is seen.

PROSTATE : Prostate is normal size, outline and echotexture appear normal. No focal lesion is seen. Prostate measures 3.3 cm x 3.9 cm x 3.1 cm. It weight approx 22 gm.



DIAGNOSTICS REPORT

Patient Name	: Mr. DEEP BISWAS	Order Date	: 11/03/2023 09:23
Age/Sex	: 36 Year(s)/Male	Report Date	: 11/03/2023 17:34
UHID	: NMHK.2305848	IP No	:
Ref. Doctor	: NMH	Facility	: NARAYAN MEMORIAL HOSPITAL
Address	: 57/7 R.N TAGORE ROAD, THAKURPUKUR,Kolkata, West Bengal, 700063	Mobile	: 9088366178

PERITONEUM : : No free fluid is noted.

RETROPERITONEUM : IVC and aorta appear normal. No lymphadenopathy is seen.

IMPRESSION : Diffuse fatty changes in liver (Grade II).

Dr.MADHUSHREE RAY NASKAR,
MBBS,DMRD

Consultant Radiologist

RegNo: 57032



DIAGNOSTICS REPORT

Patient Name	: Mr. DEEP BISWAS	Order Date	: 11/03/2023 09:23
Age/Sex	: 36 Year(s)/Male	Report Date	: 11/03/2023 16:24
UHID	: NMHK.2305848	IP No	:
Ref. Doctor	: NMH	Facility	: NARAYAN MEMORIAL HOSPITAL
Address	: 57/7 R.N TAGORE ROAD, THAKURPUKUR,Kolkata, West Bengal, 700063	Mobile	: 9088366178

CHEST X-RAY REPORT OF PA VIEW

Lung fields are clear. No focal parenchymal opacity is seen.

No appreciable pleural thickening / calcification is noted.

Costo-phrenic angles are normal.


Cardiac shadow appears normal.

Bilateral hilar shadows are normal.

No obvious bony abnormality is seen.

Dr.Sayani Mahal , MD Radiology (AIIMS),PDCC (AIIMS)

RegNo: 74369





DIAGNOSTICS REPORT

Patient Name	: Mr. DEEP BISWAS	Order Date	: 11/03/2023 09:23
Age/Sex	: 36 Year(s)/Male	Report Date	: 11/03/2023 15:05
UHID	: NMHK.2305848	IP No	:
Ref. Doctor	: NMH	Facility	: NARAYAN MEMORIAL HOSPITAL
Address	: 57/7 R.N TAGORE ROAD, THAKURPUKUR,Kolkata, West Bengal, 700063	Mobile	: 9088366178

ELECTROCARDIOGRAM REPORT (ECG)

HR	: 64 bpm
Rhythm	: Sinus
P wave	: Normal
PR Interval	: 140 msec
QRS axis	: Normal (52 Degree)
QRS duration	: 82 msec
QRS configuration	: Normal
T wave	: Non specific changes
ST segment	: Non specific changes
QTc	: 402 msec
QT	: 386 msec

IMPRESSION:

- Sinus rhythm. Normal QRS axis.
 - Non specific ST-T changes.
- Clinical correlation please.

Dr.INDIRA BANERJEE ,
MD,DNB,MRCPC (UK)

Board Certified Comprehensive
Echocardiographer (USA)



DEEP BISWAS

2305848

Male

36 years

..... cm / kg

HR 64/min

Axis: 43°

SINUS RHYTHM
NORMAL ECG

Intervals:

RR 931 ms

P 98 ms

PR 140 ms

QRS 82 ms

QT 386 ms

QTc 402 ms
(Bazett)

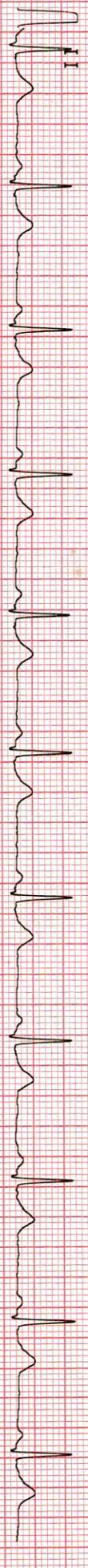
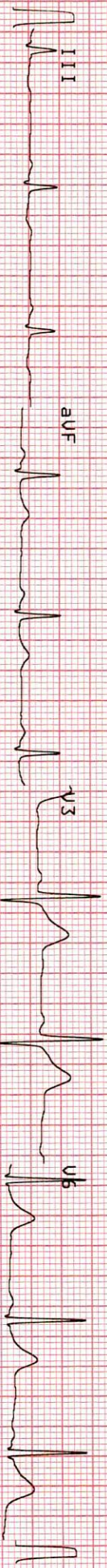
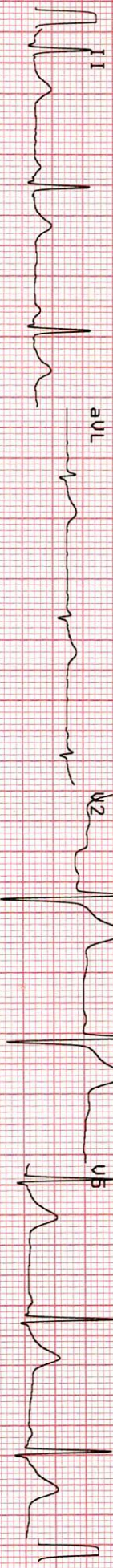
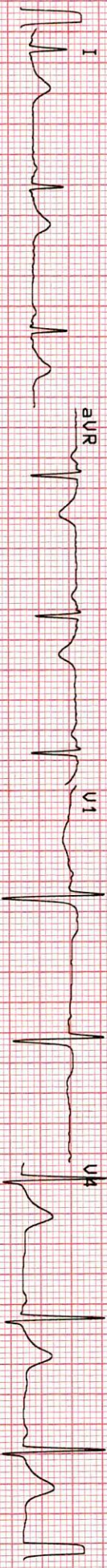
T 24°

6.02

UNCONFIRMED REPORT

10 mm/mV

10 mm/mV



10 mm/mV

25 mm/s

0.05-25 Hz

F50

55F

585

11.03.2023

11:53:46

NARAYAN MEMORIAL

HOSPITAL-BEHALA

RT-102plus

1.25/25/50





DIAGNOSTICS REPORT

Patient Name	: Mr. DEEP BISWAS	Order Date	: 11/03/2023 09:23
Age/Sex	: 36 Year(s)/Male	Report Date	: 11/03/2023 14:29
UHID	: NMHK.2305848	IP No	:
Ref. Doctor	: NMH	Facility	: NARAYAN MEMORIAL HOSPITAL
Address	: 57/7 R.N TAGORE ROAD, THAKURPUKUR,Kolkata, West Bengal, 700063	Mobile	: 9088366178

ECHOCARDIOGRAPHY (SCREENING)

Status of Patient :

- * No regional wall motion abnormality at rest.
- * Good LV systolic function (EF = 62%).
- * Good RV systolic function (TAPSE = 21 mm).
- * Mild TR. TR gradient = 25 mmHg.
- * Normal valve morphology.
- * Normal LV diastolic function.
- * No pericardial effusion.
- * No pulmonary arterial hypertension.
- * IVC normal diameter & > 50% respiratory variation.
- * No thrombus, mass, vegetation seen.

Dr.INDIRA BANERJEE ,
MD,DNB,MRCPCH (UK)

Board Certified Comprehensive
Echocardiographer (USA)

