



Cert. No. MC - 4830



Cert. No. H-2016-0369

**PRE EMPLOYMENT HEALTH CHECK UP REPORT**

**DATE-** 12/08/2022

**PATIENT NAME-** Mrs. Ritu Yadav **AGE-** 30

**GENDER** female

**WEIGHT (kg)**

**PHYSICAL EXAMINATION**

**Pulse**

**BP**

**Blood Sugar(Random)**

**FINDINGS**

**Investigations: Investigation reports are attached**

**FITNESS CERTIFICATE**

**SIGNATURE**

patient is fit  
→ Gynecology opinion I/O use  
w/A report.  
→ Avoid fatty oily food.

*[Signature]*



(This is only professional opinion and not the diagnosis, Please correlate clinically)

Q Block South City 11, Sohna Road, Main Sector-47, Gurgaon, Haryana

Ph.: 0124-4900000 (100 Lines) Fax : 0124-2218733 E-mail : parkmedicenters@gmail.com

**PARK GROUP OF HOSPITALS : West Delhi • South Delhi • Gurgaon • Karnal • Panipat • Hodal • Ambala • Behror**

the **health** care providers

the **health** care providers



**DEPARTMENT OF PATHOLOGY**

Patient Name : Mrs. RITU YADAV  
MR No : 658171  
Age/Sex : 30 Years 3 Months 16 Days / Female  
Type : OPD  
TPA/Corporate : MEDWHEEL PVT LTD

Bill Date : 09/08/2022  
Reporting Date : 09/08/2022  
Sample ID : 27279  
Bill/Req. No. : 22939658  
Ref Doctor : Dr.RMO

Test	Result	Blo. Ref. Interval	Units
<b>BLOOD SUGAR 2 HR. PP</b>			
BLOOD SUGAR P.P.	88	80 - 150	mg/dl

\*\*\*\*\* END OF THE REPORT \*\*\*\*\*



Sample no.

Dr.NALANDA BUKTARE  
MD (Pathology)

Dr.PRADIP KUMAR  
Consultant (Microbiology)

Dr.NISHA TIWARI  
MBBS, MD (Microbiology)

USER NM. NEERAJPA752

(This is only professional opinion and not the diagnosis, Please correlate clinically)

Q Block South City 11, Sohna Road, Main Sector-47, Gurgaon, Haryana  
Ph.: 0124-4900000 (100 Lines) Fax : 0124-2218733 E-mail : parkmedicenters@gmail.com

**PARK GROUP OF HOSPITALS : West Delhi • South Delhi • Gurgaon • Karnal • Panipat • Hodal • Ambala • Behror**

the **health** care providers

the **health** care providers





NABL  
Cert. No. MC - 4830



NABH  
Cert. No. H-2016-0369

**DEPARTMENT OF PATHOLOGY**

Patient Name : Mrs. RITU YADAV  
MR No : 658171  
Age/Sex : 30 Years 3 Months 16 Days / Female  
Type : OPD  
TPA/Corporate : MEDIWHEEL PVT LTD

Bill Date : 09/08/2022  
Reporting Date : 09/08/2022  
Sample ID : 27279  
Bill/Req. No. : 22939658  
Ref Doctor : Dr.RMO

Test	Result	Bio. Ref. Interval	Units
<b>BLOOD SUGAR FASTING</b>			
PLASMA GLUCOSE FASTING	88	60 - 100	mg/dl

\*\*\*\*\* END OF THE REPORT \*\*\*\*\*



Sample no.

Dr.NALANDA BUKTARE  
MD (Pathology)

Dr.PRADIP KUMAR  
Consultant (Microbiology)

Dr.BHAVANA CHAUHAN  
MBBS, MD (Microbiology)

USER NM. MOHITPA159

(This is only professional opinion and not the diagnosis, Please correlate clinically)

Q Block South City 11, Sohna Road, Main Sector-47, Gurgaon, Haryana  
Ph.: 0124-4900000 (100 Lines) Fax : 0124-2218733 E-mail : parkmedicenters@gmail.com

**PARK GROUP OF HOSPITALS : West Delhi • South Delhi • Gurgaon • Karnal • Panipat • Hodal • Ambala • Behror**

the **health** care providers

the **health** care providers





**DEPARTMENT OF PATHOLOGY**

<b>Patient Name</b> :	Mrs. RITU YADAV	<b>Bill Date</b> :	09/08/2022
<b>MR No</b> :	658171	<b>Reporting Date</b> :	09/08/2022
<b>Age/Sex</b> :	30 Years 3 Months 16 Days / Female	<b>Sample ID</b> :	27279
<b>Type</b> :	OPD	<b>Bill/Req. No.</b> :	22939658
<b>TPA/Corporate</b> :	MEDWHEEL PVT LTD	<b>Ref Doctor</b> :	Dr.RMO

Test	Result	Blo. Ref. Interval	Units
<b>BLOOD GROUPING AND RH FACTOR</b>			
BLOOD GROUP	" O " RH NEGATIVE		

\*\*\*\*\* END OF THE REPORT \*\*\*\*\*



Sample no.

**Dr.NALANDA BUKTARE**  
MD (Pathology)

**Dr.PRADIP KUMAR**  
Consultant (Microbiology)

**Dr.NISHA TIWARI**  
MBBS, MD (Microbiology)

USER NM : MOHIPA159

(This is only professional opinion and not the diagnosis, Please correlate clinically)

Q Block South City 11, Sohna Road, Main Sector-47, Gurgaon, Haryana  
Ph.: 0124-4900000 (100 Lines) Fax : 0124-2218733 E-mail : parkmedicenters@gmail.com

**PARK GROUP OF HOSPITALS : West Delhi • South Delhi • Gurgaon • Karnal • Panipat • Hodal • Ambala • Behror**

the **health** care providers

the **health** care providers





## DEPARTMENT OF PATHOLOGY

Patient Name : Mrs. RITU YADAV

MR No : 658171

Age/Sex : 30 Years 3 Months 16 Days / Female

Type : OPD

TPA/Corporate : MEDIWHEEL PVT LTD

Bill Date : 09/08/2022

Reporting Date : 09/08/2022

Sample ID : 27279

Bill/Req. No. : 22939658

Ref Doctor : Dr.RMO

Test	Result	Blo. Ref. Interval	Units
<b>CBC</b>			
HAEMOGLOBIN	13.6	12 - 15	gms/dL
TOTAL LEUCOCYTE COUNT	5600	4000 - 10000	/ $\mu$ L
<b>DIFFERENTIAL COUNT</b>			
NEUTROPHILS	50	40.0 - 80.0	%
LYMPHOCYTES	37	20.0 - 40.0	%
MONOCYTES	10	2.0 - 10.0	%
EOSINOPHILS	03	0.0 - 5.0	%
BASOPHILS	00	0.0 - 2.0	%
RED BLOOD CELL COUNT	4.6	3.5 - 5.5	millions/ $\mu$ L
PACKED CELL VOLUME	39.6	35.0 - 50.0	%
MEAN CORPUSCULAR VOLUME	84.4	83 - 101	fL
MEAN CORPUSCULAR HAEMOGLOBIN	29.0	27 - 31	Picogrames
MEAN CORPUSCULAR HB CONC	34.3	33 - 37	g/dl
PLATELET COUNT	226	150 - 450	lakhs
RDW	14.5	11.6 - 13.7	%

\*\*\*\*\* END OF THE REPORT \*\*\*\*\*



Sample no.

Dr.NALANDA BUKTARE  
MD (Pathology)

Dr.PRADIP KUMAR  
Consultant (Microbiology)

Dr.BHAVANA CHAUHAN  
MBBS, MD (Microbiology)

USER NM : MOHITPA159

(This is only professional opinion and not the diagnosis, Please correlate clinically)

Q Block South City 11, Sohna Road, Main Sector-47, Gurgaon, Haryana  
Ph.: 0124-4900000 (100 Lines) Fax : 0124-2218733 E-mail : parkmedcenters@gmail.com

PARK GROUP OF HOSPITALS : West Delhi • South Delhi • Gurgaon • Karnal • Panipat • Hodal • Ambala • Behror

the **health** care providers

the **health** care providers





## DEPARTMENT OF PATHOLOGY

Patient Name : Mrs. RITU YADAV

MR No : 658171

Age/Sex : 30 Years 3 Months 16 Days / Female

Type : OPD

TPA/Corporate : MEDIWHEEL PVT LTD

Bill Date : 09/08/2022

Reporting Date : 09/08/2022

Sample ID : 27279

Bill/Req. No. : 22939658

Ref Doctor : Dr.RMO

Test	Result	Blo. Ref. Interval	Units
<b>ESR (WESTERGREN)</b>			
E.S.R.	32	H 0 - 15	mm at the end of 1st hr

\*\*\*\*\* END OF THE REPORT \*\*\*\*\*



Sample no.

Dr.NALANDA BUKTARE  
MD (Pathology)

Dr.PRADIP KUMAR  
Consultant (Microbiology)

Dr.NISHA TIWARI  
MBBS, MD (Microbiology)

USER NM MOHIPA159

(This is only professional opinion and not the diagnosis, Please correlate clinically)

Q Block South City 11, Sohna Road, Main Sector-47, Gurgaon, Haryana  
Ph.: 0124-4900000 (100 Lines) Fax : 0124-2218733 E-mail : parkmedicenters@gmail.com

PARK GROUP OF HOSPITALS : West Delhi • South Delhi • Gurgaon • Karnal • Panipat • Hodal • Ambala • Behror

the **health** care providers

the **health** care providers





## DEPARTMENT OF PATHOLOGY

Patient Name : Mrs. RITU YADAV  
 MR No : 658171  
 Age/Sex : 30 Years 3 Months 16 Days / Female  
 Type : OPD  
 TPA/Corporate : MEDIWHEEL PVT LTD

Bill Date : 09/08/2022  
 Reporting Date : 10/08/2022  
 Sample ID : 27279  
 Bill/Req. No. : 22939658  
 Ref Doctor : Dr.RMO

Test	Result	Bio. Ref. Interval	Units
<b>THYROID PROFILE</b>			
TRI-IODOTHYRONINE (T3)	0.99	0.60 - 1.81	ng/ml
THYROXINE (T4)	6.3	5.01 - 12.45	µg/dL
THYROID STIMULATING HORMONE (TSH)	3.61	0.5-5.50	µIU/ml

\*\*\*\*\* END OF THE REPORT \*\*\*\*\*



Sample no.

Dr.NALANDA BUKTARE  
 MD (Pathology)

Dr.PRADIP KUMAR  
 Consultant (Microbiology)

Dr.NISHA TIWARI  
 MBBS, MD (Microbiology)

USER NM, DINESH

(This is only professional opinion and not the diagnosis, Please correlate clinically)

Q Block South City 11, Sohna Road, Main Sector-47, Gurgaon, Haryana  
 Ph.: 0124-4900000 (100 Lines) Fax : 0124-2218733 E-mail : parkmedicenters@gmail.com

PARK GROUP OF HOSPITALS : West Delhi • South Delhi • Gurgaon • Karnal • Panipat • Hodal • Ambala • Behror

the **health** care providers the **health** care providers





## DEPARTMENT OF PATHOLOGY

Patient Name : Mrs. RITU YADAV  
 MR No : 658171  
 Age/Sex : 30 Years 3 Months 16 Days / Female  
 Type : OPD  
 TPA/Corporate : MEDIWHEEL PVT LTD

Bill Date : 09/08/2022  
 Reporting Date : 09/08/2022  
 Sample ID : 27279  
 Bill/Req. No. : 22939658  
 Ref Doctor : Dr.RMO

Test	Result	Blo. Ref. Interval	Units
<b>LFT (LIVER FUNCTION TEST)</b>			
LFT			
TOTAL BILIRUBIN	0.8	0.1 - 1.2	mg/dL
DIRECT BILIRUBIN	0.3	0 - 0.4	mg/dL
INDIRECT BILIRUBIN	0.5	0.10 - 0.6	mg/dL
SGOT (AST)	34	0 - 45	U/L
SGPT (ALT)	39	0 - 45	U/L
ALKALINE PHOSPHATASE	107	30 - 170	IU/L
TOTAL PROTEINS	7.0	6.4 - 8.0	g/dL
ALBUMIN	4.0	3.3 - 5.5	g/dL
GLOBULIN	3	2.3 - 4.5	g/dL
A/G RATIO	1.33	1.1 - 2.2	

\*\*\*\*\* END OF THE REPORT \*\*\*\*\*



Sample no.

Dr.NALANDA BUKTARE  
 MD (Pathology)

Dr.PRADIP KUMAR  
 Consultant (Microbiology)

Dr.BHAVANA CHAUHAN  
 MBBS, MD (Microbiology)

USER NM : MOHIPA159

(This is only professional opinion and not the diagnosis, Please correlate clinically)

Q Block South City 11, Sohna Road, Main Sector-47, Gurgaon, Haryana  
 Ph.: 0124-4900000 (100 Lines) Fax : 0124-2218733 E-mail : parkmedicenters@gmail.com

PARK GROUP OF HOSPITALS : West Delhi • South Delhi • Gurgaon • Karnal • Panipat • Hodal • Ambala • Behror

the **health** care providers

the **health** care providers







NABL  
Cert. No. MC - 4230



NABH  
Cert. No. H-2018-0389

## DEPARTMENT OF PATHOLOGY

Patient Name : Mrs. RITU YADAV  
MR No : 658171  
Age/Sex : 30 Years 3 Months 16 Days / Female  
Type : OPD  
TPA/Corporate : MEDIWHEEL PVT LTD

Bill Date : 09/08/2022  
Reporting Date : 09/08/2022  
Sample ID : 27279  
Bill/Req. No. : 22939658  
Ref Doctor : Dr.RMO

Test	Result	Bio. Ref. Interval	Units
<b>KFT (RENAL PROFILE)</b>			
<b>KFT</b>			
SERUM UREA	15	10 - 45	mg/dL
SERUM CREATININE	0.8	0.4 - 1.4	mg/dL
SERUM URIC ACID	4.4	2.5 - 7.0	mg/dL
SERUM SODIUM	137	136 - 145	meq/l
SERUM POTASSIUM	4.3	3.5 - 5.5	meq/l
SERUM CALCIUM	8.8	8.5 - 10.5	mg/dL
SERUM PHOSPHORUS	3.0	2.5 - 4.5	mg/dL

\*\*\*\*\* END OF THE REPORT \*\*\*\*\*



Sample no.

Dr. NALANDA BUKTARE  
MD (Pathology)

Dr. PRADIP KUMAR  
Consultant (Microbiology)

Dr. BHAVANA CHAUHAN  
MBBS, MD (Microbiology)

(This is only professional opinion and not the diagnosis, Please correlate clinically) USER NM: MOHITPA159

Q Block South City 11, Sohna Road, Main Sector-47, Gurgaon, Haryana  
Ph.: 0124-4900000 (100 Lines) Fax : 0124-2218733 E-mail : parkmedicenters@gmail.com

PARK GROUP OF HOSPITALS : West Delhi • South Delhi • Gurgaon • Karnal • Panipat • Hodal • Ambala • Behror

the health care providers the health





## DEPARTMENT OF PATHOLOGY

Patient Name : Mrs. RITU YADAV  
 MR No : 658171  
 Age/Sex : 30 Years 3 Months 16 Days / Female  
 Type : OPD  
 TPA/Corporate : MEDIWHEEL PVT LTD

Bill Date : 09/08/2022  
 Reporting Date : 09/08/2022  
 Sample ID : 27279  
 Bill/Req. No. : 22939658  
 Ref Doctor : Dr.RMO

Test	Result	Bio. Ref. Interval	Units
<b>LIPID PROFILE</b>			
LIPID PROFILE			
TOTAL CHOLESTEROL	192	0 - 250	mg/dL
SERUM TRIGLYCERIDES	91	60 - 165	mg/dl
HDL-CHOLESTEROL	42	30 - 70	mg/dl
VLDL CHOLESTEROL	18	6 - 32	mg/dL
LDL	132	50 - 135	mg/dl
LDL CHOLESTEROL/HDL RATIO	3.1	1.0 - 3.0	mg/dL
TOTAL CHOLESTEROL/HDL RATIO	4.5	2.0 - 5.0	mg/dl

\*\*\*\*\* END OF THE REPORT \*\*\*\*\*



Sample no.

Dr.NALANDA BUKTARE  
 MD (Pathology)

Dr.PRADIP KUMAR  
 Consultant (Microbiology)

Dr.BHAVANA CHAUHAN  
 MBBS, MD (Microbiology)

USER NM : MOHIPA159

(This is only professional opinion and not the diagnosis, Please correlate clinically)

Q Block South City 11, Sohna Road, Main Sector-47, Gurgaon, Haryana  
 Ph.: 0124-4900000 (100 Lines) Fax : 0124-2218733 E-mail : parkmedicenters@gmail.com

PARK GROUP OF HOSPITALS : West Delhi • South Delhi • Gurgaon • Karnal • Panipat • Hodal • Ambala • Behror

the **health** care providers

the **health** care providers



**DEPARTMENT OF RADIOLOGY**

Patient Name	Mrs. RITU YADAV	Billed Date	: 09/08/2022	10.55 AM
Reg No	658171	Reported Date	: 09/08/2022	
Age/Sex	30 Years 3 Months 16Days / Female	Req. No.	: 22939658	
Type	OPD	Consultant Doctor	: Dr. RMO	

**X-RAY CHEST AP/PA**

X-RAY CHEST P.A. VIEW

Bilateral lungs appears normal.

No focal lung lesion seen.

No evidence of free fluid is seen.

Both hila are normal in size, have equal density and bear normal relationship.


The heart and trachea are central in position and no mediastinal abnormality is visible.

The cardiac size is normal for patient age and view.

The domes of the diaphragms are normal in position, and show smooth outline.

To be correlated clinically



  
Dr. ANSHU K. SHARMA  
MBBS, MD  
CONSULTANT RADIOLOGIST

Dr. SAKET RUPRAMKA  
MBBS, MD  
CONSULTANT RADIOLOGIST

Dr. MANJEET SEHRAWAT  
MBBS, MD, PDCC  
CONSULTANT RADIOLOGIST

Dr. NEENA SIKKA  
MBBS, DNB  
CONSULTANT RADIOLOGIST

*(This is only professional opinion and not the diagnosis, Please correlate clinically.)*

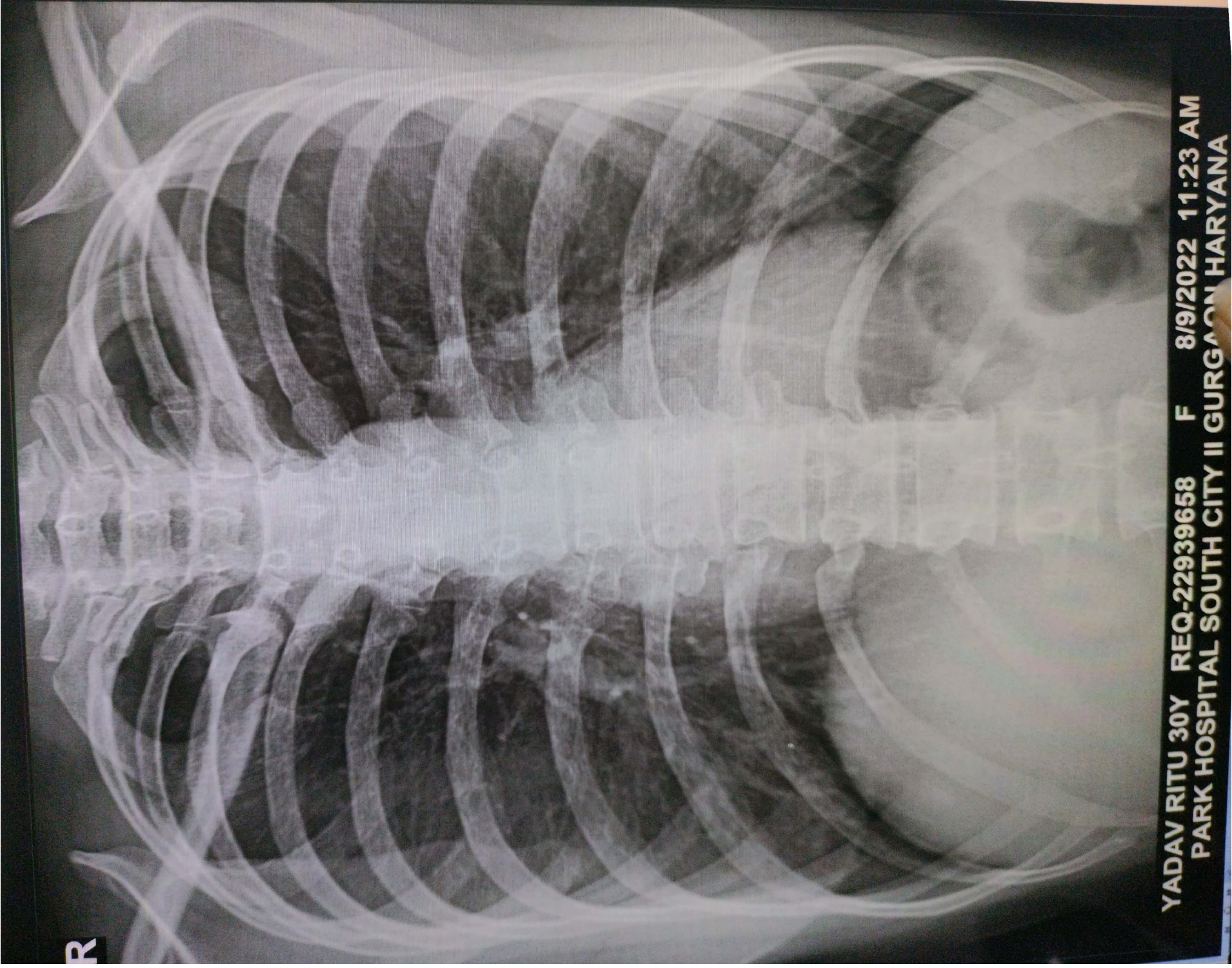
Gurgaon : Q Block, South City-II, Sohna Road, Sector-47, Gurugram-122002, (Haryana)  
Faridabad : J-Block, Sector - 10, Near Court, Faridabad - 121004, (Haryana)

• Helpline : 0124-4900000  
• Helpline : 0129-4200000

the **health** care providers

the **health** care providers





YADAV RITU 30Y REQ-22939658 F 8/9/2022 11:23 AM  
PARK HOSPITAL SOUTH CITY II GURGAON HARYANA



**DEPARTMENT OF RADIOLOGY**

Patient Name	Mrs. RITU YADAV	Billed Date	: 09/08/2022	10.55 AM
Reg No	658171	Reported Date	: 09/08/2022	
Age/Sex	30 Years 3 Months 16Days / Female	Req. No.	: 22939658	
Type	OPD	Consultant Doctor	: Dr. RMO	

**USG WHOLE ABDOMEN**

The real time, B mode, gray scale sonography of the abdominal organs was performed.

**LIVER** : The liver is normal in size, 13.2cm shape and echotexture. No evidence of any focal lesion. IHBR is not dilated.

**GALL BLADDER** : The gall bladder is well distended . No evidence any calculus or mass seen.GB wall thickness with in normal limits.No evidence of pericholecystic fluid is seen.

**BILE DUCT** :The common bile duct is normal in caliber. No evidence of calculus is noted in common bile duct.

**SPLEEN** :The spleen is normal in size and shape.Its echotexture is homogeneous.No evidence of focal lesion is noted.

**PANCREAS** :The pancreas is normal in size, shape, contours and echotexture.No evidence of solid or cystic mass lesion is noted.MPD is not dilated. No evidence of peripancreatic collection.

**KIDNEYS** :The bilateral kidneys are normal in size and echotexture. Cortico-medullary differentiation is maintained.There is no evidence of obvious calculus or hydronephrosis.

**URINARY BLADDER** :The urinary bladder is minimal distended.It shows uniformly thin walls and sharp mucosa.No evidence of calculus is seen. No evidence of mass or diverticulum is noted.

**UTERUS**: The uterus is anteverted. It measures 6.1x4.1x2.6 cms. in the longitudinal, anteroposterior and transverse dimensions respectivelyThe uterine margins is smooth and does not reveal any contour abnormalities.

The uterine myometrium shows homogeneous echotexture.

No evidence of leiomyoma is noted. No solid or cystic mass lesion is noted.

The endometrial echo is in the midline and measures 4.4 mm.

The ovaries on the either side show normal echotexture.

No adnexal mass is seen.No cyst is seen in ovaries.

**Minimal free fluid is seen in POD.**

No evidence of obvious retroperitoneal or mesentric lymphadenopathy is seen.

**IMPRESSION- Minimal free fluid is seen in POD.**



To be correlated clinically

Dr. ANSHU K. SHARMA  
MBBS, MD  
CONSULTANT RADIOLOGIST

Dr. SAKET RUPRAMKA  
MBBS, MD  
CONSULTANT RADIOLOGIST

Dr. MANJEET SEHRAWAT  
MBBS, MD, PDCC  
CONSULTANT RADIOLOGIST

Dr. NEENA SIKKA  
MBBS, DNB  
CONSULTANT RADIOLOGIST

(This is only professional opinion and not the diagnosis, Please correlate clinically.)

