

NE

MEDICAL EXAMINATION REPORT (MER)

If the examinee is suffering from an acute life threatening situation, you may be obliged to disclose the result of the medical examination to the examinee.

1. Name of the examinee	:	Mr./Mrs./Ms. SMITHA RAJ
2. Mark of Identification	:	(Mole/Scar/any other (specify location)):
3. Age/Date of Birth	:	01-01-1976 Gender: <input checked="" type="radio"/> F <input type="radio"/> M
4. Photo ID Checked	:	(Passport/Election Card/PAN Card/Driving Licence/Company ID)

PHYSICAL DETAILS:

a. Height 151 (cms)	b. Weight 58 (Kgs)	c. Girth of Abdomen ... 82 (cms)
d. Pulse Rate 70 (/Min)	e. Blood Pressure:	Systolic 120 Diastolic 80
		1 st Reading
		2 nd Reading

FAMILY HISTORY:

Relation	Age if Living	Health Status	If deceased, age at the time and cause
Father		/ NS	
Mother			
Brother(s)			
Sister(s)			

HABITS & ADDICTIONS: Does the examinee consume any of the following?

Tobacco in any form	Sedative	Alcohol
—	—	—

PERSONAL HISTORY

- a. Are you presently in good health and entirely free from any mental or Physical impairment or deformity. If No, please attach details. HIV Y N
- b. Have you undergone/been advised any surgical procedure? Hypertension Y N
- c. During the last 5 years have you been medically examined, received any advice or treatment or admitted to any hospital? Y N
- d. Have you lost or gained weight in past 12 months? Y N

Have you ever suffered from any of the following?

- Psychological Disorders or any kind of disorders of the Nervous System? Y N
- Any disorders of Respiratory system? Y N
- Any Cardiac or Circulatory Disorders? Y N
- Enlarged glands or any form of Cancer/Tumour? Y N
- Any Musculoskeletal disorder? Y N
- Any disorder of Gastrointestinal System? Y N
- Unexplained recurrent or persistent fever, and/or weight loss Y N
- Have you been tested for HIV/HBsAg / HCV before? If yes attach reports Y N
- Are you presently taking medication of any kind? Telma H. Y N

• Any disorders of Urinary System?

Y/N

• Any disorder of the Eyes, Ears, Nose, Throat or Mouth & Skin

Y/N

FOR FEMALE CANDIDATES ONLY

a. Is there any history of diseases of breast/genital organs?

Y/N

d. Do you have any history of miscarriage/abortion or MTP

Y/N

b. Is there any history of abnormal PAP Smear/Mammogram/USG of Pelvis or any other tests? (If yes attach reports)

Y/N

e. For Parous Women, were there any complication during pregnancy such as gestational diabetes, hypertension etc

Y/N

c. Do you suspect any disease of Uterus, Cervix or Ovaries?

Y/N

f. Are you now pregnant? If yes, how many months?

Y/N

CONFIDENTIAL COMMENTS FROM MEDICAL EXAMINER

➤ Was the examinee co-operative?

Y/N

➤ Is there anything about the examinee's health, lifestyle that might affect him/her in the near future with regard to his/her job?

Y/N

➤ Are there any points on which you suggest further information be obtained?

Y/N

➤ Based on your clinical impression, please provide your suggestions and recommendations below;

Medical consult

➤ Do you think he/she is MEDICALLY FIT or UNFIT for employment.

FIT

MEDICAL EXAMINER'S DECLARATION

I hereby confirm that I have examined the above individual after verification of his/her identity and the findings stated above are true and correct to the best of my knowledge.

Name & Signature of the Medical Examiner :

Seal of Medical Examiner :

Dr. GEORGE THOMAS
MD, FCSI, FIAE
MEDICAL EXAMINER
Reg: 85011

Name & Seal of DDRC SRL Branch :

Date & Time :



27/03/2023

DDRC SRL Diagnostics Limited

Corp. Office: DDRC SRL Tower, G- 131, Panampilly Nagar, Ernakulam - 682 036
Ph No. 0484-2318223, 2318222, e-mail: info@ddrcsrl.com, web: www.ddrcsrl.com

Regd. Office: 4th Floor, Prime Square, Plot No.1, Gaiwadi Industrial Estate, S.V. Road, Goregaon (West), Mumbai – 400062.

 भारत सरकार
Government of India


 Smitha Raj

DOB: 01/01/1976
FEMALE






9109 7961 3601

मेरा आधार, मेरी पहचान

 भारतीय विशिष्ट पहचान प्राधिकरण
Unique Identification Authority of India

Address:
W/O Shine E M, EDAPARAMPIL,
314, Eramalloor, Ernakulam,
Kerala - 686691

9109 7961 3601

1947   help@uidai.gov.in  www.uidai.gov.in



Smitha

I have not done the below mentioned tests during health checkup at DDRC Panampillynagar on 25/3/2023.

- 1 - T&M T
- 2 - Pap smear
- 3 - Motion Test

Smitha Raj

Smitha





Patient Ref. No. 666000003871940

CLIENT CODE : CA00010147 - MEDIWHEEL
 CLIENT'S NAME AND ADDRESS:

MEDIWHEEL ARCOFEMI HEALTHCARE LIMITED
 F701A, LADO SARAI, NEW DELHI,
 SOUTH DELHI, DELHI,
 SOUTH DELHI 110030
 DELHI INDIA
 8800465156

DDRC SRL DIAGNOSTICS
 DDRC SRL Tower, G-131, Panampilly Nagar,
 PANAMPALLY NAGAR, 682036
 KERALA, INDIA
 Tel : 93334 93334
 Email : customercare.ddrc@srl.in

PATIENT NAME : MRS. SMITHA RAJ

PATIENT ID : SMITF2503774126

ACCESSION NO : 4126WC008889 AGE : 46 Years SEX : Female

ABHA NO :

DRAWN :

RECEIVED : 25/03/2023 09:15

REPORTED : 27/03/2023 08:57

REFERRING DOCTOR : DR. MEDIWHEEL ARCOFEMI HEALTHCARE LIMITED

CLIENT PATIENT ID :

Test Report Status	Results	Biological Reference Interval	Units
Preliminary			

MEDIWHEEL HEALTH CHECKUP ABOVE 40(F)TMT**TREADMILL TEST**

TREADMILL TEST

TEST NOT DONE


OPHAL

OPHAL

TEST COMPLETED



Scan to View Details



Scan to View Report



Patient Ref. No. 666000003871940

 CLIENT CODE : CA00010147 - MEDIWHEEL
 CLIENT'S NAME AND ADDRESS:

 MEDIWHEEL ARCOFEMI HEALTHCARE LIMITED
 F701A, LADO SARAI, NEW DELHI,
 SOUTH DELHI, DELHI,
 SOUTH DELHI 110030
 DELHI INDIA
 8800465156

 DDRC SRL DIAGNOSTICS
 DDRC SRL Tower, G-131, Panampilly Nagar,
 PANAMPALLY NAGAR, 682036
 KERALA, INDIA
 Tel : 93334 93334
 Email : customercare.ddrc@srl.in

PATIENT NAME : MRS. SMITHA RAJ

PATIENT ID : SMITF2503774126

ACCESSION NO : 4126WC008889 AGE : 46 Years SEX : Female

ABHA NO :

DRAWN :

RECEIVED : 25/03/2023 09:15

REPORTED : 27/03/2023 08:57

REFERRING DOCTOR : DR. MEDIWHEEL ARCOFEMI HEALTHCARE LIMITED

CLIENT PATIENT ID :

Test Report Status	Preliminary	Results	Units
--------------------	-------------	---------	-------

MEDIWHEEL HEALTH CHECKUP ABOVE 40(F)TMT**BLOOD UREA NITROGEN (BUN), SERUM**

BLOOD UREA NITROGEN	7	Adult(<60 yrs) : 6 to 20	mg/dL
---------------------	---	--------------------------	-------

METHOD : UREASE - UV

BUN/CREAT RATIO

BUN/CREAT RATIO	10.14		
-----------------	-------	--	--

CREATININE, SERUM

CREATININE	0.69	18 - 60 yrs : 0.6 - 1.1	mg/dL
------------	------	-------------------------	-------

METHOD : JAFFE KINETIC METHOD

GLUCOSE, POST-PRANDIAL, PLASMA

GLUCOSE, POST-PRANDIAL, PLASMA	182	High Diabetes Mellitus : > or = 200. Impaired Glucose tolerance/ Prediabetes : 140 - 199. Hypoglycemia : < 55.	mg/dL
--------------------------------	-----	---	-------

METHOD : HEXOKINASE

LIPID PROFILE, SERUM

CHOLESTEROL	235	Desirable : < 200 Borderline : 200-239 High : >or= 240	mg/dL
-------------	-----	--	-------

METHOD : CHOD-POD

TRIGLYCERIDES	162	High Normal : < 150 High : 150-199 Hypertriglyceridemia : 200-499 Very High : > 499 General range : 40-60	mg/dL
---------------	-----	---	-------

HDL CHOLESTEROL

HDL CHOLESTEROL	41		mg/dL
-----------------	----	--	-------

METHOD : DIRECT ENZYME CLEARANCE

DIRECT LDL CHOLESTEROL	174	High Optimum : < 100 Above Optimum : 100-139 Borderline High : 130-159 High : 160-189 Very High : >or= 190	mg/dL
------------------------	-----	--	-------

NON HDL CHOLESTEROL	194	High Desirable: Less than 130 Above Desirable: 130 - 159 Borderline High: 160 - 189 High: 190 - 219 Very high: > or = 220	mg/dL
---------------------	-----	---	-------

VERY LOW DENSITY LIPOPROTEIN	32.4	Desirable value : 10 - 35	mg/dL
------------------------------	------	------------------------------	-------



Scan to View Details

Page 2 Of 8



Scan to View Report



Patient Ref. No. 666000003871940

 CLIENT CODE : CA00010147 - MEDIWHEEL
 CLIENT'S NAME AND ADDRESS:

 MEDIWHEEL ARCOFEMI HEALTHCARE LIMITED
 F701A, LADO SARAI, NEW DELHI,
 SOUTH DELHI, DELHI,
 SOUTH DELHI 110030
 DELHI INDIA
 8800465156

 DDRC SRL DIAGNOSTICS
 DDRC SRL Tower, G-131, Panampilly Nagar,
 PANAMPALLY NAGAR, 682036
 KERALA, INDIA
 Tel : 93334 93334
 Email : customercare.ddrc@srl.in

PATIENT NAME : MRS. SMITHA RAJ

PATIENT ID : SMITF2503774126

ACCESSION NO : 4126WC008889 AGE : 46 Years SEX : Female

ABHA NO :

DRAWN :

RECEIVED : 25/03/2023 09:15

REPORTED : 27/03/2023 08:57

REFERRING DOCTOR : DR. MEDIWHEEL ARCOFEMI HEALTHCARE LIMITED

CLIENT PATIENT ID :

Test Report Status	Preliminary	Results	Units
CHOL/HDL RATIO		5.7	High 3.3-4.4 Low Risk 4.5-7.0 Average Risk 7.1-11.0 Moderate Risk > 11.0 High Risk
LDL/HDL RATIO		4.2	High 0.5 - 3.0 Desirable/Low Risk 3.1 - 6.0 Borderline/Moderate Risk >6.0 High Risk
GLYCOSYLATED HEMOGLOBIN(HBA1C), EDTA WHOLE BLOOD			
GLYCOSYLATED HEMOGLOBIN (HBA1C)		6.2	Normal : 4.0 - 5.6%. % Non-diabetic level : < 5.7%. Diabetic : >6.5% Glycemic control goal More stringent goal : < 6.5 %. General goal : < 7%. Less stringent goal : < 8%. Glycemic targets in CKD :- If eGFR > 60 : < 7%. If eGFR < 60 : 7 - 8.5%.
MEAN PLASMA GLUCOSE		131.2	High < 116.0 mg/dL
LIVER FUNCTION TEST WITH GGT			
BILIRUBIN, TOTAL		0.67	General Range : < 1.1 mg/dL
METHOD : DIAZO METHOD			
BILIRUBIN, DIRECT		0.23	General Range : < 0.3 mg/dL
METHOD : DIAZO METHOD			
BILIRUBIN, INDIRECT		0.44	0.00 - 0.60 mg/dL
TOTAL PROTEIN		7.9	Ambulatory : 6.4 - 8.3 g/dL Recumbant : 6 - 7.8
ALBUMIN		4.8	20-60yrs : 3.5 - 5.2 g/dL
GLOBULIN		3.1	2.0 - 4.0 g/dL Neonates - Pre Mature: 0.29 - 1.04
ALBUMIN/GLOBULIN RATIO		1.5	1.00 - 2.00 RATIO
ASPARTATE AMINOTRANSFERASE (AST/SGOT)		54	Adults : < 33 U/L
ALANINE AMINOTRANSFERASE (ALT/SGPT)		96	Adults : < 34 U/L
METHOD : IFCC WITHOUT PDP			
ALKALINE PHOSPHATASE		69	Adult (<60yrs) : 35 - 105 U/L



Scan to View Details



Scan to View Report



Patient Ref. No. 66600003871940

CLIENT CODE : CA00010147 - MEDIWHEEL
CLIENT'S NAME AND ADDRESS :

 MEDIWHEEL ARCOFEMI HEALTHCARE LIMITED
 F701A, LADO SARAI, NEW DELHI,
 SOUTH DELHI, DELHI,
 SOUTH DELHI 110030
 DELHI INDIA
 8800465156

 DDRC SRL DIAGNOSTICS
 DDRC SRL Tower, G-131, Panampilly Nagar,
 PANAMPALLY NAGAR, 682036
 KERALA, INDIA
 Tel : 93334 93334
 Email : customercare.ddrc@srl.in
PATIENT NAME : MRS. SMITHA RAJ**PATIENT ID :** SMITF2503774126

ACCESSION NO : 4126WC008889 AGE : 46 Years SEX : Female

ABHA NO :

DRAWN :

RECEIVED : 25/03/2023 09:15

REPORTED : 27/03/2023 08:57

REFERRING DOCTOR : DR. MEDIWHEEL ARCOFEMI HEALTHCARE LIMITED

CLIENT PATIENT ID :

Test Report Status	Preliminary	Results	Units
METHOD : IFCC			
GAMMA GLUTAMYL TRANSFERASE (GGT)	36	Adult (female) : < 40	U/L
TOTAL PROTEIN, SERUM			
TOTAL PROTEIN	7.9	Ambulatory : 6.4 - 8.3 Recumbant : 6 - 7.8	g/dL
METHOD : BIURET			
URIC ACID, SERUM			
URIC ACID	5.3	Adults : 2.4-5.7	mg/dL
METHOD : SPECTROPHOTOMETRY			
ABO GROUP & RH TYPE, EDTA WHOLE BLOOD			
ABO GROUP	TYPE O		
METHOD : GEL CARD METHOD			
RH TYPE	POSITIVE		
BLOOD COUNTS, EDTA WHOLE BLOOD			
HEMOGLOBIN	12.5	12.0 - 15.0	g/dL
METHOD : NON CYANMETHEMOGLOBIN			
RED BLOOD CELL COUNT	4.10	3.8 - 4.8	mil/ μ L
METHOD : IMPEDANCE			
WHITE BLOOD CELL COUNT	7.66	4.0 - 10.0	thou/ μ L
METHOD : IMPEDANCE			
PLATELET COUNT	244	150 - 410	thou/ μ L
METHOD : IMPEDANCE			
RBC AND PLATELET INDICES			
HEMATOCRIT	37.4	36 - 46	%
METHOD : CALCULATED			
MEAN CORPUSCULAR VOL	91.4	83 - 101	fL
METHOD : DERIVED FROM IMPEDANCE MEASURE			
MEAN CORPUSCULAR HGB.	30.6	27.0 - 32.0	pg
METHOD : CALCULATED			
MEAN CORPUSCULAR HEMOGLOBIN CONCENTRATION	33.5	31.5 - 34.5	g/dL
METHOD : CALCULATED			
RED CELL DISTRIBUTION WIDTH	14.3	12.0 - 18.0	%
MENTZER INDEX	22.3		
MEAN PLATELET VOLUME	8.5	6.8 - 10.9	fL
METHOD : DERIVED FROM IMPEDANCE MEASURE			
WBC DIFFERENTIAL COUNT			



Scan to View Details



Scan to View Report



Patient Ref. No. 666000003871940

 CLIENT CODE : CA00010147 - MEDIWHEEL
 CLIENT'S NAME AND ADDRESS:

 MEDIWHEEL ARCOFEMI HEALTHCARE LIMITED
 F701A, LADO SARAI, NEW DELHI,
 SOUTH DELHI, DELHI,
 SOUTH DELHI 110030
 DELHI INDIA
 8800465156

 DDRC SRL DIAGNOSTICS
 DDRC SRL Tower, G-131, Panampilly Nagar,
 PANAMPALLY NAGAR, 682036
 KERALA, INDIA
 Tel : 93334 93334
 Email : customercare.ddrc@srl.in

PATIENT NAME : MRS. SMITHA RAJ

PATIENT ID : SMITF2503774126

ACCESSION NO : 4126WC008889 AGE : 46 Years SEX : Female

ABHA NO :

DRAWN :

RECEIVED : 25/03/2023 09:15

REPORTED : 27/03/2023 08:57


REFERRING DOCTOR : DR. MEDIWHEEL ARCOFEMI HEALTHCARE LIMITED

CLIENT PATIENT ID :

Test Report Status	Preliminary	Results	Units
SEGMENTED NEUTROPHILS		57	40 - 80 %
METHOD : DHSS FLOWCYTOMETRY			
LYMPHOCYTES		34	20 - 40 %
METHOD : DHSS FLOWCYTOMETRY			
MONOCYTES		7	2 - 10 %
METHOD : DHSS FLOWCYTOMETRY			
EOSINOPHILS		2	1 - 6 %
METHOD : DHSS FLOWCYTOMETRY			
BASOPHILS		0	0 - 2 %
METHOD : IMPEDANCE			
ABSOLUTE NEUTROPHIL COUNT		4.37	2.0 - 7.0 thou/ μ L
METHOD : CALCULATED			
ABSOLUTE LYMPHOCYTE COUNT		2.60	1 - 3 thou/ μ L
METHOD : CALCULATED			
ABSOLUTE MONOCYTE COUNT		0.54	0.20 - 1.00 thou/ μ L
METHOD : CALCULATED			
ABSOLUTE EOSINOPHIL COUNT		0.15	0.02 - 0.50 thou/ μ L
METHOD : CALCULATED			
ABSOLUTE BASOPHIL COUNT		0.00	0.00 - 0.10 thou/ μ L
NEUTROPHIL LYMPHOCYTE RATIO (NLR)		1.7	
ERYTHROCYTE SEDIMENTATION RATE (ESR), WHOLE BLOOD			
SEDIMENTATION RATE (ESR)		26	High 0 - 20 mm at 1 hr
METHOD : WESTERGREN METHOD			
SUGAR URINE - POST PRANDIAL			
SUGAR URINE - POST PRANDIAL		NOT DETECTED	NOT DETECTED
CYTOLOGY - CS (PAP SMEAR)		RESULT PENDING	
THYROID PANEL, SERUM			
T3		136.80	Non-Pregnant Women 80.0 - 200.0 Pregnant Women 1st Trimester:105.0 - 230.0 2nd Trimester:129.0 - 262.0 3rd Trimester:135.0 - 262.0 ng/dL



Scan to View Details



Scan to View Report

CIN : U85190MH2006PTC161480

(Refer to "CONDITIONS OF REPORTING" Overleaf)



Patient Ref. No. 666000003871940

CLIENT CODE : CA00010147 - MEDIWHEEL
CLIENT'S NAME AND ADDRESS:

MEDIWHEEL ARCOFEMI HEALTHCARE LIMITED
F701A, LADO SARAI, NEW DELHI,
SOUTH DELHI, DELHI,
SOUTH DELHI 110030
DELHI INDIA
8800465156

DDRC SRL DIAGNOSTICS
DDRC SRL Tower, G-131, Panampilly Nagar,
PANAMPALLY NAGAR, 682036
KERALA, INDIA
Tel : 93334 93334
Email : customercare.ddrc@srl.in

PATIENT NAME : MRS. SMITHA RAJ

PATIENT ID : SMITF2503774126

ACCESSION NO : 4126WC008889 AGE : 46 Years SEX : Female

ABHA NO :

DRAWN :

RECEIVED : 25/03/2023 09:15

REPORTED : 27/03/2023 08:57

REFERRING DOCTOR : DR. MEDIWHEEL ARCOFEMI HEALTHCARE LIMITED

CLIENT PATIENT ID :

Test Report Status	Preliminary	Results	Units
T4		8.36	Non-Pregnant Women 5.10 - 14.10 Pregnant Women 1st Trimester: 7.33 - 14.80 2nd Trimester: 7.93 - 16.10 3rd Trimester: 6.95 - 15.70 µg/dl
TSH 3RD GENERATION		3.550	Non-Pregnant : 0.4-4.2 Pregnant Trimester-wise : 1st : 0.1 - 2.5 2nd : 0.2 - 3 3rd : 0.3 - 3 µIU/mL
SUGAR URINE - FASTING			
SUGAR URINE - FASTING		NOT DETECTED	NOT DETECTED
PHYSICAL EXAMINATION, URINE			
COLOR		PALE YELLOW	
APPEARANCE		CLEAR	
CHEMICAL EXAMINATION, URINE			
PH		6.5	4.8 - 7.4
SPECIFIC GRAVITY		1.015	1.015 - 1.030
PROTEIN		NOT DETECTED	NOT DETECTED
GLUCOSE		NOT DETECTED	NOT DETECTED
KETONES		NOT DETECTED	NOT DETECTED
BLOOD		NOT DETECTED	NOT DETECTED
BILIRUBIN		NOT DETECTED	NOT DETECTED
UROBILINOGEN		NORMAL	NORMAL
NITRITE		NOT DETECTED	NOT DETECTED
LEUKOCYTE ESTERASE		NOT DETECTED	NOT DETECTED
MICROSCOPIC EXAMINATION, URINE			
RED BLOOD CELLS		NOT DETECTED	NOT DETECTED /HPF
WBC		1-2	0-5 /HPF
EPITHELIAL CELLS		0-1	0-5 /HPF
CASTS		NOT DETECTED	
CRYSTALS		NOT DETECTED	
BACTERIA		NOT DETECTED	NOT DETECTED
YEAST		NOT DETECTED	NOT DETECTED
GLUCOSE FASTING, FLUORIDE PLASMA			



Scan to View Details



Scan to View Report



Patient Ref. No. 66600003871940

CLIENT CODE : CA00010147 - MEDIWHEEL
CLIENT'S NAME AND ADDRESS :

MEDIWHEEL ARCOFEMI HEALTHCARE LIMITED
F701A, LADO SARAI, NEW DELHI,
SOUTH DELHI, DELHI,
SOUTH DELHI 110030
DELHI INDIA
8800465156

DDRC SRL DIAGNOSTICS
DDRC SRL Tower, G-131, Panampilly Nagar,
PANAMPALLY NAGAR, 682036
KERALA, INDIA
Tel : 93334 93334
Email : customercare.ddrc@srl.in

PATIENT NAME : MRS. SMITHA RAJ

PATIENT ID : SMITF2503774126

ACCESSION NO : 4126WC008889 AGE : 46 Years SEX : Female

ABHA NO :

DRAWN :

RECEIVED : 25/03/2023 09:15

REPORTED : 27/03/2023 08:57

REFERRING DOCTOR : DR. MEDIWHEEL ARCOFEMI HEALTHCARE LIMITED

CLIENT PATIENT ID :

Test Report Status	Results	Units
--------------------	---------	-------

GLUCOSE, FASTING, PLASMA

109


Diabetes Mellitus : > or = 126. mg/dL
Impaired fasting Glucose/
Prediabetes : 101 - 125.
Hypoglycemia : < 55.



DDRC SRL
Diagnostic Services



Scan to View Details



Scan to View Report



Patient Ref. No. 666000003871940

CLIENT CODE : CA00010147 - MEDIWHEEL
 CLIENT'S NAME AND ADDRESS :

MEDIWHEEL ARCOFEMI HEALTHCARE LIMITED
 F701A, LADO SARAI, NEW DELHI,
 SOUTH DELHI, DELHI,
 SOUTH DELHI 110030
 DELHI INDIA
 8800465156

DDRC SRL DIAGNOSTICS
 DDRC SRL Tower, G-131, Panampilly Nagar,
 PANAMPALLY NAGAR, 682036
 KERALA, INDIA
 Tel : 93334 93334
 Email : customercare.ddrc@srl.in

PATIENT NAME : MRS. SMITHA RAJ

PATIENT ID : SMITF2503774126

ACCESSION NO : 4126WC008889 AGE : 46 Years SEX : Female

ABHA NO :

DRAWN :

RECEIVED : 25/03/2023 09:15

REPORTED : 27/03/2023 08:57

REFERRING DOCTOR : DR. MEDIWHEEL ARCOFEMI HEALTHCARE LIMITED

CLIENT PATIENT ID :

Test Report Status	Preliminary	Results	Units
--------------------	-------------	---------	-------

MEDIWHEEL HEALTH CHECKUP ABOVE 40(F)TMT**ECG WITH REPORT****REPORT**

TEST COMPLETED
MAMMOGRAPHY -BOTH

REPORT

TEST COMPLETED
USG ABDOMEN AND PELVIS

REPORT

TEST COMPLETED
CHEST X-RAY WITH REPORT

REPORT

TEST COMPLETED

****End Of Report****Please visit www.ddrcsrl.com for related Test Information for this accession

DR.HARI SHANKAR, MBBS MD
 (Reg No - TCMC:62092)
 HEAD - Biochemistry &
 Immunology

DR.VIJAY K N, MBBS MD(PATH)
 (Reg No - KMC:91816)
 HEAD-HAEMATOLOGY &
 CLINICAL PATHOLOGY

DR.SMITHA PAULSON, MD
 (PATH),DPB
 (Reg No - TCMC:35960)
 LAB DIRECTOR & HEAD-
 HISTOPATHOLOGY &
 CYTOLOGY



Scan to View Details



Scan to View Report

CIN : U85190MH2006PTC161480

(Refer to " CONDITIONS OF REPORTING " Overleaf)

Date...25.03.2023

OPHTHALMOLOGY REPORT

This is to certify that I have examined

Mr / Ms : Amisha Raj.....Aged...46.....and his / her

visual standards is as follows :

Visual Acuity:

For far vision

R:6/6.....

L:6/6.....

For near vision

R:N10.....

L:N10.....

? R N6
L N6

Color Vision :Normal.....

.....

Nannu Elizabeth

Nannu Elizabeth

(Optometrist)



This is to certify that I have examined

MR / MS SMITHA RASaged 46 and

his / her oral findings are as follows

D - Decay

M - Missing

F - Filling

			M											M	M
8	7	6	5	4	3	2	1	1	2	3	4	5	6	7	8
8	7	6	5	4	3	2	1	1	2	3	4	5	6	7	8
D	F													F	M

Oral hygiene status : Good / Fair / Poor

Calculus / Stains : Calculus^T

Any other findings : 6 / 6 Crown.
Adv. Scaling

Date : 25/3/23

Dr. K C Jose



Dr. Saini Arvind

For KALARICKAL DENTAL CARE

ID: 8889

25-03-2023 12:28:08 PM

CARDIART

SMITHA RAJ
Female 46Years

HR : 80 bpm
P : 106 ms
PR : 151 ms
QRS : 86 ms
QT/QTc : 379/437 ms
P/QRST : 63/75/48 °
RV5/SV1 : 1.788/0.818 mV

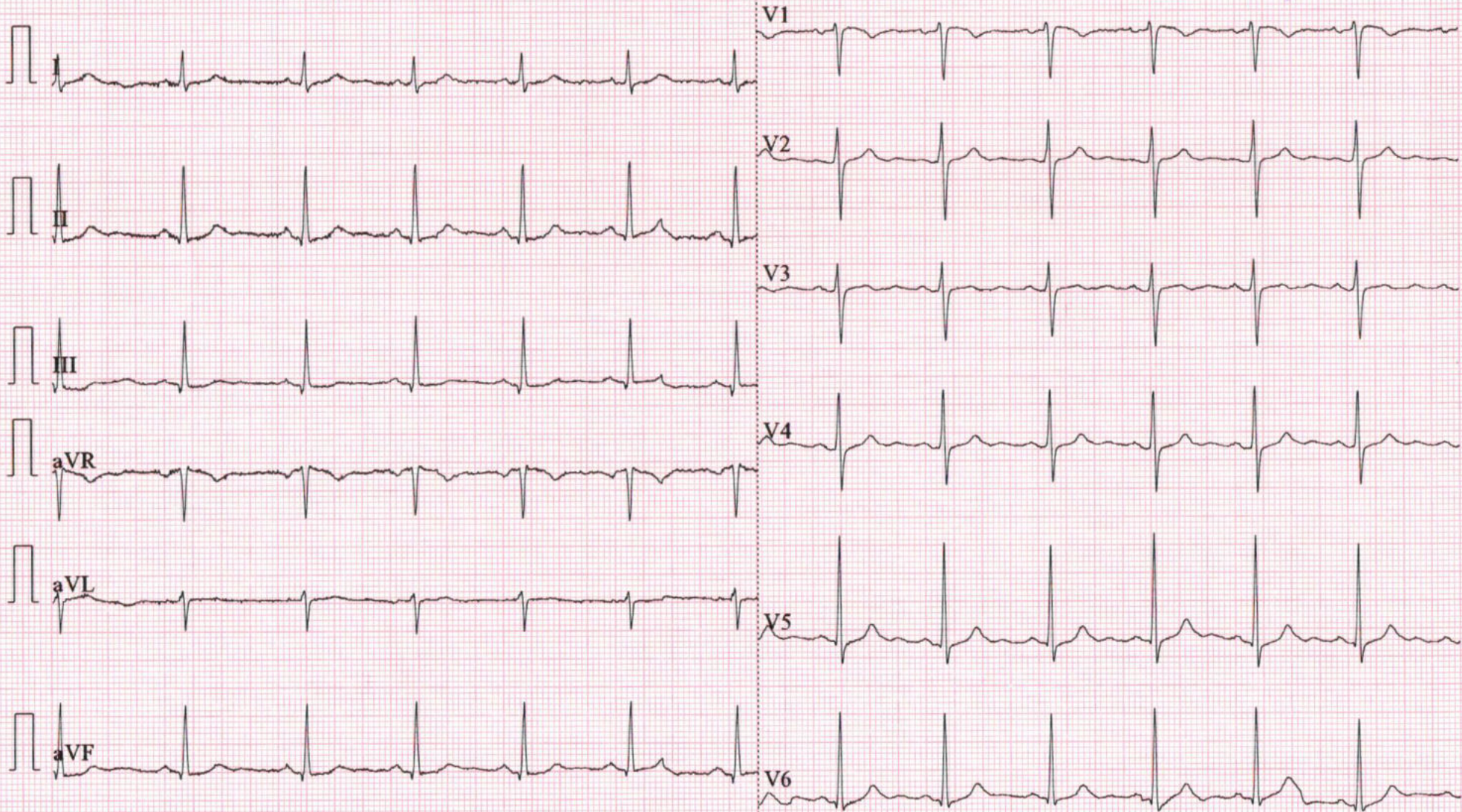
Diagnosis Information:

Within normal limits
Dr. George Thomas MD, FCSI, FIAE
Cardiologist



Technician : ALEENA
Ref-Phys. : MEDI WHEEL
Report Confirmed by:

Smitha




NAME: MRS SMITHA RAJ	STUDY DATE 25/03/2023
AGE / SEX : 46 YRS / F	REPORTING DATE 25/03/2023
REFERRED BY :MEDIWHEEL	ACC NO : 4126WC008889

X - RAY - CHEST PA VIEW

- Both the lung fields are clear.
- B/L hila and mediastinal shadows are normal.
- Cardiac silhouette appears normal.
- Cardio - thoracic ratio is normal.
- Bilateral CP angles and domes of diaphragm appear normal.

IMPRESSION: NORMAL STUDY

Kindly correlate clinically


Dr. NAVNEET KAUR, MBBS,MD
Consultant Radiologist.



NAME	MRS SMITHA RAJ	AGE	46 YRS
SEX	FEMALE	DATE	March 25, 2023
REFERRAL	MEDIWHEEL	ACC NO	4126WC008889

MAMMOGRAPHY**Technique:** Bilateral MLO and CC views**Clinical details:** Screening mammography.**Findings:**

- Both breasts show ACR type B composition.
- Prominent left axillary folds are seen. Post operative changes are noted in right axilla.
- Breast parenchymal architecture is preserved.
- No evidence of micro/macro calcifications seen in breast.
- The skin, nipple-areola complex and retro-areolar zone are normal.
- The retro-mammary clear zone and underlying pectoralis muscle appear normal

ULTRASOUND SCREENING:**RIGHT BREAST**


- Normal stromal echogenicity.
- No focal lesions seen in the present study.
- Nipple & areola normal.
- No evidence of axillary lymphadenopathy

LEFT BREAST

- Few tiny cysts are seen, largest measuring 2.7 x 1.5 mm at 10' clock location about 2cm away from the nipple.
- Nipple & areola normal.
- No evidence of axillary lymphadenopathy. Unencapsulated prominent left axillary fat is noted. No definite mass lesion seen.

IMPRESSION:

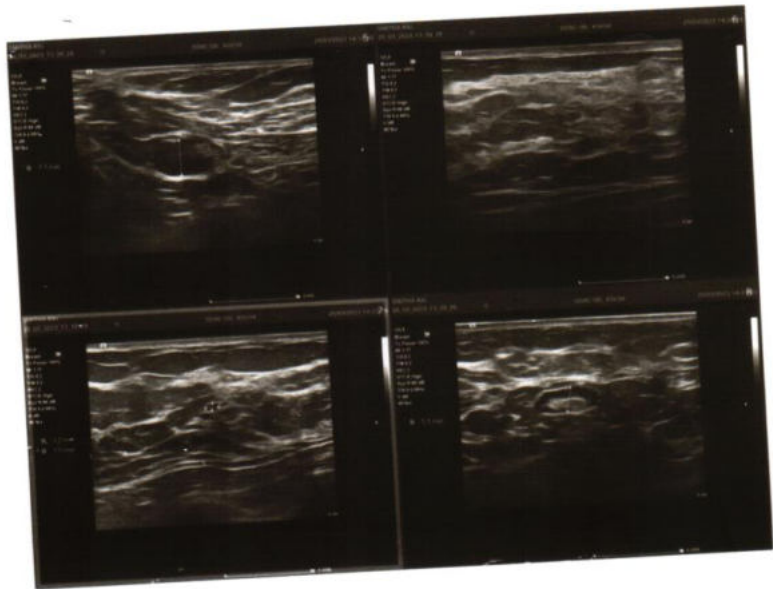
- ✦ *Left breast simple cysts (BIRADS II).*
- ✦ *Prominent left axillary fat pad.*


Dr. NAVNEET KAUR MBBS . MD
 Consultant Radiologist
ACR BIRADS Category

0	More information is needed to give a final mammogram report
I	Your mammogram is normal.
II	Your mammogram shows only minor abnormalities that are not suspicious for cancer. No additional testing is needed.
III	Your mammogram shows minor abnormalities that are probably benign. The radiologist may recommend follow-up testing to make sure the suspicious area has not changed.
IV	Your mammogram shows a suspicious change, and a biopsy should probably be performed.
V	Your mammogram shows a worrisome change. A biopsy is strongly recommended.
VI	Known biopsy – proven malignancy; Surgical excision when clinically appropriate.

For Emergency Call: 9496005127. Thanks for referral. Your feedback will be appreciated.
 (Please bring relevant investigation reports during all visits)





NAME	MRS SMITHA RAJ	AGE	46 YRS
SEX	FEMALE	DATE	March 25, 2023
REFERRAL	MEDIWHEEL	ACC NO	4126WC008889

USG ABDOMEN AND PELVIS

LIVER	Measures ~ 11.6 cm. Bright echotexture. Smooth margins and no obvious focal lesion within. No IHBR dilatation. Portal vein normal in caliber .
GB	Partially contracted.
SPLEEN	Measures ~ 8.3 cm, normal to visualized extent. Splenic vein normal.
PANCREAS	Normal to visualized extent. PD is not dilated.
KIDNEYS	RK: 9.2 x 3.7 cm, appears normal in size and echotexture. LK: 10.2 x 4.5 cm, shows 3.8 mm calculus in lower calyx. Maintained corticomedullary differentiation and normal parenchymal thickness. No hydroureteronephrosis.
BLADDER	Normal wall caliber, no internal echoes/calculus within.
UTERUS	Post hysterectomy status.
OVARIES	RT OV: 2.1 x 1.3 x 1.2 cm [volume ~ 1.9 cc]. LT OV: 2.4 x 1.2 x 1.7 cm [volume ~ 2.9 cc].
NODES/FLUID	Nil to visualized extent.
BOWEL	Visualized bowel loops appear normal.
IMPRESSION	<ul style="list-style-type: none"> ✚ <i>Grade I fatty liver.</i> ✚ <i>Left renal calculus.</i>

Kindly correlate clinically.


 Dr. NAVNEET KAUR MBBS . MD
 Consultant Radiologist

Thank you for referral. Your feedback will be appreciated.

NOTE: This report is only a professional opinion based on the real time image finding and not a diagnosis by itself. It has to be correlated and interpreted with clinical and other investigation findings. Review scan is advised, if this ultrasound opinion and other clinical findings / reports don't correlate.

