

Patient Name : Mr.GUL MOHD	Collected : 08/Jul/2023 09:47AM
Age/Gender : 37 Y 9 M 1 D/M	Received : 08/Jul/2023 01:17PM
UHID/MR No : CELE.0000117287	Reported : 08/Jul/2023 08:38PM
Visit ID : CELEOPV297315	Status : Final Report
Ref Doctor : Dr.SELF	Sponsor Name : ARCOFEMI HEALTHCARE LIMITED
Emp/Auth/TPA ID : EC171165	

DEPARTMENT OF HAEMATOLOGY

ARCOFEMI - MEDIWHEEL - FULL BODY ANNUAL CHECKUP MALE - 2D ECHO - PAN INDIA - FY2324

Test Name	Result	Unit	Bio. Ref. Range	Method
-----------	--------	------	-----------------	--------

HEMOGRAM , WHOLE BLOOD-EDTA

HAEMOGLOBIN	12.4	g/dL	13-17	Spectrophotometer
PCV	41.50	%	40-50	Electronic pulse & Calculation
RBC COUNT	5.95	Million/cu.mm	4.5-5.5	Electrical Impedence
MCV	70	fL	83-101	Calculated
MCH	20.8	pg	27-32	Calculated
MCHC	29.8	g/dL	31.5-34.5	Calculated
R.D.W	20.3	%	11.6-14	Calculated
TOTAL LEUCOCYTE COUNT (TLC)	7,300	cells/cu.mm	4000-10000	Electrical Impedence

DIFFERENTIAL LEUCOCYTIC COUNT (DLC)

NEUTROPHILS	46.9	%	40-80	Electrical Impedence
LYMPHOCYTES	42.3	%	20-40	Electrical Impedence
EOSINOPHILS	3.5	%	1-6	Electrical Impedence
MONOCYTES	7.2	%	2-10	Electrical Impedence
BASOPHILS	0.1	%	<1-2	Electrical Impedence

ABSOLUTE LEUCOCYTE COUNT

NEUTROPHILS	3423.7	Cells/cu.mm	2000-7000	Electrical Impedence
LYMPHOCYTES	3087.9	Cells/cu.mm	1000-3000	Electrical Impedence
EOSINOPHILS	255.5	Cells/cu.mm	20-500	Electrical Impedence
MONOCYTES	525.6	Cells/cu.mm	200-1000	Electrical Impedence
BASOPHILS	7.3	Cells/cu.mm	0-100	Electrical Impedence

PLATELET COUNT

PLATELET COUNT	160000	cells/cu.mm	150000-410000	Electrical impedence
----------------	--------	-------------	---------------	----------------------

ERYTHROCYTE SEDIMENTATION RATE (ESR)

ERYTHROCYTE SEDIMENTATION RATE (ESR)	27	mm at the end of 1 hour	0-15	Modified Westgren method
--------------------------------------	----	-------------------------	------	--------------------------

**PERIPHERAL SMEAR**

RBCs: Show erythrocytosis and mild anisocytosis with predominance of Microcytic hypochromic RBCs. Few poikilocytes like elliptocytes are seen. No nucleated RBCs or inclusions.

WBCs: are normal in total number with normal morphology and increase in lymphocytes.

PLATELETS: appear adequate in number.

HEMOPARASITES: negative

Patient Name : Mr.GUL MOHD	Collected : 08/Jul/2023 09:47AM
Age/Gender : 37 Y 9 M 1 D/M	Received : 08/Jul/2023 01:17PM
UHID/MR No : CELE.0000117287	Reported : 08/Jul/2023 08:38PM
Visit ID : CELEOPV297315	Status : Final Report
Ref Doctor : Dr.SELF	Sponsor Name : ARCOFEMI HEALTHCARE LIMITED
Emp/Auth/TPA ID : EC171165	

**DEPARTMENT OF HAEMATOLOGY**

**ARCOFEMI - MEDIWHEEL - FULL BODY ANNUAL CHECKUP MALE - 2D ECHO - PAN INDIA - FY2324**

Test Name	Result	Unit	Bio. Ref. Range	Method
-----------	--------	------	-----------------	--------

**IMPRESSION: MICROCYTIC HYPOCHROMIC ANAEMIA WITH ERYTHROCYTOSIS AND LYMPHOCYTOSIS**

**Note: Kindly evaluate for incipient iron deficiency status/hemoglobinopathy.**



Patient Name : Mr.GUL MOHD	Collected : 08/Jul/2023 09:47AM
Age/Gender : 37 Y 9 M 1 D/M	Received : 08/Jul/2023 01:17PM
UHID/MR No : CELE.0000117287	Reported : 08/Jul/2023 04:27PM
Visit ID : CELEOPV297315	Status : Final Report
Ref Doctor : Dr.SELF	Sponsor Name : ARCOFEMI HEALTHCARE LIMITED
Emp/Auth/TPA ID : EC171165	

**DEPARTMENT OF HAEMATOLOGY**

**ARCOFEMI - MEDIWHEEL - FULL BODY ANNUAL CHECKUP MALE - 2D ECHO - PAN INDIA - FY2324**

Test Name	Result	Unit	Bio. Ref. Range	Method
-----------	--------	------	-----------------	--------

**BLOOD GROUP ABO AND RH FACTOR , WHOLE BLOOD-EDTA**

BLOOD GROUP TYPE	O			Microplate Hemagglutination
Rh TYPE	Positive			Microplate Hemagglutination



SIN No:BED230157929

Patient Name : Mr.GUL MOHD	Collected : 08/Jul/2023 01:22PM
Age/Gender : 37 Y 9 M 1 D/M	Received : 08/Jul/2023 10:24PM
UHID/MR No : CELE.0000117287	Reported : 08/Jul/2023 10:54PM
Visit ID : CELEOPV297315	Status : Final Report
Ref Doctor : Dr.SELF	Sponsor Name : ARCOFEMI HEALTHCARE LIMITED
Emp/Auth/TPA ID : EC171165	

DEPARTMENT OF BIOCHEMISTRY

ARCOFEMI - MEDIWHEEL - FULL BODY ANNUAL CHECKUP MALE - 2D ECHO - PAN INDIA - FY2324

Test Name	Result	Unit	Bio. Ref. Range	Method
-----------	--------	------	-----------------	--------

GLUCOSE, FASTING , NAF PLASMA	88	mg/dL	70-100	HEXOKINASE
-------------------------------	----	-------	--------	------------

**Comment:**

As per American Diabetes Guidelines

Fasting Glucose Values in mg/d L	Interpretation
<100 mg/dL	Normal
100-125 mg/dL	Prediabetes
≥126 mg/dL	Diabetes

GLUCOSE, POST PRANDIAL (PP), 2 HOURS , NAF PLASMA	93	mg/dL	70-140	HEXOKINASE
---	----	-------	--------	------------

**Comment:**

It is recommended that FBS and PPBS should be interpreted with respect to their Biological reference ranges and not with each other.

Conditions which may lead to lower postprandial glucose levels as compared to fasting glucose levels may be due to reactive hypoglycemia, dietary meal content, duration or timing of sampling after food digestion and absorption, medications such as insulin preparations, sulfonylureas, amylin analogues, or conditions such as overproduction of insulin.

Ref: Marks medical biochemistry and clinical approach



Patient Name : Mr.GUL MOHD	Collected : 08/Jul/2023 09:48AM
Age/Gender : 37 Y 9 M 1 D/M	Received : 08/Jul/2023 01:36PM
UHID/MR No : CELE.0000117287	Reported : 08/Jul/2023 04:19PM
Visit ID : CELEOPV297315	Status : Final Report
Ref Doctor : Dr.SELF	Sponsor Name : ARCOFEMI HEALTHCARE LIMITED
Emp/Auth/TPA ID : EC171165	

DEPARTMENT OF BIOCHEMISTRY

ARCOFEMI - MEDIWHEEL - FULL BODY ANNUAL CHECKUP MALE - 2D ECHO - PAN INDIA - FY2324

Test Name	Result	Unit	Bio. Ref. Range	Method
-----------	--------	------	-----------------	--------

LIPID PROFILE , SERUM

TOTAL CHOLESTEROL	149	mg/dL	<200	CHO-POD
TRIGLYCERIDES	<b>223</b>	mg/dL	<150	GPO-POD
HDL CHOLESTEROL	<b>27</b>	mg/dL	40-60	Enzymatic Immunoinhibition
NON-HDL CHOLESTEROL	122	mg/dL	<130	Calculated
LDL CHOLESTEROL	77.2	mg/dL	<100	Calculated
VLDL CHOLESTEROL	<b>44.6</b>	mg/dL	<30	Calculated
CHOL / HDL RATIO	<b>5.51</b>		0-4.97	Calculated

Comment:

Reference Interval as per National Cholesterol Education Program (NCEP) Adult Treatment Panel III Report.

	Desirable	Borderline High	High	Very High
TOTAL CHOLESTEROL	< 200	200 - 239	≥ 240	
TRIGLYCERIDES	<150	150 - 199	200 - 499	≥ 500
LDL	Optimal < 100 Near Optimal 100-129	130 - 159	160 - 189	≥ 190
HDL	≥ 60			
NON-HDL CHOLESTEROL	Optimal <130; Above Optimal 130-159	160-189	190-219	>220

Measurements in the same patient can show physiological and analytical variations.

NCEP ATP III identifies non-HDL cholesterol as a secondary target of therapy in persons with high triglycerides.



Patient Name : Mr.GUL MOHD	Collected : 08/Jul/2023 09:48AM
Age/Gender : 37 Y 9 M 1 D/M	Received : 08/Jul/2023 01:36PM
UHID/MR No : CELE.0000117287	Reported : 08/Jul/2023 04:19PM
Visit ID : CELEOPV297315	Status : Final Report
Ref Doctor : Dr.SELF	Sponsor Name : ARCOFEMI HEALTHCARE LIMITED
Emp/Auth/TPA ID : EC171165	

**DEPARTMENT OF BIOCHEMISTRY**

**ARCOFEMI - MEDIWHEEL - FULL BODY ANNUAL CHECKUP MALE - 2D ECHO - PAN INDIA - FY2324**

Test Name	Result	Unit	Bio. Ref. Range	Method
-----------	--------	------	-----------------	--------

LIVER FUNCTION TEST (LFT) , SERUM				
BILIRUBIN, TOTAL	1.65	mg/dL	0.3-1.2	DPD
BILIRUBIN CONJUGATED (DIRECT)	0.21	mg/dL	<0.2	DPD
BILIRUBIN (INDIRECT)	1.44	mg/dL	0.0-1.1	Dual Wavelength
ALANINE AMINOTRANSFERASE (ALT/SGPT)	29	U/L	<50	IFCC
ASPARTATE AMINOTRANSFERASE (AST/SGOT)	32.0	U/L	<50	IFCC
ALKALINE PHOSPHATASE	101.00	U/L	30-120	IFCC
PROTEIN, TOTAL	7.60	g/dL	6.6-8.3	Biuret
ALBUMIN	4.53	g/dL	3.5-5.2	BROMO CRESOL GREEN
GLOBULIN	3.07	g/dL	2.0-3.5	Calculated
A/G RATIO	1.48		0.9-2.0	Calculated



Patient Name : Mr.GUL MOHD	Collected : 08/Jul/2023 09:48AM
Age/Gender : 37 Y 9 M 1 D/M	Received : 08/Jul/2023 01:36PM
UHID/MR No : CELE.0000117287	Reported : 08/Jul/2023 04:19PM
Visit ID : CELEOPV297315	Status : Final Report
Ref Doctor : Dr.SELF	Sponsor Name : ARCOFEMI HEALTHCARE LIMITED
Emp/Auth/TPA ID : EC171165	

**DEPARTMENT OF BIOCHEMISTRY**

**ARCOFEMI - MEDIWHEEL - FULL BODY ANNUAL CHECKUP MALE - 2D ECHO - PAN INDIA - FY2324**

Test Name	Result	Unit	Bio. Ref. Range	Method
-----------	--------	------	-----------------	--------

**RENAL PROFILE/KIDNEY FUNCTION TEST (RFT/KFT) , SERUM**

CREATININE	0.87	mg/dL	0.72 – 1.18	JAFFE METHOD
UREA	27.40	mg/dL	17-43	GLDH, Kinetic Assay
BLOOD UREA NITROGEN	12.8	mg/dL	8.0 - 23.0	Calculated
URIC ACID	6.60	mg/dL	3.5–7.2	Uricase PAP
CALCIUM	9.20	mg/dL	8.8-10.6	Arsenazo III
PHOSPHORUS, INORGANIC	2.89	mg/dL	2.5-4.5	Phosphomolybdate Complex
SODIUM	<b>135</b>	mmol/L	136–146	ISE (Indirect)
POTASSIUM	4.5	mmol/L	3.5–5.1	ISE (Indirect)
CHLORIDE	104	mmol/L	101–109	ISE (Indirect)



Patient Name : Mr.GUL MOHD	Collected : 08/Jul/2023 09:48AM
Age/Gender : 37 Y 9 M 1 D/M	Received : 08/Jul/2023 01:36PM
UHID/MR No : CELE.0000117287	Reported : 08/Jul/2023 04:19PM
Visit ID : CELEOPV297315	Status : Final Report
Ref Doctor : Dr.SELF	Sponsor Name : ARCOFEMI HEALTHCARE LIMITED
Emp/Auth/TPA ID : EC171165	

**DEPARTMENT OF BIOCHEMISTRY**

**ARCOFEMI - MEDIWHEEL - FULL BODY ANNUAL CHECKUP MALE - 2D ECHO - PAN INDIA - FY2324**

Test Name	Result	Unit	Bio. Ref. Range	Method
<b>GAMMA GLUTAMYL TRANSPEPTIDASE (GGT) , SERUM</b>	28.00	U/L	<55	IFCC





Patient Name : Mr.GUL MOHD	Collected : 08/Jul/2023 09:48AM
Age/Gender : 37 Y 9 M 1 D/M	Received : 08/Jul/2023 09:39PM
UHID/MR No : CELE.0000117287	Reported : 08/Jul/2023 09:51PM
Visit ID : CELEOPV297315	Status : Final Report
Ref Doctor : Dr.SELF	Sponsor Name : ARCOFEMI HEALTHCARE LIMITED
Emp/Auth/TPA ID : EC171165	

DEPARTMENT OF CLINICAL PATHOLOGY

ARCOFEMI - MEDIWHEEL - FULL BODY ANNUAL CHECKUP MALE - 2D ECHO - PAN INDIA - FY2324

Test Name	Result	Unit	Bio. Ref. Range	Method
-----------	--------	------	-----------------	--------

COMPLETE URINE EXAMINATION (CUE) , URINE

PHYSICAL EXAMINATION				
COLOUR	PALE YELLOW		PALE YELLOW	Visual
TRANSPARENCY	CLEAR		CLEAR	Visual
pH	5.5		5-7.5	DOUBLE INDICATOR
SP. GRAVITY	1.025		1.002-1.030	Bromothymol Blue
BIOCHEMICAL EXAMINATION				
URINE PROTEIN	NEGATIVE		NEGATIVE	PROTEIN ERROR OF INDICATOR
GLUCOSE	NEGATIVE		NEGATIVE	GLUCOSE OXIDASE
URINE BILIRUBIN	NEGATIVE		NEGATIVE	AZO COUPLING REACTION
URINE KETONES (RANDOM)	NEGATIVE		NEGATIVE	SODIUM NITRO PRUSSIDE
UROBILINOGEN	NORMAL		NORMAL	MODIFIED EHRlich REACTION
BLOOD	NEGATIVE		NEGATIVE	Peroxidase
NITRITE	NEGATIVE		NEGATIVE	Diazotization
LEUCOCYTE ESTERASE	NEGATIVE		NEGATIVE	LEUCOCYTE ESTERASE
CENTRIFUGED SEDIMENT WET MOUNT AND MICROSCOPY				
PUS CELLS	2-3	/hpf	0-5	Microscopy
EPITHELIAL CELLS	1-2	/hpf	<10	MICROSCOPY
RBC	NIL	/hpf	0-2	MICROSCOPY
CASTS	NIL		0-2 Hyaline Cast	MICROSCOPY
CRYSTALS	ABSENT		ABSENT	MICROSCOPY



Patient Name : Mr.GUL MOHD	Collected : 08/Jul/2023 09:48AM
Age/Gender : 37 Y 9 M 1 D/M	Received : 08/Jul/2023 06:39PM
UHID/MR No : CELE.0000117287	Reported : 08/Jul/2023 07:02PM
Visit ID : CELEOPV297315	Status : Final Report
Ref Doctor : Dr.SELF	Sponsor Name : ARCOFEMI HEALTHCARE LIMITED
Emp/Auth/TPA ID : EC171165	


**DEPARTMENT OF CLINICAL PATHOLOGY**

**ARCOFEMI - MEDIWHEEL - FULL BODY ANNUAL CHECKUP MALE - 2D ECHO - PAN INDIA - FY2324**


Test Name	Result	Unit	Bio. Ref. Range	Method
URINE GLUCOSE(POST PRANDIAL)	NEGATIVE		NEGATIVE	Dipstick
URINE GLUCOSE(FASTING)	NEGATIVE		NEGATIVE	Dipstick

\*\*\* End Of Report \*\*\*


Result/s to Follow:  
PERIPHERAL SMEAR




**Dr. Prasanna**  
M.B.B.S, M.D  
Consultant Pathologist



**Dr. Anita Shobha Flynn**  
M.B.B.S MD(Pathology)  
Consultant Pathologist



**DR. SHIV ARAJA SHETTY**  
M.B.B.S, M.D(Biochemistry)  
CONSULTANT BIOCHEMIST



**Dr. Anita Shobha Flynn**  
M.B.B.S MD(Pathology)  
Consultant Pathologist



Name : Mr. GUL MOHD

Age: 37 Y

UHID:CELE.0000117287



OP Number:CELEOPV297315

Bill No :CELE-OCR-48875

Date : 08.07.2023 09:40

Address : ECITY

Plan : ARCOFEMI MEDIWHEEL MALE AHC CREDIT PAN  
INDIA OP AGREEMENT

Sno	Service Type/ServiceName	Department
1	ARCOFEMI - MEDIWHEEL - FULL BODY ANNUAL CHECKUP MALE - 2D ECHO - PAN INDIA - FY2324	
<del>1</del>	URINE GLUCOSE(FASTING)	
<del>2</del>	GAMMA GLUTAMYL TRANSFERASE (GGT)	
<del>3</del>	2D ECHO	
<del>4</del>	LIVER FUNCTION TEST (LFT)	
<del>5</del>	X-RAY CHEST PA	
<del>6</del>	GLUCOSE, FASTING	
<del>7</del>	HEMOGRAM + PERIPHERAL SMEAR	
<del>8</del>	ENT CONSULTATION	
<del>9</del>	FITNESS BY GENERAL PHYSICIAN	
<del>10</del>	HFA SPEECH AUDIOMETRY	
<del>11</del>	DIET CONSULTATION	
<del>12</del>	COMPLETE URINE EXAMINATION	
<del>13</del>	URINE GLUCOSE(POST PRANDIAL)	
<del>14</del>	PERIPHERAL SMEAR	
<del>15</del>	ECG	
<del>16</del>	BLOOD GROUP ABO AND RH FACTOR	
<del>17</del>	LIPID PROFILE	
<del>18</del>	BODY MASS INDEX (BMI)	
<del>19</del>	OPHTHAL BY GENERAL PHYSICIAN	
<del>20</del>	RENAL PROFILE/RENAL FUNCTION TEST (RFT/KFT)	
<del>21</del>	ULTRASOUND - WHOLE ABDOMEN	
<del>22</del>	DENTAL CONSULTATION	
<del>23</del>	GLUCOSE, POST PRANDIAL (PP), 2 HOURS (POST MEAL)	

Physio-12

Dental-15/20

Ortho-05

DR. YASHASWI  
M.B.B.S., D.M.D., D.D.S.  
DENTIST  
MOS: DENTISTRY  
MOS: ORTHODONTICS

Patient Name : Mr. GUL MOHD  
UHID : CELE.0000117287  
Reported on : 09-07-2023 14:57  
Adm/Consult Doctor :

Age : 37 Y M  
OP Visit No : CELEOPV297315  
Printed on : 09-07-2023 14:58  
Ref Doctor : SELF

**DEPARTMENT OF RADIOLOGY**

**X-RAY CHEST PA**

**Prominent bronchovascular marking.**

Both lung fields and hila are normal .

No obvious active pleuro-parenchymal lesion seen .

Both costophrenic and cardiophrenic angles are clear .

Both diaphragms are normal in position and contour .

Thoracic wall and soft tissues appear normal.

Printed on:09-07-2023 14:57

---End of the Report---



**Dr. SHALU MISHRA**  
MBBS, MD, MIMSA, FICR, FKSR  
Radiology

**Apollo Health and Lifestyle Limited**

(CIN - U85110TG2000PLC115819)

Regd. Office: 1-10-60/62, Ashoka Raghupathi Chambers, 5th Floor, Begumpet, Hyderabad, Telangana - 500 016.

Ph No: 040-4904 7777, Fax No: 4904 7744 | Email ID: enquiry@apollohl.com | www.apollohl.com

**APOLLO CLINICS NETWORK KARNATAKA**

**Bangalore** (Basavanagudi | Bellandur | Electronic City | Fraser Town | HSR Layout | Indira Nagar | JP Nagar | Kundalahalli | Koramangala | Sarjapur Road) **Mysore** (VV Mohalla)

Online appointments: [www.apolloclinic.com](http://www.apolloclinic.com)

Page 1 of 1

TO BOOK AN APPOINTMENT

 **1860 500 7788**

Date: IST: 2023-07-08 12:57:38

**Personal Details**  
UHID: 00XHE1PUGMM02YY  
PatientID: 117287  
Name: Mr-Gul Mohd  
Age: 37  
Gender: Male  
Mobile: 9741536300


**Pre-Existing Medical-  
Conditions**

**Vitals**

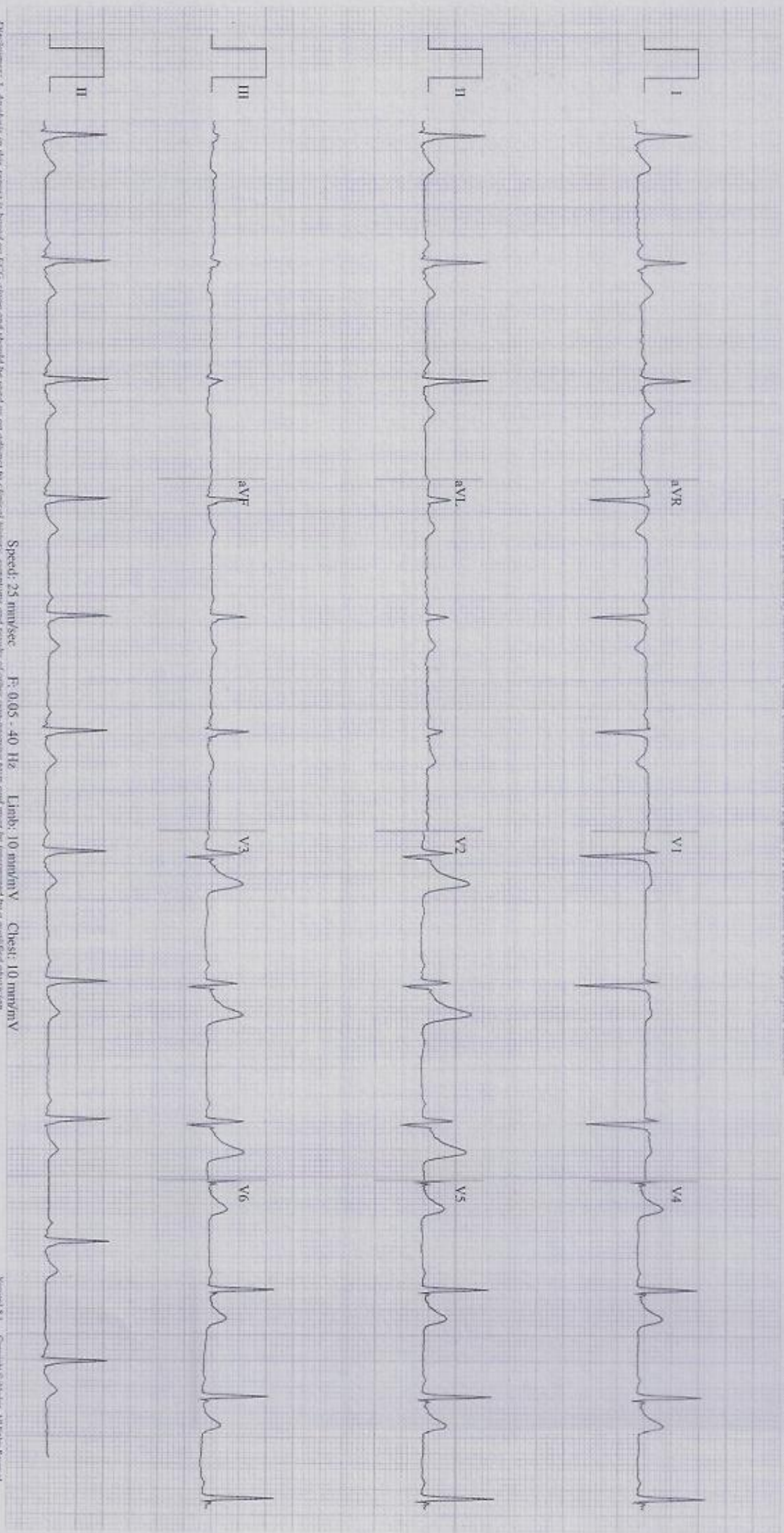
**Measurements**  
HR : 66 BPPM  
PR : 140 ms  
PD : 104 ms  
QRS : 102 ms  
QRS Axis: 34 deg  
QT/QTc: 344/361 ms

Report ID: AHILP\_00XHE1PUGMM02YY\_V6MM1002  
**Interpretation**  
Sinus Rhythm Regular  
No Significant ST-T Changes  
Normal Axis

**Apollo Medical  
Centre**

Authorized by  
  
Dr. Y. Sangeetha  
M.D.(N.B),ESC,FRP  
Reg No- KMC 44065

This trace is generated by EschulSystem - Cloud-Connect, Mumbai, Digital-6-11 Low-Solution ECG Platform from 20200313



Speed: 25 mm/sec F: 0.05 - 40 Hz Limb: 10 mm/mV Chest: 10 mm/mV

Disclaimer: 1. Analysis on this report is based on ECG alone and should be used in conjunction with clinical examination and history. 2. Normal ECG does not rule out heart disease. Abnormal ECG does not always mean serious heart disease. Comments: R report is being generated automatically. Clinical examination is required.

<b>NAME:</b>	MR.GUL MOHD
<b>AGE / SEX:</b>	37YRS/ MALE
<b>DATE:</b>	08/07/2023
<b>REFERRED BY:</b>	ARCOFEMI- MEDIWHEEL

**ABDOMINAL ULTRASONOGRAPHY REPORT**

**LIVER:** Appear normal in size and echogenicity. No focal lesion seen. The intra hepatic biliary and portal venous radicals are normal. Portal vein and CBD is normal

**GALL BLADDER:** well distended and appears normal. No abnormal wall thickening / pericholecystic fluid seen.

**PANCREAS:** Normal to the extent visualized.

**SPLEEN:** Normal in size and echo texture. No focal lesion noted.

**KIDNEYS:** Both kidneys are normal in size and echo texture. Normal cortico-medullary differentiation is maintained. No calculus / hydronephrosis on both sides.

**PELVIC ORGANS:**

Urinary bladder is Well distended and appears normal.

Visualized Prostate appear normal in size and echogenicity.

No free fluid in the abdomen and pelvis.

**IMPRESSION:**

- **No definitive sonological abnormality detected in present scan .**

*To correlate clinically & with other investigations.  
Not for medico-legal purpose*



**DR. SHALU MISHRA**  
MBBS ,MD, MIMSA ,FICR ,FKSR  
CONSULTANT RADIOLOGIST

**Apollo Health and Lifestyle Limited**

(CIN - U85110TG2000PLC115819)

Regd. Office: 1-10-60/62, Ashoka Raghupathi Chambers, 5th Floor, Begumpet, Hyderabad, Telangana - 500 016.

Ph No: 040-4904 7777, Fax No: 4904 7744 | Email ID: enquiry@apollohl.com | www.apollohl.com

APOLLO CLINICS NETWORK KARNATAKA

**Bangalore** (Basavanagudi | Bellandur | Electronic City | Fraser Town | HSR Layout | Indira Nagar | JP Nagar | Kundalahalli | Koramangala | Sarjapur Road) **Mysore** (VV Mohalla)

Online appointments: [www.apolloclinic.com](http://www.apolloclinic.com)

TO BOOK AN APPOINTMENT

 **1860 500 7788**

## 2-D ECHO-CARDIOGRAPHY DOPPLER & COLOUR DOPPLER REPORT

NAME : MR GUL MOHD

DATE : 08/07/2023


AGE/SEX: 33 Y/ M

REF ;ARCOFEMI MEDIWHEEL

UHID:117287

**\*\*\* MEASUREMENTS & FLOW VELOCITIES AS DEPICTED IN IMAGES OVERLEAF.**

1. NORMAL VALVES.
2. NORMAL FLOW ACROSS ALL VALVES.
3. NO MR/ AR/ TR.
4. NORMAL GREAT VESSELS.
5. NORMAL SYSTEMIC VEINS & AT LEAST 3 PULMONARY VEINS SEEN DRAINING INTO LA.
6. NORMAL SIZED CHAMBERS.
7. NO REGIONAL WALL MOTION ABNORMALITIES.
8. INTACT SEPTAE ( IVS & IAS ).
9. GOOD LV & RV SYSTOLIC FUNCTION.
10. PERICARDIUM : NORMAL
11. NO OBVIOUS VEGETATION / CLOTS.

  
**DR SOUMYA RAGHU**  
**CLINICAL CARDIOLOGIST**

*To correlate with clinical findings & other relevant investigations .*

**Apollo Health and Lifestyle Limited**

(CIN - U85110TG2000PLC115819)

Regd. Office: 1-10-60/62, Ashoka Raghupathi Chambers, 5th Floor, Begumpet, Hyderabad, Telangana - 500 016.

Ph No: 040-4904 7777, Fax No: 4904 7744 | Email ID: enquiry@apollohl.com | www.apollohl.com

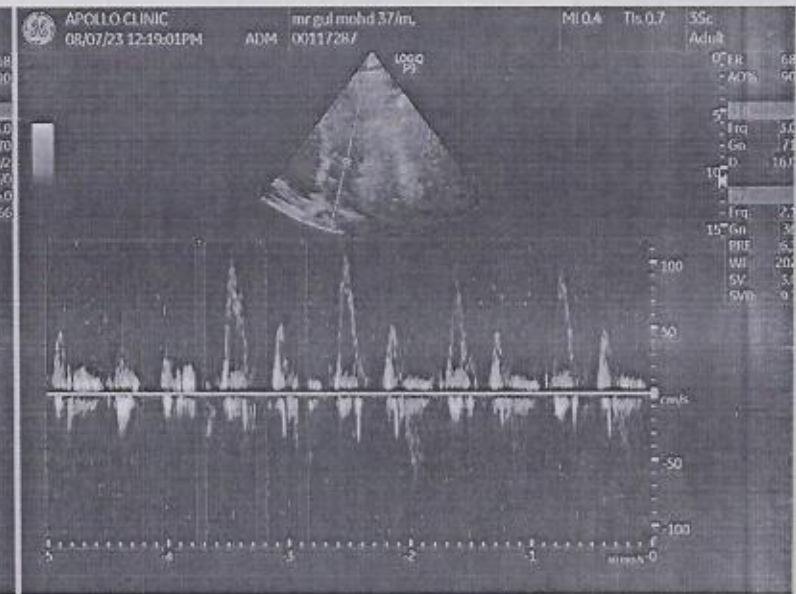
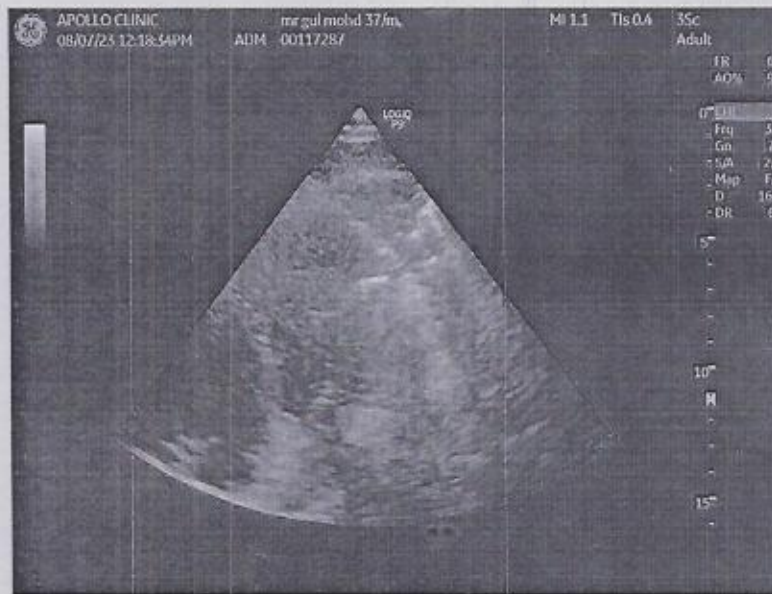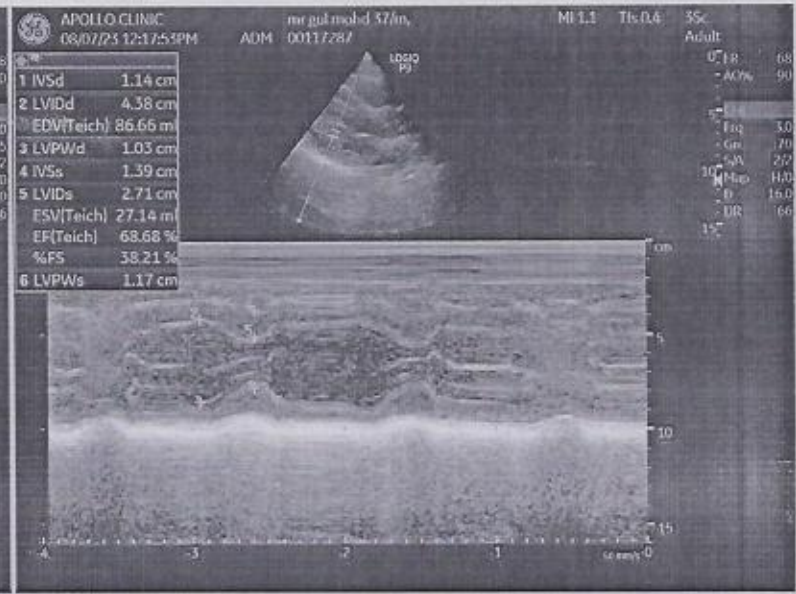
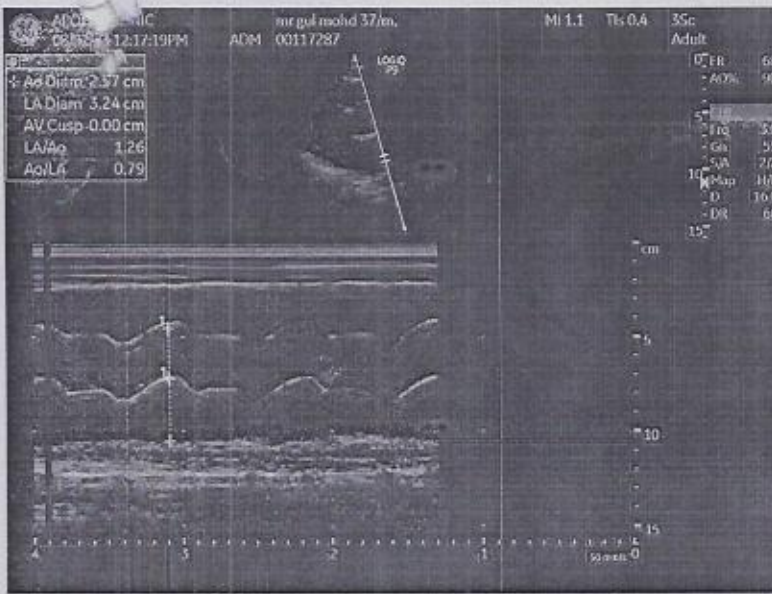
**APOLLO CLINICS NETWORK KARNATAKA**

**Bangalore** (Basavanagudi | Bellandur | Electronic City | Fraser Town | HSR Layout | Indira Nagar | JP Nagar | Kundalahalli | Koramangala | Sarjapur Road) **Mysore** (VV Mohalla)

Online appointments: www.apolloclinic.com

TO BOOK AN APPOINTMENT

 **1860 500 7788**





NAME:

AGE/SEX:

UHID:

DATE:

CHIEF COMPLAINTS:

PAST/FAMILY HISTORY:-

ALLERGIES:-

GENERAL EXAMINATION:-

PULSE: 68 bpm	BP: 125/74 mm/Hg	TEMP:	RR:
HT: 168 cm	WT: 74.8 kg	WAIST:	BMI: 26.5

SYSTEMIC EXAMINATION: -

VISION SCREENING

<u>Vision</u>	<u>Rt</u>	<u>Lt</u>	<u>With Corrections</u>
DISTANT	6/10	6/10	
NEAR	N-6	N-6	
COLOUR	(N)	(N)	

Chest:

CVS:

P/A:

IMPRESSION:-

FINAL RECOMMENDATIONS:-

**Apollo Health and Lifestyle Limited**

(CIN - U85110TG2000PLC115819)

Regd. Office: 1-10-60/62, Ashoka Raghupathi Chambers, 5th Floor, Begumpet, Hyderabad, Telangana - 500 016.

Ph No: 040-4904 7777, Fax No: 4904 7744 | Email ID: enquiry@apollohl.com | www.apollohl.com

APOLLO CLINICS NETWORK KARNATAKA

**Bangalore** (Basavanagudi | Bellandur | Electronic City | Fraser Town | HSR Layout | Indira Nagar | JP Nagar | Kundalahalli | Koramangala | Sarjapur Road) **Mysore** (VV Mohalla)

Online appointments: www.apolloclinic.com

**GENERAL PHYSICIAN**

TO BOOK AN APPOINTMENT

 **1860 500 7788**

## Your Apollo order has been confirmed

noreply@apolloclinics.info <noreply@apolloclinics.info>

Tue 7/4/2023 1:19 PM

To: customercare@mediwheel.in <customercare@mediwheel.in>

Cc: Electronic City <ecity@apolloclinic.com>; Rajendran K <rajendran.k@apolloclinic.com>; Syamsunder M <syamsunder.m@apollohl.com>

Dear Gul Mohd ,

Namaste Team,

Greetings from Apollo Clinics,

With regards to the below request the below appointment is scheduled at **ELECTRONIC CITY clinic** on **2023-07-08** at **08:55-09:00**.

Corporate Name	ARCOFEMI HEALTHCARE LIMITED
Agreement Name	ARCOFEMI MEDIWHEEL MALE AHC CREDIT PAN INDIA OP AGREEMENT
Package Name	[ARCOFEMI - MEDIWHEEL - FULL BODY ANNUAL PLUS MALE - 2D ECHO - PAN INDIA - FY2324]

"In view of corona virus precautionary measures, you are requested to take a mandatory check for symptoms & self-declaration at centre. Please cooperate. Thank you."

NOTE: We are not providing the breakfast in view of corona virus. And that customers on their own should carry their breakfast.

Note: Also once appointment is booked, based on availability of doctors at clinics tests will happen, any pending test will happen based on doctor availability and clinics will be updating the same to customers.

### Instructions to undergo Health Check:

1. Please ensure you are on complete fasting for 10-To-12-Hours prior to check.
2. During fasting time do not take any kind of medication, alcohol, cigarettes, tobacco or any other liquids (except Water) in the morning.
3. Bring urine sample in a container if possible (containers are available at the Health Check Centre).
4. Please bring all your medical prescriptions and previous health medical records with you.
5. Kindly inform the health check reception in case if you have a history of diabetes and cardiac problems.

For Women:

APOLLO CLINIC, NEELADRI NAGAR, ELECTRONIC CITY  
BANGLORE-560100

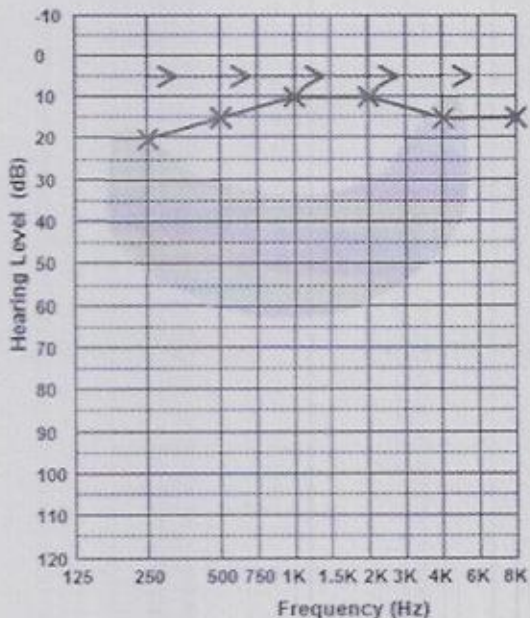
Name : GUL MOHD  
C R No. : 117287

Age : 37 yrs  
Audiogram No. : 1117

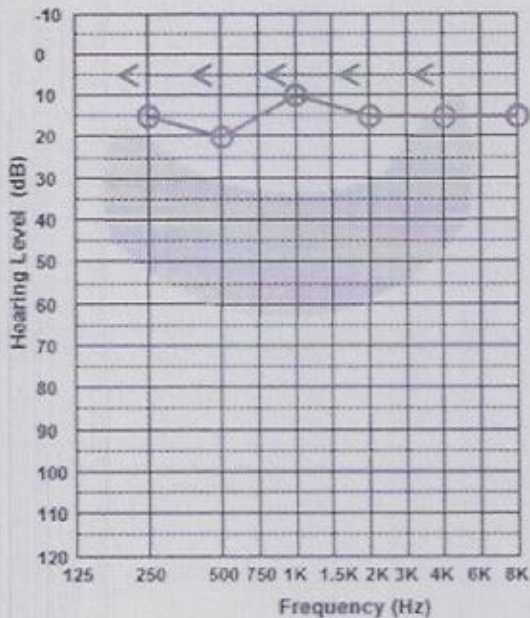
Sex : Male Date : 7/8/2023 1:41:51 PM

PURE TONE TEST

LEFT EAR



RIGHT EAR



Freq.	125	250	500	750	1000	1.5K	2K	3K	4K	6K	8K
R		15	20		10		15		15		15
R(M)											
BCR		5	5		5		5		5		

PTA (R) = 15dB      PTA-M(R) =      PTA-BCM(R) = (500,1K,2K)

Freq.	125	250	500	750	1000	1.5K	2K	3K	4K	6K	8K
L		20	15		10		10		15		15
L(M)											
BCL		5	5		5		5		5		

PTA (L) = 11dB      PTA-M(L) =      PTA-BCM(L) = (500,1K,2K)

- Legend
- Air: R (O), L (X)
  - Air/Masked: R (Δ), L (□)
  - Bone: R (<), L (>)
  - Bone/Masked: R (⌊), L (⌋)
  - MCL: R (M), L (M)
  - UCL: R (m), L (m)
  - Free Field: R (⊙), L (⊗)
  - FF/Prothesis: R (A), L (A)
  - Binaural: B
  - No Response: ↓

AUDIOLOGICAL DIAGNOSIS

BILATERAL HEARING SENSITIVITY WITHIN NORMAL LIMITS

Audiometer : Labat

आयकर विभाग  
INCOME TAX DEPARTMENT



भारत सरकार  
GOVT. OF INDIA

GUL MOHD

JABIR HUSAIN

07/10/1985

Permanent Account Number

BIIPM0291A

Signature



<b>Patient Name</b>	: Mr. GUL MOHD	<b>Age/Gender</b>	: 37 Y/M
<b>UHID/MR No.</b>	: CELE.0000117287	<b>OP Visit No</b>	: CELEOPV297315
<b>Sample Collected on</b>	:	<b>Reported on</b>	: 09-07-2023 14:58
<b>LRN#</b>	: RAD2041856	<b>Specimen</b>	:
<b>Ref Doctor</b>	: SELF		
<b>Emp/Auth/TPA ID</b>	: EC171165		

---

**DEPARTMENT OF RADIOLOGY**

---

**X-RAY CHEST PA**

**Prominent bronchovascular marking.**

Both lung fields and hila are normal .

No obvious active pleuro-parenchymal lesion seen .

Both costophrenic and cardiophrenic angles are clear .

Both diaphragms are normal in position and contour .

Thoracic wall and soft tissues appear normal.

**Dr. SHALU MISHRA**  
**MBBS, MD, MIMSA, FICR, FKS**  
Radiology

<b>Patient Name</b>	: Mr. GUL MOHD	<b>Age/Gender</b>	: 37 Y/M
<b>UHID/MR No.</b>	: CELE.0000117287	<b>OP Visit No</b>	: CELEOPV297315
<b>Sample Collected on</b>	:	<b>Reported on</b>	: 08-07-2023 16:30
<b>LRN#</b>	: RAD2041856	<b>Specimen</b>	:
<b>Ref Doctor</b>	: SELF		
<b>Emp/Auth/TPA ID</b>	: EC171165		

**DEPARTMENT OF RADIOLOGY**

**ULTRASOUND - WHOLE ABDOMEN**

<b>NAME:</b>	MR.GUL MOHD
<b>AGE / SEX:</b>	37YRS/ MALE
<b>DATE:</b>	08/07/2023
<b>REFERRED BY:</b>	ARCOFEMI- MEDIWHEEL

**ABDOMINAL ULTRASONOGRAPHY REPORT**

**LIVER:** Appear normal in size and echogenicity. No focal lesion seen. The intra hepatic biliary and portal venous radicals are normal. Portal vein and CBD is normal

**GALL BLADDER:** well distended and appears normal. No abnormal wall thickening / pericholecystic fluid seen.

**PANCREAS:** Normal to the extent visualized.

**SPLEEN:** Normal in size and echo texture. No focal lesion noted.

**KIDNEYS:** Both kidneys are normal in size and echo texture. Normal cortico-medullary differentiation is maintained. No calculi or hydronephrosis on both sides.

**PELVIC ORGANS:**

Urinary bladder is Well distended and appears normal.

Visualized Prostate appear normal in size and echogenicity.

No free fluid in the abdomen and pelvis.

**IMPRESSION:**

- **No definitive sonological abnormality detected in present scan .**

*To correlate clinically & with other investigations.*

*Not for medico-legal purpose*

**DR. SHALU MISHRA**  
**MBBS ,MD, MIMSA ,FICR ,FKSR**  
**CONSULTANT RADIOLOGIST**



**Patient Name** : Mr. GUL MOHD

**Age/Gender** : 37 Y/M

---

h6 { direction: ltr; color: rgb(0, 0, 0); text-align: center; background: transparent none repeat scroll 0% 0%; text-decoration: underline; break-after: avoid; }h6.western { font-size: 14pt; }h6.cjk { font-size: 14pt; }h6.cml { font-size: 11pt; }p { direction: ltr; color: rgb(0, 0, 0); background: transparent none repeat scroll 0% 0%; }p.western { font-size: 13pt; font-style: italic; }p.cjk { font-size: 13pt; font-style: italic; }p.cml { font-size: 11pt; font-style: italic; }

**Dr. SHALU MISHRA**  
MBBS, MD, MIMSA, FICR, FKS  
Radiology

Name: Mr. GUL MOHD  
Age/Gender: 37 Y/M  
Address: ECITY  
Location: BANGALORE, KARNATAKA  
Doctor:  
Department: GENERAL  
Rate Plan: Electronic City\_03122022  
Sponsor: ARCOFEMI HEALTHCARE LIMITED  
Consulting Doctor: Dr. ASWATHY .

MR No: CELE.0000117287  
Visit ID: CELEOPV297315  
Visit Date: 08-07-2023 09:40  
Discharge Date:  
Referred By: SELF

**HT-CHIEF COMPLAINTS AND PRESENT KNOWN ILLNESS**

**SYSTEMIC REVIEW**

**HT-HISTORY**

**PHYSICAL EXAMINATION**

**SYSTEMIC EXAMINATION**

**IMPRESSION**

**RECOMMENDATION**

**Doctor's Signature**



Name: Mr. GUL MOHD  
Age/Gender: 37 Y/M  
Address: ECITY  
Location: BANGALORE, KARNATAKA  
Doctor:  
Department: GENERAL  
Rate Plan: Electronic City\_03122022  
Sponsor: ARCOFEMI HEALTHCARE LIMITED  
Consulting Doctor: Dr. ASWATHY .

MR No: CELE.0000117287  
Visit ID: CELEOPV297315  
Visit Date: 08-07-2023 09:40  
Discharge Date:  
Referred By: SELF

**HT-CHIEF COMPLAINTS AND PRESENT KNOWN ILLNESS**

**SYSTEMIC REVIEW**

**HT-HISTORY**

**PHYSICAL EXAMINATION**

**SYSTEMIC EXAMINATION**

**IMPRESSION**

**RECOMMENDATION**

**Doctor's Signature**

Name: Mr. GUL MOHD  
Age/Gender: 37 Y/M  
Address: ECITY  
Location: BANGALORE, KARNATAKA  
Doctor:  
Department: GENERAL  
Rate Plan: Electronic City\_03122022  
Sponsor: ARCOFEMI HEALTHCARE LIMITED  
Consulting Doctor: Dr. PAVITRA RAMAN

MR No: CELE.0000117287  
Visit ID: CELEOPV297315  
Visit Date: 08-07-2023 09:40  
Discharge Date:  
Referred By: SELF

**HT-CHIEF COMPLAINTS AND PRESENT KNOWN ILLNESS**

**SYSTEMIC REVIEW**

**HT-HISTORY**

**PHYSICAL EXAMINATION**

**SYSTEMIC EXAMINATION**

**IMPRESSION**

**RECOMMENDATION**

**Doctor's Signature**

Name: Mr. GUL MOHD  
Age/Gender: 37 Y/M  
Address: ECITY  
Location: BANGALORE, KARNATAKA  
Doctor:  
Department: GENERAL  
Rate Plan: Electronic City\_03122022  
Sponsor: ARCOFEMI HEALTHCARE LIMITED  
Consulting Doctor: Dr. YASHASWI R G

MR No: CELE.0000117287  
Visit ID: CELEOPV297315  
Visit Date: 08-07-2023 09:40  
Discharge Date:  
Referred By: SELF

**Doctor's Signature**

Established Patient: No

**Vitals**

Date	Pulse (Beats/min)	B.P (mmHg)	Resp (Rate/min)	Temp (F)	Height (cms)	Weight (Kgs)	Body Fat Percentage (%)	Visceral Fat Level (%)	Body Age (Years)	BMI	Waist Circum (cms)	Hip (cms)	Waist (cms)	Waist & Hip Ratio	User
08-07-2023 16:49	68 Beats/min	125/74 mmHg	22 Rate/min	97.2 F	168 cms	74.8 Kgs	%	%	Years	26.5	cms	cms	cms		AHLL07132

Established Patient: No

**Vitals**

Date	Pulse (Beats/min)	B.P (mmHg)	Resp (Rate/min)	Temp (F)	Height (cms)	Weight (Kgs)	Body Fat Percentage (%)	Visceral Fat Level (%)	Body Age (Years)	BMI	Waist Circum (cms)	Hip (cms)	Waist (cms)	Waist & Hip Ratio	User
08-07-2023 16:49	68 Beats/min	125/74 mmHg	22 Rate/min	97.2 F	168 cms	74.8 Kgs	%	%	Years	26.5	cms	cms	cms		AHLL07132

Established Patient: No

**Vitals**

Date	Pulse (Beats/min)	B.P (mmHg)	Resp (Rate/min)	Temp (F)	Height (cms)	Weight (Kgs)	Body Fat Percentage (%)	Visceral Fat Level (%)	Body Age (Years)	BMI	Waist Circum (cms)	Hip (cms)	Waist (cms)	Waist & Hip Ratio	User
08-07-2023 16:49	68 Beats/min	125/74 mmHg	22 Rate/min	97.2 F	168 cms	74.8 Kgs	%	%	Years	26.5	cms	cms	cms		AHLL07132

Established Patient: No

**Vitals**

Date	Pulse (Beats/min)	B.P (mmHg)	Resp (Rate/min)	Temp (F)	Height (cms)	Weight (Kgs)	Body Fat Percentage (%)	Visceral Fat Level (%)	Body Age (Years)	BMI	Waist Circum (cms)	Hip (cms)	Waist (cms)	Waist & Hip Ratio	User
08-07-2023 16:49	68 Beats/min	125/74 mmHg	22 Rate/min	97.2 F	168 cms	74.8 Kgs	%	%	Years	26.5	cms	cms	cms		AHLL07132