



YASHFEEN CARDIAC HOSPITAL™

At. & Po. Viraval, Navsari. 396 445. Phone (H) (02637) 235725

Website : www.yashfeenhospital.in E-mail : info@yashfeenhospital.in

(For Laboratory Reports Only)



Patient Name : DIVYANSHI JEEGNESHBHAI PATEL Age : 24 Years Sex : F
 Ref By Dr. : - Area : Navsari Date : 29/03/2024
 Sample Time : 29/03/2024 08:28 No : 11 Time : 12:40PM

HAEMOGRAM

Test	Findings	UOM	Normal Range
HAEMOGLOBIN	11.1	gm/dl	M-13.5-17.0 gm/dl F-11.5-15.5 gm/dl
HAEMOGRAM			
RED BLOOD CELL	5.76	10 ⁶ /μL	3.76-5.70
TOTAL LEUCOCYTE COUNT	10300	cells/cumm	4,000-11,000cells/cumm
Differential Count			
Neutrophil	64	%	40-75 %
Lymphocytes	29	%	20-40 %
Eosinophil	1	%	01-06 %
Monocytes	6	%	02-10 %
Basophils	0	%	00-00 %
PLATELET COUNT	380000	lacs/cumm	1.5-5.5 Lacs/cumm
RBC INDICES			
P.C.V.	34.9	%	Male-40-56%, Female-37-47%
M.C.V.	60.6	cu/microns	76.0-94.0
M.C.H.	19.2	pg	27.0-30.0
M.C.H.C.	31.7	-	30.0-35.0
BLOOD GROUP	" AB "	-	-
RH FACTOR	POSITIVE	-	-
E.S.R.(1 hour)	18	mm/hr.	Male-5-10 mm/hr, Female-5-20 mm/hr

Remarks

Designed By : Sarita Infotech Pvt. Ltd., Navsari

P. Chaudhary
Dr. PIYUSH B. CHAUDHARI

M.D. Medicine

Reg. No. G-21518

Yashfeen Cardiac Hospital

Signature

Technician

Thanks for Reference



YASHFEEN CARDIAC HOSPITAL™


At. & Po. Viraval, Navsari. 396 445. Phone (H) (02637) 235725
Website : www.yashfeenhospital.in E-mail : info@yashfeenhospital.in
(For Laboratory Reports Only)



Patient Name : DIVYANSHI JEEGNESHBHAI PATEL Age : 24 Years Sex : F
Ref By Dr. : - Area : Navsari Date : 29/03/2024
Sample Time : 29/03/2024 08:31 No : 11 Time : 12:40PM

LIVER FUNCTION TEST REPORT

Test	Findings	UOM	Normal Range
TOTAL BILIRUBIN	0.4	mg/dL	0-1.0 mg/dL
DIRECT BILIRUBIN	0.2	mg/dL	0-0.8 mg/dL
INDIRECT BILIRUBIN	0.2	mg/dL	0-0.2 mg/dL
SGPT	10.0	U/L	Below 40.0 U/L
S.ALKALINE PHOSPHATASE	70.5	U/L	Child-170.0-515.0 U/L, Adults-37.0-147.0 U/L
TOTAL PROTEIN	7.4	g/dl	6.0-8.0 g/dl
ALBUMIN	4.6	g/dl	3.0-5.0 g/dl
GLOBULIN	2.8	g/dl	3.0-3.5 g/dl
A/G	1.7	g/dl	
SGOT	12.0	U/L	Below 40.0 U/L



P. Chaudhari
Dr. PIYUSH B. CHAUDHARI
M.D. Medicine
Reg. No. G-21518

Remarks

Designed By : Sarita Infotech Pvt. Ltd., Navsari

Yashfeen Cardiac Hospital

Signature

signature

Technician

Thanks for Reference



YASHFEEN CARDIAC HOSPITAL™

At. & Po. Viraval, Navsari. 396 445. Phone (H) (02637) 235725
Website : www.yashfeenhospital.in E-mail : info@yashfeenhospital.in
(For Laboratory Reports Only)



Patient Name : DIVYANSHI JEEGNESHBHAI PATEL Age : 24 Years Sex : F
Ref By Dr. : - Area : Navsari Date : 29/03/2024
Sample Time : 29/03/2024 08:37 No : 11 Time : 12:41PM

GGT TEST REPORT

Test	Findings	UOM	Normal Range
SERUM GGT	25.0	U/L	10.0-71.0 U/L



P. Chaudhari
Dr. PIYUSH B. CHAUDHARI
M.D. Medicine
Reg. No. G-21518

Remarks

Designed By : Sarita Infotech Pvt. Ltd., Navsari

Yashfeen Cardiac Hospital

Signature
Signature
Technician

Thanks for Reference



YASHFEEN CARDIAC HOSPITAL™

At. & Po. Viraval, Navsari. 396 445. Phone (H) (02637) 235725
Website : www.yashfeenhospital.in E-mail : info@yashfeenhospital.in
(For Laboratory Reports Only)



Patient Name : DIVYANSHI JEEGNESHBHAI PATEL Age : 24 Years Sex : F
Ref By Dr. : - Area : Navsari Date : 29/03/2024
Sample Time : 29/03/2024 08:37 No : 11 Time : 12:41PM

BLOOD SUGAR TEST REPORT

Test	Findings	UOM	Normal Range
FASTING BLOOD SUGAR	102.0	mg/dL	70-110 mg/dL
FASTING URINE SUGAR	NIL	-	NIL
POSTPANDRIAL BLOOD SUGAR	86.0	mg/dL	70-140 mg/dL
POSTPANDRIAL URINE SUGAR	N.R	-	NIL



f. cees
Dr. PIYUSH B. CHAUDHARI
M.D. Medicine
Reg. No. G-21518

Remarks

Designed By : Sarita Infotech Pvt. Ltd., Navsari

Yashfeen Cardiac Hospital

Amesha
Signature
Technician

Thanks for Reference



YASHFEEN CARDIAC HOSPITAL™

At. & Po. Viraval, Navsari. 396 445. Phone (H) (02637) 235725
Website : www.yashfeenhospital.in E-mail : info@yashfeenhospital.in
(For Laboratory Reports Only)



Patient Name : DIVYANSHI JEEGNESHBHAI PATEL Age : 24 Years Sex : F
Ref By Dr. : - Area : Navsari Date : 29/03/2024
Sample Time : 29/03/2024 08:37 No : 11 Time : 12:41PM

BIOCHEMICAL TEST REPORT

Test	Findings	UOM	Normal Range
S.CREATININE	0.6	mg/dL	Male-0.9-1.4 mg/dL, Female-0.8-1.2 mg/dL
S.URIC ACID	5.4	mg/dL	Male:3.5-7.2 mg/dL, Female:2.6-6.0 mg/dL
BLOOD UREA NITROGEN	8.5	mg/dL	4.7-23.0 mg/dL



P. Chaudhari
Dr. PIYUSH B. CHAUDHARI
M.D. Medicine
Reg. No. G-21518

Remarks

Designed By : Sarita Infotech Pvt. Ltd., Navsari

Yashfeen Cardiac Hospital

Signature
Signature
Technician

Thanks for Reference



YASHFEEN CARDIAC HOSPITAL™

At. & Po. Viraval, Navsari. 396 445. Phone (H) (02637) 235725

Website : www.yashfeenhospital.in E-mail : info@yashfeenhospital.in

(For Laboratory Reports Only)



Patient Name : DIVYANSHI JEEGNESHBHAI PATEL
Ref By Dr. : -
Sample Time : 29/03/2024 08:37 No : 11

Age : 24 Years Sex : F
Area : Navsari Date : 29/03/2024
Time : 12:41PM

THYROID FUNCTION TEST REPORT

Test	Findings	UOM	Normal Range
T3 (TRIODOTHYRONINE)	1.39	ng/ml	Newborns:0.73-2.88, 6 Days-3 Months:0.80-2.75, 4-12Months:0.86-2.65, 1-6 Years:0.92-2.48, 7-11 Years:0.93-2.31, 12-20Years:0.91-2.18, Adults:0.80-2.00
T4 (THYROXINE)	6.04	µg/dl	Newborns:5.04-18.5, 6 Days-3 Months:5.41-17.0, 4-12 Months:5.67-16.0, 1-6 Years:5.95-14.7, 7-11 Years:5.99-13.8, 12-20 Years:5.91-13.2, Adults:5.10-14.1
TSH	5.27	µIU/ml	Newborns:0.70-15.2, 6 Days-3 Months:0.72-11.0, 4-12 Months:0.73-8.35, 1-6 Years:0.70-5.97, 7-11 Years:0.60-4.84, 12-20 Years:0.51-4.30, Adults:0.27-4.20

TECHNIQUE
ELECTROCHEMILUMINESCEN
CE



P. Chaudhari
Dr. PIYUSH B. CHAUDHARI
M.D. Medicine
Reg. No. G-21518

Remarks

Designed By : Sarita Infotech Pvt. Ltd., Navsari

Yashfeen Cardiac Hospital

[Signature]
signature
Technician

Thanks for Reference



YASHFEEN CARDIAC HOSPITAL™

At. & Po. Viraval, Navsari. 396 445. Phone (H) (02637) 235725

Website : www.yashfeenhospital.in E-mail : info@yashfeenhospital.in

(For Laboratory Reports Only)



Patient Name : DIVYANSHI JEEGNESHBHAI PATEL
Ref By Dr. : -
Sample Time : 29/03/2024 08:37 No : 11

Age : 24 Years Sex : F
Area : Navsari Date : 29/03/2024
Time : 12:41PM

ROUTINE URINE ANALYSIS

Test	Findings	UOM	Normal Range
------	----------	-----	--------------

PHYSICAL EXAMINATION

Quantity	-	-	
Colour	YELLOW	-	
Appearance	CLEAR	-	
Reaction	ACIDIC	-	
Sp. Gravity	1.004	-	

CHEMICAL EXAMINATION

U. Albumin	NIL	-	
Sugar	NIL	-	
Acetone	NIL	-	
Bile Salt	NIL	-	
Bile Pigment	NIL	-	
Occult Blood	TRACE	-	

MICROSCOPIC EXAMINATION

Pus Cells	3-4	/hpf	
Epithelial cells	6-8	/hpf	
Red cells	2-3	/hpf	
Casts	-	/hpf	
Crystals	AMORPHOUS SEEN	/hpf	
Others	BACTERIA {++} SEEN	/hpf	



P. Chaudhari
Dr. PIYUSH B. CHAUDHARI
M.D. Medicine
Reg. No. G-21518

Remarks

Designed By : Sarita Infotech Pvt. Ltd., Navsari

Yashfeen Cardiac Hospital

Amrisha
Signature
Technician

Thanks for Reference

YASHFEEN IMAGING & RADIOLOGY DEPARTMENT

MANAGED BY :- YASHFEEN FOUNDATION

VIRAVAL, NAVSARI. 396 445. PHONE : (H) (02637) 235725

Website : www.yashfeenhospital.in E-mail : info@yashfeenhospital.in

Patient's Name:	DIVYANSHI J. PATEL	Age & Sex:	24Yrs/F
Ref. by Dr.	SELF	Date:	29-03-2024

X RAY CHEST (PA VIEW)

Both lung fields appear normal.

Both hila appear normal.

Both CP angles appear clear.

Cardiac size appears within normal limit.

Both domes of diaphragm appear normal.

Bony thoracic cage appears normal.

IMPRESSION:

- Normal X-ray chest (PA view).



Dr. DHARMESH DESAI

Dr. Dharmesh Desai
(M.D. Radiology)

Reg. No. G - 45284

YASHFEEN GROUP OF HOSPITAL

Please contact immediately for any typographical error.

This is only professional opinion, not a final diagnosis. Kindly correlate clinically. Not valid for medicolegal purpose.



(Regd. No. E / 1390 / Navsari)

YASHFEEN CARDIAC HOSPITAL™

MANAGED BY :- YASHFEEN FOUNDATION

VIRAVAL, NAVSARI. 396 445. PHONE : (H) (02637) 235725

Website : www.yashfeenhospital.in E-mail : info@yashfeenhospital.in

(Stationary For Report Only)

2D ECHO CARDIOGRAPHY COLOUR DOPPLER REPORT

Patient Name & No	: DIVYANSHI JEEGNESHBHAI PATEL CH2305306	Age/Sex	UHID :	: 5111
Doctor	: Mohil Nagad	24/ F	No :	: 7783
Referred By	:		Date :	: 29/03/2024

M-Mode findings

LVIDd : 44mm
 LVIDs : 29mm
 IVSd : 09mm
 PWd : 09mm
 EF : 60%
 Aorta : 20mm
 LA : 30mm

2D Imaging

Aortic Valve : Trileaflet, Peak gradient 5mm of Hg.
 Mitral Valve : Thin, Pliable, Normal Mobility, Normal function
 Tricuspid Valve : Normal
 Pulmonary Valve : Normal

=> : All cardiac chambers are normal sized.
 => : All cardiac valves are normal.
 => : No regional wall motion abnormality.
 => : Normal LV systolic function.
 => : Normal LV diastolic function.
 => : IAS/IVS intact.
 => : No obvious clots/ vegetations/ or effusion.
 => : IVC Normal size.

Doppler Findings

=> : No MS/MR, No TS/TR, No AS/AR & No PS/PR
 Mitral inflow Pattern : E > A
 Tissue Doppler Findings : E' > A'

Impression : Normal LVEF:60%, No RWMA.



Report Prepared By

Report Checked By
DR. MOHIL NAGAD
 M.D. Medicine, Interventional Cardiology
 Senior Consultant, Interventional Cardiology
 Reg. No. 62851
 YASHFEEN HOSPITAL, NAVSARI

YASHFEEN IMAGING & RADIOLOGY DEPARTMENT

MANAGED BY :- YASHFEEN FOUNDATION

VIRAVAL, NAVSARI. 396 445. PHONE : (H) (02637) 235725

Website : www.yashfeenhospital.in E-mail : info@yashfeenhospital.in

Name	DIVYANSHI J. PATEL	Age	24Y/F
Ref by Dr	SELF	Date	29/03/2024

USG ABDOMEN & PELVIS (SCREENING)(TVS)

Liver appears normal in size & shape with normal echopattern.
No e/o focal or diffuse lesion. IHBR appear normal.
PV and CBD appear normal.

Gall bladder appears distended & normal in shape & size. No e/o calculus or mass seen.
Walls appear normal.

Pancreas appears normal in size and echogenicity. No e/o focal or diffuse lesion.

Spleen appears normal in size and shows normal echopattern. No e/o focal lesion.

Both Kidneys appear normal in size and echopattern. CM Differentiation is preserved.
No e/o calculus or hydronephrosis on either side.
Perirenal spaces appear normal on either side.
Suprarenal regions appear normal on either side. No e/o mass lesion.

Bladder is empty (due to non-compliance of patient). Adv: Follow up USG with normally distended bladder.

Uterus appears anteverted, normal in size & shows normal echopattern.
Endometrial cavity is empty. ET- 11 mm. No e/o focal or diffuse mass lesion.

Left ovary appear normal in size & echopattern.
16 x 21 mm in size right ovarian simple cyst noted.
No e/o adnexal mass on left side.

RIF region appears normal.

No e/o ascites.

IMPRESSION:

Right ovarian simple cyst



Dr. DHARMESH DESAI
(M.D. Radiology)
Reg. No. G - 45284
Dr. Dharmesh Desai
YASHFEEN GROUP OF HOSPITAL

Please contact immediately for any typographical error.

This is only professional opinion, not a final diagnosis. Kindly consult clinically. Not valid for medical/legal purposes.

DIVYANSHI,
ID:
DOB:
24 Years,
Female, Unknown
Med.:
Location:
Referring Physician:
Notes:

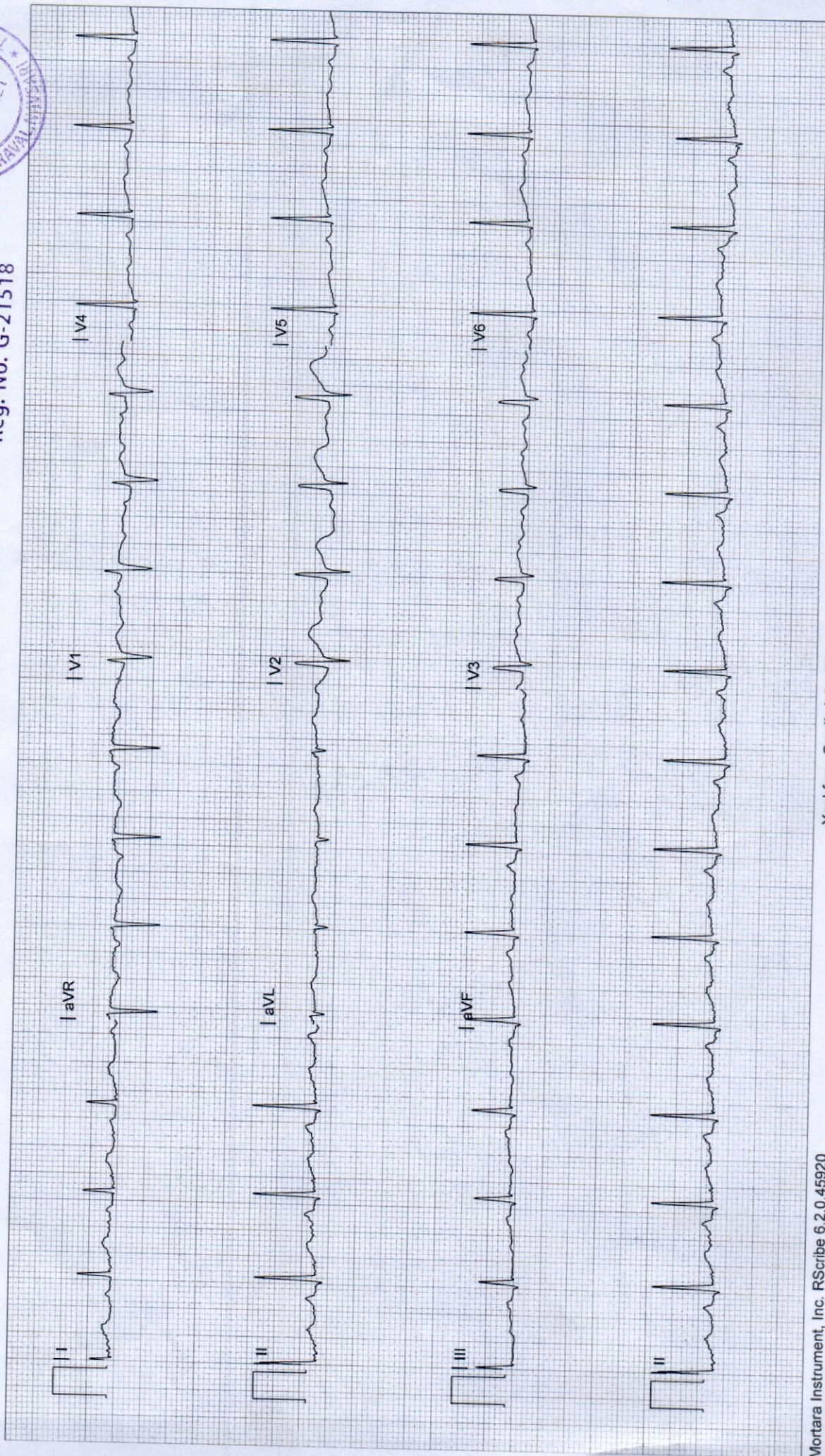
29-03-2024 09:53:21

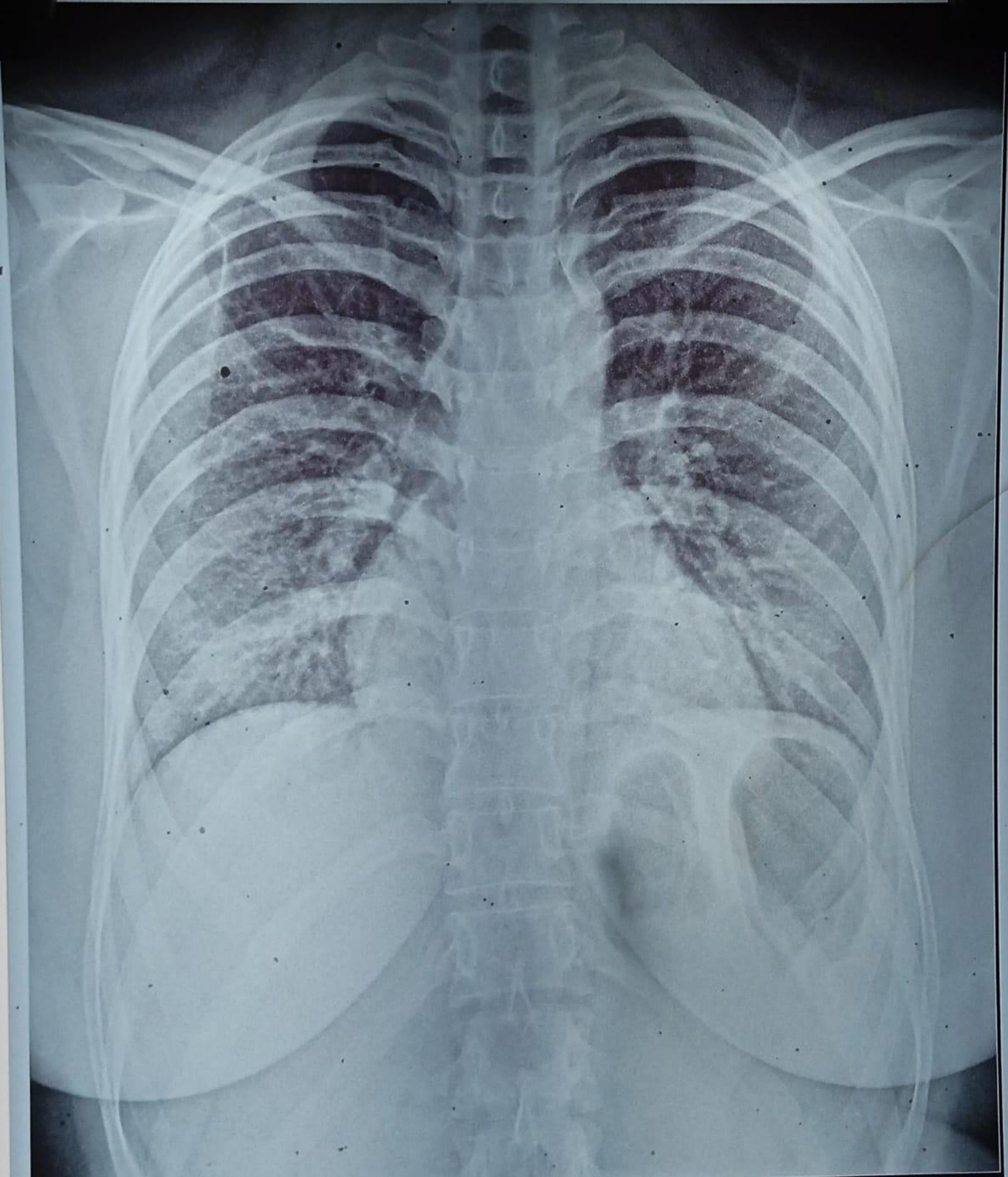
Vent. Rate: 92 BPM
PR Int: 162 ms
QRS dur: 90 ms
QT/QTc: 361/410 ms
P-R-T axes: 59 62 46
Avg. RR: 652 ms
QTcB: 447 ms
QTcF: 416 ms

SINUS RHYTHM
NONSPECIFIC T-WAVE ABNORMALITY
BORDERLINE ECG

UNCONFIRMED REPORT
Reviewed by:

f. Leon
Signed by:
Dr. PIYUSH B. CHAUDHARI
M.D. Medicine
Reg. No. G-21518





H23053065 DIVYANSHI J PATEL 24/Y 290324797. ChestErect PA 29/03/2024
YASHFEEN GROUP OF HOSPITALS NAVSARI PH:9924047789