

NAME: MRS.PRATIVA MAJUMDAR	AGE: 25YRS	SEX:FEMALE
REF BY : CORPORATE	MR NO:FSIN-0000	DATE:21/07/2021

ULTRASOUND OF WHOLE ABDOMEN

LIVER: Liver is normal in size, shape, outline and echotexture. The intrahepatic tubular structures are normal. No focal area of alterea echogenicity is noted. The porta hepatis is normal. The common bile duct measures **0.26cm** in diameter .The portal vein measures **0.68cm** at porta.

GALL BLADDER: Gall bladder is normal .Wall is normal limits. No calculus or mass is seen within the gall bladder.

PANCREAS: It is normal in size, Shape, Outline and echotexture. Pancreatic duct is not dilated.

SPLEEN: It is normal in size **8.00cm**, Shape, Outline and echotexture. No parenchymal lesion is noted.

RIGHT KIDNEY: kidney are normal in position, size, shape, outline and echotexture .The cortico medullary differentiation is maintained. No calculus or hydronephrosis is seen.

RIGHT KIDNEY: measures – **9.21cm**.

LEFT KIDNEY: kidney are normal in position, size, shape, outline and echotexture. The cortico medullary differentiation is maintained. No calculus or hydronephrosis is seen.


LEFT KIDNEY: measures –**10.21cm**.

UTERUS: It is normal size, shape and echotexture. It is anteverted. No SOL is seen in the myometrium. Uterine cavity is empty. Uterus measures. (**6.90cmX4.00cmX3.51cm**).

Endometrial thickness is normal measures- **0.84cm**.

RIGHT OVARIES- They are normal in size, shape ,outline and echotexture. measures-(**0.84cmX3.41cm**)

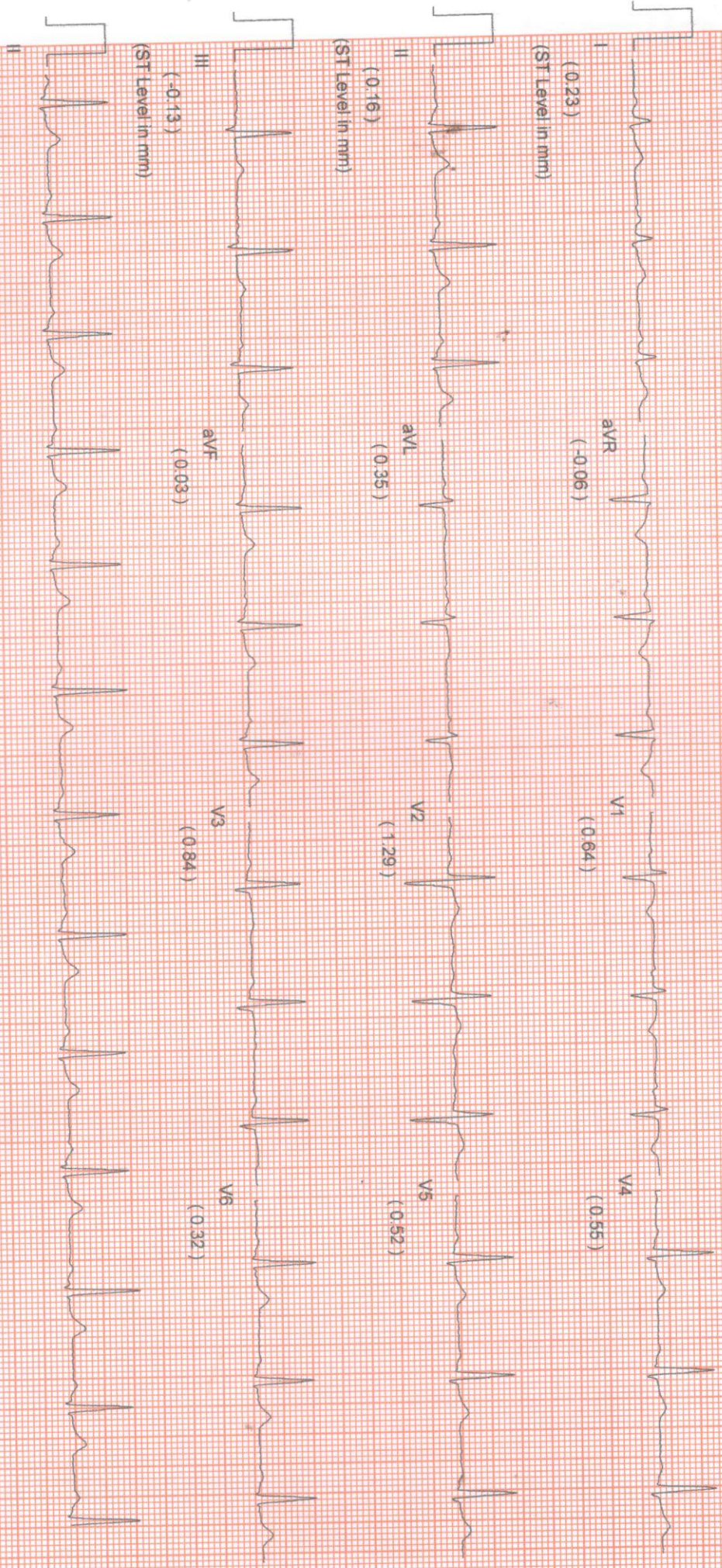
LEFT OVARIES- They are normal in size, shape ,outline and echotexture. measures-(**4.04cmX1.70cm**)


DR.SUSMITA CHOWDHURY
MBBS,MD.

IMPRESSION: HEPATOMEGALY WITH MODERATE FATTY CHANGES
CONSULTANT SONOLOGIST

Resting ECG Report

Patient Name: Mrs. PRATIVA MAJUMDAR 25/F
 July 21, 2021
 Time: 12:05:44
 QT / QTc: 0.360 / 0.404 Sec
 P-QRS-T Axis: (-23) (-74) (-48) deg
 PR Interval: 0.14 sec
 QRS Duration: 0.092 Sec
 RR Interval: 0.79 sec
 HR: 75 bpm
 BP: 110/70 mmHg



Comments :-

Prativa Majumdar

NAME:MRS. PRATIVA MAJUMDAR	MR NO: FSIN-0000	DATE : 21.07.2021
AGE: 25YRS.	SEX:FEMALE	REF BY: CORPORATE

ECG REPORT

HR : 75 b/min
AXIS : NORMAL
RHYTHM : SINUS
PR INTERVAL : 0.14 sec
QT INTERVAL : 0.404 sec
QRS DURATION : 0.092 sec
T-WAVE : NORMAL

IMPRESSION:

- RESTING ECG IS WITHIN NORMAL LIMITS.



Dr. SIDDHARTHA KUNDU
MBBS (Cal), PGDCC, CCEBDM
Clinical Cardiologist
Ex Sr Resident, Cardiology Dept
B.R Singh Hospital, Eastern Railway



DEPARTMENT OF RADIOLOGY X-RAY OF CHEST (PA) VIEW

MR. NO- FSIN.0000000

SEX-FEMALE

NAME: - Mrs. PRATIVA MAJUMDAR

EXAMINATION DATE- 21/07/2021

AGE- 25YRS

REPORT DATE-21/07/2021

REF DR. SELF

FINDINGS:

- Bilateral accentuated pulmonary vascular marking noted.
- Tracheal shadow is in the midline.
- Bilateral CP angle are clear.
- Both hila appear normal.
- CTR appears normal.



DR. ARNAB MANDAL

MD, Physician, PGDUS (Delhi) CEFT-USG (WBUHS KOLKATA)
Fellow of Jefferson Ultrasound Radiology and Education Institute
Philadelphia Ex-Radiology Resident (S.E. Railway)
Regd.No:72022(WBMC)

APOLLO CLINIC @ OM TOWER
Opp. of Rabindra Bharati University
Licensee : Satyam Credit Pvt. Ltd.
36C, B.T. Road, Kolkata - 700 002
E-mail : sinthimor@theapolloclinic.com
satyamcreditpvtltd@gmail.com



033 2556 3333



033 2556 5555



+91 98521 66666



+91 74392 97827