

Dr. Goyal's

Path Lab & Imaging Centre

B-51, Ganesh Nagar, Opp. Janpath Corner, New Sangar
Tale : 0141-2293346, 4049787, 9887048787

Website : www.dr.goyalpathlab.com | E-mail : dr.goyalpiyush@gmail.com

General Physical Examination



Name: RITU PAWAR Age: 26 DOB: 14-07-1996 Sex: Female

Referred By: BOB

Photo ID: AADHAR ID #: attached

Ht: 162 (cm)

Wt: 60 (Kg)

Chest (Expiration): 92 (cm)

Abdomen Circumference: 82 (cm)

Blood Pressure: 124/86 mm Hg PR: 70 /min RR: /min Temp: Afebrile

BMI 22.9

Eye Examination: Distant vision: R/E: 6/6. N/E 6/9. Near vision N/6.
Color vision normal (B/L eyes)

Other: noV significant

On examination he/she appears physically and mentally fit : Yes / No

Signature Of Examinee : Ritu

Name of Examinee: Ritu

Signature Medical Examiner :

Name Medical Examiner :

Dr Piyush Goyal
M.B.B.S., D.M.R.B.
M.C. Reg No -0179-3



ગુજરાત સરકાર

Government of India



રિતુ પાવાર

Ritu Pawar

જન્મ તારીખ/DOB: 14/07/1996

મહિલા/ FEMALE

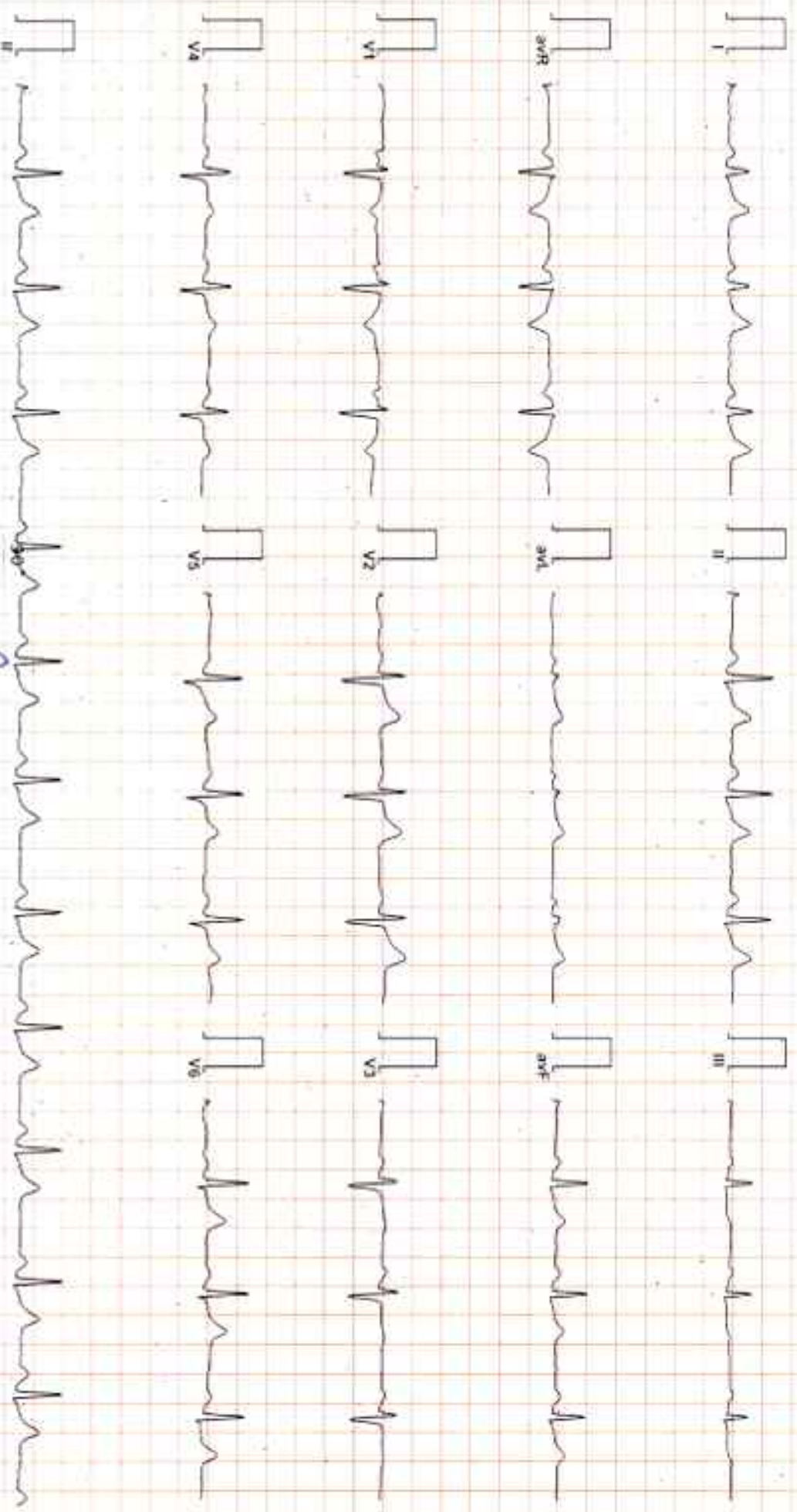
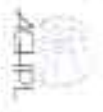Dr Piyush Goyal
M.B.B.S., D.M.R.D
RMC Reg No -017940

8241 0490 6949

VID - 9159 4759 4000 4192



मेरा आधार, मेरी पहचान



Heart Rate : 71 bpm
 PR Interval : 156 ms
 QRS Duration : 84 ms
 QT/QTc Int : 382/401 ms
 P-QRS-T axis : 52.00° 55.00° 29.00°

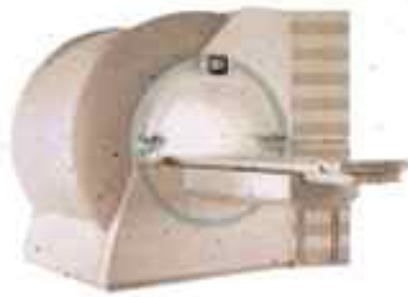180°

-30°

Handwritten signature

DR. Pooja Goyal
MR. S. D. D. D.
 9000-2000-2000-2000

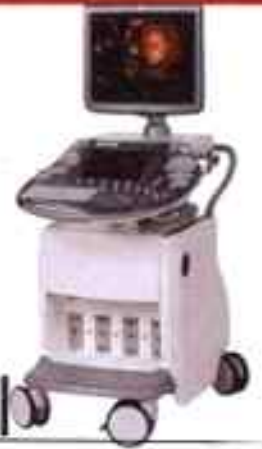DR. Renuka Sharma
DR. Renuka Sharma
DR. Renuka Sharma



Dr. Goyal's

Path Lab & Imaging Centre

8-51, Ganesh Nagar, Opp. Janpeth Corner, New Sangarner Road, Jaipur
 Tele : 0141-2293346, 4049787, 9887049787
 Website : www.dr.goyalspathlab.com | E-mail : dr.goyalpiyush@gmail.com



Date : - 27/08/2022 09:08:35
NAME :- Mrs. RITU PAWAR
 Sex / Age :- Female 25 Yrs
 Company :- Medi/Wheel

Patient ID :- 12221896
 Ref. By Doctor :- BOB
 Lab/Hosp :-

Fetal Authentication : 27/08/2022 12:04:08

BOB PACKAGE FEMALE BELOW 40

ULTRA SOUND SCAN OF ABDOMEN

Liver is of normal size. Echo-texture is normal. No focal space occupying lesion is seen within liver parenchyma. Intra hepatic biliary channels are not dilated. Portal vein diameter is normal.

Gall bladder is of normal size. Wall is not thickened. No calculus or mass lesion is seen in gall bladder. Common bile duct is not dilated.

Pancreas is of normal size and contour. Echo-pattern is normal. No focal lesion is seen within pancreas.

Spleen is of normal size and shape. Echotexture is normal. No focal lesion is seen.

Kidneys are normally sited and are of normal size and shape. Cortico-medullary echoes are normal. No focal lesion is seen. Collecting system does not show any dilatation or calculus.

Urinary Bladder is well distended and showing smooth wall with normal thickness. Urinary bladder does not show any calculus or mass lesion.

Uterus is anteverted and normal in size and measures 80 x 48 x 37 mm. Myometrium shows normal echo - pattern. No focal space occupying lesion is seen. Endometrial echo is normal.

Both ovaries are visualised and are normal. No adnexal mass is seen.

No enlarged nodes are visualised. No retro-peritoneal lesion is identified. No significant free fluid is seen in pouch of douglas.

IMPRESSION:

***Normal Study.**

Needs clinical correlation & further evaluation

DR. RATHOD HETALI AMRUTLAL
MD RADIO DIAGNOSIS
RMC NO. 17163

*** End of Report ***

Page No: 1 of 1

BILAL

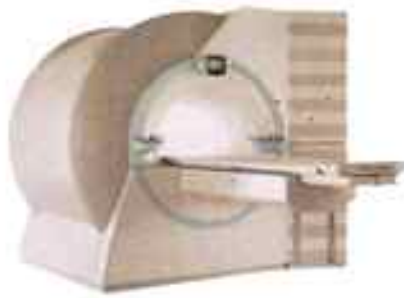Dr. Piyush Goyal
 M.B.B.S., D.M.R.D.
 RMC Reg No. 017096

Dr. Poonam Gupta
 MBBS, MD (Radio Diagnosis)
 RMC No. 32495

Dr. Ashish Choudhary
 MBBS, MD (Radio Diagnosis)
 Fetal Medicine Consultant
 FMF ID - 260517 | RMC No 22430

Dr. Rathod Hetali Amrutlal
 MBBS, M.D. (Radio-Diagnosis)
 RMC No. 17163

Transcript by:



Dr. Goyal's

Path Lab & Imaging Centre

B-51, Ganesh Nagar, Opp. Janpath Corner, New Sangarner Road, Jaipur
Tele : 0141-2293345, 4049787, 9887049787
Website : www.dr.goyalpathlab.com | E-mail : dr.goyalpiyush@gmail.com



Date : - 27/08/2022 09:08:35
NAME :- Mrs. RITU PAWAR
Sex / Age : - Female : 26 Yrs
Company : - MediWheel

Patient ID :- 12221696
Ref. By Doctor :- BOB
Lab/Hosp :-

Final Authentication : 27/08/2022 12:04:08

BOB PACKAGE FEMALE BELOW 40

ULTRA SOUND SCAN OF ABDOMEN

Liver is of normal size. Echo-texture is normal. No focal space occupying lesion is seen within liver parenchyma. Intra hepatic biliary channels are not dilated. Portal vein diameter is normal.

Gall bladder is of normal size. Wall is not thickened. No calculus or mass lesion is seen in gall bladder. Common bile duct is not dilated.

Pancreas is of normal size and contour. Echo-pattern is normal. No focal lesion is seen within pancreas.

Spleen is of normal size and shape. Echotexture is normal. No focal lesion is seen.

Kidneys are normally sited and are of normal size and shape. Cortico-medullary echoes are normal. No focal lesion is seen. Collecting system does not show any dilatation or calculus.

Urinary Bladder : is well distended and showing smooth wall with normal thickness. Urinary bladder does not show any calculus or mass lesion.

Uterus is anteverted and normal in size and measures 80 x 48 x 37 mm. Myometrium shows normal echo - pattern. No focal space occupying lesion is seen. Endometrial echo is normal.

Both ovaries are visualised and are normal. No adnexal mass is seen.

No enlarged nodes are visualised. No retro-peritoneal lesion is identified.
No significant free fluid is seen in pouch of Douglas.

IMPRESSION:

***Normal Study.**

Needs clinical correlation & further evaluation

*** End of Report ***

Page No: 1 of 1

BILAL

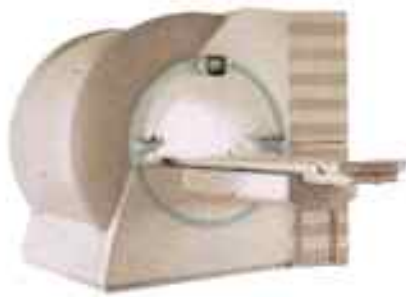Dr. Piyush Goyal
M.B.B.S., D.M.R.D.
RMC Reg No. 017996

Dr. Pooja Gupta
MBBS, MD (Radio Diagnosis)
RMC No. 32495

Dr. Ashish Choudhary
MBBS, MD (Radio Diagnosis)
Fetal Medicine Consultant
FMF ID - 260517 | RMC No 22430

Dr. Rathod Hetali Amrutlal
MBBS, M.D. (Radio-Diagnosis)
RMC No. 17163

Transcript by



Dr. Goyal's

Path Lab & Imaging Centre

B-51, Ganesh Nagar, Opp. Janpath Corner, New Sangner Road, Jaipur
 Tele : 0141-2293345, 4049787, 9867049787
 Website : www.dr.goyalspathlab.com | E-mail : dr.goyalpiyush@gmail.com



Date : 27/08/2022 09:08:35
NAME :- Mrs. RITU PAWAR
 Sex / Age : Female 28 Yrs
 Company : MedWHEEL

Patient ID :- 12221896
 Ref. By Doctor :- BOB
 Lab/Hosp :-

Final Authentication : 27/08/2022 12:04:08

BOB PACKAGE FEMALE BELOW 40
 2D ECHO OPTION TMT (ADULT/CHILD)

2D-ECHOCARDIOGRAPHY M-MODE WITH DOPPLER STUDY:

FAIR TRANSTHORACIC ECHOCARDIOGRAPHIC WINDOW MORPHOLOGY:

MITRAL VALVE	NORMAL	TRICUSPID VALVE	NORMAL
AORTIC VALVE	NORMAL	PULMONARY VALVE	NORMAL

M-MODE EXAMINATION:

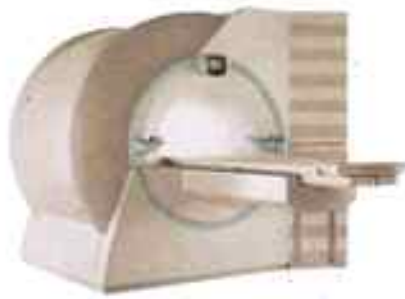AO	22	mm	LA	25	Mm	IVS-D	5	mm
IVS-S	11	mm	LVID	45	Mm	LVSD	28	mm
LVPW-D	6	mm	LVPW-S	13	Mm	RV		mm
RVWT		mm	EDV		ml	LVVS		ml
LVEF	67%		RWMA			ABSENT		

CHAMBERS:

LA	NORMAL	RA	
LV	NORMAL	RV	NORMAL
PERICARDIUM		NORMAL	

COLOUR DOPPLER:

MITRAL VALVE					
E VELOCITY	1.03	m/sec	PEAK GRADIENT		Mm/hg
A VELOCITY	0.54	m/sec	MEAN GRADIENT		Mm/hg
MVA BY PHT		Cm ²	MVA BY PLANIMETRY		Cm ²
MITRAL REGURGITATION		ABSENT			
AORTIC VALVE					
PEAK VELOCITY	0.98	m/sec	PEAK GRADIENT		mm/hg
AR VMAX		m/sec	MEAN GRADIENT		mm/hg
AORTIC REGURGITATION		ABSENT			
TRICUSPID VALVE					
PEAK VELOCITY	0.53	m/sec	PEAK GRADIENT		mm/hg
MEAN VELOCITY		m/sec	MEAN GRADIENT		mm/hg
VMAX VELOCITY					
TRICUSPID REGURGITATION		ABSENT			
PULMONARY VALVE					
PEAK VELOCITY	0.92	M/sec	PEAK GRADIENT		Mm/hg
MEAN VELOCITY			MEAN GRADIENT		Mm/hg
PULMONARY REGURGITATION		ABSENT			



Dr. Goyal's

Path Lab & Imaging Centre

B-51, Ganesh Nagar, Opp. Janpath Corner, New Sangarner Road, Jalpur
Tele : 0141-2293346, 4049787, 9887049787
Website : www.dr.goyalpathlab.com | E-mail : dr.goyalpiyush@gmail.com



Date :- 27/08/2022 09:08:35
NAME :- Mrs. RITU PAWAR
Sex / Age - Female 26 Yrs
Company - MediWheel

Patient ID :- 12221896
Ref. By Doctor - BOB
Lab/Hosp :-

Final Authentication : 27/08/2022 12:04:08

Impression--

1. Normal LV size & contractility
2. No RWMA, LVEF 67 %.
3. Normal cardiac chamber.
4. Normal valve
5. No clot, no vegetation, no pericardial effusion.

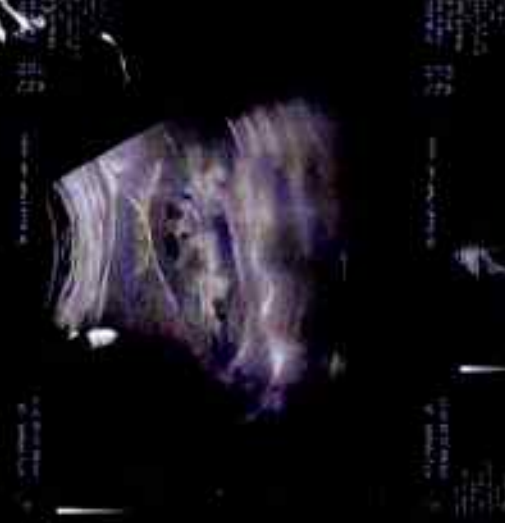

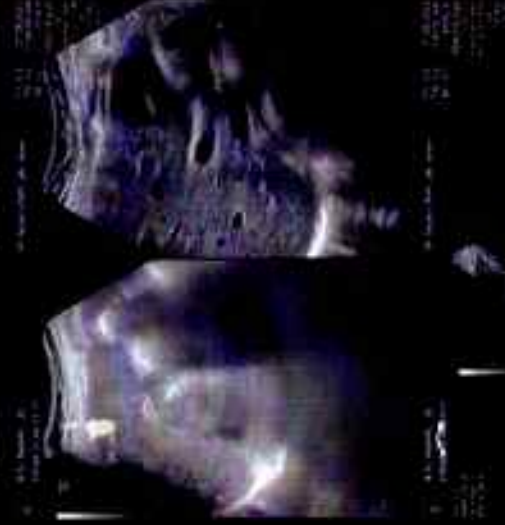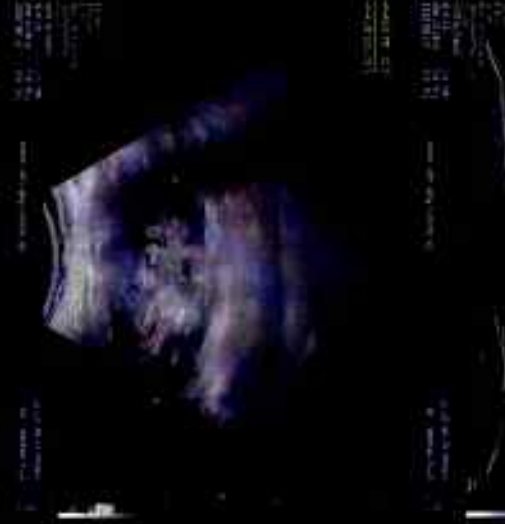
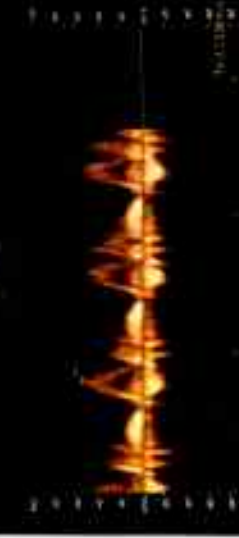
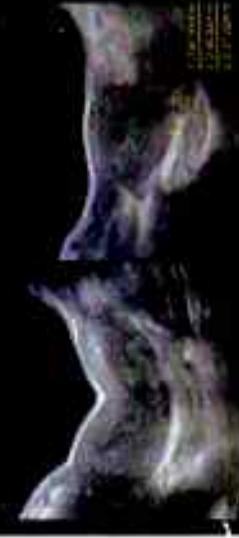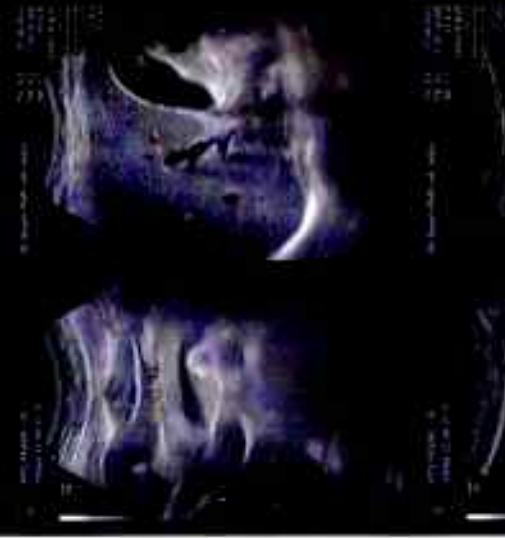

(Cardiologist)

*** End of Report ***

Dr Goyal's Path Lab, Jaipur

Name: RITU PAWAR / F

27 Aug 2022



Dr. Goyal's

Path Lab & Imaging Centre

B-51, Ganesha Nagar, Opp. Janpath Corner, New Sanganer Road, Jaipur - 302019
Tele : 0141-2293346, 4049707, 9887049787
Website : www.drgoyalpathlab.com | E-mail : drgoyalpiyush@gmail.com



Date :- 27/08/2022 09:08:35
NAME :- Mrs. RITU PAWAR
Sex / Age :- Female 26 Yrs
Company :- MediWheel

Patient ID :- 12221896
Ref. By Dr.- BOB
Lab/Hosp :-



Sample Type :- EDTA

Sample Collected Time 27/08/2022 10:00:28

Final Authentication : 27/08/2022 13:30:48

HAEMATOLOGY

Test Name	Value	Unit	Biological Ref Interval
BOB PACKAGE FEMALE BELOW 40			
HAEMOGARAM			
HAEMOGLOBIN (Hb)	11.1 L	g/dL	12.0 - 15.0
TOTAL LEUCOCYTE COUNT	6.72	/cumm	4.00 - 10.00
DIFFERENTIAL LEUCOCYTE COUNT			
NEUTROPHIL	57.0	%	40.0 - 80.0
LYMPHOCYTE	37.7	%	20.0 - 40.0
EOSINOPHIL	2.1	%	1.0 - 6.0
MONOCYTE	2.9	%	2.0 - 10.0
BASOPHIL	0.3	%	0.0 - 2.0
NEUT#	3.84	10 ³ /uL	1.50 - 7.00
LYMPH#	2.53	10 ³ /uL	1.00 - 3.70
EO#	0.14	10 ³ /uL	0.00 - 0.40
MONO#	0.19	10 ³ /uL	0.00 - 0.70
BASO#	0.02	10 ³ /uL	0.00 - 0.10
TOTAL RED BLOOD CELL COUNT (RBC)	4.81 H	x10 ⁶ /uL	3.80 - 4.80
HEMATOCRIT (HCT)	35.10 L	%	36.00 - 46.00
MEAN CORP VOLUME (MCV)	72.9 L	fL	83.0 - 101.0
MEAN CORP HB (MCH)	23.1 L	pg	27.0 - 32.0
MEAN CORP HB CONC (MCHC)	31.7	g/dL	31.5 - 34.5
PLATELET COUNT	275	x10 ³ /uL	150 - 410
RDW-CV	15.9 H	%	11.6 - 14.0
MENTZER INDEX	15.16		

The Mentzer index is used to differentiate iron deficiency anemia from beta thalassemia trait. If a CBC indicates microcytic anemia, these are two of the most likely causes, making it necessary to distinguish between them.

If the quotient of the mean corpuscular volume divided by the red blood cell count is less than 13, thalassemia is more likely. If the result is greater than 13, then iron-deficiency anemia is more likely.

AJAYSINGH
Technologist

Page No: 1 of 12



Dr. Rashmi Bakshi
MBBS, MD (Path)
RMC No. 17975/008828

Dr. Goyal's

Path Lab & Imaging Centre

B-51, Ganesh Nagar, Opp. Janpath Corner, New Sanganer Road, Jaipur - 302019
Tele : 0141-2293346, 4049787, 9887049787
Website : www.dr.goyalspathlab.com | E-mail : dr.goyalpiyush@gmail.com



Date :- 27/08/2022 09:08:35

Patient ID :- 12221896

NAME :- Mrs. RITU PAWAR

Ref. By Dr- BOB

Sex / Age :- Female 26 Yrs

Lab/Hosp :-

Company :- MediWheel



Sample Type :- EDTA

Sample Collected Time 27/08/2022 10:00:28

Final Authentication : 27/08/2022 12:30:48

HAEMATOLOGY

Test Name	Value	Unit	Biological Ref Interval
Erythrocyte Sedimentation Rate (ESR)	12	mm/hr.	00 - 20

(ESR) Methodology : Measurement of ESR by cells aggregation.

Instrument Name : Independent form Hematocrit value by Automated Analyzer (Roller-20)

Interpretation : ESR test is a non-specific indicator of inflammatory disease and abnormal protein states.

The test is used to detect, follow course of a certain disease (e.g. tuberculosis, rheumatic fever, myocardial infarction)

Levels are higher in pregnancy due to hyperfibrinogenaemia.

The "3-figure ESR" $\times >100$ value nearly always indicates serious disease such as a serious infection, malignant paraproteinaemia.

(CBC) Methodology : CBC, DLC, Fluorescent Flow cytometry, HB SLS method, TRBC, PCV, PLT Hydrodynamically focused Impedance, and

MCH, MCV, MCHC, MENTZER INDEX are calculated. Instrument Name: Sysmex 6 part fully automatic analyzer XN-L, Japan

AJAYSINGH
Technologist

Page No: 2 of 12



Dr. Rashmi Bakshi
MBBS, MD (Path)
RMC No, 17975/008828



Date :- 27/08/2022 09:08:35

Patient ID :- 12221896

NAME :- Mrs. RITU PAWAR

Ref. By Dr.- BOB

Sex / Age :- Female 26 Yrs.

Lab/Hosp :-

Company :- MedWheel



Sample Type :- EDTA, K₂Ox/Na FLUORIDE-F, LSANBLE Collected Time 27/08/2022 10:00:28

Final Authentication : 27/08/2022 13:30:48

HAEMATOLOGY

Test Name	Value	Unit	Biological Ref Interval
-----------	-------	------	-------------------------

BLOOD GROUP ABO

B POSITIVE

BLOOD GROUP ABO Methodology : Haemagglutination reaction Kit Name : Monoclonal agglutinating antibodies (Span clone)

FASTING BLOOD SUGAR (Plasma)

87.0

mg/dl

75.0 - 115.0

Method:- GOD-PAP

Impaired glucose tolerance (IGT)

111 - 125 mg/dL

Diabetes Mellitus (DM)

> 126 mg/dL

Instrument Name: Randox Rs Imola Interpretation: Elevated glucose levels (hyperglycemia) may occur with diabetes, pancreatic neoplasm, hyperthyroidism and adrenal cortical hyper-function as well as other disorders. Decreased glucose levels (hypoglycemia) may result from excessive insulin therapy or various liver diseases.

URINE SUGAR (FASTING)
Collected Sample Received

Nil

Nil

AJAYSINGH, SKSHARMA, SURENDRAMEENA
Technologist

Page No: 3 of 12



Dr. Rashmi Bakshi
MBBS, MD (Path)
RMC No. 17975/008828
Dr. Chandrika Gupta

Dr. Goyal's

Path Lab & Imaging Centre

B-51, Ganesh Nagar, Opp. Janpath Corner, New Sangoner Road, Jaipur - 302019
Tele : 0141-2293346, 4049787, 9887049787
Website : www.drgoyalspathlab.com | E-mail : drgoyalpiyush@gmail.com



Date :- 27/08/2022 09:08:35

Patient ID :- 12221896

NAME :- Mrs. RITU PAWAR

Ref. By Dr.- BOB

Sex / Age :- Female 26 Yrs

Lab/Hosp :-

Company :- MediWheel



Sample Type :- STOOL

Sample Collected Time 27/08/2022 10:00:28

Final Authentication : 27/08/2022 12:54:12

CLINICAL PATHOLOGY

Test Name	Value	Unit	Biological Ref Interval
STOOL ANALYSIS			
PHYSICAL EXAMINATION			
MUCUS			
BLOOD			
MICROSCOPIC EXAMINATION			
RBCs		/HPF	
WBC/HPF		/HPF	
OVA			
CYSTS			
OTHERS			
Collected Sample Received			

SURENDRAMEENA
Technologist

Page No: 4 of 12



Dr. Chandrika Gupta
MBBS,MD (Path)
RMC NO. 21021/008037

Dr. Goyal's

Path Lab & Imaging Centre

B-51, Ganesh Nagar, Opp. Janpath Corner, New Sanganer Road, Jaipur-302019
 Tele : 0141-2293346, 4049787, 9887649787
 Website : www.dr.goyalpathlab.com | E-mail : drgoyalpiyush@gmail.com



Date :- 27/08/2022 09:08:35 Patient ID :- 12221896
NAME :- Mrs. RITU PAWAR Ref. By Dr:- BOB
 Sex / Age :- Female 26 Yrs Lab/Hosp :-
 Company :- Med/Wheel



Sample Type :- PLAIN/SERUM Sample Collected Time 27/08/2022 10:00:28 Final Authentication : 27/08/2022 11:06:15

BIOCHEMISTRY

Test Name	Value	Unit	Biological Ref Interval
LIPID PROFILE			
TOTAL CHOLESTEROL Method:- Enzymatic Endpoint Method	188.00	mg/dl	Desirable <200 Borderline 200-239 High > 240
TRIGLYCERIDES Method:- GPO-PAP	67.46	mg/dl	Normal <150 Borderline high 150-199 High 200-499 Very high >500
DIRECT HDL CHOLESTEROL Method:- Direct clearance Method	48.36	mg/dl	Low < 40 High > 60
DIRECT LDL CHOLESTEROL Method:- Direct clearance Method	128.40	mg/dl	Optimal <100 Near Optimal/above optimal 100-129 Borderline High 130-159 High 160-189 Very High > 190
VLDL CHOLESTEROL Method:- Calculated	13.49	mg/dl	0.00 - 80.00
T. CHOLESTEROL/HDL CHOLESTEROL RATIO Method:- Calculated	3.89		0.00 - 4.90
LDL / HDL CHOLESTEROL RATIO Method:- Calculated	2.66		0.00 - 3.50
TOTAL LIPID Method:- CALCULATED	511.66	mg/dl	400.00 - 1000.00
<small>TOTAL CHOLESTEROL InstrumentName: Randox Rx Imola Interpretation: Cholesterol measurements are used in the diagnosis and treatment of lipid dysprotein metabolism disorders.</small>			
<small>TRIGLYCERIDES InstrumentName: Randox Rx Imola Interpretation: Triglyceride measurements are used in the diagnosis and treatment of diseases involving lipid metabolism and various endocrine disorders e.g. diabetes mellitus, nephrosis and liver obstruction.</small>			
<small>DIRECT HDL CHOLESTEROL InstrumentName: Randox Rx Imola Interpretation: An inverse relationship between HDL cholesterol (HDL-C) levels in serum and the incidence/prevalence of coronary heart disease (CHD) has been demonstrated in a number of epidemiological studies. Accurate measurement of HDL-C is of vital importance when assessing patient risk from CHD. Direct measurement gives improved accuracy and reproducibility when compared to precipitation methods.</small>			
<small>DIRECT LDL CHOLESTEROL InstrumentName: Randox Rx Imola Interpretation: Accurate measurement of LDL cholesterol is of vital importance in therapies which focus on lipid reduction to prevent atherosclerosis or reduce its progress and to avoid plaque rupture.</small>			
TOTAL LIPID AND VLDL ARE CALCULATED			

SKSHARMA

Page No: 5 of 12



Dr. Rashmi Bakshi
 MBBS, MD (Path)
 RMC No. 17975/068828

Dr. Goyal's

Path Lab & Imaging Centre

B-51, Genesh Nagar, Opp. Jangpeth Corner, New Sangoner Road, Jaipur-302019
 Tele : 0141-2283346, 4049787, 9887049787
 Website : www.dr.goyalpathlab.com | E-mail : dr.goyalpiyush@gmail.com



Date :- 27/08/2022 09:08:35 Patient ID :- 12221898
NAME :- Mrs. RITU PAWAR Ref. By Dr:- BOB
 Sex / Age :- Female 26 Yrs Lab/Hosp :-
 Company :- MediWheel



Sample Type :- PLAIN/SERUM Sample Collected Time 27/08/2022 10:00:28 Final Authentication : 27/08/2022 11:05:15

BIOCHEMISTRY

Test Name	Value	Unit	Biological Ref Interval
LIVER PROFILE WITH GGT			
SERUM BILIRUBIN (TOTAL) Method:- Colorimetric method	0.53	mg/dl	Up to - 1.0 Cord blood <2 mg/dL Premature < 6 days <16mg/dL Full-term < 6 days= 12 mg/dL 1month - <12 months <2 mg/dL 1-19 years <1.5 mg/dL Adult - Up to - 1.2 Ref-(ACCP 2020)
SERUM BILIRUBIN (DIRECT) Method:- Colorimetric Method	0.26	mg/dL	Adult - Up to 0.25 Newborn - <0.6 mg/dL >- 1 month - <0.2 mg/dL
SERUM BILIRUBIN (INDIRECT) Method:- Calculated	0.27	mg/dl	0.30-0.70
SGOT Method:- IFCC	51.9 H	U/L	Men- Up to - 37.0 Women - Up to - 31.0
SGPT Method:- IFCC	86.3 H	U/L	Men- Up to - 40.0 Women - Up to - 31.0
SERUM ALKALINE PHOSPHATASE Method:- AMP Buffer	74.70	IU/L	30.00 - 120.00
SERUM GAMMA GT Method:- IFCC	45.40 H	U/L	7.00 - 32.00
SERUM TOTAL PROTEIN Method:- Biorad Reagent	7.34	g/dl	6.40 - 8.30
SERUM ALBUMIN Method:- Bromocresol Green	4.39	g/dl	3.80 - 5.00
SERUM GLOBULIN Method:- CALCULATION	2.95	gm/dl	2.20 - 3.50
A/G RATIO	1.49		1.30 - 2.50

Total Bilirubin Methodology: Colorimetric method Instrument:Name Random Rx Inits Interpretation: An increase in bilirubin concentration in the serum occurs in toxic or infectious diseases of the liver e.g. hepatitis B or obstruction of the bile duct and in other (non-hepatic) causes. High levels of unconjugated bilirubin indicate that too much haemoglobin is being destroyed or that the liver is not actively treating the haemoglobin it is receiving.

AST Aspartate Aminotransferase Methodology: IFCC Instrument:Name Random Rx Inits Interpretation: Elevated levels of AST can signal myocardial infarction, hepatic disease, muscular dystrophy and organ damage. Although heart muscle is found to have the most activity of the enzyme, significant activity has also been seen in the brain, liver, gastric mucosa, adipose tissue and salivary gland.

ALT Alanine Aminotransferase Methodology: IFCC Instrument:Name Random Rx Inits Interpretation: The enzyme ALT has been found to be in highest concentrations in the liver, with decreasing concentrations found in kidney, heart, skeletal muscle, pancreas, spleen and lung tissue respectively. Elevated levels of the transaminase can indicate myocardial infarction, hepatic disease, muscular dystrophy and organ damage.

Alkaline Phosphatase Methodology: AMP Buffer Instrument:Name Random Rx Inits Interpretation: Measurements of alkaline phosphatase are of use in the diagnosis, treatment and investigation of hepatobiliary disease and in bone disease associated with increased osteoblastic activity. Alkaline phosphatase is also used in the diagnosis of parathyroid and intestinal disease.

TOTAL PROTEIN Methodology: Biorad Reagent Instrument:Name Random Rx Inits Interpretation: Measurements obtained by this method are used in the diagnosis and treatment of a variety of diseases involving the liver, kidney and bone marrow as well as other metabolic or nutritional disorders.

ALBUMIN (ALB) Methodology: Bromocresol Green Instrument:Name Random Rx Inits Interpretation: Albumin measurements are used in the diagnosis and treatment of various diseases involving

SKSHARMA

Page No: 6 of 12



Rashmi

Dr. Rashmi Bakshi
 MBBS, MD (Path)
 RMC No. 17975/008828

Dr. Goyal's

Path Lab & Imaging Centre

B-51, Ganesh Nagar, Opp. Janpath Corner, New Sanganer Road, Jaipur - 302019
Tele : 0141-2293346, 4049787, 9887049787
Website : www.drgoyalpathlab.com | E-mail : drgoyalpiyush@gmail.com



Date :- 27/08/2022 09:08:35

Patient ID :- 12221896

NAME :- Mrs. RITU PAWAR

Ref. By Dr- BOB

Sex / Age :- Female 26 Yrs

Lab/Hosp :-

Company :- Med/Wheel



Sample Type :- PLAIN/SERUM

Sample Collected Time 27/08/2022 10:00:28

Final Authentication : 27/08/2022 11:08:15

BIOCHEMISTRY

Test Name	Value	Unit	Biological Ref Interval
-----------	-------	------	-------------------------

primarily the liver or kidneys. Glucose & A/G ratio is not valid

Instrument Name: Random Six Levels. **Interpretation:** Elevations in GGT levels across culture and more pronounced than those with other liver enzymes in cases of obstructive jaundice and alcoholic consumption. It may reach 7 to 82 times normal levels in extreme post-hepatic (biliary) obstruction. Only moderate elevations in the enzyme level (2 to 3 times normal) are observed with infectious hepatitis.

SKSHARMA

Page No: 7 of 12



Dr. Rashmi Bakshi
MBBS, MD (Path)
RMC No. 17975/008828

Dr. Goyal's

Path Lab & Imaging Centre

B-51, Ganesha Nagar, Opp. Janpath Corner, New Sanganer Road, Jaipur - 302019
Tele : 0141-2293346, 4049787, 9887049787
Website : www.dr.goyal'spathlab.com | E-mail : dr.goyalpiyush@gmail.com



Date :- 27/08/2022 09:08:35

NAME :- Mrs. RITU PAWAR

Sex / Age :- Female 28 Yrs

Company :- MediWheel

Patient ID :- 12221896

Ref. By Dr. :- BOB

Lab/Hosp :-



Sample Type :- PLAIN/SERUM

Sample Collected Time 27/08/2022 10:00:28


Final Authentication :- 27/08/2022 11:08:15

BIOCHEMISTRY

Test Name	Value	Unit	Biological Ref Interval
SERUM CREATININE Method:- Colorimetric Method	0.94	mg/dl	Men - 0.6-1.30 Women - 0.5-1.20
SERUM URIC ACID Method:- Enzymatic colorimetric	3.65	mg/dl	Men - 3.4-7.0 Women - 2.4-5.7

SKSHARMA

Page No: 8 of 12



Dr. Rashmi Bakshi
MBBS, MD (Path)
RMC No. 17975/008828

Dr. Goyal's

Path Lab & Imaging Centre

B-51, Ganesh Nagar, Opp. Jangpath Corner, New Sangner Road, Jaipur - 302018
Tele : 0141-2293346, 4049787, 9887049787
Website : www.drgoyalpathlab.com | E-mail : drgoyalpiyush@gmail.com



Date :- 27/08/2022 09:08:35

Patient ID :- 12221896

NAME :- Mrs. RITU PAWAR

Ref. By Dr:- BOB

Sex / Age :- Female 26 Yrs

Lab/Hosp :-

Company :- Med/Wheel



Sample Type :- PLAIN/SERUM

Sample Collected Time 27/08/2022 10:00:28

Final Authentication : 27/08/2022 11:06:15

BIOCHEMISTRY

Test Name	Value	Unit	Biological Ref Interval
BLOOD UREA NITROGEN (BUN)	11.0	mg/dl	0.0 - 23.0

SKSHARMA

Page No: 9 of 12



Dr. Rashmi Bakshi
MBBS, MD (Path)
RMC No, 17975/008828

Dr. Goyal's

Path Lab & Imaging Centre

B-51, Ganesh Nagar, Opp. Janpath Corner, New Sanganer Road, Jaipur - 302019
Tele : 0141-2293346, 4049787, 9887049787
Website : www.dr.goyalpathlab.com | E-mail : dr.goyalpiyush@gmail.com



Date :- 27/08/2022 09:08:35
NAME :- Mrs. RITU PAWAR
Sex / Age :- Female 26 Yrs.
Company :- MediWheel

Patient ID :- 12221896
Ref. By Dr:- BOB
Lab/Hosp :-



Sample Type :- EDTA

Sample Collected Time 27/08/2022 10:00:28

Final Authentication : 27/08/2022 13:30:48

HAEMATOLOGY

Test Name	Value	Unit	Biological Ref Interval
-----------	-------	------	-------------------------

GLYCOSYLATED HEMOGLOBIN (HbA1C)
Method:- HPLC

5.9

%

Non-diabetic: < 5.7
Pre-diabetics: 5.7-6.4
Diabetics: ≥ 6.5 or higher
AOA Target: 7.0
Action suggested: > 6.5

Instrument name: ARKRAY's ADAMS Lite HA 8380V, JAPAN

Test Interpretation:

HbA1C is formed by the condensation of glucose with n-terminal valine residue of each beta chain of HbA to form an unstable Schiff base. It is the major fraction, constituting approximately 80% of HbA1c. Formation of glycated hemoglobin (GHb) is essentially irreversible and the concentration in the blood depends on both the lifespan of the red blood cells (RBC) (120 days) and the blood glucose concentration. The GHb concentration represents the integrated values for glucose over the period of 6 to 8 weeks. GHb values are free of day to day glucose fluctuations and are unaffected by recent exercise or food ingestion. Concentration of plasma glucose concentration in GHb depends on the time interval, with more recent values providing a larger contribution than earlier values. The interpretation of GHb depends on RBC having a normal life span. Patients with hemolytic disease or other conditions with shortened RBC survival exhibit a substantial reduction of GHb. High GHb have been reported in iron deficiency anemia. GHb has been firmly established as an index of long term blood glucose concentrations and as a measure of the risk for the development of complications in patients with diabetes mellitus. The absolute risk of retinopathy and nephropathy are directly proportional to the mean of HbA1C. Genetic variants (e.g. HbS trait, HbC trait), elevated HbF and chemically modified derivatives of hemoglobin can affect the accuracy of HbA1c measurements. The effects vary depending on the specific Hb variant or derivative and the specific HbA1c method.

Ref by ADA 2020

MEAN PLASMA GLUCOSE
Method:- Calculated Parameter

123

mg/dL

Non Diabetic < 100 mg/dL
Prediabetic 100- 125 mg/dL
Diabetic ≥ 126 mg/dL or Higher

AJAYSINGH
Technologist

Page No. 10 of 12



Dr. Rashmi Bakshi
MBBS, MD (Path)
RMC No. 17975/008828

Dr. Goyal's

Path Lab & Imaging Centre

B-51, Ganesh Nagar, Opp. Janpath Corner, New Sanganer Road, Jaipur - 302019
Tele : 0141-2293346, 4049787, 9887049787
Website : www.dr.goyalspathlab.com | E-mail : dr.goyalpiyush@gmail.com



Date :- 27/08/2022 09:08:35
NAME :- Mrs. RITU PAWAR
Sex / Age :- Female 26 Yrs
Company :- MediWheel

Patient ID :- 12221896
Ref. By Dr.- BOB
Lab/Hosp :-



Sample Type :- URINE

Sample Collected Time 27/08/2022 10:00:28

Final Authentication : 27/08/2022 12:54:12

CLINICAL PATHOLOGY

Test Name	Value	Unit	Biological Ref Interval
Urine Routine			
<u>PHYSICAL EXAMINATION</u>			
COLOUR	PALE YELLOW		PALE YELLOW
APPEARANCE	Clear		Clear
<u>CHEMICAL EXAMINATION</u>			
REACTION(PH)	6.0		5.0 - 7.5
SPECIFIC GRAVITY	1.020		1.010 - 1.030
PROTEIN	NIL		NIL
SUGAR	NIL		NIL
BILIRUBIN	NEGATIVE		NEGATIVE
UROBILINOGEN	NORMAL		NORMAL
KETONES	NEGATIVE		NEGATIVE
NITRITE	NEGATIVE		NEGATIVE
<u>MICROSCOPY EXAMINATION</u>			
RBC/HPF	NIL	/HPF	NIL
WBC/HPF	2-3	/HPF	2-3
EPITHELIAL CELLS	2-3	/HPF	2-3
CRYSTALS/HPF	ABSENT		ABSENT
CAST/HPF	ABSENT		ABSENT
AMORPHOUS SEDIMENT	ABSENT		ABSENT
BACTERIAL FLORA	ABSENT		ABSENT
YEAST CELL	ABSENT		ABSENT
OTHER	ABSENT		ABSENT

SURENDRAMEENA
Technologist

Page No: 11 of 12



Dr. Chandrika Gupta
MBBS,MD (Path)
RMC NO. 21021/008037

Dr. Goyal's

Path Lab & Imaging Centre

B-51, Ganesh Nagar, Opp. Jangpath Corner, New Sangmer Road, Jaipur - 302015
 Tele : 0141-2293346, 4049787, 9887049787
 Website : www.dr.goyalpathlab.com | E-mail : dr.goyalpiyush@gmail.com



Date :- 27/08/2022 09:08:35 Patient ID :- 12221896
NAME :- Mrs. RITU PAWAR Ref. By Dr.- BOB
 Sex / Age :- Female 26 Yrs. Lab/Hosp :-
 Company :- MediWheel



Sample Type :- PLAIN/SERUM Sample Collected Time 27/08/2022 10:00:28 Final Authentication : 27/08/2022 11:38:06

IMMUNOASSAY

Test Name	Value	Unit	Biological Ref Interval
TOTAL THYROID PROFILE			
SERUM TOTAL T3 Method:- Chemiluminescence(Competitive immunoassay)	1.320	ng/ml	0.600 - 1.810
SERUM TOTAL T4 Method:- Chemiluminescence(Competitive immunoassay)	8.250	ug/dl	4.500 - 10.900
SERUM TSH ULTRA Method:- Enhanced Chemiluminescence Immunoassay	2.940	µIU/mL	0.500 - 6.880

Interpretation: Triiodothyronine (T3) contributes to the maintenance of the euthyroid state. A decrease in T3 concentration of up to 50% occurs in a variety of clinical situations, including acute and chronic disease. Although T3 results alone cannot be used to diagnose hypothyroidism, T3 concentration may be more sensitive than thyroxine (T4) for hyperthyroidism. Consequently, the total T3 assay can be used in conjunction with other assays to aid in the differential diagnosis of thyroid disease. T3 concentrations may be altered in some conditions, such as pregnancy, that affect the capacity of the thyroid hormone-binding proteins. Under such conditions, Free T3 can provide the best estimate of the metabolically active hormone concentration. Alternatively, T3 uptake, or T4 uptake can be used with the total T3 result to calculate the free T3 index and estimate the concentration of free T3.

Interpretation: The measurement of Total T4 aids in the differential diagnosis of thyroid disease. While >99.9% of T4 is protein-bound, primarily to thyroxine-binding globulin (TBG), it is the free fraction that is biologically active. In most patients, the total T4 concentration is a good indicator of thyroid status. T4 concentrations may be altered in some conditions, such as pregnancy, that affect the capacity of the thyroid hormone-binding proteins. Under such conditions, free T4 can provide the best estimate of the metabolically active hormone concentration. Alternatively, T3 uptake may be used with the total T4 result to calculate the free T4 index (FT4I) and estimate the concentration of free T4. Some drugs and some nonthyroidal patient conditions are known to alter T4 concentrations in vivo.

Interpretation: TSH stimulates the production of thyroxine (T4) and triiodothyronine (T3) by the thyroid gland. The diagnosis of overt hypothyroidism by the finding of a low total T4 or free T4 concentration is readily confirmed by a raised TSH concentration. Measurement of low or undetectable TSH concentrations may assist the diagnosis of hyperthyroidism, where concentrations of T4 and T3 are elevated and TSH secretion is suppressed. These have the advantage of discriminating between the concentrations of TSH observed in thyrotoxicosis, compared with the low, but detectable, concentrations that occur in subclinical hyperthyroidism. The performance of this assay has not been established for neonatal specimens. Some drugs and some nonthyroidal patient conditions are known to alter TSH concentrations in vivo.

INTERPRETATION

PREGNANCY	REFERENCE RANGE FOR TSH IN µIU/mL (As per American Thyroid Association)
1st Trimester	0.10-2.50
2nd Trimester	0.20-3.00
3rd Trimester	0.30-3.00

*** End of Report ***

C.L.SAINI
Technologist

Page No. 12 of 12



Dr. Chandrika Gupta
 MBBS,MD (Path)
 RMC NO. 21021/008037