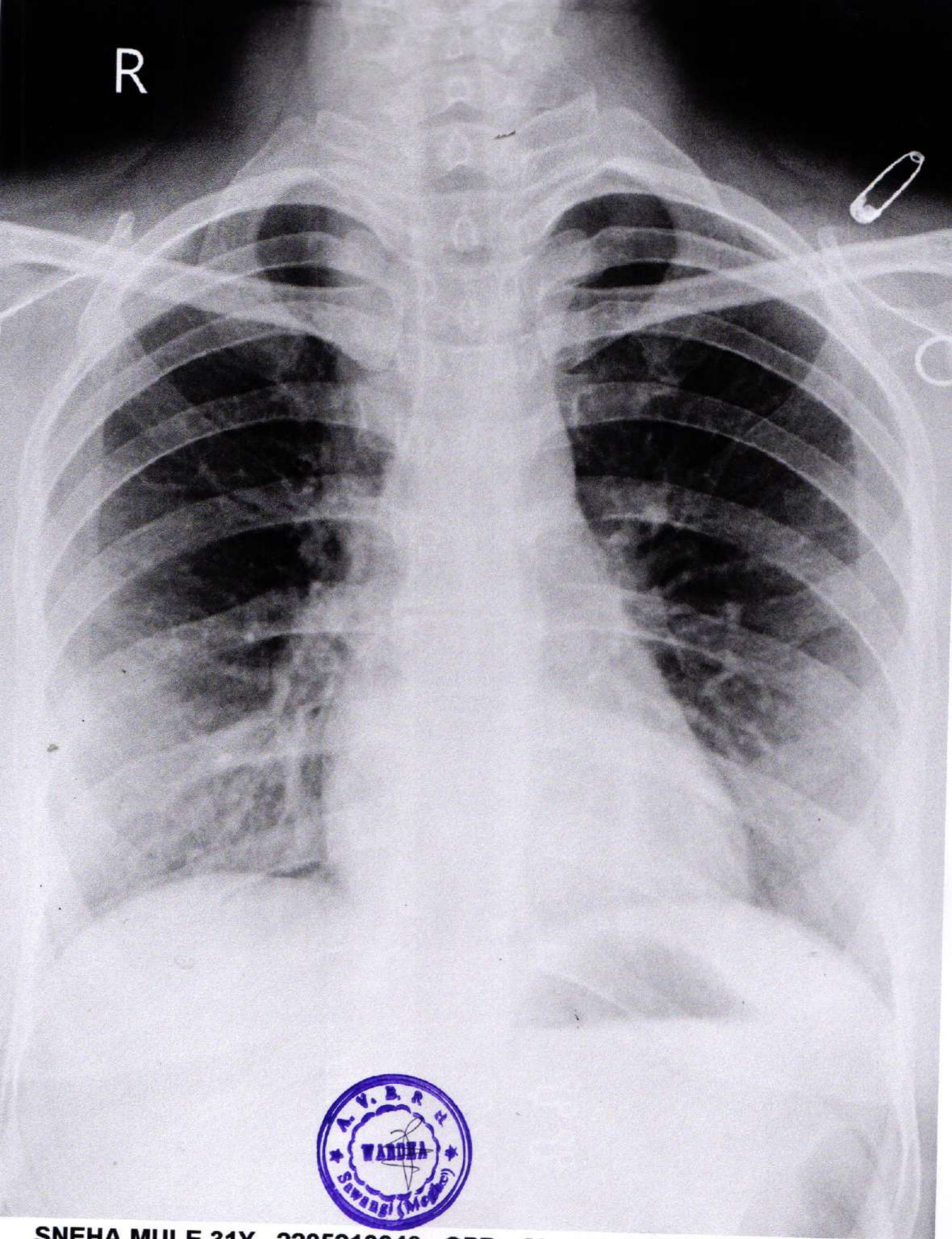


R



**SNEHA MULE 31Y 2205210048 OPD Chest PA/AP-REALISM
21/05/2022**

Acharya Vinoba Bhave Rural hospital, Sawangi (Meghe)



Datta Meghe Institute of Medical Sciences (Deemed to be University) NAAC Grade A+

ACHARYA VINOBA BHAVE RURAL HOSPITAL

Transforming Lives Through Well Being



A Teaching Hospital of Jawaharlal Nehru Medical College, Sawangi (Meghe), WARDHA-442 004

Ph. : 07152-287701 - 06, 304000 Ext. 342 Visit us at : www.avbrhsawangimeghe.com Email : info@avbrhsawangimeghe.com

DEPARTMENT OF RADIODIAGNOSIS

NAME:	SNEHA MULE 31Y	AGE & SEX:	& F
REG. NO.:	2205210048	DATE:	21-May-2022
REFERRED BY:			

Radiogram of chest

- Lung fields do not show any parenchymal abnormality.
- Hila appear normal. No adenopathy noted.
- Cardiac silhouette appears normal.
- Diaphragmatic outline and bilateral costophrenic angles are clear.
- The visualised soft tissues are normal.
- Bony cage is normal.

Impression: No obvious pleuroparenchymal abnormality.

DR R P DHANDE
PROF AND HOD
RADIODIAGNOSIS

Date: 21-May-2022 11:18:44

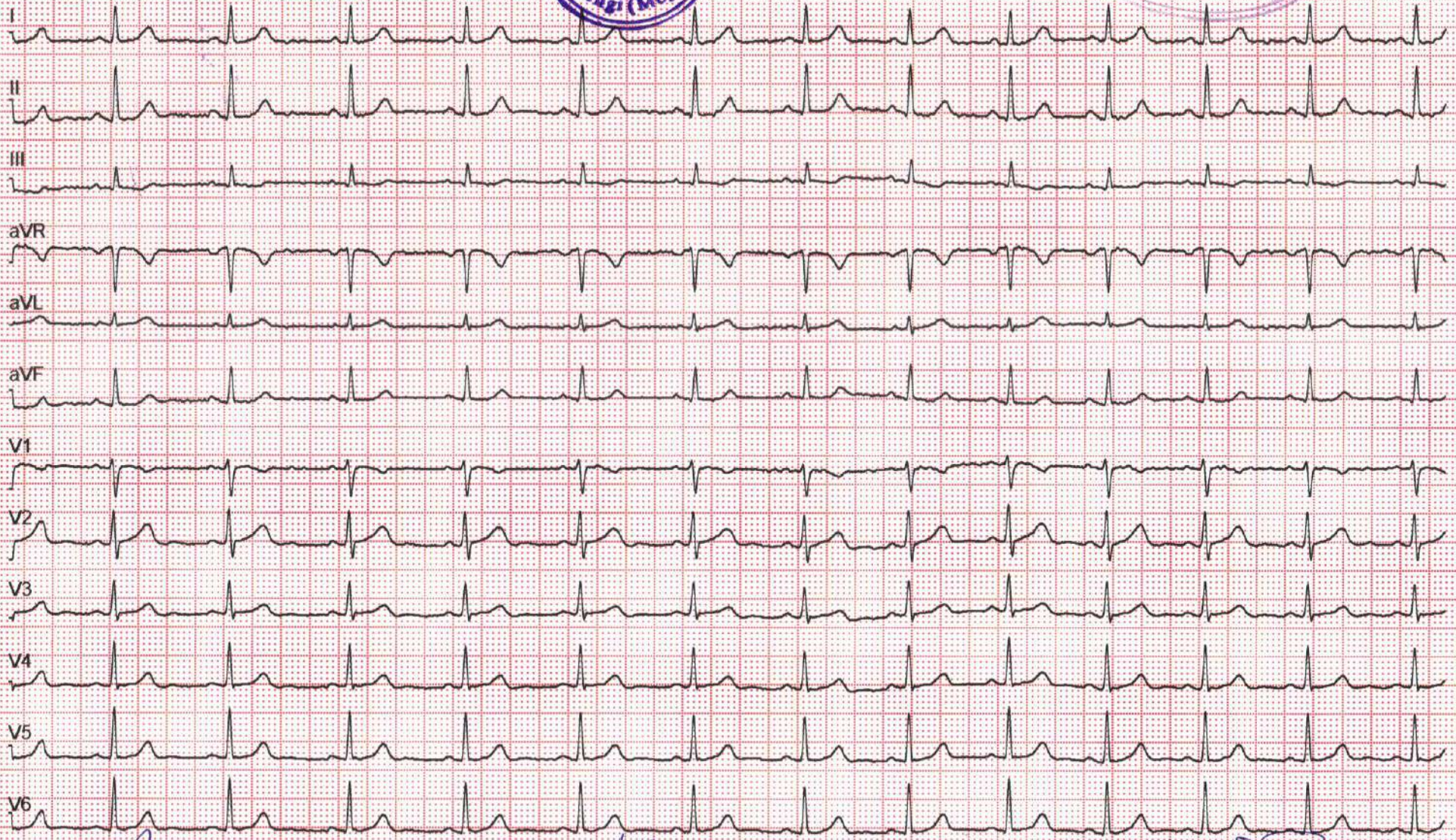


Female
Dr. Anuj Verma
MBBS, MD (Medicine)
Reg. No. MCI 09 / 34884
Acharya Vinoba Bhave Rural Hospital
Sawangi (Meghe), WARDHA

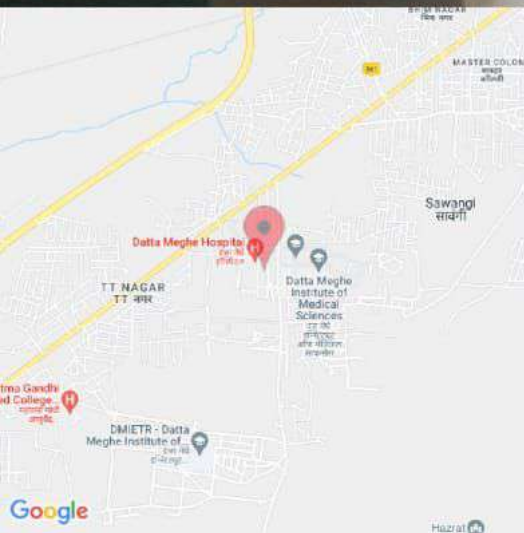
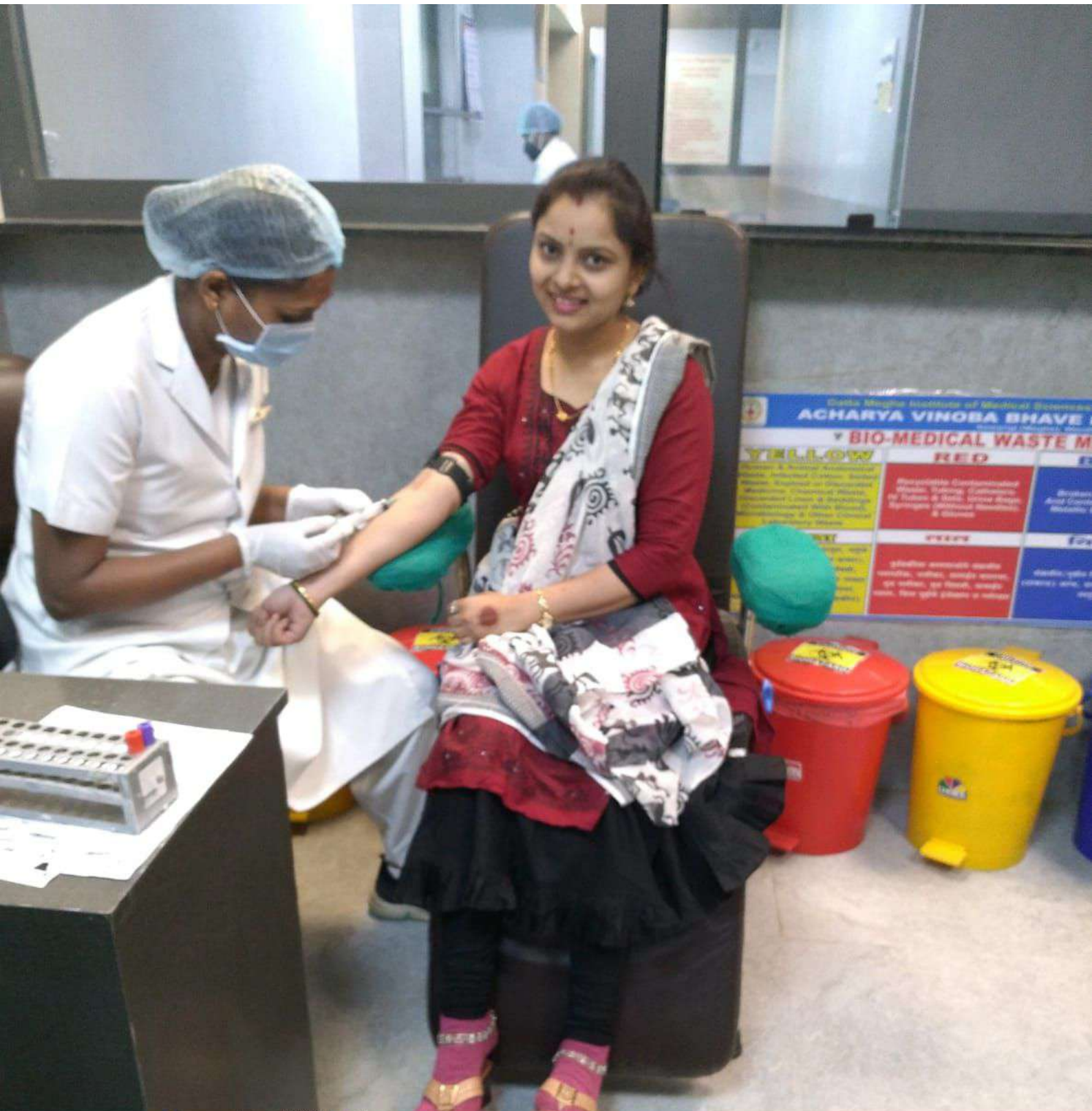
Sate Amule

2205210048
21/05/22



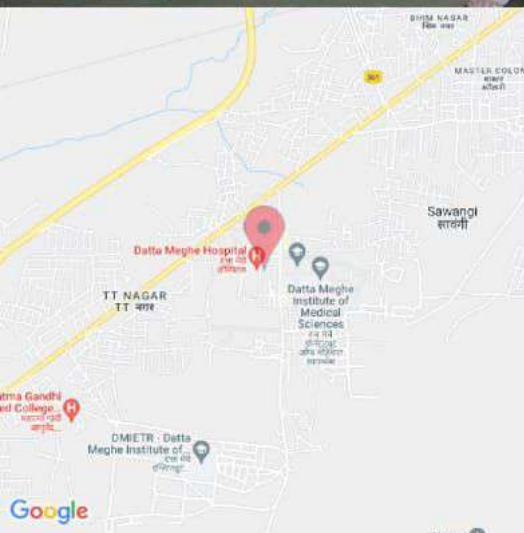** Reporting & ECG within Normal limit* Unconfirmed



PH7F+W85, Sawangi, Maharashtra 442001, India

Sawangi
Maharashtra
India

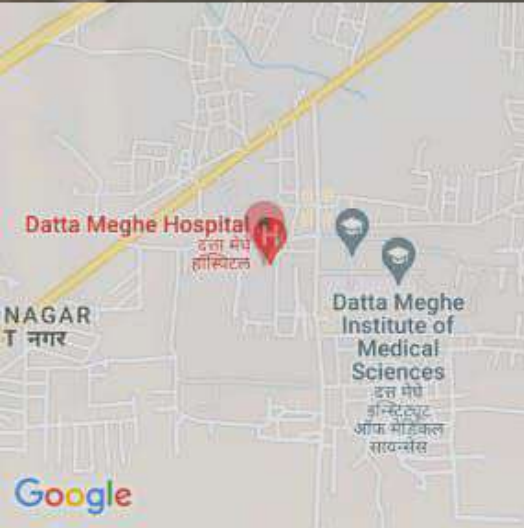2022-05-21(Sat) 10:14



AVBRH Complex, Sawangi Meghe, Wardha, Maharashtra 442001, India

Wardha
Maharashtra
India

2022-05-21(Sat) 11:07



PH7F+W4R, Sawangi, Maharashtra 442001, India

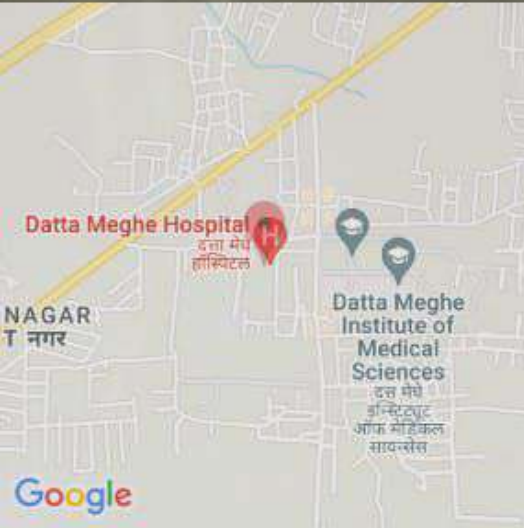Sawangi
Maharashtra
India



40°C

104°F

2022-05-21(Sat) 11:54(am)



PH7F+W4R, Sawangi, Maharashtra 442001, India

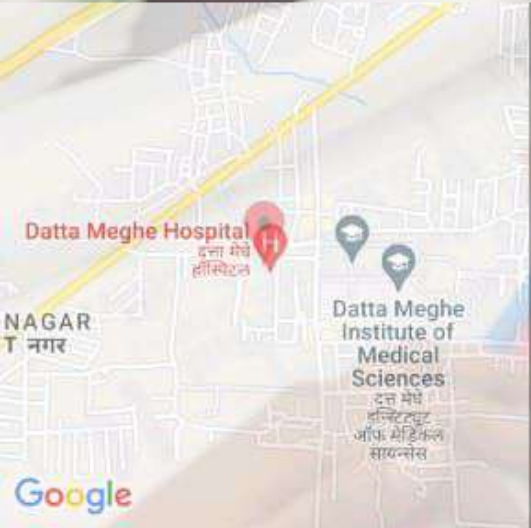Sawangi
Maharashtra
India



40°C

104°F

2022-05-21(Sat) 11:55(am)



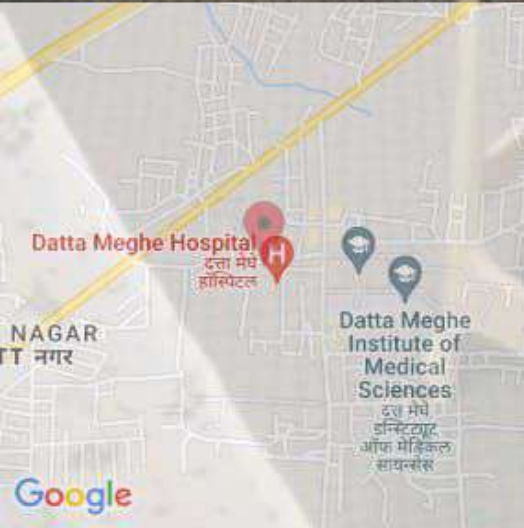
Near Sawangi Meghe Hospital, beside A.G. House, Sawangi, Maharashtra 442001, India

Sawangi
Maharashtra
India



41°C
106°F

2022-05-21(Sat) 12:10(pm)



PH8F+852, Sawangi, Maharashtra 442001, India

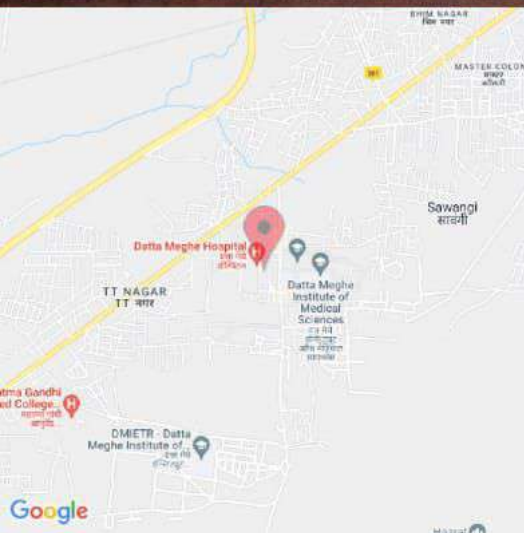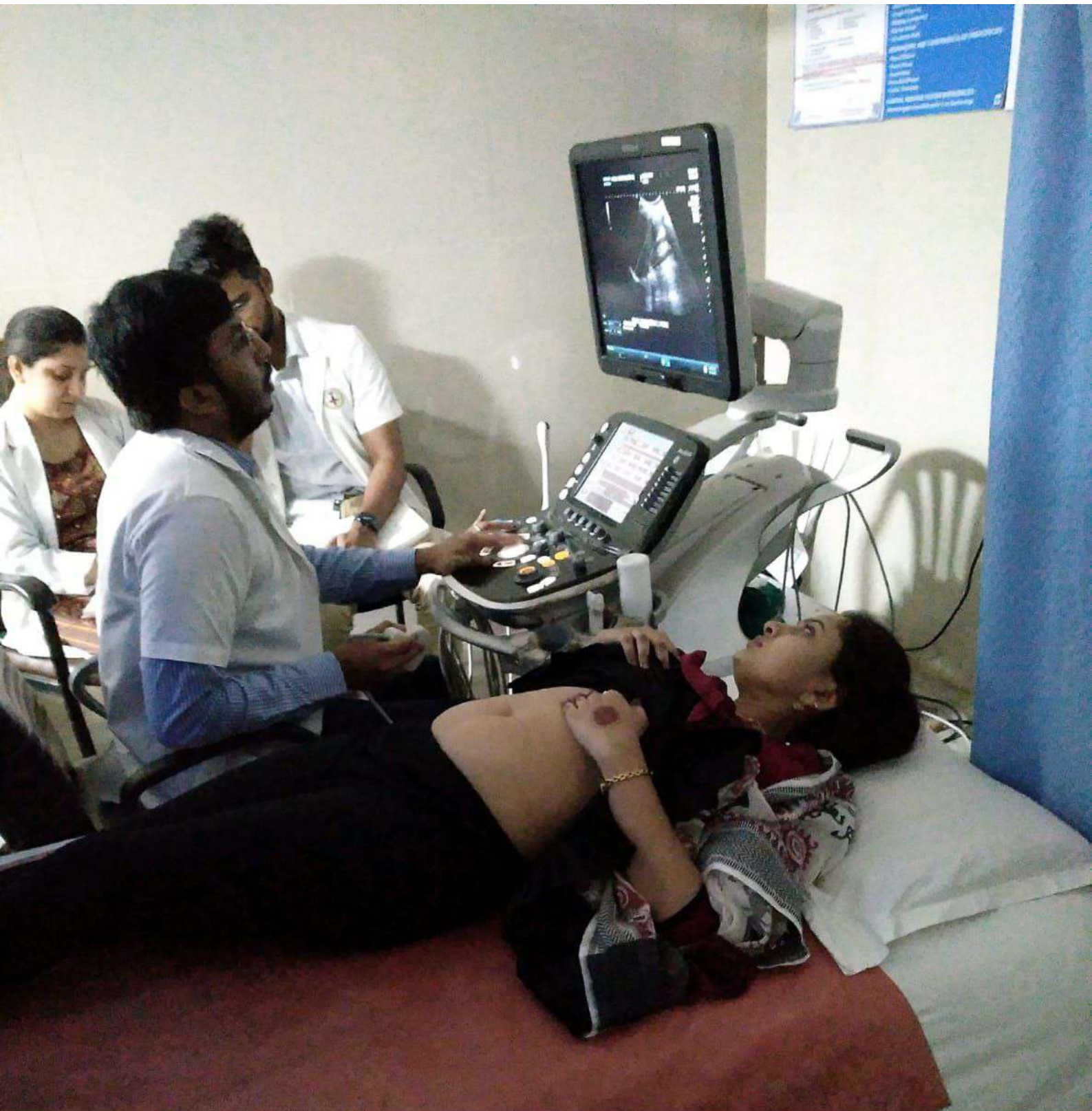Sawangi
Maharashtra
India



41°C

106°F

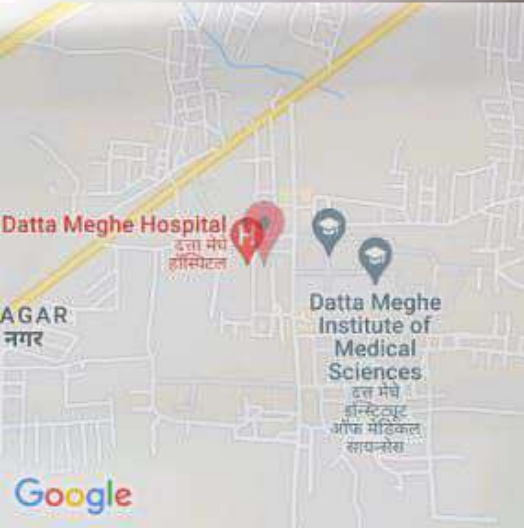2022-05-21(Sat) 01:10(pm)



PH7F+W85, Sawangi, Maharashtra 442001, India

Sawangi
Maharashtra
India

2022-05-21(Sat) 11:23



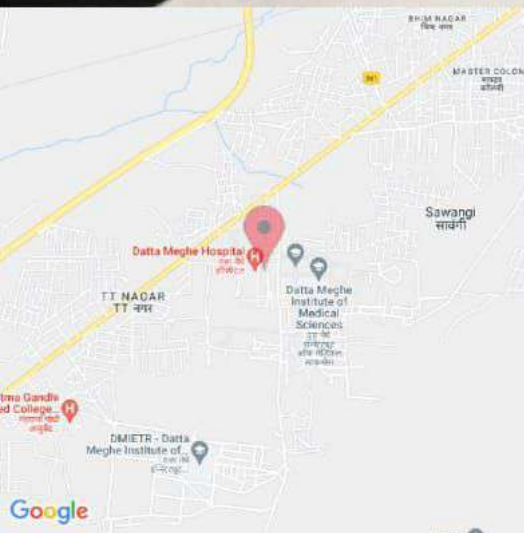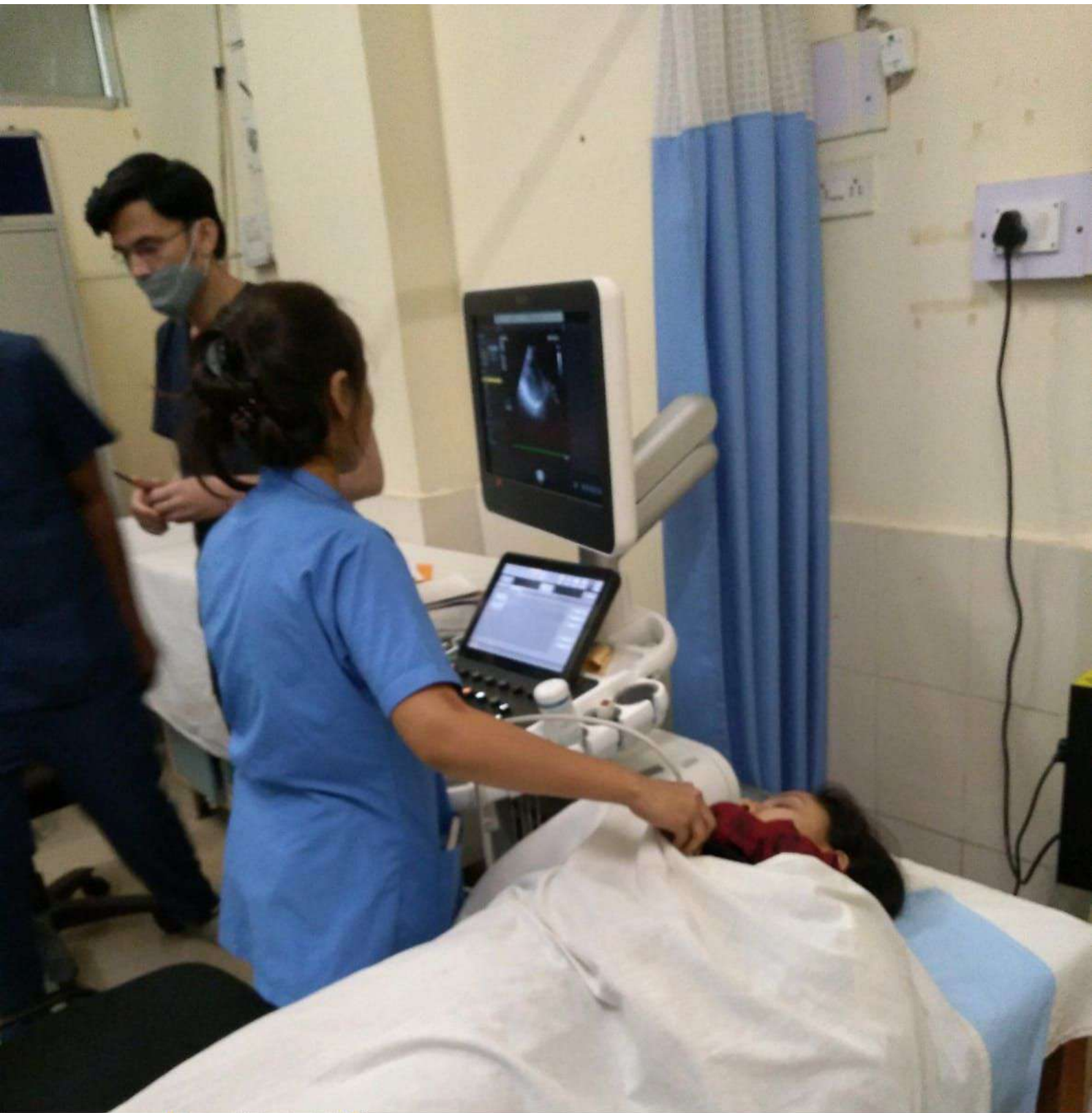
AVBAH Complex, Sawangi Meghe, Wardha, Maharashtra 442001, India

Wardha
Maharashtra
India



41°C
106°F

2022-05-21(Sat) 12:27(pm)



AVBRH Complex, Sawangi Meghe, Wardha, Maharashtra 442001, India

Wardha
Maharashtra
India

2022-05-21(Sat) 13:45

NATIONAL AIDS CONTROL ORGANIZATION

Laboratory Test Report form for HCTS Confirmatory facility

Name & Address of the SA-ICTC: J N M C Sawangi M) WardhaName: Surname Mule Middle Name Poozulla First Name SnehaGender: Male Female Transgender Age: 30 (years)PID No.: SC/SAICTCMHWDH003 22-01650 Lab ID No.: _____Date & Time of Blood Drawn: 21.5.22 (DD/MM/YY) _____ (HH:MM)

Test Details:

- Specimen type used for testing (tick one): Serum / Plasma / Whole Blood
- Date & Time of specimen tested: 21.5.22 (DD/MM/YY) 2pm (HH:MM)

Note:

- Column 2 and 3 to be filled only when HIV 1 & 2 antibody discriminatory test(s) used
- No cell has to be left blank; indicate as NA wherever not applicable

Column 1	Column 2	Column 3	Column 4
Name of the HIV kit	Reactive/Nonreactive (R/NR) for HIV-1 antibodies	Reactive/Nonreactive (R/NR) for HIV-2 antibodies	Reactive/Nonreactive (R/NR) for HIV-antibodies
Test I: Comb AIDS Rs	N.A.	N.A.	NON REACTIVE
Test II: N.A.	N.A.	N.A.	N.A.
Test III: N.A.	N.A.	N.A.	N.A.

Interpretation of the result: Tick (✓) relevant

- Specimen is Negative for HIV antibodies
 - Specimen is Positive for HIV-1 antibodies
 - *Specimen is positive for HIV antibodies (HIV-1 and HIV-2; or HIV-2 alone)
 - Specimen is indeterminate for HIV antibodies. Collect fresh sample in 2 weeks
- *Confirmation of HIV 2 sero-status at identified referral laboratory through ART centers

Name & Signature
Laboratory technician
 DEPTT OF MICROBIOLOGY
 Name & Signature
 Laboratory in charge



Datta Meghe Institute of Medical Sciences (Deemed to be University) NAAC Grade A+

ACHARYA VINOBA BHAVE RURAL HOSPITAL

Transforming Lives Through Well Being

A Teaching Hospital of Jawaharlal Nehru Medical College, Sawangi (Meghe), WARDHA-442 004

Ph. : 07152-287701 - 06, 304000 Ext. 342 Visit us at : www.avbrhsawangimeghe.com Email : info@avbrhsawangimeghe.com



DEPARTMENT OF RADIODIAGNOSIS

Patient Name Sneha Mule Age 30 Sex F

RAF By _____ Date: 21/5/22

OPED /I.D. Rig No. 2205210048 Indication/Clinical _____

LIVER: Normal in size 11 cm. shape and Echotexture. No focal Lesion noted.

IHBR : not dilated, portal vein CBD not dilated. Normal in course and caliber.

GB : Appears normal descendent/~~collapsed~~, no calculus noted. Wall thickness appears normal.

PANCREAS : Normal in size, Shape and Echotexture. Obscured to Bowel shadow

SPLEEN : Normal in size 7.5 cm. Shape and Echotexture.

RENALS:

Right Kidney : 8.2 x 2.8 cm

Left Kidney : 8.1 x 3.2 cm

Both Kidneys: Normal in size, Shape and Echotexture with CMD maintained. No focal lesion noted.

No hydromephrosis or calculus seen.

URINARY BLADDER: APPEARS normal, wall thickness is also normal. No local lesion noted.

No obvious mass lesion noted in the pelvis.

No ascitis seen.

Uterus: 7.2 x 5.1 x 3.3 cm

Endometrial thickness;

Right ovary:] (N)

Left ovary :

Left ovary:

Peritoneal Cavity: No free fluid noted

IMPRESSION, NO OBVIOUS ABNORMALITY NOTED IN PRESENT SCAN



Dr. Harshith Gowda

M B B S.

Reg. No. 19362

Resident, Dept. of Radiodiagnosis

Date :-

Time :- Signature

Dr. Harshith Gowda

for [Signature]

Sign : Consultant Radiologist

(Receiving of Specimen)

(Despatch of Report)

MICROBIOLOGY REPORT

JNMC : _____

Lab. No. : 21/05/2022

Name : Sneha P. Mule


Age/Sex : 30/female Reg. No. 2205210048

Ward/Bed _____ O.P.D.

Consultant : _____ Specimen : Stool

Microscopy : No pus cell, NO RBC, NO WBC & Cyst seen.

Culture : _____


Signature

