



Bangalore Diagnostics & Multi-Speciality Centre

Quality Assurance : EQAP from AIIMS & CMC- Vellore

Quality. Trust. Since 1982.

198, 12th Main, 3rd Block, (Above Namma MTR, Next to SBI), Rajajinagar, Bangalore- 560 010.
Ph. : 080-23505407, 9448079978 e-mail : bangalore.d.s@gmail.com

SUMMARY REPORT

NAME ::	mes. Vijay Lakshmi
EMPLOYEE ID::	PKG10000251
REF.BY::	Bank of Baroda
AGE::	47/years
GENDER::	Female
DATE::	22/11/2021
HEIGHT (in mts)::	1.59
WEIGHT (in kgs)::	71
BMI::	28.1
WAIST CIRCUMFERENCE (in cms)::	98
HIP CIRCUMFERENCE (in cms)::	98
WAIST TO HIP RATIO::	0.95:1.0
BLOOD PRESSURE (mm hg)::	

BANGALORE DIAGNOSTICS &
MULTI-SPECIALITY CENTRE
198, 12th Main, 3rd Block,
Rajajinagar, Bangalore

Dr. MAHADEVA. K.G.
M.D., (Path)
KMC. No.: 17547



ಭಾರತ ಸರ್ಕಾರ
Government of India



ವಿಜಯ ಲಕ್ಷ್ಮಿ
Vijay Lakshmi

ಜನ್ಮ ದಿನಾಂಕ / DOB: 22/10/1974
ಲಿಂಗ / Female



9005 2428 6454

ಆಧಾರ್ - ಶ್ರೀಸಾಮಾನ್ಯನ ಅಧಿಕಾರ


BANGALORE DIAGNOSTICS &
MULTI-SPECIALITY CENTRE
198, 12th Main, 3rd Block
Kumar Nagar, Bangalore-560 076



Bangalore Diagnostics & Multi-Speciality Centre

Quality Assurance : EQAP from AIIMS & CMC- Vellore

Quality. Trust. Since 1982.

198, 12th Main, 3rd Block, (Above Namma MTR, Next to SBI), Rajajinagar, Bangalore- 560 010.
Ph. : 080-23505407, 9448079978 e-mail : bangalore.d.s@gmail.com

Name : MRS. VIJAY LAKSHMI
Age/Sex: 47 Year(s) / Female
Ref. by : DR. BANK OF BARODA

Reg. No : C6311
Date : 22/11/2021
Corporate: NON CORPORATE

Page 1 of 3

HAEMATOLOGY REPORT

COMPLETE BLOOD COUNT

Haemoglobin	10.3 gms %	Male : 13.0 - 18.0 gms % Female: 11.0 - 15.0 gms %
Red Blood Cell Count	4.31 million/cumm	Male : 4.5-6.5 millions/cumm Female : 3.7-5.5 million/cumr
Packed Cell Volume	32.5 %	Females: 32 - 45 % Males: 39 - 54%
Total Count	5,800 cells /cumm	4000-11000 cells /cumm
Differential Count		
Neutrophils	55.9 %	40 - 75%
Lymphocytes	36.7 %	20 - 45%
Monocytes	5.4 %	01 - 10%
Eosinophils	1.5 %	01 - 06 %
Basophils	0.5 %	00 to 01 %

COMPLETE BLOOD COUNT

Platelet count	2,92,000 cells/cumm	150000-400000 cells/cumm
Mean Corpuscular Volume	75 fL	78 - 98 fL
Mean Corpuscular Heamoglobin	24.0 pg	27 - 32 pg
Mean Corpuscular Haemoglobin Concentration	31.8 g/dl	31 - 36 g/dl
ESR	04 mm/hour	Male: 0 - 10 mm/ hour Female: 0 - 20 mm/hour

ABSOLUTE EOSINOPHIL COUNT 88 cells/cumm 40 - 440 cells/cumm

BLOOD GROUP(ABO) "A"
Rh Type (D) POSITIVE

BIOCHEMISTRY REPORT

FASTING BLOOD SUGAR 106 mg/dl 70 to 100 mg/dl
FASTING URINE SUGAR NIL

Dr. MAHADEVA. K.C.
M.D., (Path)
KMC. No.: 17647



Bangalore Diagnostics & Multi-Speciality Centre

Quality Assurance : EQAP from AIIMS & CMC- Vellore

Quality. Trust. Since 1982.

198, 12th Main, 3rd Block, (Above Namma MTR, Next to SBI), Rajajinagar, Bangalore- 560 010.

Ph. : 080-23505407, 9448079978 e-mail : bangalore.d.s@gmail.com

Name : MRS. VIJAY LAKSHMI

Reg. No : C6311

Age/Sex: 47 Year(s) / Female

Date : 22/11/2021

Ref. by : DR. BANK OF BARODA

Corporate: NON CORPORATE

Test Name

Result

Reference Range

Page 2 of 3

BIOCHEMISTRY REPORT

Glycosylated Haemoglobin (HbA1c)

Glycosylated Haemoglobin (HbA1c) 6.3 %

Normal <6.0 %
Good control 6.0-7.0 %
Fair control 7.0-8.0 %
Unsatisfactory 8.0-10.0 %
Poor control >10 %

POST PRANDIAL BLOOD SUGAR 117 mg/dl

80 to 140 mg/dl

LIPID PROFILE

TOTAL CHOLESTEROL 158.9 mg/dl

up to 200 mg/dl

TRIGLYCERIDES 75.5 mg/dl

<150 : Normal

HDL Cholesterol 46.8 mg/dl

Male: >40 mg/dl
Female: > 50 mg/dl

LDL Cholesterol 97.0 mg/dl

<100 mg/dl

VLDL Cholesterol 15.1 mg/dl

<40 mg/dl

CHOLESTEROL/HDL RATIO 3.4:1.0

up to 6.0 %

LIVER FUNCTION TESTS

Total Bilirubin 0.41 mg/dl

up to 1.2 mg/dl

Direct Bilirubin 0.13 mg/dl

0 to 0.3 mg/dl

Indirect Bilirubin 0.28 mg/dl

up to 1.5 mg/dl

S.G.O.T. (AST) 11.9 U/L

0 - 46 U/L

S.G.P.T. (ALT) 14.1 U/L

0 - 49 U/L

ALKALINE PHOSPHATASE 78.0 U/L

Men : 80-306
Women : 64-306

Children upto 15 Yrs : upto 644

Children upto 17 yrs : upto 483

Gamma Glutamyl Transpeptidase (GGT) 16.0 IU/L

0 - 55 IU/L

Total Protein 7.2 gms/dl

6.6 - 8.3 gms/dl

Albumin 3.8 gms/dl

3.4 - 5.0 gms/dl

Globulin 3.4 gms/dl

2.3 - 3.5 gms/dl

A/G Ratio 1.1:1.0

1.2 : 1.0

Dr. MAHADEVA. K.C.
M.D., (Path)
KMC. No.: 17647



Bangalore Diagnostics & Multi-Speciality Centre

Quality Assurance : EQAP from AIIMS & CMC- Vellore

Quality. Trust. Since 1982.

198, 12th Main, 3rd Block, (Above Namma MTR, Next to SBI), Rajajinagar, Bangalore- 560 010.
Ph. : 080-23505407, 9448079978 e-mail : bangalore.d.s@gmail.com

Name : MRS. VIJAY LAKSHMI

Reg. No : C6311

Age/Sex: 47 Year(s) / Female

Date : 22/11/2021

Ref. by : DR. BANK OF BARODA

Corporate: NON CORPORATE

Test Name

Result

Reference Range

Page 3 of 3

BIOCHEMISTRY REPORT

SERUM CREATININE	1.09 mg/dl	Females 0.6 – 1.2 mg/dl Males 0.7 – 1.4 mg/dl
BLOOD UREA NITROGEN (BUN)	12.2 mg/dl	7-18 mg/dl
URIC ACID	4.47 mg/dl	M: 3.5 -7.2 mg/dl F: 2.6 - 6.0 mg/dl

URINE EXAMINATION REPORT

PHYSICAL EXAMINATION

COLOUR	LIGHT YELLOW
APPEARANCE	CLEAR
REACTION	ACIDIC

BIOCHEMICAL EXAMINATION

PROTEIN	NIL	
GLUCOSE	NIL	
BILE SALT	NIL	
BILE PIGMENT	NIL	
SPECIFIC GRAVITY	1.019	1.003 – 1.035

MICROSCOPIC EXAMINATION


PUS CELLS	2-3/HPF
EP CELLS	1-2/HPF
R.B.C.s	NIL
CASTS	NIL
CRYSTALS	NIL

----- End of Report -----

Biochemist

Microbiologist

Pathologist


Dr. MAHADEVA. K.C.
M.D., (Path)
KMC, No.: J7647



Bangalore Diagnostics & Multi-Speciality Centre

Quality Assurance : EQAP from AIIMS & CMC- Vellore

Quality. Trust. Since 1982.

198, 12th Main, 3rd Block, (Above Namma MTR, Next to SBI), Rajajinagar, Bangalore- 560 010.
Ph. : 080-23505407, 9448079978 e-mail : bangalore.d.s@gmail.com

Name : Mrs. VIJAYLAKSHMI (C-311) Ref. Doctor : DR. SELF
Age / Sex : 47 Year(s) / Female Client : BANGALORE DIAGNOSTICS
Patient ID : PDJ289209
Visit No. : 21JC518035

Registered Date : 22/11/2021 04:07 PM
Collected On : 22/11/2021 04:07 PM
Received On : 22/11/2021 04:37 PM
Reported On : 22/11/2021 05:53 PM



Report Type : Final

Test	Results	Units	Biological Reference Range
IMMUNOLOGY			
<u>TFT - THYROID FUNCTION TEST</u> - Serum			
CLIA			
T3 (TOTAL)	0.87	ng/mL	Newborn : 0.7-2.0 < 1 Year: 1.0-2.4 1 - 5 Years : 1.0-2.4 6 - 10 Years: 0.9-2.4 11 - 50 Years: 0.7-2.0 > 50 Years: 0.4-1.8 First Trimester: 0.8-1.9 Second Trimester: 1.0-2.6
T4 - TOTAL	9.33	µg/dL	6.09-12.23
Thyroid Stimulating Hormone (TSH)	3.426	µIU/mL	Newborn: 1.0-39.0 2 - 20 Weeks: 1.7-9.1 21 Weeks - 20 Years: 0.7-6.4 21 - 54 Years: 0.4-4.2 55 - 87 Years: 0.5-8.9 First Trimester: 0.1-2.5 Second Trimester: 0.2-3.0

-- End of Report --

Kindly correlate clinically. If necessary discuss/repeat

Samiksha Ray

Dr. Samiksha.Ray,
Consultant
Pathologist
KMC-NO:93425

Page 1 / 1



Bangalore Diagnostics & Multi-Speciality Centre

Quality Assurance : EQAP from AIIMS & CMC- Vellore

Quality. Trust. Since 1982.

198, 12th Main, 3rd Block, (Above Namma MTR, Next to SBI), Rajajinagar, Bangalore- 560 010.
Ph. : 080-23505407, 9448079978 e-mail : bangalore.d.s@gmail.com

Abdomen And Pelvic Ultrasound Scan Report

Name : Mrs.Vijaylakshmi

Date: 22/11/2021

Ref By : Bank of Baroda

Age/ Gender 47 Years/Female

Liver : Normal in size, shape and echotexture. No focal lesion seen.

No intrahepatic biliary dilatation seen. PV & CBD is normal

Gall Bladder: GB is normal. Normal in wall thickness. No abnormal intraluminal echoes.

Pancreas : Normal in size and echotexture. No focal lesion, Pancreatic duct appears normal.

Spleen : Normal in size, shape and echotexture.

Kidneys : Both Kidney's are normal in size, shape and position.

No Calculi / Hydronephrosis seen. Cortico meduallary differentiation is good.

Right Kidney : 108 x 17 mm

Left Kidney : 116 x 20 mm

Urinary Bladder: Normal in contour and wall thickness with clear contents.

Uterus : Anteverted, Measures **102 x 52 x 56 mm**, bulky in size, Normal shape and echotexture. Endometrial thickness = **5 mm**. POD is empty.

Ovaries : Both Ovaries are visualized in adenexa,

Right Ovary : **34 x 20 mm** and appeared Normal.

Left Ovary : **41 x 26 mm** appeared bulky.

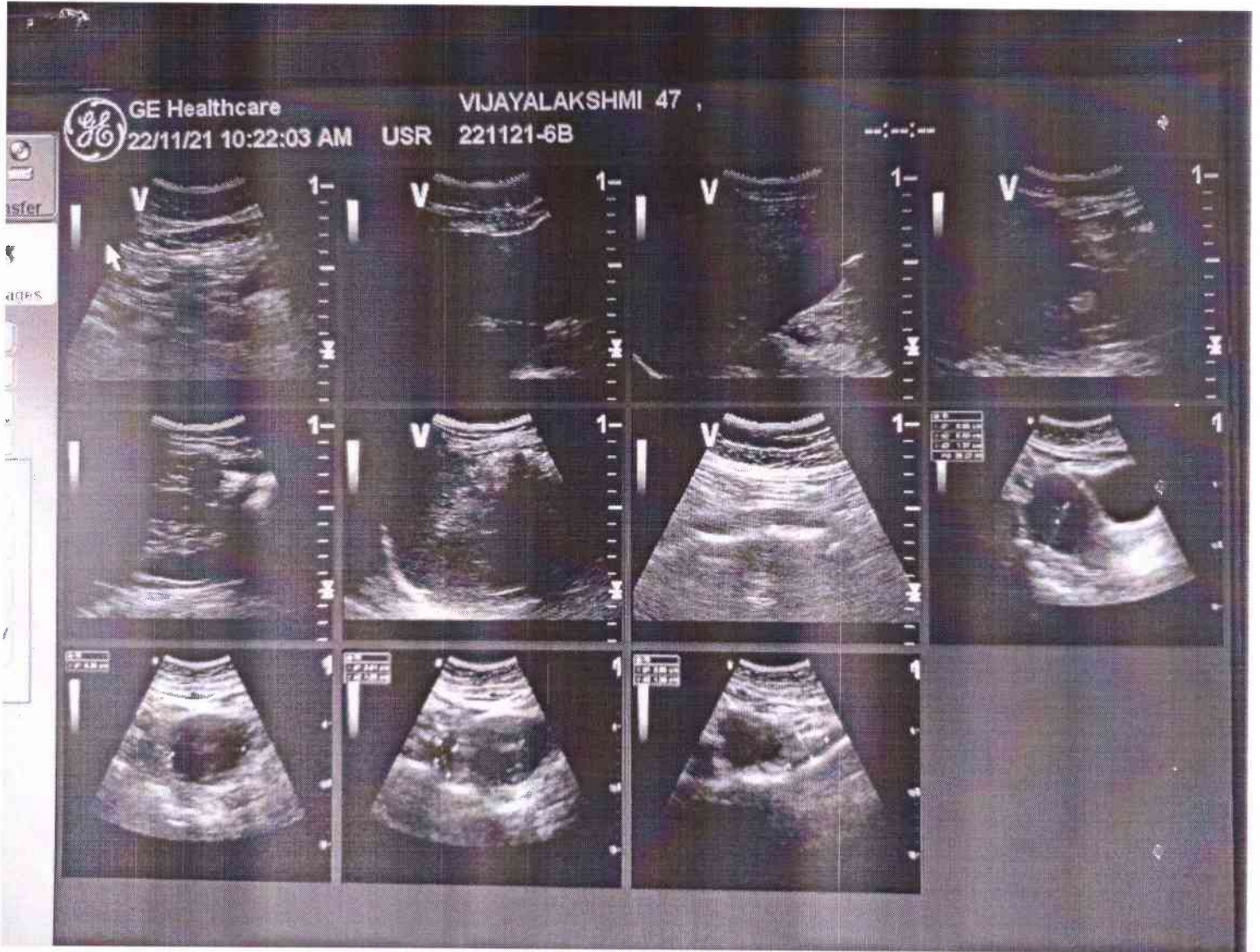IMPRESSION:

- Bulky Uterus.
- Bulky Left Ovary.
- Otherwise Normal Sonologic Study.


Dr. Mohan Kumar

Consultant Radiologist

BANGALORE DIAGNOSTICS &
MULTI-SPECIALITY CENTRE
198, 12th Main, 3rd Block
Rajajinagar, Bangalore-560 010



**BANGALORE DIAGNOSTICS &
MULTI-SPECIALITY CENTRE**
198, 12th Main, 3rd Block
Rajajinagar, Bangalore-560 010



Bangalore Diagnostics & Multi-Speciality Centre

Quality Assurance : EQAP from AIIMS & CMC- Vellore

Quality. Trust. Since 1982.

198, 12th Main, 3rd Block, (Above Namma MTR, Next to SBI), Rajajinagar, Bangalore- 560 010.

Ph. : 080-20505407, 9448079978 e-mail : bangalore.d.s@gmail.com

Echocardiography Report

Name : Mrs. Vijaylakshmi

Date: 22/11/2021

Ref By : Bank of Baroda

Age/ Gender 47 Years/Female

LA : 32 mm	MV : E 0.97 A : 0.71 m/sec
AO : 22 mm	AV : 1.75 m/sec
RVID : 19 mm	TV : 0.61 m/sec
LVIDD : 42 mm	PV : 0.53 m/sec
LVIDS : 28 mm	
IVSD : 11 mm	MR : Nil
IVSS : 18 mm	AR : Nil
LVPWD: 11 mm	TR : Nil
LVPWS : 18 mm	PR : Nil
FS : 33 %	
EF : 62%	
LV mass: 239 gm	

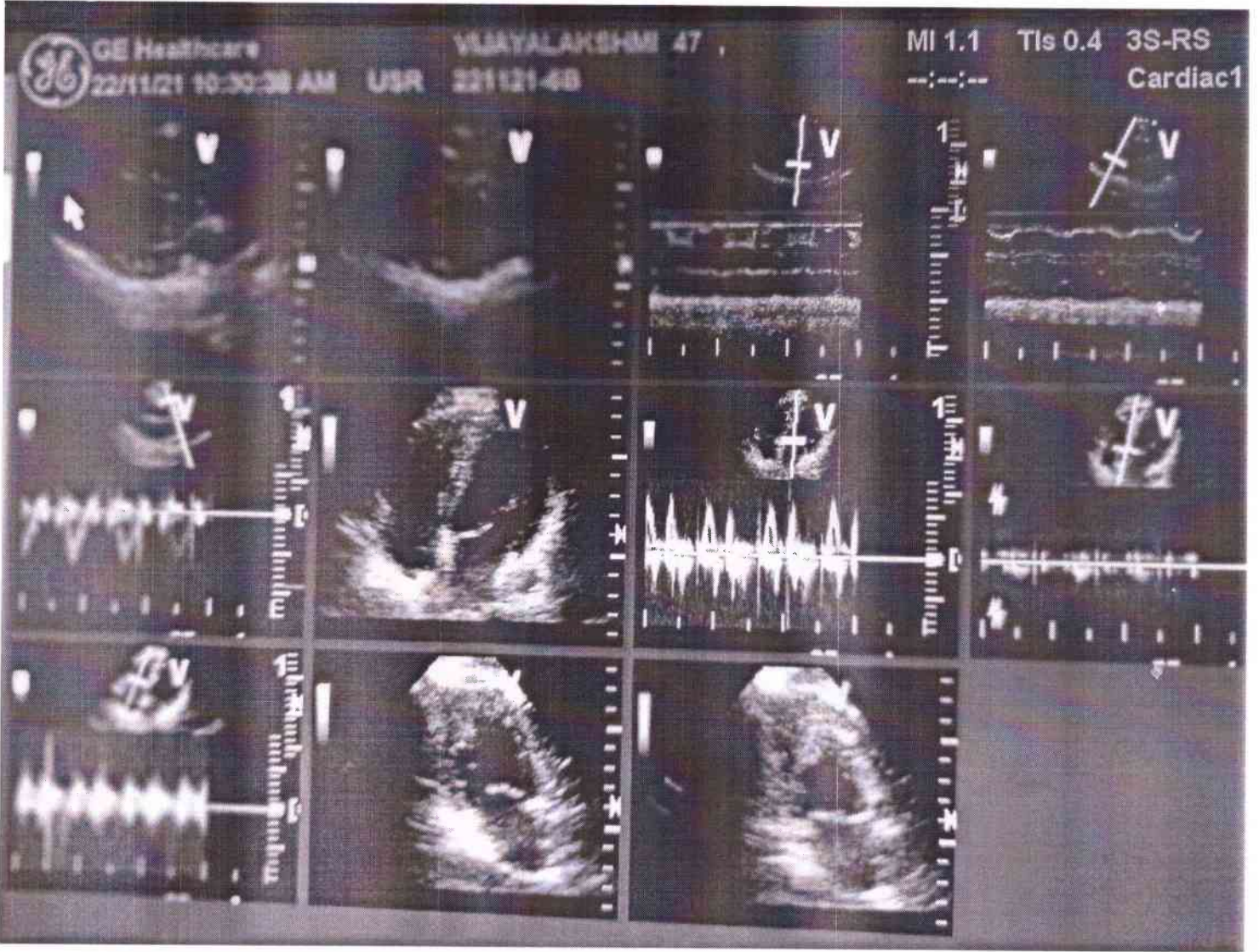
IMPRESSION

- Normal Chamber Dimensions.
- No RWMA.
- Normal LV Systolic Function. LVEF 62%
- Normal Valves.
- Normal Color Flow and Spectral Doppler Study.
- No Thrombus / PE

Dr.

Consultant Cardiologist

BANGALORE DIAGNOSTICS &
MULTI-SPECIALITY CENTRE
198, 12th Main, 3rd Block
Rajajinagar, Bangalore-560 010



BANGALORE DIAGNOSTICS &
MULTI-SPECIALITY CENTRE
198, 12th Main, 3rd Block
Rajajinagar, Bangalore-560 010



Bangalore Diagnostics & Multi-Speciality Centre

Quality Assurance : EQAP from AIIMS & CMC- Vellore

Quality. Trust. Since 1982.

198, 12th Main, 3rd Block, (Above Namma MTR, Next to SBI), Rajajinagar, Bangalore- 560 010.
Ph. : 080-23505407, 9448079978 e-mail : bangalore.d.s@gmail.com

Breast Ultrasound Scan Report

Name : Mrs.Vijaylakshmi

Date: 22/11/2021

Ref By : Bank of Baroda

Age/ Gender 47 Years/Female

Right breast: Shows normal echotexture of glandular and adipose soft tissue.

No obvious focal lesions noted.

Nipple and retroareolar regions appeared normal.

No ductal dilatation seen.

Left breast: Shows normal echotexture of glandular and adipose soft tissue.

No obvious focal lesions noted.

Nipple and retroareolar regions appeared normal.

No ductal dilatation seen.

No evidence of enlarged lymphnodes seen in both axillae .

IMPRESSION:

- Normal Sonologic Study.

BIRADE SCORE: I (Suggest Routine Screening)


Dr.Mohan Kumar

Consultant Radiologist

**BANGALORE DIAGNOSTICS &
MULTI-SPECIALITY CENTRE**
198, 12th Main, 3rd Block
Rajajinagar, Bangalore-560 010



GE Healthcare

22/11/21 10:37:50 AM

USR

VIJAYALAKSHMI 47

221121-6B

MI 0.6

TIs 0.6

12L-RS

Carotid

Data Transfer

Active Images

Review

Permanent Store

Standard Print

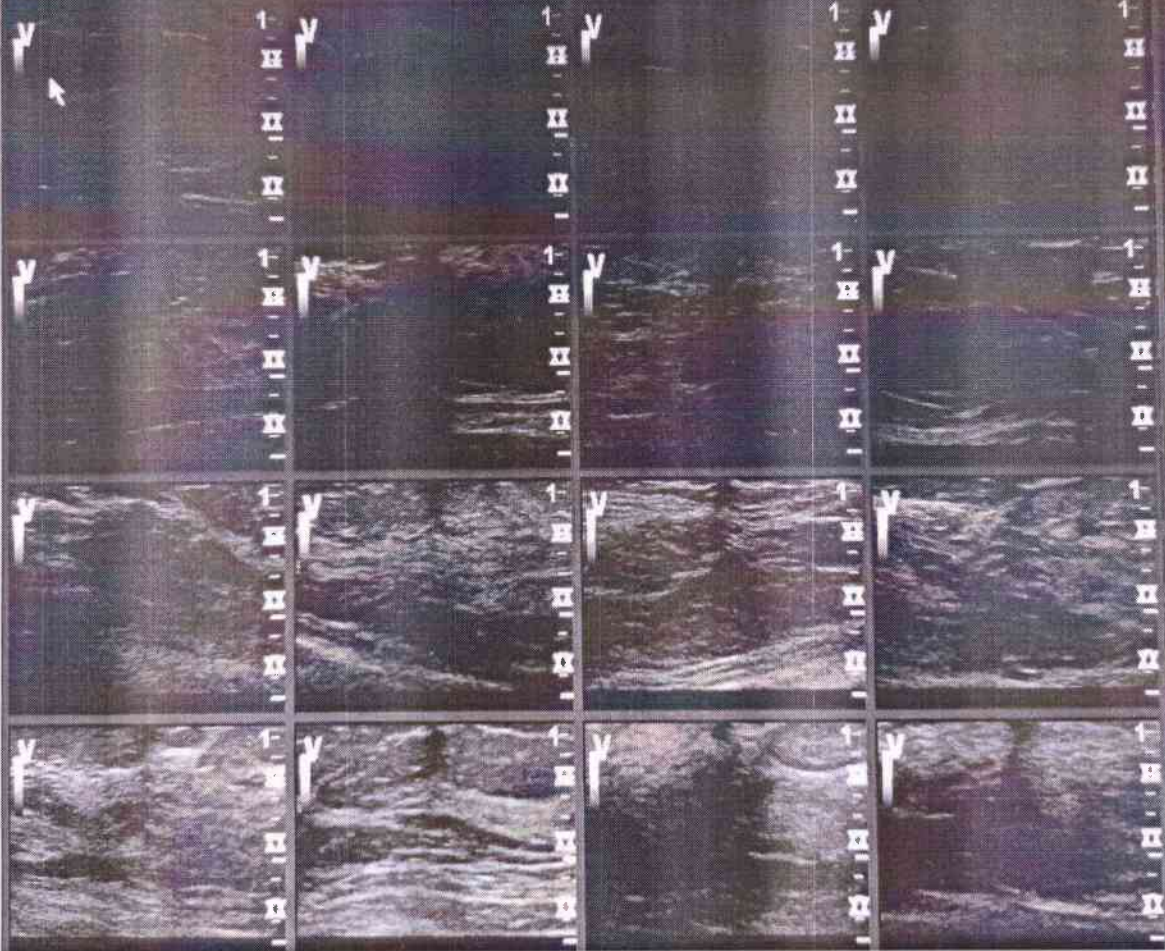
Delete

Select All

Deselect All

Apply to Selected Images

Apply to All Temporary Images



1 of 1

Exit

BANGALORE DIAGNOSTICS &
MULTI-SPECIALITY CENTRE
198, 12th Main, 3rd Block
Rajajinagar, Bangalore-560 010



Bangalore Diagnostics & Multi-Speciality Centre

Quality Assurance : EQAP from AIIMS & CMC- Vellore

Quality. Trust. Since 1982.

198, 12th Main, 3rd Block, (Above Namma MTR, Next to SBI), Rajajinagar, Bangalore- 560 010.
Ph. : 080-23505407, 9448079978 e-mail : bangalore.d.s@gmail.com

Patient Name	MRS.VIJAY LAKSHMI	Patient Id	X-RA-21
Age/DOB	47/	Gender	F
Ref.Doctor	BANK OF BARODA	Date	22/11/2021

Thank you for referring the patient for XRay

X-RAY CHEST PA VIEW

OBSERVATION:

The trachea is central.

The mediastinal and cardiac silhouette are normal.

Cardiothoracic ratio is normal.

Cardiophrenic and costophrenic angles are normal.

Both hila are normal.

The lung fields are clear.

Bones of the thoracic cage are normal.

Soft tissues of the chest wall are normal.

IMPRESSION:

- No significant abnormality seen.

Dr. Shankar Poudel
MD Radiodiagnosis
Consultant Radiologist

**BANGALORE DIAGNOSTICS &
MULTI-SPECIALITY CENTRE**
198, 12th Main, 3rd Block
Rajajinagar, Bangalore-560 010

1875
1876
1877
1878
1879
1880
1881
1882
1883
1884
1885
1886
1887
1888
1889
1890
1891
1892
1893
1894
1895
1896
1897
1898
1899
1900

R



Bangalore Diagnostics & Multi-Speciality Centre

Quality Assurance : EQAP from AIIMS & CMC- Vellore

Quality. Trust. Since 1982.

198, 12th Main, 3rd Block, (Above Namma MTR, Next to SBI), Rajajinagar, Bangalore- 560 010.

Ph. : 080-23505407, 9448079978 e-mail : bangalore.d.s@gmail.com

ELECTROCARDIOGRAM


NAME/AGE : Mrs. Vijay Lakshmi

Lab No.: Bank of Baroda DATE: 22/11/21

ECG FINDINGS

Standardization	low	Rate	78
Rhythm	sin	Axis	✓
P Wave	✓	PR Interval	0.23 sec
Q Wave	✓	QRS Voltage	5.0 mV in lead I
QRS Duration	0.09 sec	ST Segment	5.0 mV in lead I
QT interval	0.38 sec		
U Wave		Wave	✓
Recommendations	Normal		

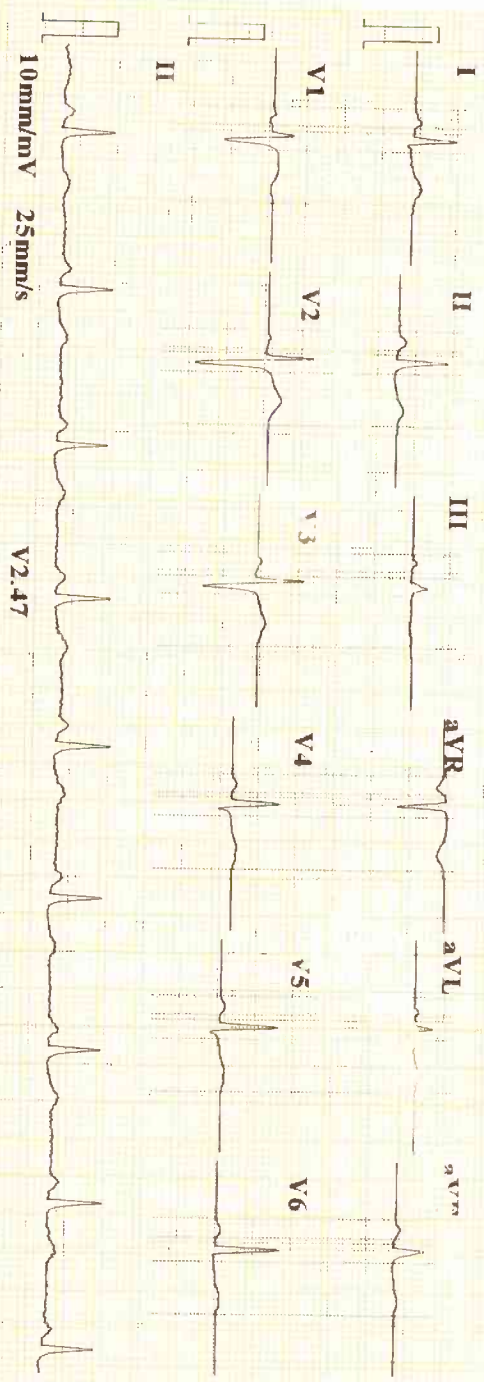
BANGALORE DIAGNOSTICS CENTRE
198, 12th Main, 3rd Block
Rajajinagar, Bangalore-560 010


Dr. Dr. ASHOK
MD (Internal Medicine)
Reg No.: 13444



Average Template:

2021-11-22 16:12:27

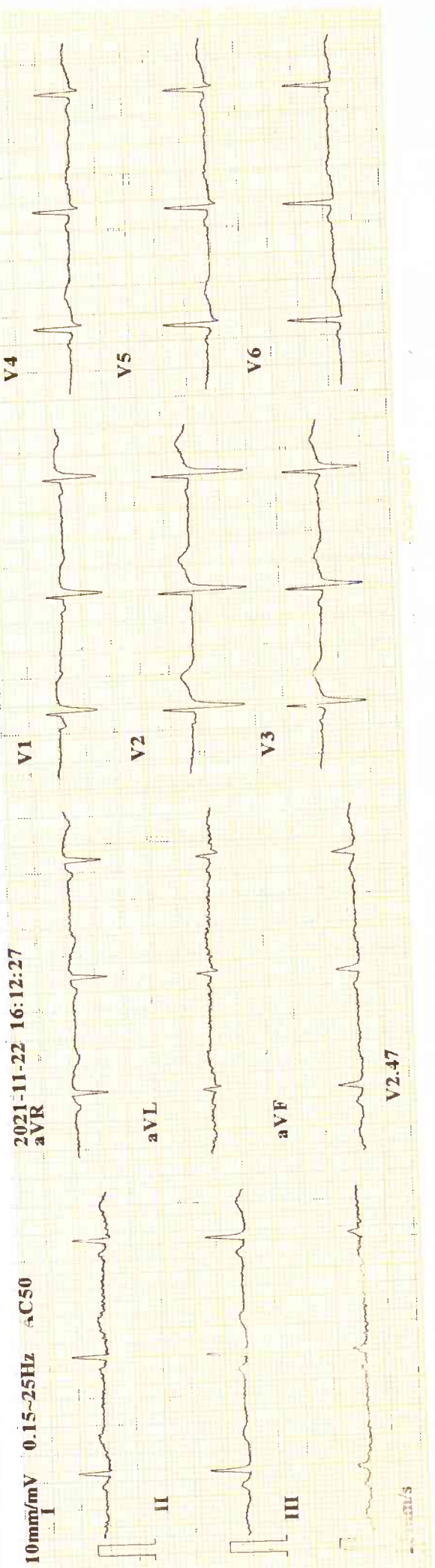


ID : 211122-1612
 Name : V. Sanyal
 Age : 47 yr
 Sex : Female
 BP :
 Height : cm
 Weight : kg
 HR : 73 bpm
 P Dur : 99 ms
 PR int : 134 ms
 QRS Dur : 95 ms
 QT/QTc int : 370/409 ms
 P/QRS/T axis : 49/54/23 °
 RV5/SV1 amp : 0.768/0.619 mV
 RV6/SV2 amp : 1.387 mV
 RV6/SV2 amp : 0.841/0.930 mV

Diagnosis
 800: Sin
 ***Nor

Report

Minnesota 4-5-0(1)



2021-11-22 16:12:27

aVR
 C50
 25Hz
 15-0
 V/m/m/m101