



To,

The Coordinator,  
Mediwheel (Arcofemi Healthcare Limited)  
Helpline number: 011- 41195959

Dear Sir / Madam,

**Sub: Annual Health Checkup for the employees of Bank of Baroda**

This is to inform you that the following spouse of our employee wishes to avail the facility of Cashless Annual Health Checkup provided by you in terms of our agreement.

PARTICULARS OF HEALTH CHECK UP BENEFICIARY	
NAME	SANDIPAN GHOSH
DATE OF BIRTH	05-01-1985
PROPOSED DATE OF HEALTH CHECKUP FOR EMPLOYEE SPOUSE	11-03-2023
BOOKING REFERENCE NO.	22M108563100042878S
SPOUSE DETAILS	
EMPLOYEE NAME	MRS. SAHA SHREYA
EMPLOYEE EC NO.	108563
EMPLOYEE DESIGNATION	SMS CREDIT PROCESSING
EMPLOYEE PLACE OF WORK	BENGALURU,RO BENGALURU SOUTH
EMPLOYEE BIRTHDATE	05-05-1989

This letter of approval / recommendation is valid if submitted along with copy of the Bank of Baroda employee id card. This approval is valid from **17-02-2023** till **31-03-2023**.The list of medical tests to be conducted is provided in the annexure to this letter. Please note that the said health checkup is a **cashless facility** as per our tie up arrangement. We request you to attend to the health checkup requirement of our employee's spouse and accord your top priority and best resources in this regard. The EC Number and the booking reference number as given in the above table shall be mentioned in the invoice, invariably.

We solicit your co-operation in this regard.

Yours faithfully,

Sd/-

**Chief General Manager**  
**HRM Department**  
**Bank of Baroda**

(Note: This is a computer generated letter. No Signature required. For any clarification, please contact Mediwheel (Arcofemi Healthcare Limited))

Employee Name	MR. Sandeepan Ghosh.
---------------	----------------------

Employee ID	100563
-------------	--------

Age	38yrs.
-----	--------

Gender	male.
--------	-------

Date	11/3/2023
------	-----------

Name of center	NH SALTAPUR
----------------	-------------

City	Bangalore
------	-----------

**BASIC PARAMTERS:**

Height (in mts)	173cm
Weight (in Kgs)	80.9 Kg.
BMI	

Waist circumference (in cms)	99cm.
Hip circumference (in cms)	97cm.
Waist-to-hip ratio	

Systolic BP	120/80
Diastolic BP	





ID: 201-24170  
Name: MR SANDIPAN  
Age: 38 Years  
Gender: Male

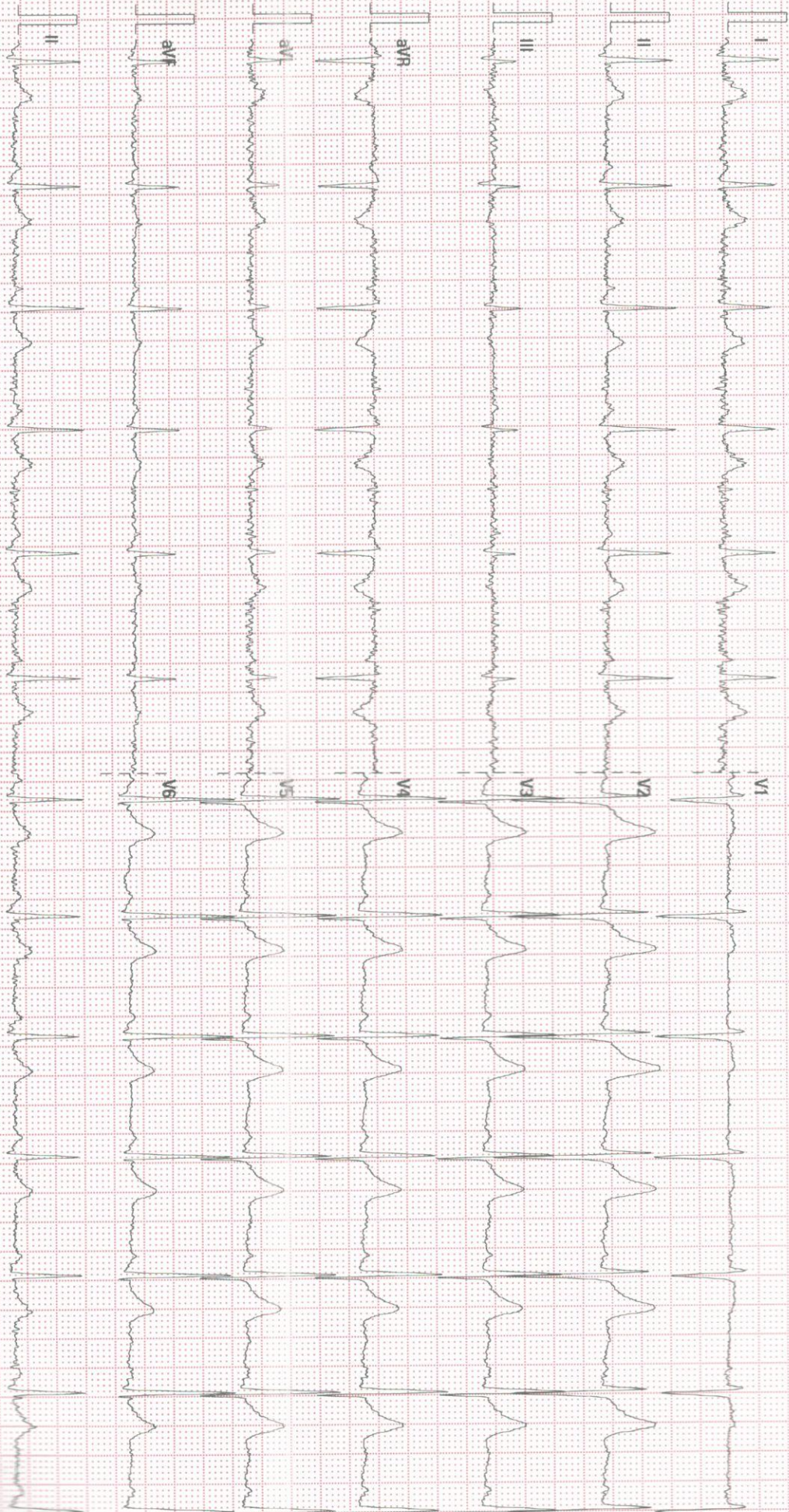
11-03-2023 08:52:20

Vent. Rate 73 bpm  
PR Interval 138 ms  
QRS Duration 92 ms  
QT/QTc Interval 380/403 ms  
P/QRS/T Axes 58/45/28 deg  
RV5/SV1 1.746/1.218 mV  
RV5 + SV1 2.964 mV

Sinus rhythm  
Normal ECG

Unconfirmed Diagnosis

Dr: e-Hodges



25 mm/s

10 mm/mV

50 Hz

BD8 35 Hz

NARAYANA MSC SARALAPUR

02.04.00/V28.4.1

SN FN 000013000



## TRANS-THORACIC ECHO REPORT

Patient MRN : 201-24170

Date : 11.03.2023

Patient Name : Mr. SANDIPAN GHOSH

Age/Gender : 38 yrs/male

### M-MODE / 2D MEASUREMENTS

LVEF (>55)%	: 60%	LVID(d) (40-56)mm	: 48mm	LVID (s) mm	: 34mm
TAPSE (>16) mm	: 20mm	IVS (d) (6-10)mm	: 10mm	LV-EDV ml	: --
LA (<39) mm	: 30mm	PWD (d) (6-10)mm	: 9mm	LV-ESV ml	: --
RA (<44)mm	: 31mm	RV (<35) mm	: 27mm	BSA m <sup>2</sup> : --	PRESSURE

### DOPPLER MEASUREMENTS

MITRAL VALVE : E/A - 0.7/0.5 M/S, NORMAL LV DIASTOLIC FUNCTION, MR-TRIVIAL

AORTIC VALVE : PG - 4MMHG /AR-TRIVIAL

TRICUSPID VALVE : TR -TRIVIAL

PULMONARY VALVE : PG - 4 MMHG

PA PRESSURE : PASP- 20 MMHG/ NORMAL PA PRESSURE.

### FINDINGS

SITUS SOLITUS, LEVOCARDIA, AV AND VA CONCORDANT, NORMAL GREAT ARTERY RELATIONSHIP

### VALVES

MITRAL : NORMAL

AORTIC : NORMAL

TRICUSPID : NORMAL

PULMONARY : NORMAL

### CHAMBERS

LV : NORMAL SIZED, NORMAL LV SYSTOLIC FUNCTION.

RV : NORMAL SIZED, NORMAL RV FUNCTION.

RWMA : NO RWMA

LVOT : NORMAL

LEFT ATRIUM : NORMAL SIZED

RIGHT ATRIUM : NORMAL SIZED

**SEPTAE**

**IVS** : INTACT

**IAS** : INTACT

**ARTERIES & VEINS**

**AORTA** : AORTIC ANNULUS - 21 MM, ASCENDING AORTA- 29 MM,  
NORMAL ARCH NORMAL SIZED.

**PULMONARY ARTERY** : NORMAL

**IVC, SVC & CS** : IVC – 13 MM, NORMAL SIZED, COLLAPSING, NORMAL RA PRESSURE.

**PULMONARY VEINS** : NORMAL

**PERICARDIUM** : NORMAL


**VEGETATION / THROMBUS / TUMOR**: NIL

**OTHER FINDINGS:**

SINUS RHYTHM- 73 BPM  
NO PREVIOUS ECHO REPORT

**CONCLUSION**

NORMAL CHAMBER DIMENSIONS  
NORMAL PA PRESSURE  
NO RWMA  
NORMAL LV SYSTOLIC FUNCTION  
LVEF:- 55-60%

  
CHANDANA V  
CARDIAC SONOGRAPHER





**TO WHOMSOEVER IT MAY CONCERN**

I hereby give a consent Sandipan ghat (Patient Name) 201-24170  
(MRN No) that I have not taken service Eye, PPBS, PP Sugar, stool routine  
(ECG/ECHO/Doppler/TMT/X-Ray/Investigation/Consultation against  
Package/Health Checkup) Mediwheel below 40 Male (Package Name/HC  
Name) against Invoice number INR-2010-230300479  
dated 11/3/2023.

Shreyas Saha  
Patient Sign

Resmi  
Dept Sign

A.B.K  
Unit Head Sign/Seal

9886287630  
Mobile Number

108863  
EC Number



316370  
EC Number

Sandipan  
[Signature]

349939

## Package Details

<b>Patient Name :</b> Mr Sandipan Ghosh, 2010000024170, male, 38y 2m
<b>Package Name :</b> EHP Mediwheel Full Body Health checkup Below 40 Male
<b>Start Date :</b> 11/03/2023 08:52 <b>End Date :</b> 12/03/2023 08:52
<b>Generated By:</b> Hemanth Kumar
<b>Generated On :</b> 11-03-2023 08:52

Service Name	Ordered Date	Service Center	Consultant	Qty	Explicit
CONSULTATION - FIRST VISIT	11/03/2023 08:52 AM	OPD-2F	Dr. Sharma Vasant Kumar	1	No
USG ABDOMEN	11/03/2023 08:52 AM	ULTRA SOUND-2F	Dr. Sharma Vasant Kumar	1	No
XRAY CHEST PA	11/03/2023 08:52 AM	X-RAY	Dr. Sharma Vasant Kumar	1	No
ECHO COLOR DOPPLER	11/03/2023 08:52 AM	ECHO-2F	Dr. Sharma Vasant Kumar	1	No
TREADMILL TEST	11/03/2023 08:52 AM	OPD-2F	Dr. Sharma Vasant Kumar	1	No
ECG	11/03/2023 08:52 AM	OPD-2F	Dr. Sharma Vasant Kumar	1	No
BLOOD UREA NITROGEN (BUN)	11/03/2023 08:52 AM	BIOCHEMISTRY	Dr. Sharma Vasant Kumar	1	No
URIC ACID	11/03/2023 08:52 AM	BIOCHEMISTRY	Dr. Sharma Vasant Kumar	1	No
THYROID PROFILE (T3, T4, TSH)	11/03/2023 08:52 AM	BIOCHEMISTRY	Dr. Sharma Vasant Kumar	1	No
LIVER FUNCTION TEST (LFT)	11/03/2023 08:52 AM	BIOCHEMISTRY	Dr. Sharma Vasant Kumar	1	No
SERUM CREATININE	11/03/2023 08:52 AM	BIOCHEMISTRY	Dr. Sharma Vasant Kumar	1	No
LIPID PROFILE (CHOL, TRIG, HDL, LDL, VLDL)	11/03/2023 08:52 AM	BIOCHEMISTRY	Dr. Sharma Vasant Kumar	1	No
HBA1C	11/03/2023 08:52 AM	BIOCHEMISTRY	Dr. Sharma Vasant Kumar	1	No
URINE FOR SUGAR (FASTING)	11/03/2023 08:52 AM	CLINICAL PATHOLOGY	Dr. Sharma Vasant Kumar	1	No
URINE FOR SUGAR (POST PRANDIAL)	11/03/2023 08:52 AM	CLINICAL PATHOLOGY	Dr. Sharma Vasant Kumar	1	No
POST PRANDIAL BLOOD SUGAR (PPBS)	11/03/2023 08:52 AM	BIOCHEMISTRY	Dr. Sharma Vasant Kumar	1	No
FASTING BLOOD SUGAR (FBS)	11/03/2023 08:52 AM	BIOCHEMISTRY	Dr. Sharma Vasant Kumar	1	No
BLOOD GROUP & RH TYPING	11/03/2023 08:52 AM	NARAYANA HRUDAYALAYA BLOOD CENTRE	Dr. Sharma Vasant Kumar	1	No
STOOL ROUTINE EXAMINATION	11/03/2023 08:52 AM	CLINICAL PATHOLOGY	Dr. Sharma Vasant Kumar	1	No
URINE ROUTINE & MICROSCOPY	11/03/2023 08:52 AM	CLINICAL PATHOLOGY	Dr. Sharma Vasant Kumar	1	No
ERYTHROCYTE SEDIMENTATION RATE (ESR)	11/03/2023 08:52 AM	HEMATOLOGY	Dr. Sharma Vasant Kumar	1	No

WT - 80.9 kg  
 HT - 173 cm  
 Lipid = 97 EM  
 waist - 99

BP - 120/80  
 PR - 80/mc





Service Name	Ordered Date	Service Center	Consultant	Qty	Explicit
COMPLETE BLOOD COUNT (CBC)	11/03/2023 08:52 AM	HEMATOLOGY	Dr. Sharma Vasant Kumar	1	No



11-03-2023 08:52



Patient Name : Mr. SANDEEPAN GHOSH

Patient ID : 201-24170

Age : 38 Years

Sex : male

Referring Doctor : PKG

Date : 11.03.2023

**ULTRASOUND ABDOMEN AND PELVIS****FINDINGS:**

**Liver** is normal in size (15.2cm), and Shows mild diffuse increase in echogenicity. No intra or extra hepatic biliary duct dilatation. No focal lesions.

**Portal vein** is normal in size, course and caliber. **CBD** is not dilated.

**Gall bladder** is normal without evidence of calculi, wall thickening or pericholecystic fluid.

**Pancreas** to the extent visualized, appears normal in size, contour and echogenicity.

**Spleen** is normal in size (9.5cm), shape, contour and echopattern. No evidence of mass or focal lesions.

**Right Kidney** is normal in size (measures 10.7 cm in length & 1.6cm in parenchymal thickness), position, shape and echopattern. Corticomedullary differentiation is maintained. No evidence of calculi or hydronephrosis.

**Left Kidney** is normal in size (measures 10.6 cm in length & 1.8 cm in parenchymal thickness), position, shape and echopattern. Corticomedullary differentiation is maintained. No evidence of calculi or hydronephrosis.

**Retroperitoneum** – Obscured by bowel gas.


**Urinary Bladder** is well distended. Wall thickness is normal. No evidence of calculi, mass or mural lesion.

**Prostate** is normal in echopattern and size, measures 3.2x2.4x2.9 cm (Volume =12.2cc).

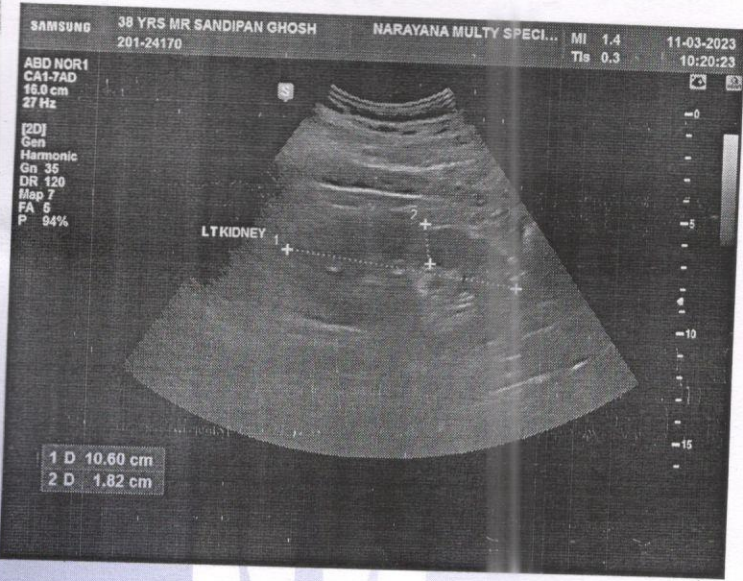
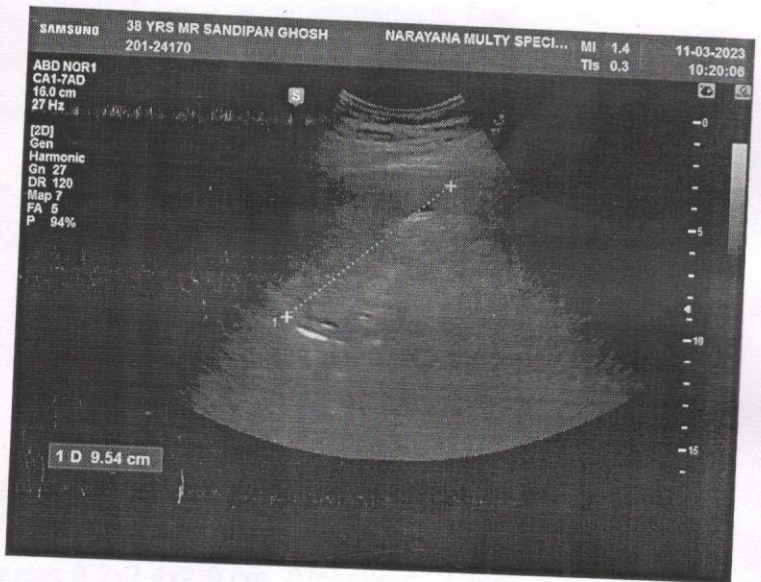
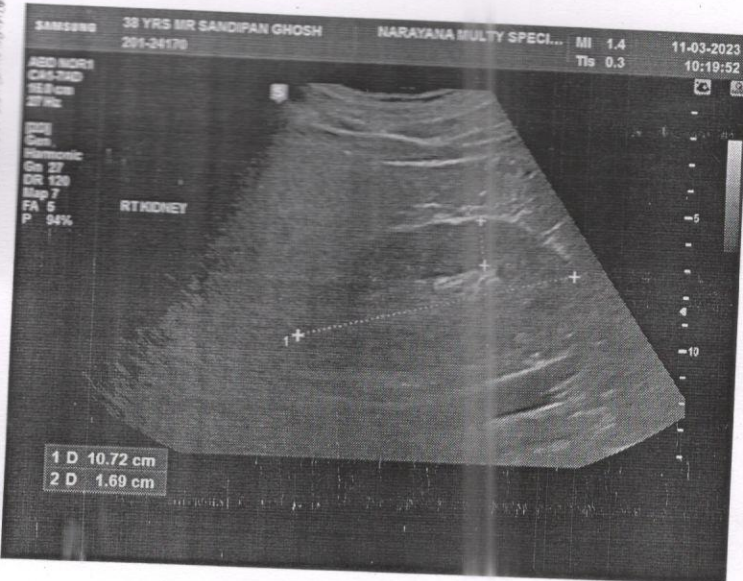
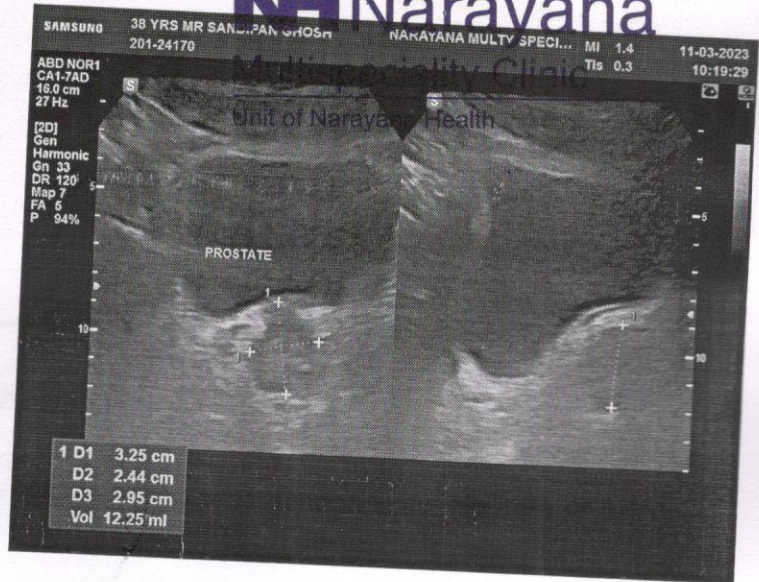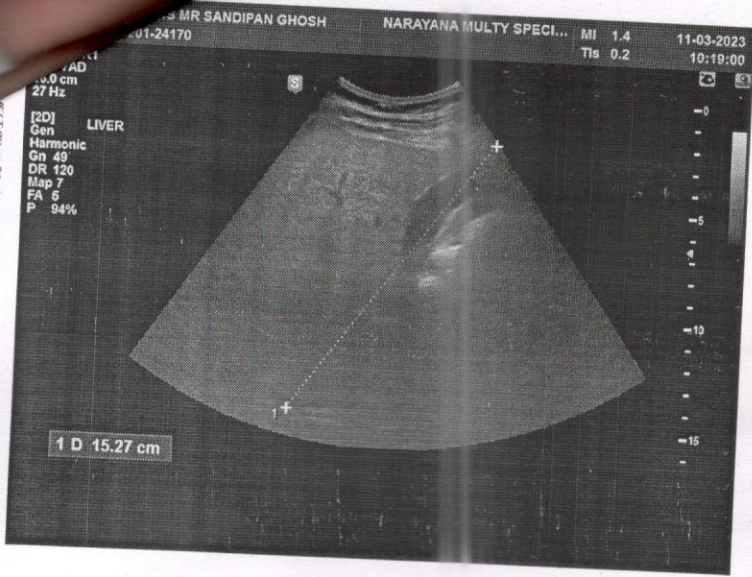
**Fluid** - There is no ascites or pleural effusion.

**IMPRESSION:**

- **MILD HEPATOMEGALY WITH GRADE 1 FATTY LIVER**

  
**Dr. Ananthalakshmi.S**  
**Sonologist**







R

MR SANDIPANI 38 YRS / M 20121170 11-Mar-2023 09:43:54 AM CHEST FRN P-A  
NARAYANA MULTISPECIALTY CLINIC, SARJAPUR ROAD