



भारत सरकार
GOVERNMENT OF INDIA



अन्नू रानी
Annu Rani
जन्म तिथि/ DOB: 04/10/1989
महिला / FEMALE



9038 3955 0785



भारतीय विशिष्ट पहचान प्राधिकरण
UNIQUE IDENTIFICATION AUTHORITY OF INDIA

पता:

नितिन कुमार, लीग 42/1
पॉकेट डी 12, विभाग 7
रोहिणी, साई बाबा मंदिर के
पास, विभाग 7 रोहिणी,
रोहिणी सेक्टर-7, उत्तर
पश्चिमी,
दिल्ली - 110085

Address:

W/O, Nitin Kumar, Lig 42/1 Pocket
D 12, Sector 7 Rohini, Near Sai
Baba Mandir, Sector 7 Rohini,
Rohini Sector-7, North West
Delhi,
Delhi - 110085

9038 3955 0785

DR. NITIN AGARWAL
MBBS, MD
DMC-R-145

ONEPLUS ULTRASOUND LAB
47, Harsh Vihar, Pitam Pura
Delhi-110034
Ph 011-42480101, 999913051
E-mail oneplusul@gmail.com

Dt : 26/06/2021

Dear Sir/madam,

I request you to process my other tests reports as I am not comfortable in giving my stool sample.

Thanking you.

Annu Rani

@ms

ONEPLUS ULTRASOUND LAB
47, Harsh Mihar, Pitam Pura
Delhi-110034
Ph: 011-42460104, 0226913051
E-mail: oneplusul@gmail.com



ams

[Signature]
DR. NITIN AGARWAL
MBBS, MD
Reg. No. DMC-R-146

ONEPLUS ULTRASOUND LAB
47, Harsh Vihar, Pitam Pura
Delhi-110034
Ph 011-42480104, 8869913051
E-mail oneplusul@gmail.com



OnePLUS
Ultrasound Lab

— QUALITY FIRST... ALWAYS! —

Dr. Nitin Agarwal

Pathologist & Director
Ex. Sr. Res. MAMC
& Lok Nayak Hospital
Ex. Chief of Lab Dr. Lal Path Labs.

Dr. Pooja (Garg) Agarwal

Radiologist & Director
MAMC & Lok Nayak Hospital

| | |
|--------------------------------|--------------------------------|
| Name : Mrs. ANNU RANI | Age/Sex : 31 YRS/Female |
| Ref. By : Dr. MEDIWHEEL | Lab No : 012106260024 |
| Date : 26-Jun-2021 | Patient ID : LSHHI80562 |

X-ray-Chest PA view

Bony cage and soft tissues are normal.

Cardiothoracic ratio is normal.

Mediastinum is normal.


Both hila are normal.

Both costophrenic angles are clear.

Both domes of diaphragm are normal.

Lung fields are clear. No parenchymal lesion seen.

IMPRESSION: Normal Study.


DR. POOJA GARG
RADIOLOGIST
REG NO- DMC/R/03398

Dr. POOJA GARG
M.B.B.S., D.M.R.D.
Reg No. DMC/R/03398
Radiologist

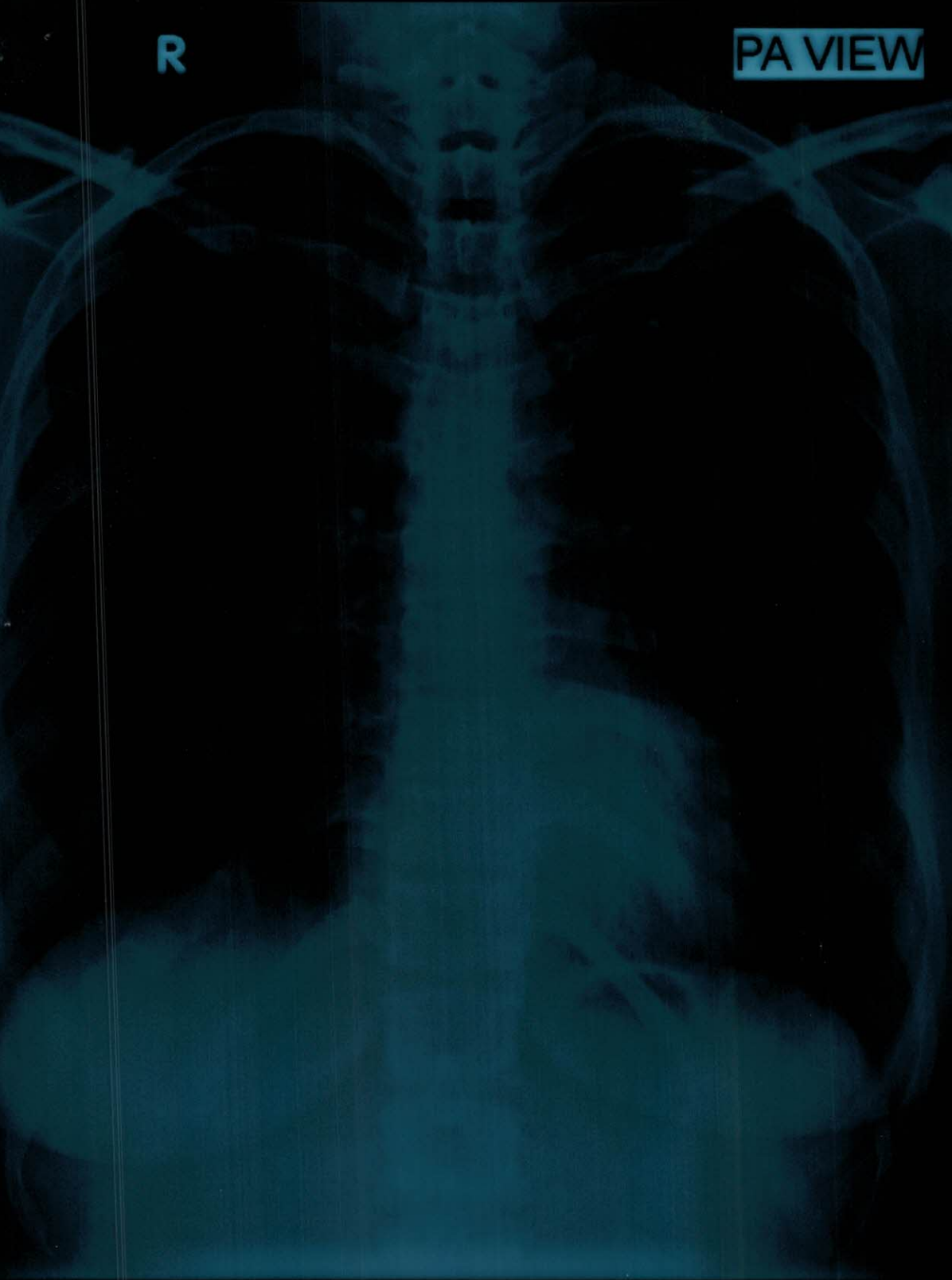
Type By : darshita

47, Harsh Vihar, Pitampura, New Delhi-110034 | Ph.: 011-42480101, 9599913051
E-mail: oneplusul@gmail.com | Web.: www.oneplusul.in

Clinical correlation is essential for final diagnosis. • If test results are unsatisfactory please contact personally or on phone. • This report is for perusal of doctors only.
• All disputes Subject to Delhi Jurisdiction only. • Not for medicolegal purposes. • All congenital anomalies in a foetus may not be diagnosed in routine obstetric ultrasound.

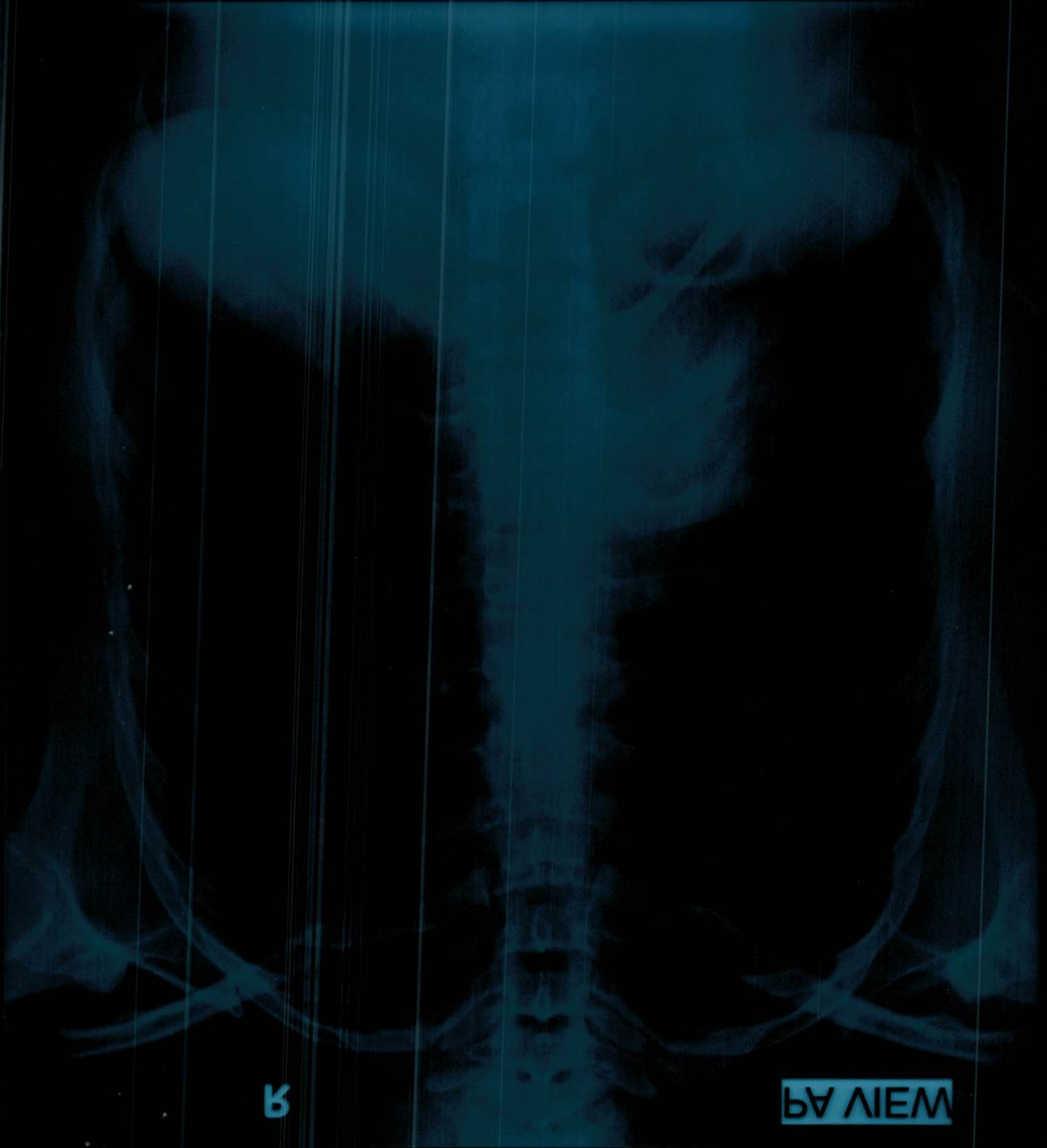R

PA VIEW



MRS ANNU RANI AGE 31 YRS 26-6-2021 F CHEST PA
OnePLUS ULTRASOUND LAB, 47-HARSH VIHAR, PITAMPURA

ONPGLS UGTRAGOUND GAB'AT-HAPSH VINAAP'BITAMPUBA
MPS ANIU BANACE 31 YPS 3E-8-3051 E CHESTPA



B

WELIAP



OnePLUS
Ultrasound Lab
— QUALITY FIRST... ALWAYS! —

Dr. Nitin Agarwal
Pathologist & Director
Ex. Sr. Res. MAMC
& Lok Nayak Hospital
Ex. Chief of Lab Dr. Lal Path Labs.

Dr. Pooja (Garg) Agarwal
Radiologist & Director
MAMC & Lok Nayak Hospital

| | | | |
|----------------|------------------|-------------------|-----------------|
| Name | : Mrs. ANNU RANI | Age/Sex | : 31 YRS/Female |
| Ref. By | : Dr. MEDIWHEEL | Lab No | : 012106260024 |
| Date | : 26-Jun-2021 | Patient ID | : LSHHI80562 |

ULTRASOUND EXAMINATION----WHOLE ABDOMEN

Liver is normal in size and outline with normal echopattern. Intrahepatic biliary radicles are not dilated. No abscess or mass lesion seen. Hepatic veins, portal vein, IVC and aorta are normal. CBD is normal in caliber.

Gall bladder is well distended with anechoic lumen. Wall thickness is normal.

Both kidneys are normal in size, shape, position, outline and echopattern. Corticomedullary differentiation is maintained. No pelvicalyceal dilation or mass lesion is seen.

Spleen is normal in size and echotexture. No mass lesion seen.

Pancreas is normal in size, outline and echotexture.

Urinary bladder is normal in shape and position. No evidence of intravesical stone or mass seen.

Uterus. is normal in size (measures 7.8 x 4.4 cm), shape, position and echopattern. No mass seen

Uterine cavity is empty. Endometrial thickness is 12.3 mm

Both ovaries appear normal in size, shape and echopattern. No tubo-ovarian mass seen.

No abnormal bowel wall thickening seen in right iliac fossa.
No free fluid seen anywhere in abdomen.

IMPRESSION:

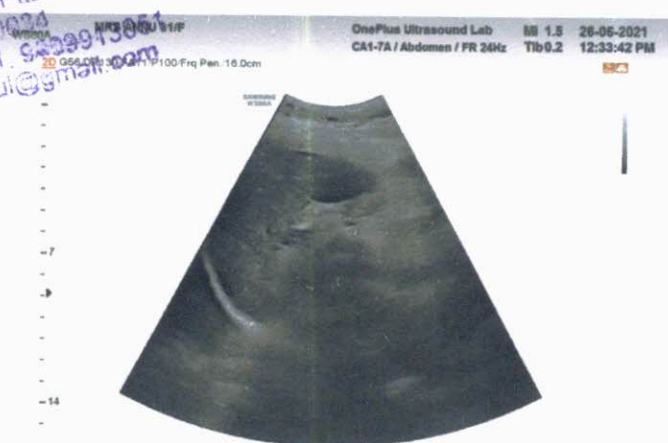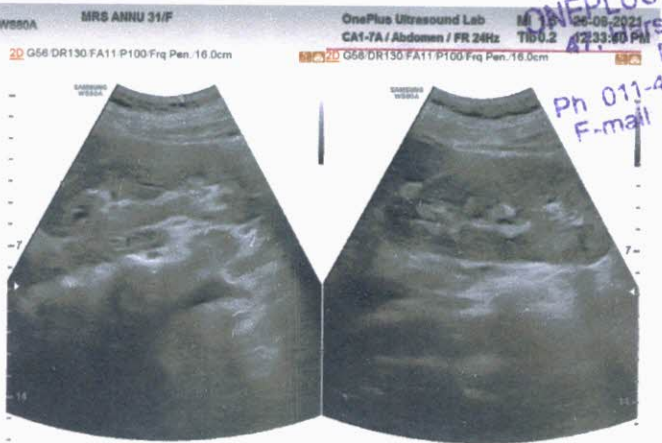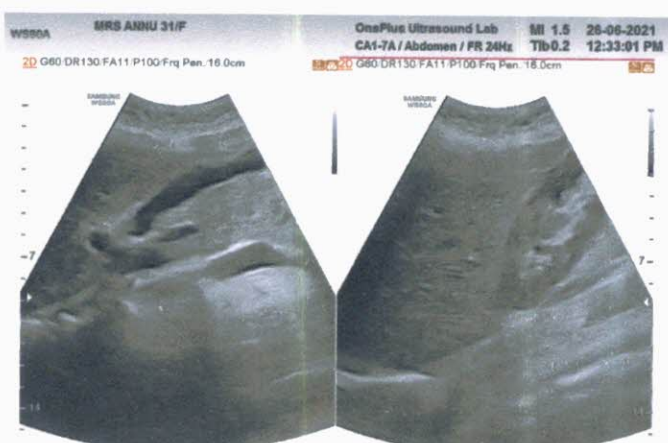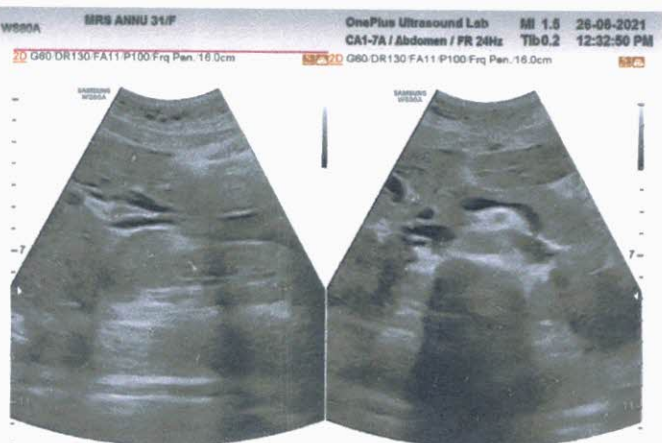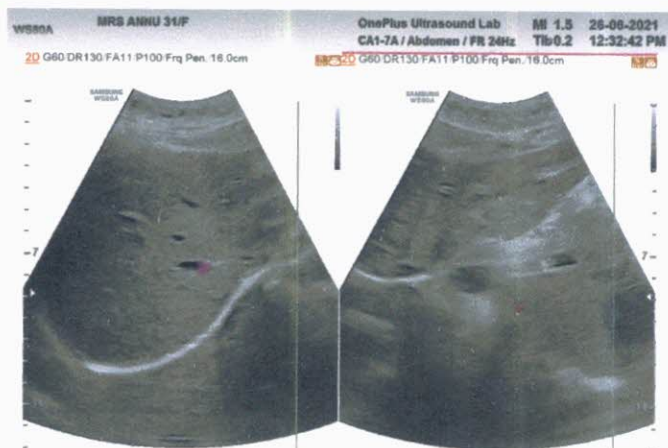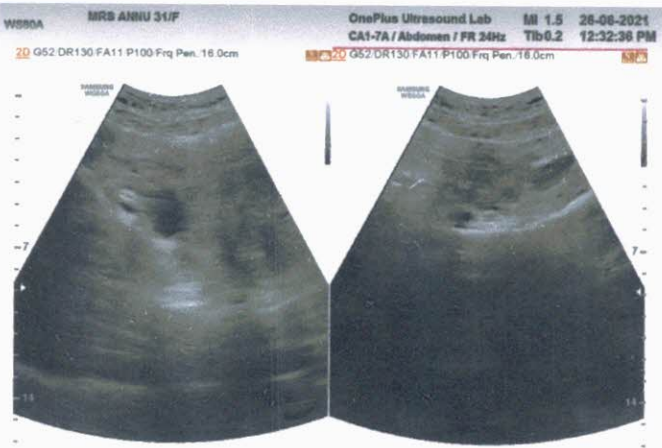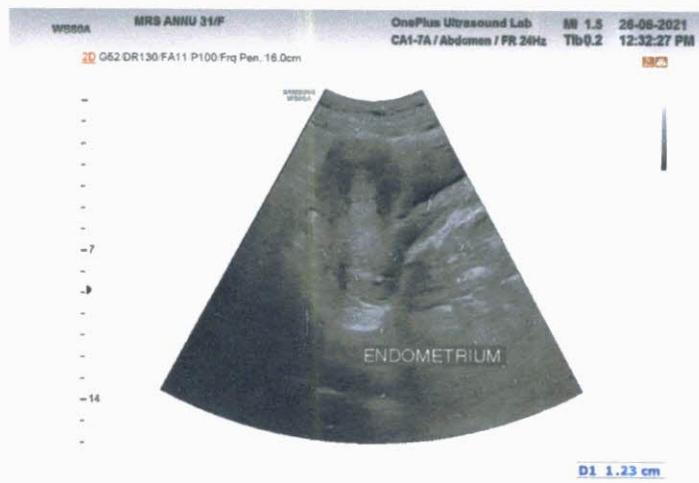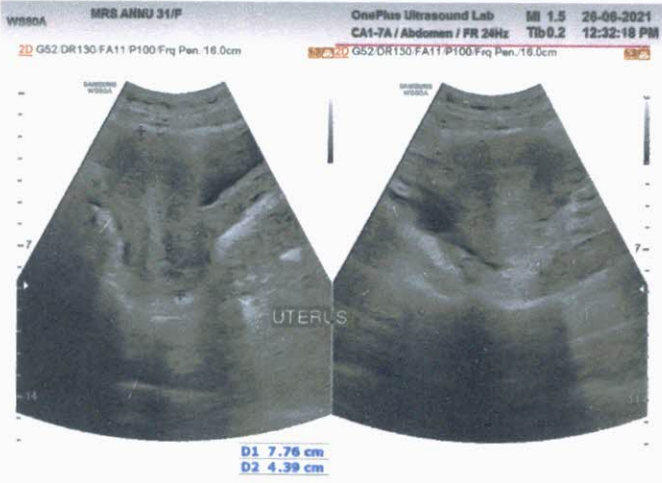
- Normal study.

DR. POOJA GARG
RADIOLOGIST
REG NO- DMC/R/03398

Dr. POOJA GARG
M.B.B.S., D.M.R.D.
Reg No. DMC/R/03398
Radiologist

Type By : darshita

47, Harsh Vihar, Pitampura, New Delhi-110034 | Ph.: 011-42480101, 9599913051
E-mail: oneplusul@gmail.com | Web.: www.oneplusul.in



ONEPLUS ULTRASOUND LAB
47, Fresh Vihar, Pitam Pura
Deli-110024
Ph 011-42480101, 9439913041
F-mail oneplusul@gmail.com



OnePLUS
Ultrasound Lab
— QUALITY FIRST... ALWAYS! —

Dr. Nitin Agarwal
Pathologist & Director
Ex. Sr. Res. MAMC
& Lok Nayak Hospital
Ex. Chief of Lab Dr. Lal Path Labs.

Dr. Pooja (Garg) Agarwal
Radiologist & Director
MAMC & Lok Nayak Hospital



| | | | |
|-------------|-------------------------|-------------------|----------------------|
| NAME | :Mrs. ANNU RANI | Barcode No | :10099335 |
| AGE/GENDER | :31 YRS/Female | SPECIMEN DATE | :26/Jun/2021 10:19AM |
| PATIENT ID | :80562 | SPECIMEN RECEIVED | :26/Jun/2021 10:38AM |
| REFERRED BY | :Dr. MEDIWHEEL | REPORT DATE | :26/Jun/2021 04:55PM |
| CENTRE NAME | :ONEPLUS ULTRASOUND LAB | LAB NO. | :012106260024 |

| Test Name | Result | Unit | Ref. Range |
|-----------|--------|------|------------|
|-----------|--------|------|------------|

HAEMATOLOGY

Health checkup 2 Female

| | | | |
|--|-----|---|--|
| Glycosylated Hemoglobin (HbA1c) | 5.2 | % | Non Diabetic adults <5.7 Prediabetic (at risk) 5.7-6.4 Diabetes >6.4 |
|--|-----|---|--|

Estimated average blood glucose (eag) 103

Reference range (mg/dl):

90 - 120:Excellent control, 121 - 150:Good Control, 151 - 180:Average Control, 181 - 210:Action Suggested

>211:Panic value

REMARKS:-

In vitro quantitative determination of **HbA1C** in whole blood is utilized in long term monitoring of glycemia. The **HbA1C** level correlates with the mean glucose concentration prevailing in the course of the patient's recent history (approx - 6-8 weeks) and therefore provides much more reliable information for glycemia monitoring than do determinations of blood glucose or urinary glucose. It is recommended that the determination of **HbA1C** be performed at intervals of 4-6 weeks during Diabetes Mellitus therapy. On testing of HbA1C by HPLC method the result shows high variant window (93.8%) & no value of HbA1C. Therefore for accurate assay of glycaemic Control Fructosamine assay & for variant analysis Hb electrophoresis should be done.

Assay done by : Bio-Rad : D-10 (HPLC)

Checked By.

DR. NITIN AGARWAL
MBBS,MD(PATHOLOGIST)

Dr. NITIN AGARWAL

M.B.B.S., MD (Path)

MC/R/01436

47, Harsh Vihar, Pitampura, New Delhi-110034 | Ph.: 011-42480101, 9599913051 Page 1 of 7

E-mail: oneplusul@gmail.com | Web.: www.oneplusul.in



OnePLUS
Ultrasound Lab

— QUALITY FIRST... ALWAYS! —

Dr. Nitin Agarwal
Pathologist & Director
Ex. Sr. Res. MAMC
& Lok Nayak Hospital
Ex. Chief of Lab Dr. Lal Path Labs.

Dr. Pooja (Garg) Agarwal
Radiologist & Director
MAMC & Lok Nayak Hospital



| | | | |
|-------------|-------------------------|-------------------|----------------------|
| NAME | :Mrs. ANNU RANI | Barcode No | :10099335 |
| AGE/GENDER | :31 YRS/Female | SPECIMEN DATE | :26/Jun/2021 10:19AM |
| PATIENT ID | :80562 | SPECIMEN RECEIVED | :26/Jun/2021 10:38AM |
| REFERRED BY | :Dr. MEDIWHEEL | REPORT DATE | :26/Jun/2021 02:54PM |
| CENTRE NAME | :ONEPLUS ULTRASOUND LAB | LAB NO. | :012106260024 |

| Test Name | Result | Unit | Ref. Range |
|-----------|--------|------|------------|
|-----------|--------|------|------------|

HAEMATOLOGY

BLOOD GROUP (ABO)

O

Rh typing

POSITIVE

NOTE :

- * Apart from major A,B,H antigens which are used for ABO grouping and Rh typing, many minor blood group antigens exist. Agglutination may also vary according to titre of antigen and antibody.
- * So before transfusion, reconfirmation of blood group as well as cross-matching is needed.
- * Presence of maternal antibodies in newborns, may interfere with blood grouping.
- * Auto agglutination (due to cold antibody, falciparum malaria, sepsis, internal malignancy etc.) may also cause erroneous result.

CBC

| | | | |
|--|--------|--------------|---------------|
| Haemoglobin | 10.6 | g/dl | 11.5-15.0 |
| Total Leucocyte Count | 5730 | /cumm | 4000-10000 |
| <u>Differential leucocyte count</u> | | | |
| Neutrophils | 49.5 | % | 40-80 |
| Lymphocyte | 41.00 | % | 20-40 |
| Monocytes | 5.60 | % | 2-10 |
| Eosinophils | 3.7 | % | 1-6 |
| Basophils | 0.2 | % | 0-2 |
| RBC Count | 4.06 | million/cumm | 3.8-4.8 |
| PCV(Hematocrit) | 34.5 | % | 36-46 |
| MCV | 85.1 | fL | 83-101 |
| MCH | 26.1 | Pg | 27-32 |
| MCHC | 30.7 | G/dL | 32-35 |
| Platelet count | 302000 | /cumm | 150000-450000 |
| RDW-CV | 15.6 | % | 11.4-14.0 |
| ESR(WESTEGRENs METHOD) | 16 | mm/1hr | <20 |

BIOCHEMISTRY

Checked By.

DR. NITIN AGARWAL
MBBS,MD(PATHOLOGIST)

Dr. NITIN AGARWAL
M.B.B.S., MD (Path)
DNC/1701436

47, Harsh Vihar, Pitampura, New Delhi-110034 | Ph.: 011-42480101, 9599913051 Page 2 of 7
E-mail: onepusul@gmail.com | Web.: www.oneplusul.in



OnePLUS Ultrasound Lab

— QUALITY FIRST... ALWAYS! —

Dr. Nitin Agarwal

Pathologist & Director
Ex. Sr. Res. MAMC
& Lok Nayak Hospital
Ex. Chief of Lab Dr. Lal Path Labs.

Dr. Pooja (Garg) Agarwal

Radiologist & Director
MAMC & Lok Nayak Hospital



| | | | |
|-------------|-------------------------|-------------------|----------------------|
| NAME | :Mrs. ANNU RANI | Barcode No | :10099335 |
| AGE/GENDER | :31 YRS/Female | SPECIMEN DATE | :26/Jun/2021 10:19AM |
| PATIENT ID | :80562 | SPECIMEN RECEIVED | :26/Jun/2021 10:38AM |
| REFERRED BY | :Dr. MEDIWHEEL | REPORT DATE | :26/Jun/2021 02:54PM |
| CENTRE NAME | :ONEPLUS ULTRASOUND LAB | LAB NO. | :012106260024 |

| Test Name | Result | Unit | Ref. Range |
|----------------------------|--------|-------|------------|
| <u>Blood sugar fasting</u> | 86 | mg/dL | 70-110 |

Checked By.

DR. NITIN AGARWAL
MBBS,MD(PATHOLOGIST)

Dr. NITIN AGARWAL
M.B.B.S, MD (Path)
DMC/R/01436

47, Harsh Vihar, Pitampura, New Delhi-110034 | Ph.: 011-42480101, 9599913051
E-mail: oneplusul@gmail.com | Web.: www.oneplusul.in



OnePLUS Ultrasound Lab

— QUALITY FIRST... ALWAYS! —

Dr. Nitin Agarwal
Pathologist & Director
Ex. Sr. Res. MAMC
& Lok Nayak Hospital
Ex. Chief of Lab Dr. Lal Path Labs.

Dr. Pooja (Garg) Agarwal
Radiologist & Director
MAMC & Lok Nayak Hospital



| | | | |
|-------------|-------------------------|-------------------|----------------------|
| NAME | :Mrs. ANNU RANI | Barcode No | :10099335 |
| AGE/GENDER | :31 YRS/Female | SPECIMEN DATE | :26/Jun/2021 10:19AM |
| PATIENT ID | :80562 | SPECIMEN RECEIVED | :26/Jun/2021 01:50PM |
| REFERRED BY | :Dr. MEDIWHEEL | REPORT DATE | :26/Jun/2021 04:55PM |
| CENTRE NAME | :ONEPLUS ULTRASOUND LAB | LAB NO. | :012106260024 |

| Test Name | Result | Unit | Ref. Range |
|-----------------------|--------|-------|------------|
| BIOCHEMISTRY | | | |
| <u>Blood sugar pp</u> | 135 | mg/dL | 70.0-140.0 |

Checked By.


DR. NITIN AGARWAL
MBBS, MD(PATHOLOGIST)

Dr. NITIN AGARWAL
MBBS, MD (Path)
DMC/R/01436

47, Harsh Vihar, Pitampura, New Delhi-110034 | Ph.: 011-42480101, 9599913051 Page 4 of 7
E-mail: oneplusul@gmail.com | Web.: www.oneplusul.in



OnePLUS

Ultrasound Lab

— QUALITY FIRST... ALWAYS! —

Dr. Nitin Agarwal
Pathologist & Director
Ex. Sr. Res. MAMC
& Lok Nayak Hospital
Ex. Chief of Lab Dr. Lal Path Labs.

Dr. Pooja (Garg) Agarwal
Radiologist & Director
MAMC & Lok Nayak Hospital



| | | | |
|-------------|-------------------------|-------------------|----------------------|
| NAME | :Mrs. ANNU RANI | Barcode No | :10099335 |
| AGE/GENDER | :31 YRS/Female | SPECIMEN DATE | :26/Jun/2021 10:19AM |
| PATIENT ID | :80562 | SPECIMEN RECEIVED | :26/Jun/2021 10:38AM |
| REFERRED BY | :Dr. MEDIWHEEL | REPORT DATE | :26/Jun/2021 02:54PM |
| CENTRE NAME | :ONEPLUS ULTRASOUND LAB | LAB NO. | :012106260024 |

| Test Name | Result | Unit | Ref. Range |
|-----------|--------|------|------------|
|-----------|--------|------|------------|

BIOCHEMISTRY

| | | | |
|-----------------------------------|-------|-------|----------|
| Bun (blood urea nitrogen) | 13.80 | mg/dl | 7-18.7 |
| Uric acid, serum | 5.2 | mg/dl | 2.4-5.7 |
| Creatinine, serum | 0.64 | mg/dl | 0.60-1.1 |

LFT(LIVER FUNCTION TEST)

| | | | |
|-------------------------------|------|-------|-------------|
| Bilirubin Total | 0.62 | mg/dl | 0.1-1.2 |
| Bilirubin Conjugated | 0.35 | mg/dl | 0-0.4 |
| Bilirubin Unconjugated | 0.27 | mg/dl | up to 0.7 |
| SGOT (AST) | 26 | U/L | 0-31 |
| SGPT (ALT) | 11 | U/L | <34 |
| Alkaline phosphatase | 117 | U/L | 64-306 |
| Gamma glutamyl transpeptidase | 29 | U/L | 9-39 |
| Total Protein | 6.7 | gm/dl | 6.40 - 8.20 |
| Albumin | 3.8 | g/dL | 3.5-5.5 |
| Globulin | 2.90 | gm/dl | 1.8-3.4 |
| Albumin/Globulin Ratio | 1.31 | | 1.10 - 2.50 |

LIPID PROFILE

| | | | |
|-----------------------|------|-------|--|
| Cholesterol | 147 | mg/dl | 50-240 |
| Triglycerides | 104 | mg/dL | 25-150 |
| HDL Cholesterol | 46 | mg/dL | 30 - 70 |
| LDL cholesterol | 80 | mg/dL | < 130 |
| VLDL cholesterol | 20.8 | mg/dL | 5-40 |
| Cholesterol/HDL Ratio | 3.2 | | Low Risk 3.3-4.97 Average Risk 4.4-7.1 Moderate Risk 7.1-11.0 High Risk >11.0 |
| LDL/HDL Ratio | 1.7 | | 0 - 3.55 |

According to ATP III and NCEP guidelines

Checked By.

DR. NITIN AGARWAL
MBBS,MD(PATHOLOGIST)

Dr. NITIN AGARWAL
M.B.B.S., MD (Path)
MAMC/NO1436

47, Harsh Vihar, Pitampura, New Delhi-110034 | Ph.: 011-42480101, 9599913051 Page 5 of 7

E-mail: oneplusul@gmail.com | Web.: www.oneplusul.in

Clinical correlation is essential for final diagnosis. • If test results are unsatisfactory please contact personally or on phone. • This report is for perusal of doctors only. • All disputes Subject to Delhi Jurisdiction only. • Not for medicolegal purposes. • All congenital anomalies in a foetus may not be diagnosed in routine obstetric ultrasound.



OnePLUS Ultrasound Lab

QUALITY FIRST... ALWAYS!

Dr. Nitin Agarwal
Pathologist & Director
Ex. Sr. Res. MAMC
& Lok Nayak Hospital
Ex. Chief of Lab Dr. Lal Path Labs.

Dr. Pooja (Garg) Agarwal
Radiologist & Director
MAMC & Lok Nayak Hospital



| | | | |
|-------------|-------------------------|-------------------|----------------------|
| NAME | :Mrs. ANNU RANI | Barcode No | :10099335 |
| AGE/GENDER | :31 YRS/Female | SPECIMEN DATE | :26/Jun/2021 10:19AM |
| PATIENT ID | :80562 | SPECIMEN RECEIVED | :26/Jun/2021 10:38AM |
| REFERRED BY | :Dr. MEDIWHEEL | REPORT DATE | :26/Jun/2021 02:54PM |
| CENTRE NAME | :ONEPLUS ULTRASOUND LAB | LAB NO. | :012106260024 |

| Test Name | Result | | | Unit | Ref. Range |
|-------------------|--------------------------------------|-----------|------------|------|------------|
| | Normal | Desirable | Borderline | | |
| Total cholesterol | <200 | 200-239 | | | 240 |
| Triglycerides | <150 | 150-199 | 200-499 | | 500 |
| LDL | Optimal <100 Near Optimal 100-129 | 130-159 | 160-180 | | 190 |
| HDL | <40 : LOW 60 : HIGH | | | | |

ENDOCRINOLOGY

THYROID PROFILE(T3,T4,TSH)

| | | | |
|-----------------------------------|------|--------|----------|
| Triiodothyronine total [t3] | 0.65 | ng/dl | 0.52-1.9 |
| Thyroxine total [t4] | 7.50 | µg/dl | 4.8-11.6 |
| TSH (Thyroid Stimulating Hormone) | 2.20 | µIU/ml | 0.25-5.0 |

AGE WISE VARIATION IN TSH

| AGE | TSH(µIU/ml) | AGE | TSH(µIU/ml) |
|-----------|-------------|----------------------------|-------------|
| 1-4 weeks | 1.00 - 19.0 | 16-20 yrs | 0.25 - 5.0 |
| 1-12 mths | 1.70 - 9.1 | 21 - 80 yrs | 0.25 - 5.0 |
| 1-5 yrs | 0.80 - 8.2 | I st trimester | 0.25 - 5.0 |
| 6-10 yrs | 0.25 - 5.0 | II nd trimester | 0.50 - 5.0 |
| 11-15 yrs | 0.25 - 5.0 | II rd trimester | 0.4 - 6.0 |

Reference ranges - Interpretation of Diagnostic tests - (Jacques Wallach)

1. Primary hypothyroidism is accompanied by depressed serum T3 and T4 values and elevated serum TSH level.
2. Primary hyperthyroidism is accompanied by elevated serum T3 and T4 levels along with depressed TSH values.
3. Slightly elevated T3 levels may be found in pregnancy and estrogen therapy, while depressed levels may be encountered in severe illness, renal failure and during therapy with drugs like propranolol and propyl thiouracil.
4. Although elevated TSH levels are nearly always indicative of primary hypothyroidism, and may be seen in secondary thyrotoxicosis

Checked By.

DR. NITIN AGARWAL
MBBS,MD(PATHOLOGIST)

47, Harsh Vihar, Pitampura, New Delhi-110034 | Ph.: 011-42480101, 9599913051
E-mail: oneplusul@gmail.com | Web.: www.oneplusul.in



OnePLUS Ultrasound Lab

— QUALITY FIRST... ALWAYS! —

Dr. Nitin Agarwal
Pathologist & Director
Ex. Sr. Res. MAMC
& Lok Nayak Hospital
Ex. Chief of Lab Dr. Lal Path Labs.

Dr. Pooja (Garg) Agarwal
Radiologist & Director
MAMC & Lok Nayak Hospital



| | | | |
|-------------|-------------------------|-------------------|----------------------|
| NAME | :Mrs. ANNU RANI | Barcode No | :10099335 |
| AGE/GENDER | :31 YRS/Female | SPECIMEN DATE | :26/Jun/2021 10:19AM |
| PATIENT ID | :80562 | SPECIMEN RECEIVED | :26/Jun/2021 10:38AM |
| REFERRED BY | :Dr. MEDIWHEEL | REPORT DATE | :26/Jun/2021 04:55PM |
| CENTRE NAME | :ONEPLUS ULTRASOUND LAB | LAB NO. | :012106260024 |

| Test Name | Result | Unit | Ref. Range |
|-----------|--------|------|------------|
|-----------|--------|------|------------|

CLINICAL PATHOLOGY

URINE ROUTINE

Physical examination

| | | | |
|--------------|-----------------|--|-------------|
| Quantity | 20 | | ML |
| Colour | PALE YELLOW | | |
| Transparency | SLIGHTLY TURBID | | CLEAR |
| Sp.gravity | 1.015 | | 1.010-1.030 |
| pH | 6.00 | | |
| Reaction | ACIDIC | | ACIDIC |

Chemical examination

| | | | |
|------------------|----------|--|----------|
| Urine protein | NIL | | NIL |
| Urine sugar | NIL | | NIL |
| Bilirubin, urine | NEGATIVE | | NEGATIVE |
| Urobilinogen | NORMAL | | NORMAL |
| Ketones | NEGATIVE | | NEGATIVE |

Microscopic examination

| | | | |
|-------------------|------|------|-----|
| Pus cells. | 1-2 | /HPF | 1-2 |
| Epithelial cells | 8-10 | /HPF | 0-5 |
| R.B.C. | NIL | /HPF | NIL |
| Casts | NIL | /HPF | NIL |
| Crystals | NIL | /HPF | NIL |
| Bacteria | NIL | /HPF | NIL |
| Others. | NIL | | NIL |

*** End Of Report ***

Checked By.

DR. NITIN AGARWAL
MBBS, MD(PATHOLOGIST)

Dr. NITIN AGARWAL

M.B.B.S., MD (Pathology)
DMC/R/01436

47, Harsh Vihar, Pitampura, New Delhi-110034 | Ph.: 011-42480101, 9599913051 Page 7 of 7

E-mail: oneplusul@gmail.com | Web.: www.oneplusul.in

Clinical correlation is essential for final diagnosis. • If test results are unsatisfactory please contact personally or on phone. • This report is for perusal of doctors only.
• All disputes Subject to Delhi Jurisdiction only. • Not for medicolegal purposes. • All congenital anomalies in a foetus may not be diagnosed in routine obstetric ultrasound.

ONEPLUS ULTRASOUND LAB

47, HARSH VIHAR, PITAMPURA, DELHI- 110034

Ms. ANNU RANI
 Age : 31/F
 Ref. by : MEDIWHEEL
 Indication1 :
 Indication2 :
 Indication3 :
 COMMENTS :

ID : 1652
 HWWT : 158/55
 Recorded : 26-6-2021 11:25
 Medication1 :
 Medication2 :
 Medication3 :

BPM : 87
 BP : 110/64
 P Axis : 73 deg
 QRS Axis : 60 deg
 T Axis : 41 deg

P duration : 86 msec
 PR duration : 153 msec
 QRS duration : 90 msec
 QT interval : 326 msec
 QTc interval : 373 msec

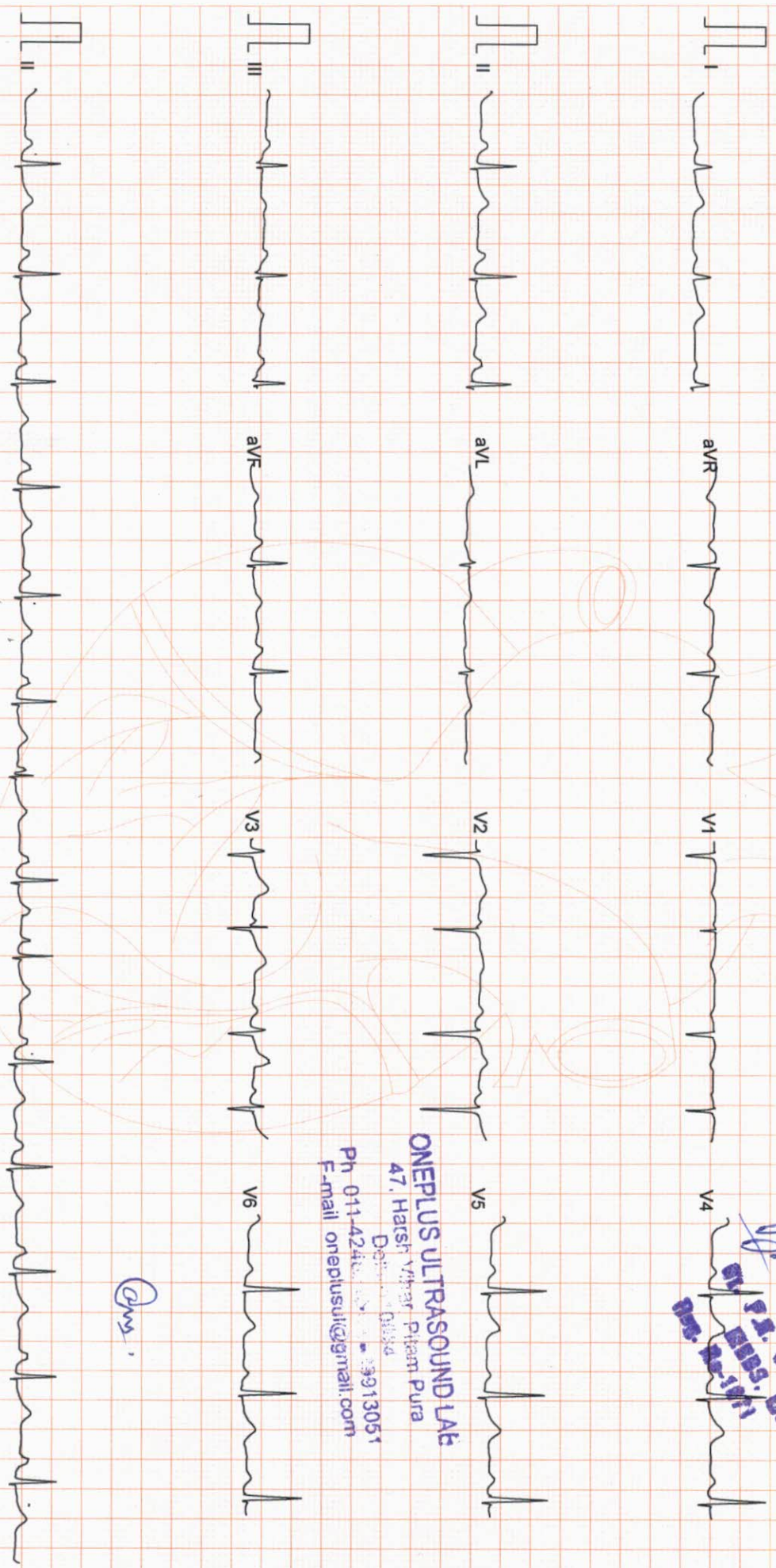
Raw E.C.G.(Seq)

Dr. P. J. Gupta

DR. P. J. GUPTA
MBBS, MD
Reg. No. 1971

Unconfirmed Report Reviewed By:

Cardiologist



Filtered

25mm/sec 10mm/mV

ARROW

CardiCom, INDIA

ONEPLUS ULTRASOUND LAB
 47, Harsh Vihar Pitampura
 Delhi-110034
 Ph 011-42400000 - 3913051
 E-mail onepplus@gmail.com

Dr. P. J. Gupta

ONEPLUS ULTRASOUND LAB

47, HARSH VIHAR PITAMPURA DELHI 110034

ID : 999

HVM: 158/55

Recorded : 26-6-2021 11:28

TREADMILL TEST SUMMARY REPORT

Protocol: BRUCE

History:

Medication 1 :

Medication 2 :

Medication 3 :

Ms. ANNU RANI

Age : 31/F

Ref. by : MEDIWHEEL

Indication 1 :

Indication 2 :

Indication 3 :

| PHASE | PHASE TIME | STAGE TIME | SPEED (Km./Hr.) | GRADE (%) | H.R. (BPM) | B.P. (mmHg) | RPP X100 | II | ST LEVEL (mm) V2 | V5 | METS |
|-----------------|------------|------------|-----------------|-----------|------------|------------------|----------|------------|------------------|------------|------|
| STANDING SUPINE | | | | | 86 79 | 110/64 110/64 | 94 86 | 0.2 0.3 | 1.0 1.0 | 0.4 0.4 | |
| STAGE 1 | 2:59 | 2:59 | 2.70 | 10.00 | 107 | 124/68 | 132 | 0.1 | 0.9 | 0.4 | 4.80 |
| STAGE 2 | 5:59 | 2:59 | 4.00 | 12.00 | 135 | 132/70 | 178 | 0.2 | 0.9 | 0.3 | 7.10 |
| STAGE 3 | 8:29 | 2:29 | 5.40 | 14.00 | 162 | 134/74 | 217 | 0.0 | 1.0 | 0.4 | 9.51 |
| PEAK EXER | 8:42 | 2:42 | | | 182 | 140/76 | 254 | 0.6 | 1.6 | 0.8 | 9.72 |
| RECOVERY | 2:59 | 2:59 | 0.00 | 0.00 | 97 | 116/66 | 112 | 0.1 | 0.8 | 0.0 | |

RESULTS

Exercise Duration : 8:42 Minutes

Max Heart Rate : 182 bpm 96 % of target heart rate 189 bpm

Max Blood Pressure : 140/76 mmHg

Max Work Load : 9.72 METS

Reason of Termination :

IMPRESSIONS :

Normal for age

Cardiologist **P. I. GUPTA**
M.D.S. GD
Reg. No-1671

ONEPLUS ULTRASOUND LAB
47, Harsh Vihar, Pitampura
Delhi-110034
Ph 011-42480104, 6299913051
E-mail onepulsul@gmail.com

ONEPLUS ULTRASOUND LAB

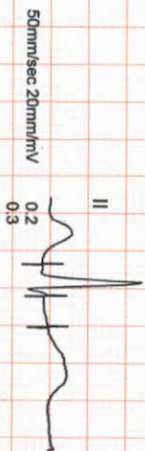
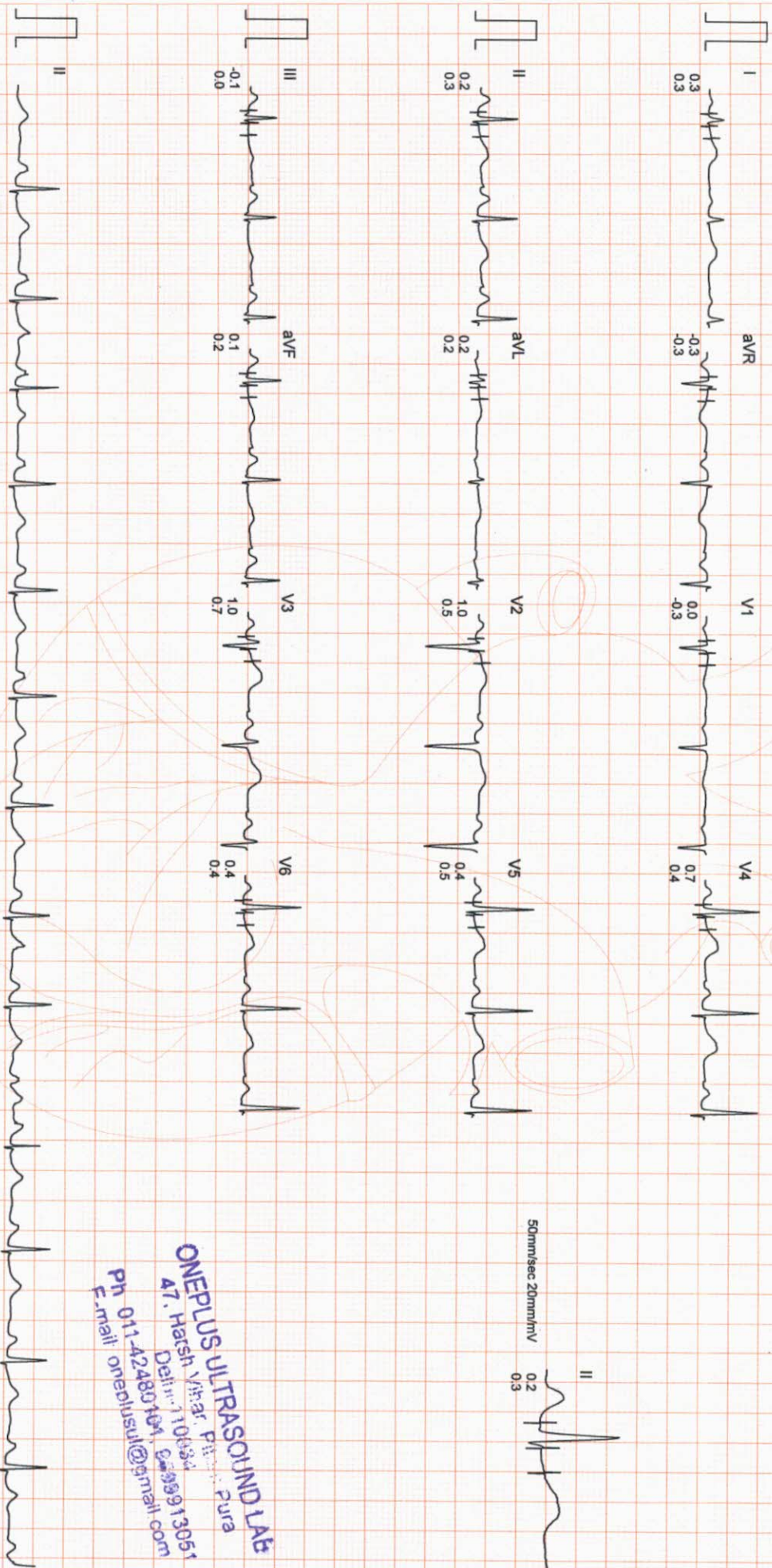
STANDING
PRETEST

ST @ 10mm/mV
80ms PostJ

Ms. ANNU RANI
I.D. : 999
AGE/SEX : 31/F
RECORDED : 26-6-2021 11:28

RATE : 86 BPM
B.P. : 110/64 mmHg

LINKED MEDIAN



ONEPLUS ULTRASOUND LAB
47, Harsh Vihar, Pitambara Pura
Delhi-110034
Ph 011-42480104, 699913051
E-mail: oneplusul@gmail.com

Filtered

Computer Corrected Baseline

25mm/sec 10mm/mV

ARROW

CardiCom, INDIA Ph.:091-731-2620740; TeleFax:091-731-2431214

ONEPLUS ULTRASOUND LAB

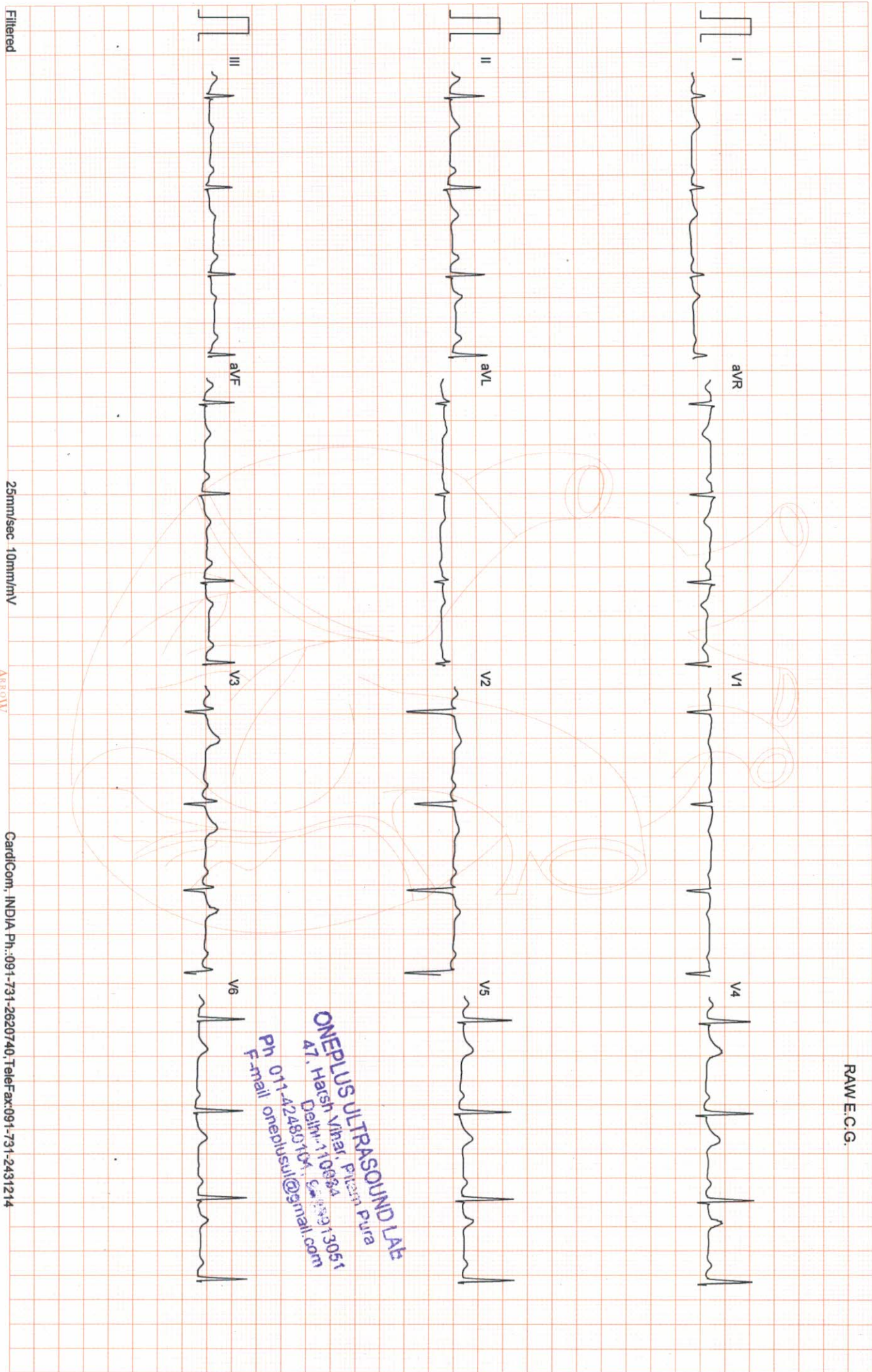
SUPINE
PRETEST

ST @ 10mm/mV
80ms PostJ

Ms. ANNU RANI
I.D. : 999
AGE/SEX : 31/F
RECORDED : 26-6-2021 11:28

RATE : 79 BPM
B.P. : 110/64 mmHg

RAW E.C.G.



Filtered

25mm/sec 10mm/mV

ARROW

CardiCom, INDIA Ph.:091-731-2620740, TeleFax:091-731-2431214

ONEPLUS ULTRASOUND LAB
47, Harsh Vihar, Pitampura
Delhi-110084
Ph 011-42480107, 42480108
F-mail: oneplusul@snmail.com
www.oneplusul.com

ONEPLUS ULTRASOUND LAB

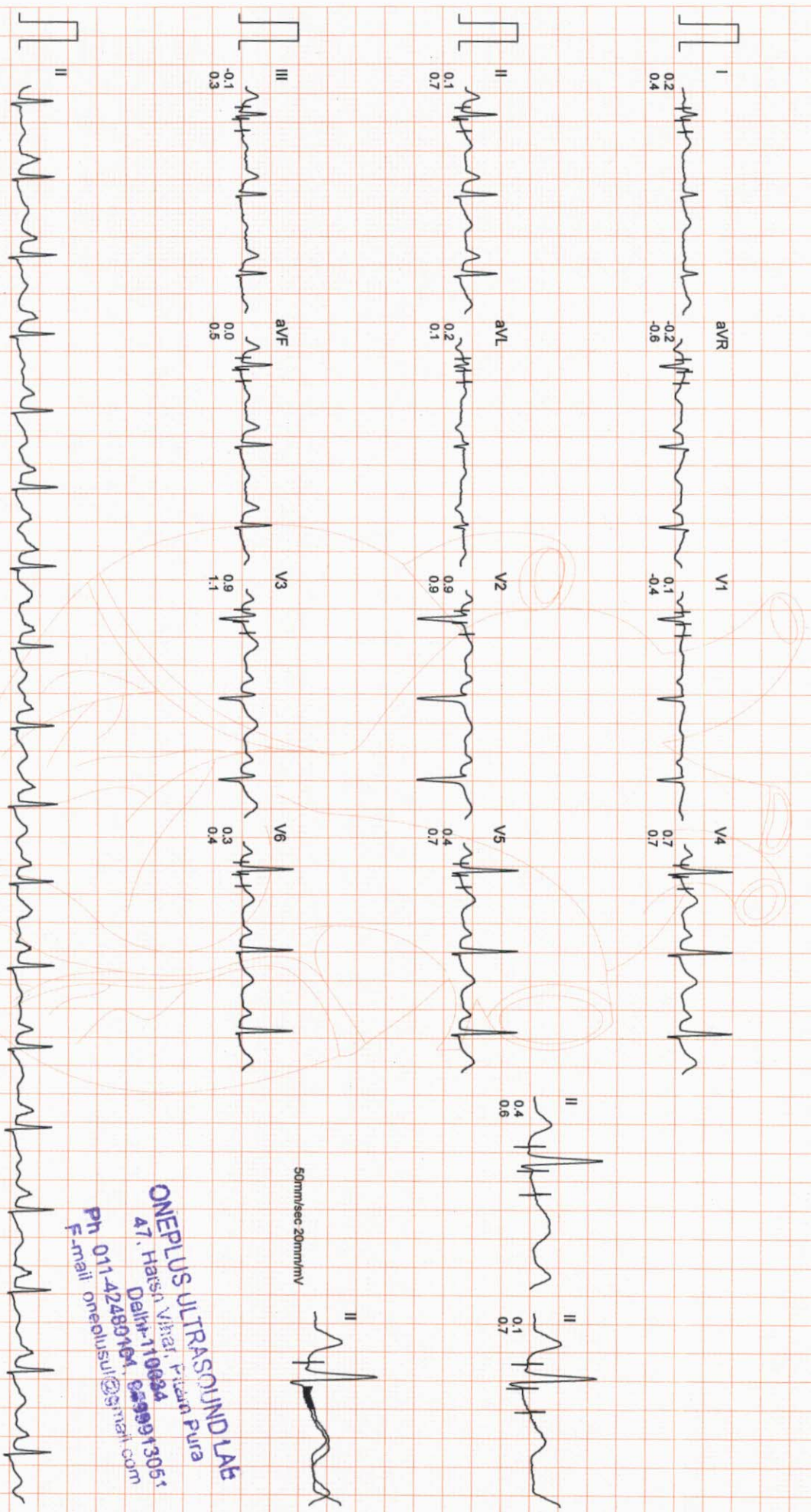
Ms. ANNU RANI
 I.D. : 999
 AGE/SEX : 31/F
 RECORDED : 26-6-2021 11:28

RATE : 107 BPM
 B.P. : 124/68 mmHg

BRUCE
 EXERCISE 1
 PHASE TIME : 2:59
 STAGE TIME : 2:59

ST @ 10mm/mV
 80ms PostJ
 SPEED : 2.7 Km./Hr.
 GRADE : 10.0%

LINKED MEDIAN



ONEPLUS ULTRASOUND LAB
 47, Harsa Vihar, Fizaan Pura
 Delhi-110084
 Ph: 011-42489164, 999913051
 E-mail: oneplusul@sttmail.com

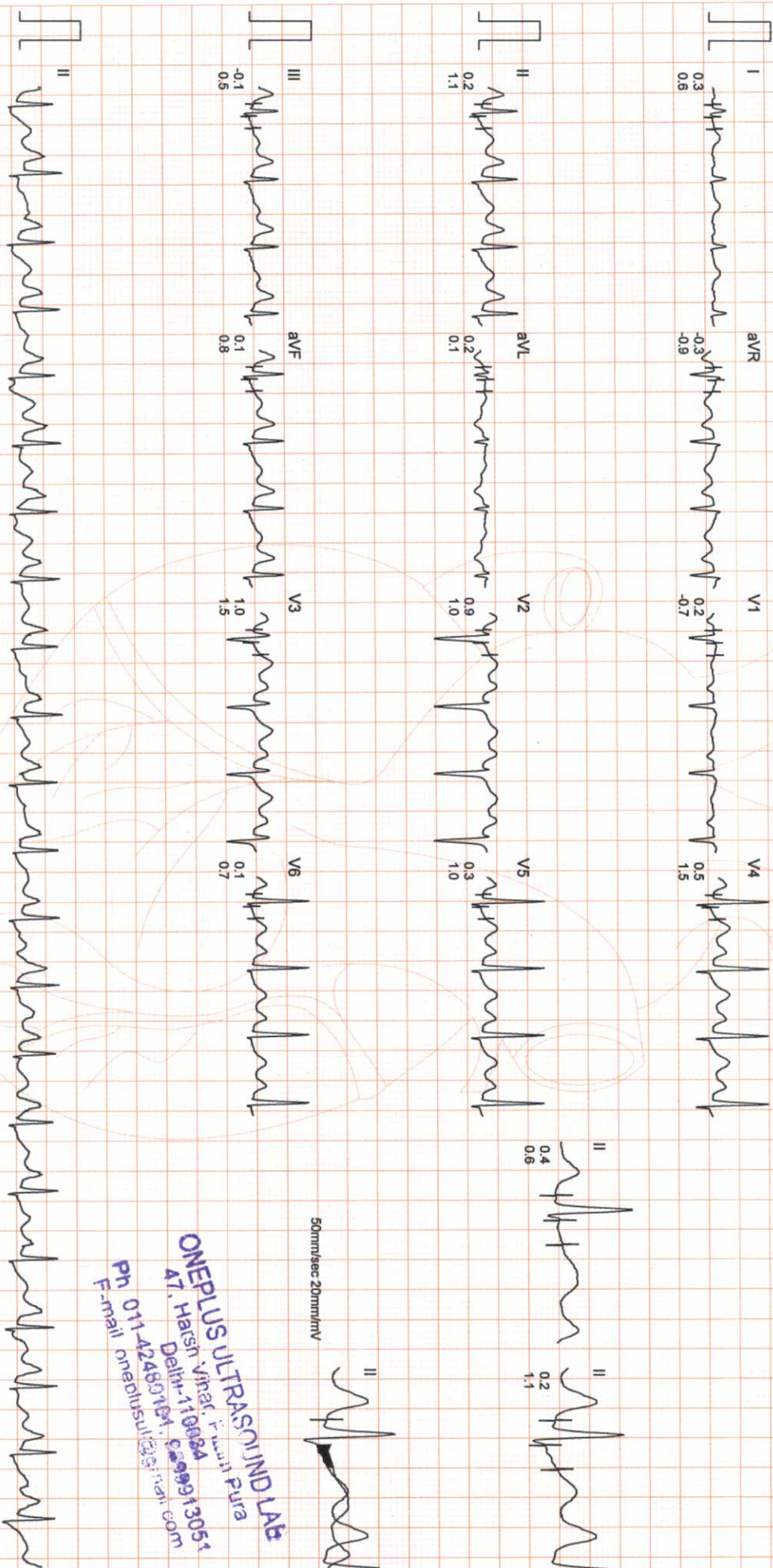
ONEPLUS ULTRASOUND LAB

Ms. ANNU RANI
I.D. : 999
AGE/SEX : 31/F
RECORDED : 26-6-2021 11:28

BRUCE
EXERCISE 2
PHASE TIME : 5:59
STAGE TIME : 2:59

ST @ 10mm/mV
80ms PostJ
SPEED : 4.0 Km./Hr.
GRADE : 12.0 %

LINKED MEDIAN



50mm/sec 20mm/mV

ONEPLUS ULTRASOUND LAB
47, Harsn Vihar, P. Connaught Place
Delhi-110084
Ph: 011-42480191, 6999913051
E-mail: onepusul@gniprati.com


ONEPLUS ULTRASOUND LAB

Ms. ANNU RANI
I.D. : 999
AGE/SEX : 31/F
RECORDED : 26-6-2021 11:28

BRUCE
EXERCISE 3
PHASE TIME : 8:29
STAGE TIME : 2:29

ST @ 10mm/mV
80ms PostJ
SPEED : 5.4 Km./hr.
GRADE : 14.0 %

LINKED MEDIAN



50mm/sec 20mm/mV

ONEPLUS ULTRASOUND LAB
PURA
47, Hareh, 99913051
Dr. Annu Rani
Ph: 011-42481100, 99913051
E-mail: onepusui@gmail.com

ONEPLUS ULTRASOUND LAB

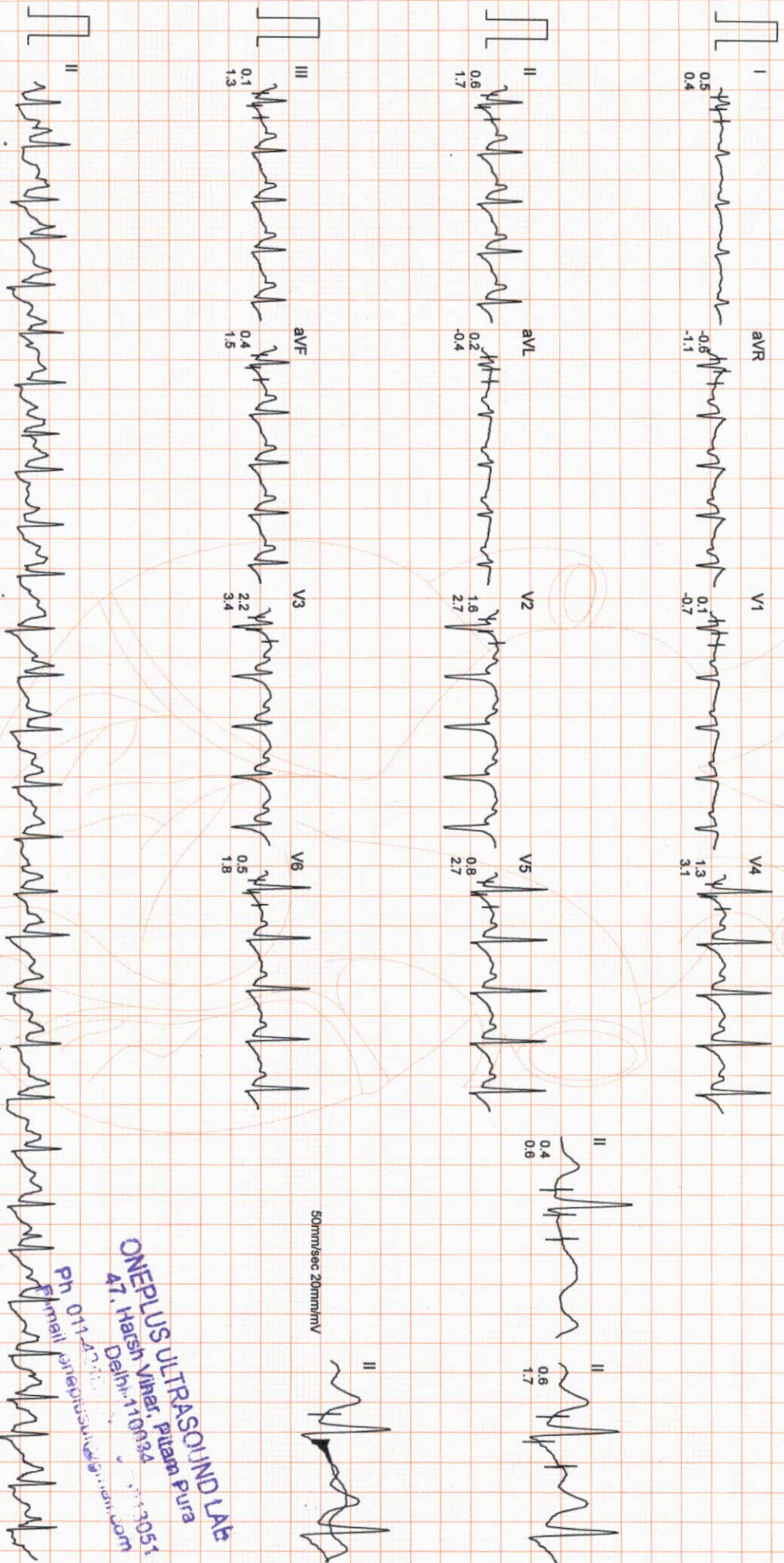
Ms. ANNU RANI
I.D. : 999
AGE/SEX : 31/F
RECORDED : 26-6-2021 11:28

RATE : 182 BPM
B.P. : 140/76 mmHg

BRUCE
PEAK EXER
PHASE TIME : 8:42
STAGE TIME : 2:42

ST @ 10mm/mV
80ms PostJ
SPEED : 5.4 Km./Hr.
GRADE : 14.0 %

LINKED MEDIAN



ONEPLUS ULTRASOUND LAB
47, Harsht, Vihar, Patna
Delhi-110034
Ph 011-26103511
Email oneplusultrasound@gmail.com

ONEPLUS ULTRASOUND LAB

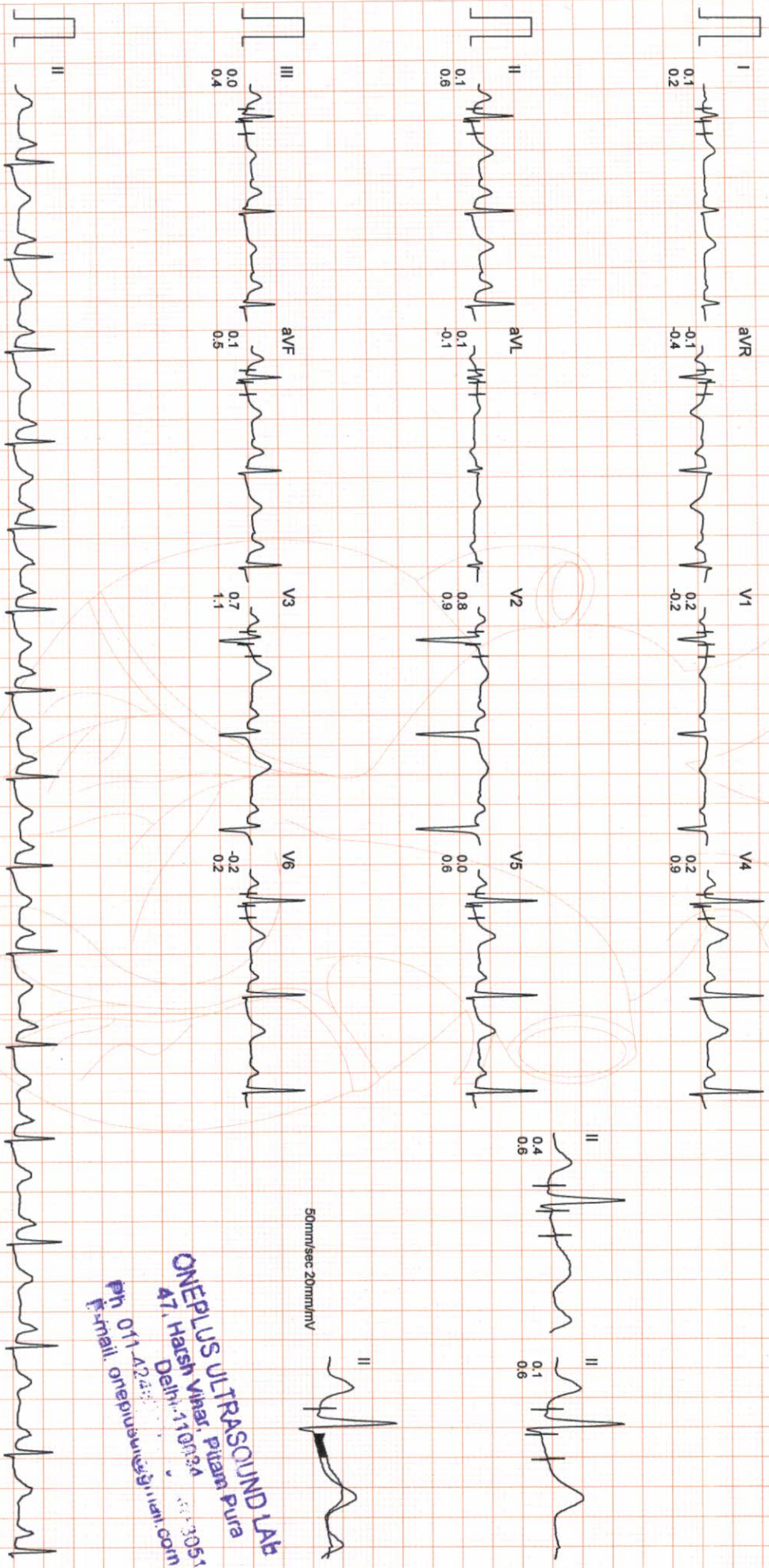
Ms. ANNU RANI
 I.D. : 999
 AGE/SEX : 31/F
 RECORDED : 26-6-2021 11:28

RATE : 97 BPM
 B.P. : 116/66 mmHg

BRUCE
 RECOVERY
 PHASE TIME : 2:59

ST @ 10mm/mV
 80ms PostJ
 SPEED : 0.0 Km./Hr.
 GRADE : 0.0 %

LINKED MEDIAN



Filtered Computer Corrected Baseline 25mm/sec 10mm/mV CardCom, INDIA Ph.:091-731-2620740, Telefax:091-731-2431214

ONEPLUS ULTRASOUND LAB
 47, Harsh Vihar, Pitampura
 Delhi-110034
 Ph: 011-43222222
 E-mail: info@oneplusultrasound.com

Ms. ANNU RANI

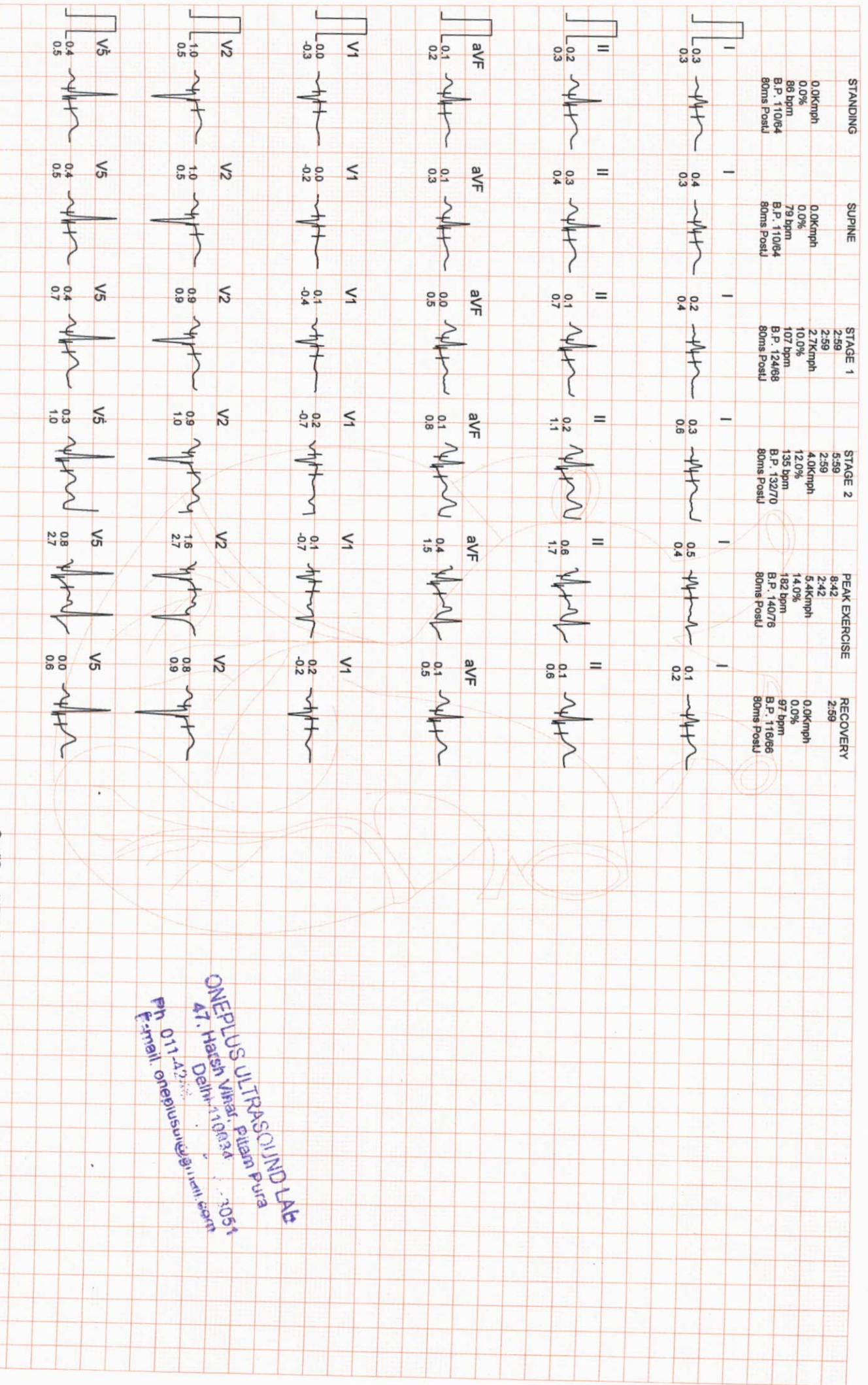
I.D. : 999

AGE/SEX : 31/F

ONEPLUS ULTRASOUND LAB

RECORDED : 26-6-2021 11:28

AVG E.C.G.

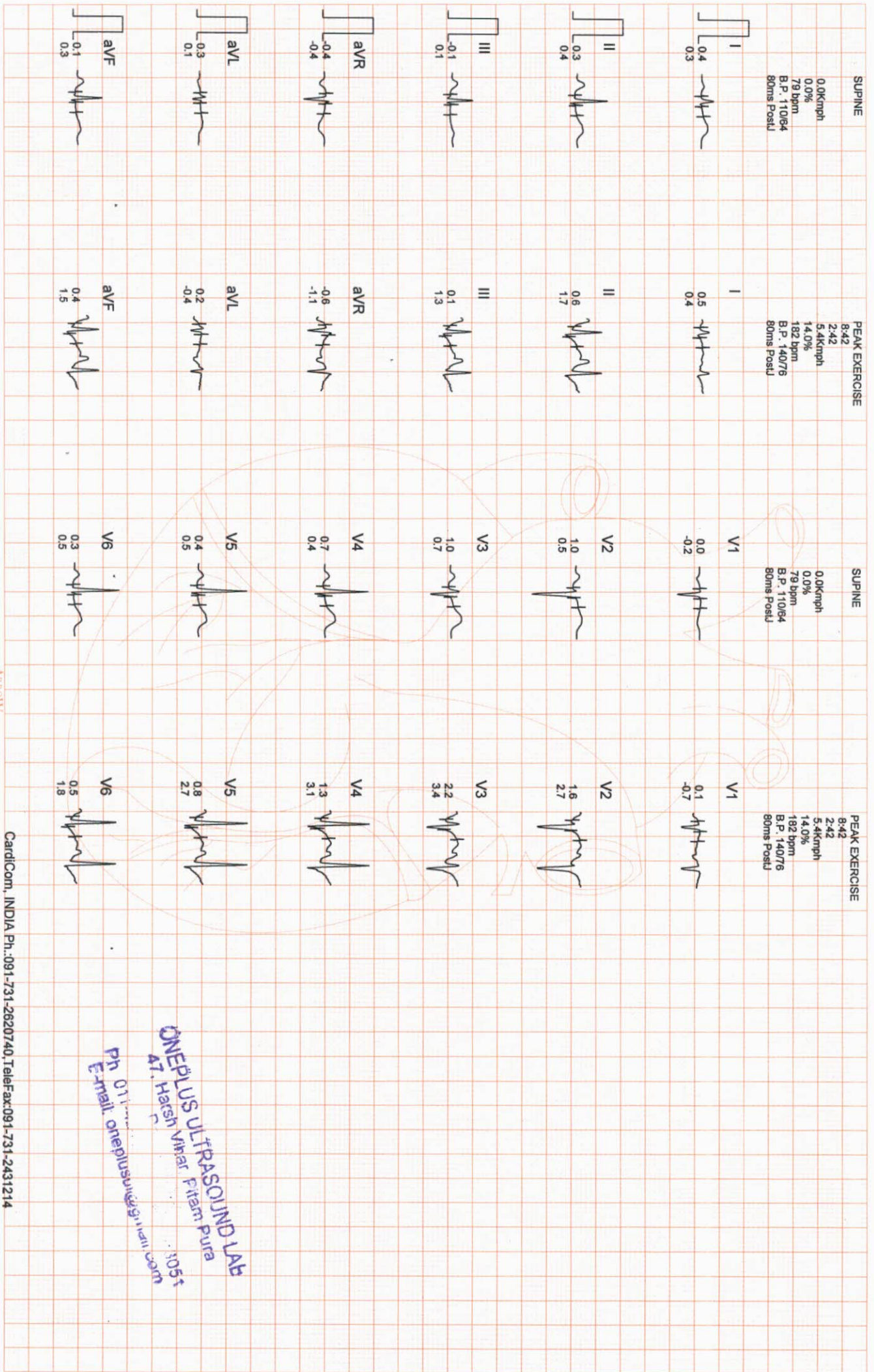


ONEPLUS ULTRASOUND LAB
 47, Harsik Mitra, Pitambar Pur
 Delhi-110034
 Ph: 011-47333333
 E-mail: onepplusultrasound@gmail.com

ONEPLUS ULTRASOUND LAB

RECORDED : 26-6-2021 11:28

COMPARISON REPORT



ONEPLUS ULTRASOUND LAB
 47, Harsh Vihar Pitam Pura
 Ph. 011-2620740
 Email: oneplusultrasound@gmail.com