


plm-5

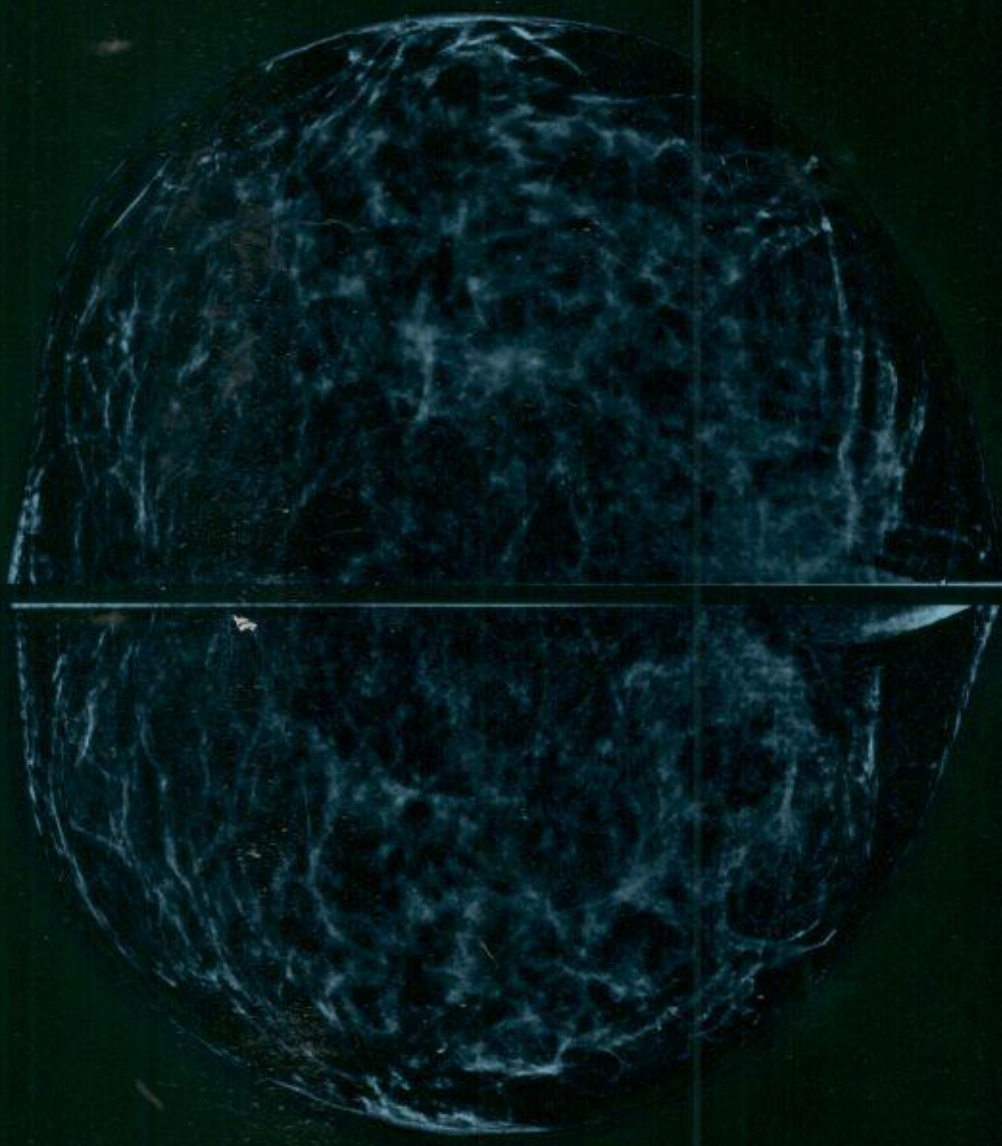


plm-5



DDRC AGILUS

ГАКШНИ Б А ДУЕ ТУПИСОСЗ
СУИГА СРД
ДРКС АГИНС
МАННОСРЪРЪНУ-СС МК00405В
ЗУ



Р-00

Г-00

us

8S0A00KW

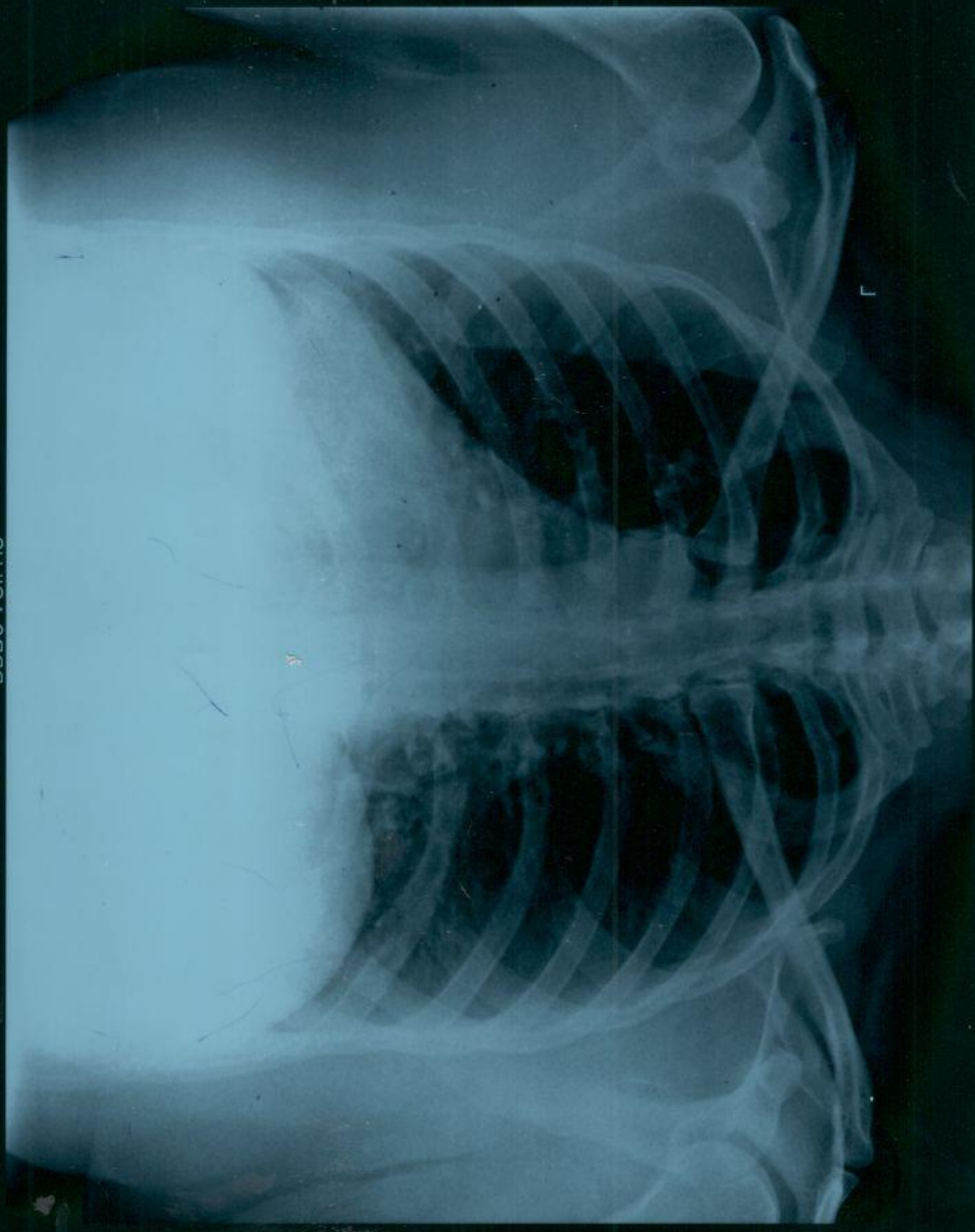
AP-T2EHC

3S0S111111

9 Y1P V 9

ГАРЭНН П

DDPC AGIGU2



V1

V2

V3

V4

ID: 004026

Diagnosis Information:

Female
41 Years
cm

/ mmHg
kg

Mw. Lakshmi, P.V



HR
P
PR
QRS
QT/QTc
P/QRS/T
RV5/SV1

: 69 bpm
: 109 ms
: 172 ms
: 86 ms
: 396/425 ms
: 51-4/20 °
: 0.389/0.317 mV
Report Confirmed by:

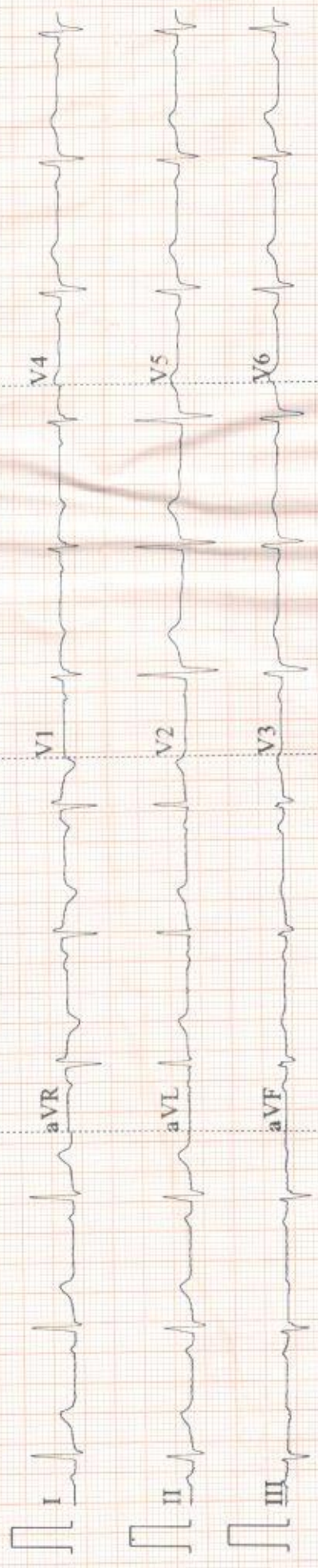
V6

Standard

17-2023

Standard	L I	L II	L III	L III Inspiration

ID: 004026 11-11-2023 08:47:18 AM



0.5~35Hz AC50 25mm/s 10mm/mV V1.0 SEMIP V1.7 DDRRC-AGILUS

Arrow CE

RADIOLOGY DIVISION

Acc no:4182WK004026	Name: Mrs. Lakshmi P V	Age:41 y	Sex:Female	Date: 11.11.23
---------------------	------------------------	----------	------------	----------------

US SCAN WHOLE ABDOMEN (TAS + TVS)

LIVER is mildly enlarged in size (15.3 cm). Margins are regular. Hepatic parenchyma shows increased echogenicity. No focal lesions seen. No dilatation of intrahepatic biliary radicles. CBD is not dilated. Portal vein is normal in caliber (11.2 mm).

GALL BLADDER is partially distended and grossly normal. No pericholecystic fluid seen.

SPLEEN is normal in size (11.2 cm) and parenchymal echotexture. No focal lesion seen.

PANCREAS Head and body visualized, appears normal in size and parenchymal echotexture. Pancreatic duct is not dilated.

RIGHT KIDNEY is normal in size (10.2 x 4.2 cm) and shows normal parenchymal echotexture. Cortico medullary differentiation is maintained. Parenchymal thickness is normal. No echogenic focus with shadowing suggestive of renal calculi seen. No dilatation of pelvicalyceal system seen. Ureter is not dilated. Perinephric spaces are normal.

LEFT KIDNEY is normal in size (11.4 x 4.4 cm) and shows normal parenchymal echotexture. Cortico medullary differentiation is maintained. Parenchymal thickness is normal. No echogenic focus with shadowing suggestive of renal calculi seen. No dilatation of pelvicalyceal system seen. Ureter is not dilated. Perinephric spaces are normal.

PARAAORTIC AREA No retroperitoneal lymphadenopathy or mass seen.

URINARY BLADDER is distended, normal in wall thickness, lumen clear.

UTERUS is retroverted, measures 9.3 x 5.2 x 4.2 cm. **Small intramural fibroid measuring 9.2 x 9.5 mm noted in anterior wall. A few other seedling fibroids also noted. Myometrial echopattern is mildly inhomogeneous.** Endometrial thickness is 10.6 mm.

Both ovaries are normal. Right ovary measures 2.8 x 1.9 cm and shows dominant follicle measuring 1.9 x 1.5 cm. Another large follicle measuring 1.3 x 1.2 cm also noted in right ovary. Left ovary measures 3.1 x 1.9 cm. No adnexal mass seen. No fluid in pouch of Douglas.

No ascites or pleural effusion.

Gaseous distension of bowel loops noted. No obvious bowel wall thickening seen sonologically.

Diastasis recti noted. Inter recti distance measures 3.2 cm at supraumbilical region.

CONCLUSION:-

- > **Mild hepatomegaly with grade II / III fatty changes - Suggest LFT correlation.**
- > **Small uterine fibroids.**


Dr. Nisha Unni MD , DNB (RD)
Consultant radiologist.

Thanks for referral. Your feedback will be appreciated.

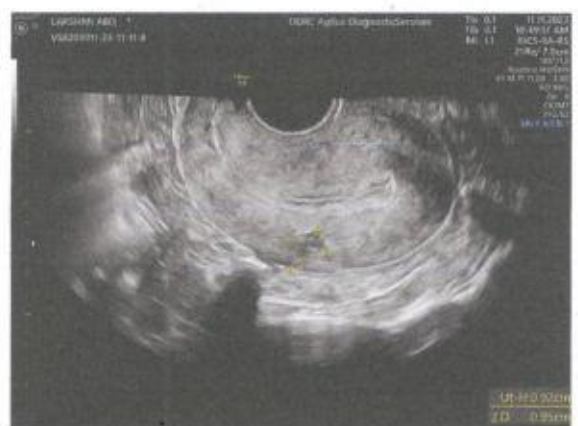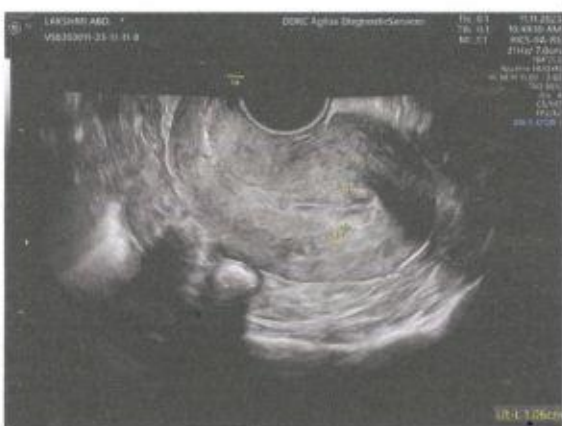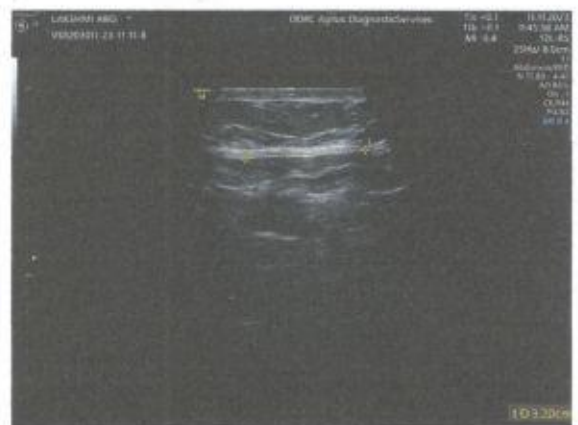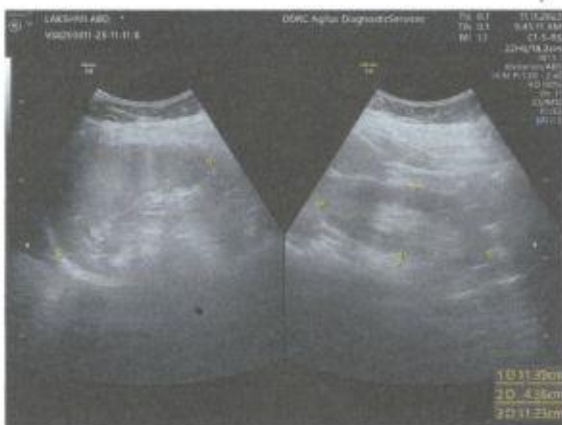
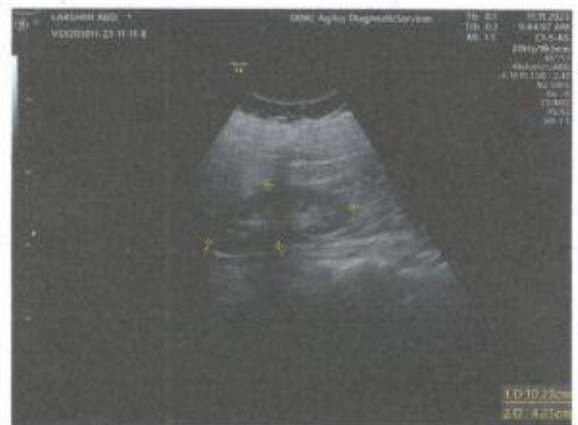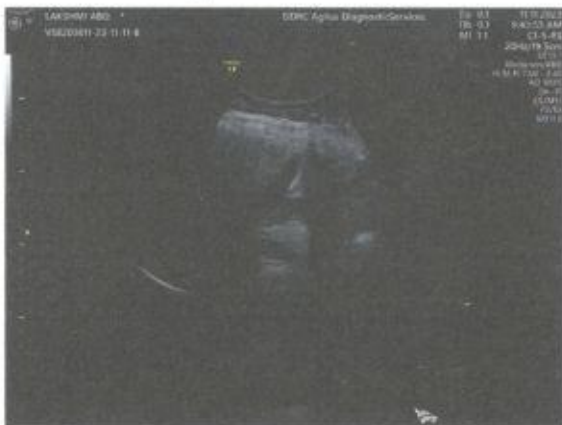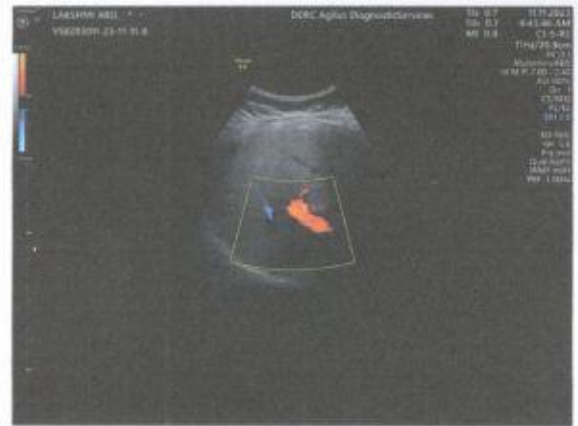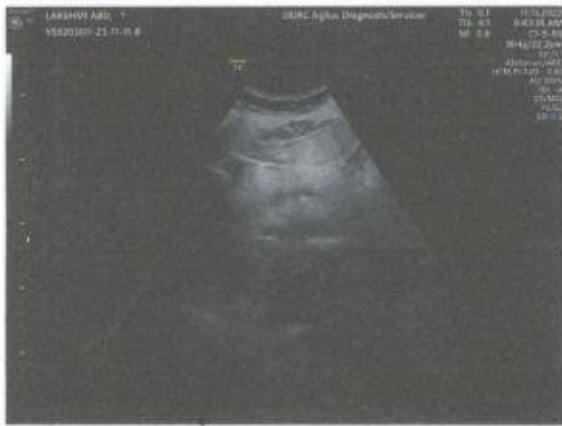(Please bring relevant investigation reports during all visits)

Because of technical and technological limitations complete accuracy cannot be assured on imaging.

Suggested correlation with clinical findings and other relevant investigations consultations and if required repeat imaging recommended in the event of controversies. AR

(For appointments and any clarification of report please contact **9496005190** between 9 am - 5.30 pm).

Contact :- 93334 93334, Web :- www.ddrcagilus.com Email :- info.ddrc@agilus.in



RADIOLOGY DIVISION

MAMMOGRAM REPORT (BOTH)

Acc no:4182WK004026	Name: Mrs. Lakshmi P V	Age:41 y	Sex:Female	Date: 11.11.23
---------------------	------------------------	----------	------------	----------------

(i) **INDICATION** : - Screening

(ii) **BREAST COMPOSITION** : -

RIGHT :Heterogeneously dense breast which may obscure small masses.

LEFT :Heterogeneously dense breast which may obscure small masses .

(iii) **OBSERVATION**:-

RIGHT :Punctate and round calcifications in diffuse distribution. No mass / asymmetry / architectural distortion. Suggestion of a few axillary lymphnodes.

LEFT :-Punctate and round calcifications in diffuse distribution.No mass / asymmetry / architectural distortion. Suggestion of a few axillary lymphnodes.

(iv)**COMPARISON WITH THE PREVIOUS STUDIES** : - Sonomammogram taken previously reports not available

(v) **ULTRASOUND FINDINGS** :-

RIGHT : **Breast composition** - Heterogeneous background echotexture - predominantly fatty.

No mass / cysts / intramammary duct dilation. Nipple areolar complex normal. A few morphologically benign axillary lymphnodes noted, largest measuring 1.7 x 0.7 cm.

LEFT : - **Breast composition** - Heterogeneous background echotexture - predominantly fatty.

No mass / cysts / intramammary duct dilation. Nipple areolar complex normal. A few morphologically benign axillary lymphnodes noted, largest measuring 1.8 x 0.5 cm.

(vi) **IMPRESSION** :-

RIGHT : - BIRADS assessment category - Benign

BIRADS numeric code - 2

LEFT : - BIRADS assessment category - Benign.

BIRADS numeric code - 2.

(vii) **RECOMMENDATIONS** : - Routine mammography screening.

Dr. Nisha Unni MD , DNB (RD)
Consultant radiologist.

Thanks, your feedback will be appreciated.

(Please bring relevant investigation reports during all visits).

Because of technical and technological limitations complete accuracy cannot be assured on imaging.

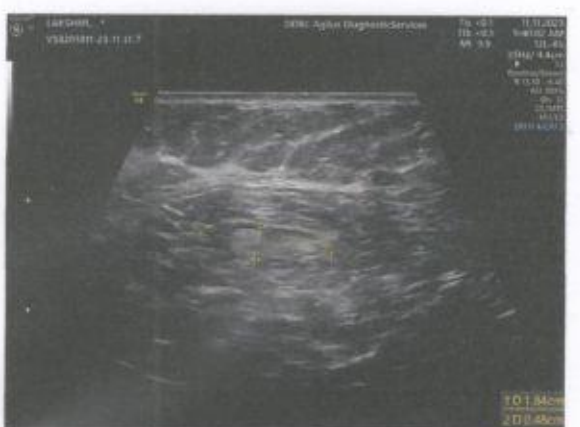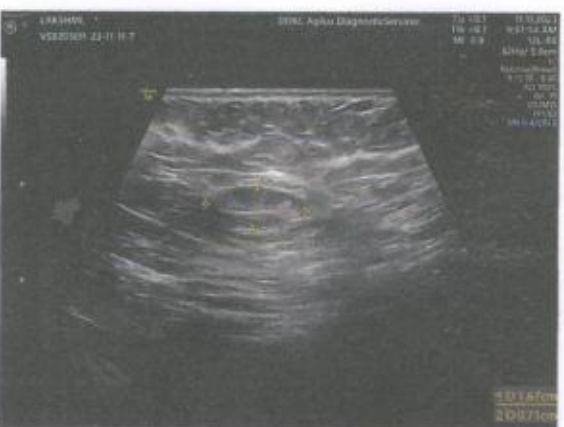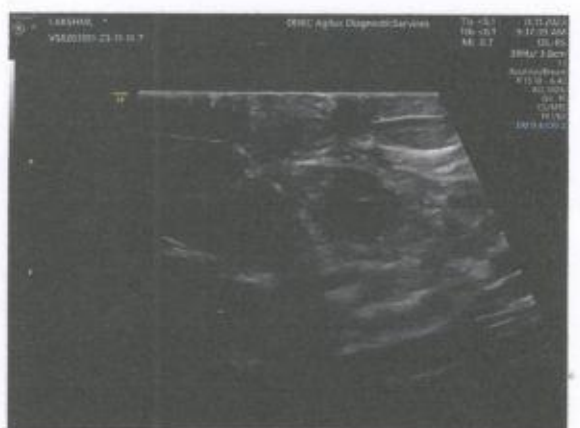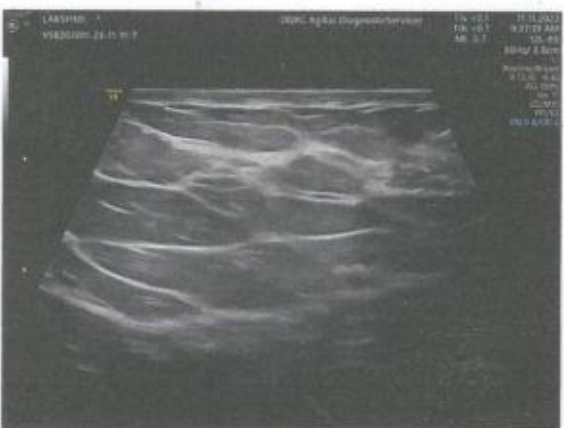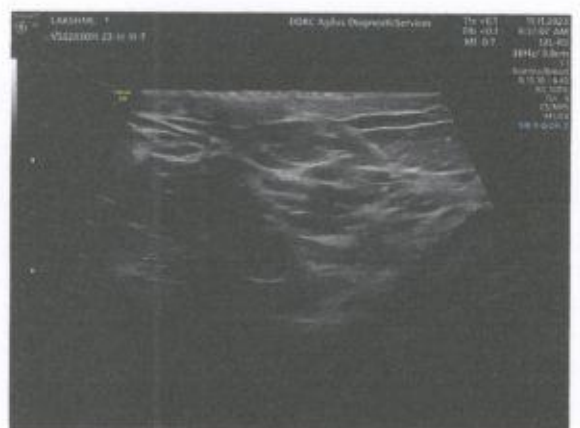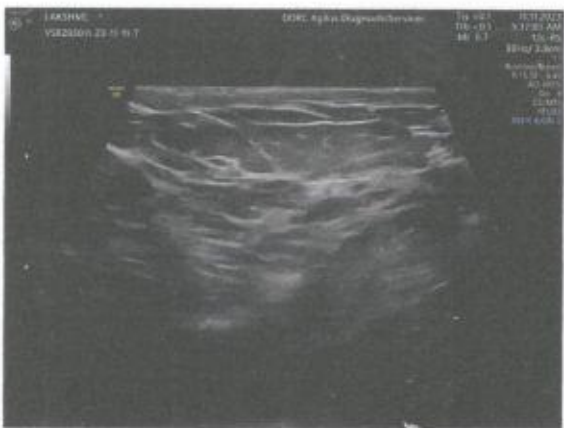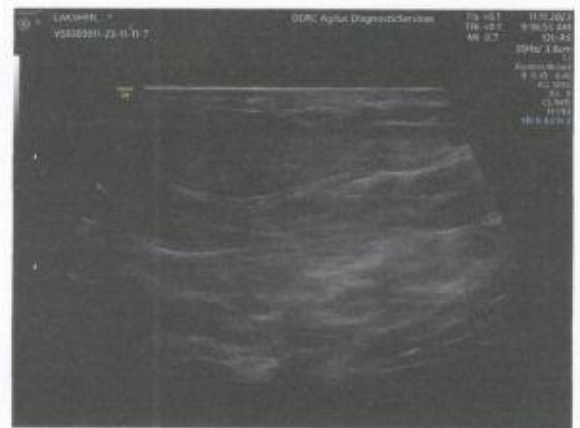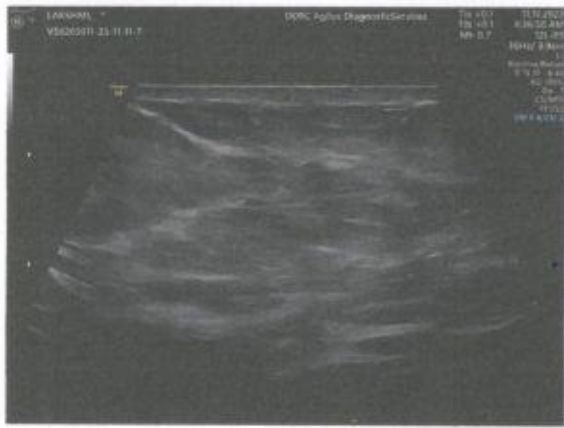Suggested correlation with clinical findings and other relevant investigations consultations , and if required repeat imaging recommended in the event of controversies.AR

(For appointments please contact **9496005190** between 9 am – 5.30 pm).

DDRC agilus Pathlabs Limited.

Corp. Office : Express House, Second Floor, Opp. Pothys Silks, Banerjee Road, Kaloor -682017

Contact :- 93334 93334, Web :- www.ddrcagilus.com Email :- info.ddrc@agilus.in



From:

Lakshmi Pr
TC 24/1636-1
Thycaud p^o
TUPM-16

To

DDRC
Towandem.

See

I am not interested to do physical & Dental
examination.Yours faithfully
Lakshmi Pr

11-11-23

Towandem.

ECHO REPORT

Name: LEKSHMI.P.V	Age/Sex:41Y/F	Date:11/11/2023
-------------------	---------------	-----------------

Left Ventricle:-

	Diastole	Systole
IVS	1.06cm	1.13cm
LV	4.66cm	2.75cm
LVPW	1.13cm	1.20cm

EF - 71% FS - 40%


AO	LA
3.39cm	3.75cm

PV - 0.97m/s
AV - 1.09m/s
MVE - 0.71m/s
MVA - 0.49m/s
E/A - 1.47

IMPRESSION:-

- Normal chambers dimensions
- No RWMA
- Good LV systolic function
- No diastolic dysfunction
- No AS,AR,MR,MS,TR,PAH
- No Vegetation/clot/effusion
- IAS/IVS intact




Consultant Cardiologist
Dr SHASHIKANTH Y.S
MBBS,MD,DM(Cardiology)
Consultant Cardiologist
TCMC Reg No: 73538

PATIENT NAME : MRS LAKSHMI P V
REF. DOCTOR : SELF
CODE/NAME & ADDRESS : CA00010147 -

 MEDIWHEEL ARCOFEMI HEALTHCARE LIMITED
 F701A, LADO SARAI, NEW DELHI, SOUTH DELHI,
 DELHI,
 SOUTH DELHI 110030
 8800465156

ACCESSION NO : 4182WK004026
PATIENT ID : MRSLF2909824182
CLIENT PATIENT ID:
ABHA NO :
AGE/SEX : 41 Years Female
DRAWN :
RECEIVED : 11/11/2023 08:03:09
REPORTED : 12/11/2023 08:24:13

Test Report Status	<u>Preliminary</u>	Results	Biological Reference Interval	Units
--------------------	--------------------	---------	-------------------------------	-------

MEDIWHEEL HEALTH CHECKUP ABOVE 40(F)2DECHO
PHYSICAL EXAMINATION

PHYSICAL EXAMINATION

REPORT GIVEN


**DR NISHA UNNI, MBBS,MD
 (RD),DNB (Reg.No:50162)
 Consultant Radiologist**

Page 1 Of 12



View Details



View Report

PERFORMED AT :

 DDRC AGILUS PATHLABS LIMITED
 ASTER SQUARE BUILDING, ULLOOR,
 MEDICAL COLLEGE P.O
 TRIVANDRUM, 695011
 KERALA, INDIA
 Tel : 93334 93334, Fax : CIN - U85190MH2006PTC161480
 Email : customercare.ddrc@agilus.in

Patient Ref. No. 66600006691235

PATIENT NAME : MRS LAKSHMI P V

REF. DOCTOR : SELF

CODE/NAME & ADDRESS : CA00010147 -
MEDIWHEEL ARCOFEMI HEALTHCARE LIMITED
F701A, LADO SARAI, NEW DELHI, SOUTH DELHI,
DELHI,
SOUTH DELHI 110030
8800465156

ACCESSION NO : **4182WK004026**
PATIENT ID : MRS LF2909824182
CLIENT PATIENT ID:
ABHA NO :

AGE/SEX : 41 Years Female
DRAWN :
RECEIVED : 11/11/2023 08:03:09
REPORTED : 12/11/2023 08:24:13

Test Report Status	Preliminary	Results	Units
--------------------	-------------	---------	-------

MEDIWHEEL HEALTH CHECKUP ABOVE 40(F)2DECHO**ECG WITH REPORT****REPORT**

REPORT GIVEN

2D - ECHO WITH COLOR DOPPLER**REPORT**

REPORT GIVEN

USG ABDOMEN AND PELVIS**REPORT**

REPORT GIVEN

CHEST X-RAY WITH REPORT**REPORT**

REPORT GIVEN

MAMMOGRAPHY -BOTH**REPORT**

REPORT GIVEN

HAEMATOLOGY**MEDIWHEEL HEALTH CHECKUP ABOVE 40(F)2DECHO****GLYCOSYLATED HEMOGLOBIN(HBA1C), EDTA WHOLE BLOOD**

HBA1C	5.4	Non-diabetic Adult < 5.7	%
-------	-----	--------------------------	---



DR NISHA UNNI, MBBS,MD
(RD),DNB (Reg.No:50162)
Consultant Radiologist



DR.VAISHALI RAJAN, MBBS DCP
(Pathology)
(Reg No - TCC 27150)
HOD - HAEMATOLOGY



DR. ASTHA YADAV, MD
Biochemistry
(Reg No - DMC/R/20690)
CONSULTANT BIOCHEMIST

Page 2 Of 12



View Details



View Report

PERFORMED AT :

DDRC AGILUS PATHLABS LIMITED
ASTER SQUARE BUILDING, ULLOOR,
MEDICAL COLLEGE P.O
TRIVANDRUM, 695011
KERALA, INDIA
Tel : 93334 93334, Fax : CIN - U85190MH2006PTC161480
Email : customercare.ddrc@agilus.in



Patient Ref. No. 66600006691235

PATIENT NAME : MRS LAKSHMI P V

REF. DOCTOR : SELF

CODE/NAME & ADDRESS : CA00010147 -

MEDIWHEEL ARCOFEMI HEALTHCARE LIMITED
F701A, LADO SARAI, NEW DELHI, SOUTH DELHI,
DELHI,
SOUTH DELHI 110030
8800465156ACCESSION NO : **4182WK004026**

PATIENT ID : MRSLF2909824182

CLIENT PATIENT ID:

ABHA NO :

AGE/SEX : 41 Years Female

DRAWN :

RECEIVED : 11/11/2023 08:03:09

REPORTED : 12/11/2023 08:24:13

Test Report Status	Preliminary	Results	Units
--------------------	-------------	---------	-------

MEAN PLASMA GLUCOSE	108.3	Pre-diabetes 5.7 - 6.4 Diabetes diagnosis: > or = 6.5 Therapeutic goals: < 7.0 Action suggested : > 8.0 (ADA Guideline 2021) < 116.0	mg/dL
---------------------	-------	---	-------

BLOOD COUNTS, EDTA WHOLE BLOOD

HEMOGLOBIN	13.6	12.0 - 15.0	g/dL
RED BLOOD CELL COUNT	4.68	3.80 - 4.80	mil/ μ L
WHITE BLOOD CELL COUNT	6.57	4.0 - 10.0	thou/ μ L
PLATELET COUNT	279	150 - 410	thou/ μ L

RBC AND PLATELET INDICES

HEMATOCRIT	40.6	36.0 - 46.0	%
MEAN CORPUSCULAR VOL	86.8	83.0 - 101	fL
MEAN CORPUSCULAR HGB.	29.1	27.0 - 32.0	pg
MEAN CORPUSCULAR HEMOGLOBIN CONCENTRATION	33.5	31.50 - 34.50	g/dL
RED CELL DISTRIBUTION WIDTH	12.7	11.60 - 14.0	%
MENTZER INDEX	18.6		
MEAN PLATELET VOLUME	9.2	6.80 - 10.90	fL

WBC DIFFERENTIAL COUNT

SEGMENTED NEUTROPHILS	50	40.0 - 80.0	%
LYMPHOCYTES	38	20.0 - 40.0	%
MONOCYTES	5	2.0 - 10.0	%
EOSINOPHILS	7 High	1.0 - 6.0	%
BASOPHILS	0	0.0 - 1.0	%
ABSOLUTE NEUTROPHIL COUNT	3.27	2.0 - 7.0	thou/ μ L



DR. VAISHALI RAJAN, MBBS DCP
(Pathology)
(Reg No - TCC 27150)
HOD - HAEMATOLOGY



DR. ASTHA YADAV, MD
Biochemistry
(Reg No - DMC/R/20690)
CONSULTANT BIOCHEMIST

Page 3 Of 12



View Details



View Report

PERFORMED AT :

DDRC AGILUS PATHLABS LIMITED
ASTER SQUARE BUILDING, ULLOOR,
MEDICAL COLLEGE P.O
TRIVANDRUM, 695011
KERALA, INDIA
Tel : 93334 93334, Fax : CIN - U85190MH2006PTC161480
Email : customercare.ddrc@agilus.in



Patient Ref. No. 66600006691235

PATIENT NAME : MRS LAKSHMI P V

REF. DOCTOR : SELF

CODE/NAME & ADDRESS : CA00010147 -

MEDIWHEEL ARCOFEMI HEALTHCARE LIMITED
F701A, LADO SARAI, NEW DELHI, SOUTH DELHI,
DELHI,
SOUTH DELHI 110030
8800465156

ACCESSION NO : 4182WK004026

PATIENT ID : MRSLF2909824182

CLIENT PATIENT ID:

ABHA NO :

AGE/SEX : 41 Years Female

DRAWN :

RECEIVED : 11/11/2023 08:03:09

REPORTED : 12/11/2023 08:24:13

Test Report Status	Preliminary	Results	Units	
ABSOLUTE LYMPHOCYTE COUNT		2.47	1.0 - 3.0	thou/ μ L
ABSOLUTE MONOCYTE COUNT		0.32	0.20 - 1.0	thou/ μ L
ABSOLUTE EOSINOPHIL COUNT		0.45	0.02 - 0.50	thou/ μ L
ABSOLUTE BASOPHIL COUNT		0.00 Low	0.02 - 0.10	thou/ μ L
NEUTROPHIL LYMPHOCYTE RATIO (NLR)		1.3		

ERYTHROCYTE SEDIMENTATION RATE (ESR), WHOLE BLOODSEDIMENTATION RATE (ESR) **27 High** 0 - 20 mm at 1 hr

SUGAR URINE - POST PRANDIAL RESULT PENDING

SUGAR URINE - FASTING

SUGAR URINE - FASTING NOT DETECTED NOT DETECTED

IMMUNOHAEMATOLOGY**MEDIWHEEL HEALTH CHECKUP ABOVE 40(F)2DECHO****ABO GROUP & RH TYPE, EDTA WHOLE BLOOD**

ABO GROUP TYPE AB

RH TYPE POSITIVE

BIO CHEMISTRY**MEDIWHEEL HEALTH CHECKUP ABOVE 40(F)2DECHO****BLOOD UREA NITROGEN (BUN), SERUM**

BLOOD UREA NITROGEN 7 Adult(<60 yrs) : 6 to 20 mg/dL

DR. ASTHA YADAV, MD
Biochemistry
(Reg No - DMC/R/20690)
CONSULTANT BIOCHEMISTDR. VAISHALI RAJAN, MBBS DCP
(Pathology)
(Reg No - TCC 27150)
HOD - HAEMATOLOGY

Page 4 Of 12



View Details



View Report

PERFORMED AT :DDRC AGILUS PATHLABS LIMITED
ASTER SQUARE BUILDING, ULLOOR,
MEDICAL COLLEGE P.O
TRIVANDRUM, 695011
KERALA, INDIA
Tel : 93334 93334, Fax : CIN - U85190MH2006PTC161480
Email : customercare.ddrc@agilus.in

Patient Ref. No. 66600006691235

PATIENT NAME : MRS LAKSHMI P V

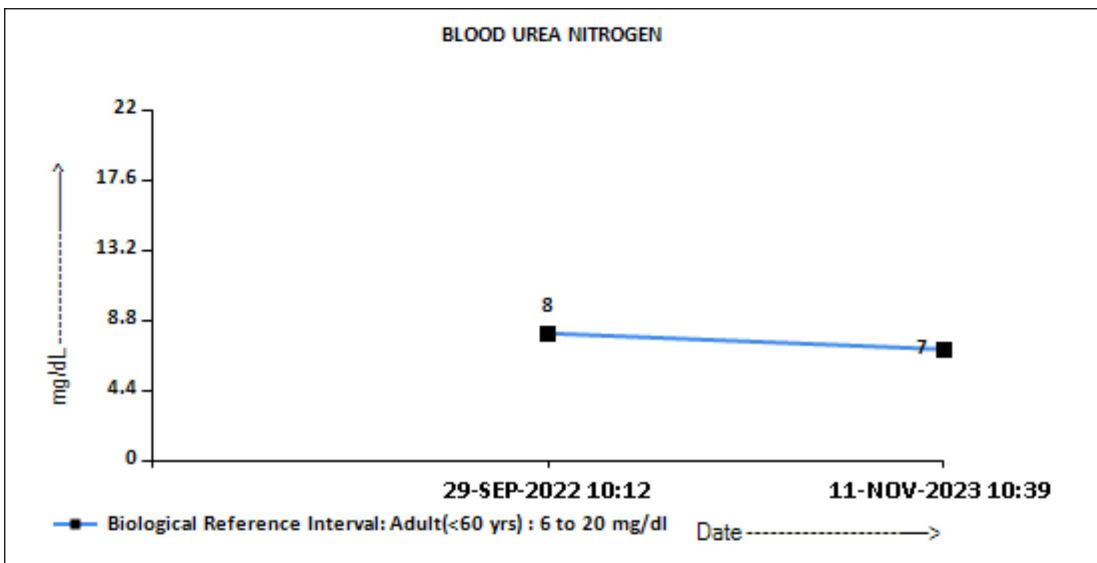
REF. DOCTOR : SELF

CODE/NAME & ADDRESS : CA00010147 -
MEDIWHEEL ARCOFEMI HEALTHCARE LIMITED
F701A, LADO SARAI, NEW DELHI,SOUTH DELHI,
DELHI,
SOUTH DELHI 110030
8800465156

ACCESSION NO : **4182WK004026**
PATIENT ID : MRSLF2909824182
CLIENT PATIENT ID:
ABHA NO :

AGE/SEX : 41 Years Female
DRAWN :
RECEIVED : 11/11/2023 08:03:09
REPORTED : 12/11/2023 08:24:13

Test Report Status	Preliminary	Results	Units
--------------------	-------------	---------	-------



BUN/CREAT RATIO

BUN/CREAT RATIO 9.7

CREATININE, SERUM

CREATININE 0.72 18 - 60 yrs : 0.6 - 1.1 mg/dL

DR. ASTHA YADAV, MD
Biochemistry
(Reg No - DMC/R/20690)
CONSULTANT BIOCHEMIST



View Details



View Report

PERFORMED AT :

DDRC AGILUS PATHLABS LIMITED
ASTER SQUARE BUILDING, ULLOOR,
MEDICAL COLLEGE P.O
TRIVANDRUM, 695011
KERALA, INDIA
Tel : 93334 93334, Fax : CIN - U85190MH2006PTC161480
Email : customercare.ddrc@agilus.in



Patient Ref. No. 66600006691235

PATIENT NAME : MRS LAKSHMI P V

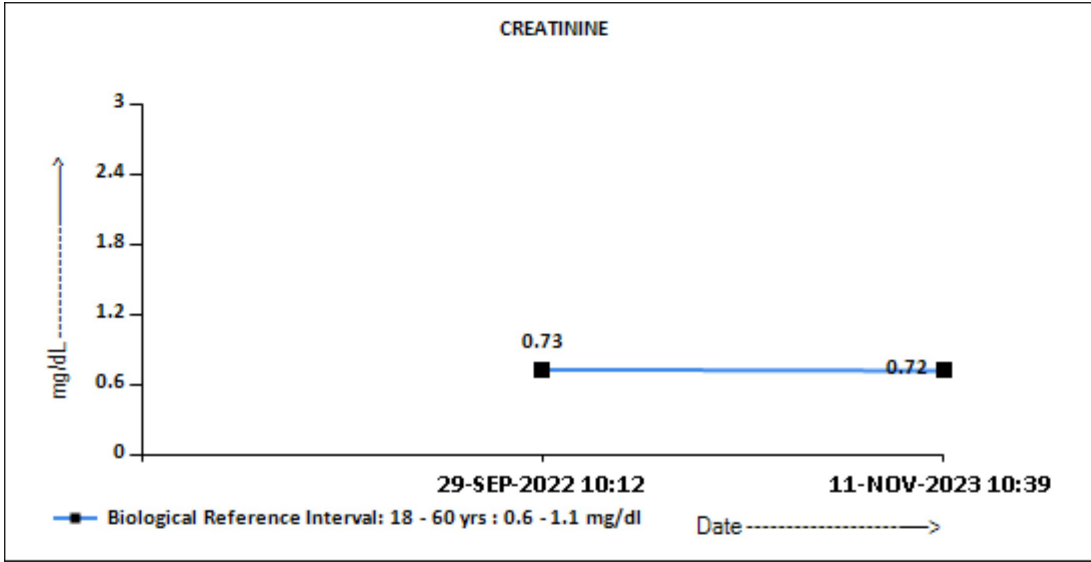
REF. DOCTOR : SELF

CODE/NAME & ADDRESS : CA00010147 -
 MEDIWHEEL ARCOFEMI HEALTHCARE LIMITED
 F701A, LADO SARAI, NEW DELHI,SOUTH DELHI,
 DELHI,
 SOUTH DELHI 110030
 8800465156

ACCESSION NO : **4182WK004026**
PATIENT ID : MRSLF2909824182
CLIENT PATIENT ID:
ABHA NO :

AGE/SEX : 41 Years Female
DRAWN :
RECEIVED : 11/11/2023 08:03:09
REPORTED : 12/11/2023 08:24:13

Test Report Status	Preliminary	Results	Units
--------------------	-------------	---------	-------



GLUCOSE, POST-PRANDIAL, PLASMA

GLUCOSE, POST-PRANDIAL, PLASMA	90	Diabetes Mellitus : > or = 200. mg/dL Impaired Glucose tolerance/ Prediabetes : 140 - 199. Hypoglycemia : < 55.
--------------------------------	----	--

DR. ASTHA YADAV, MD
Biochemistry
(Reg No - DMC/R/20690)
CONSULTANT BIOCHEMIST



View Details



View Report

PERFORMED AT :

DDRC AGILUS PATHLABS LIMITED
 ASTER SQUARE BUILDING, ULLOOR,
 MEDICAL COLLEGE P.O
 TRIVANDRUM, 695011
 KERALA, INDIA
 Tel : 93334 93334, Fax : CIN - U85190MH2006PTC161480
 Email : customercare.ddrc@agilus.in



Patient Ref. No. 66600006691235

PATIENT NAME : MRS LAKSHMI P V


REF. DOCTOR : SELF

CODE/NAME & ADDRESS : CA00010147 -
MEDIWHEEL ARCOFEMI HEALTHCARE LIMITED
F701A, LADO SARAI, NEW DELHI,SOUTH DELHI,
DELHI,
SOUTH DELHI 110030
8800465156

ACCESSION NO : 4182WK004026
PATIENT ID : MRSLF2909824182
CLIENT PATIENT ID:
ABHA NO :

AGE/SEX : 41 Years Female
DRAWN :
RECEIVED : 11/11/2023 08:03:09
REPORTED : 12/11/2023 08:24:13

Test Report Status	Preliminary	Results	Units
--------------------	-------------	---------	-------



GLUCOSE FASTING,FLUORIDE PLASMA

FBS (FASTING BLOOD SUGAR)	93	Diabetes Mellitus : > or = 126. mg/dL Impaired fasting Glucose/ Prediabetes : 101 - 125. Hypoglycemia : < 55.
---------------------------	----	--

DR. ASTHA YADAV, MD
Biochemistry
(Reg No - DMC/R/20690)
CONSULTANT BIOCHEMIST



View Details



View Report

PERFORMED AT :

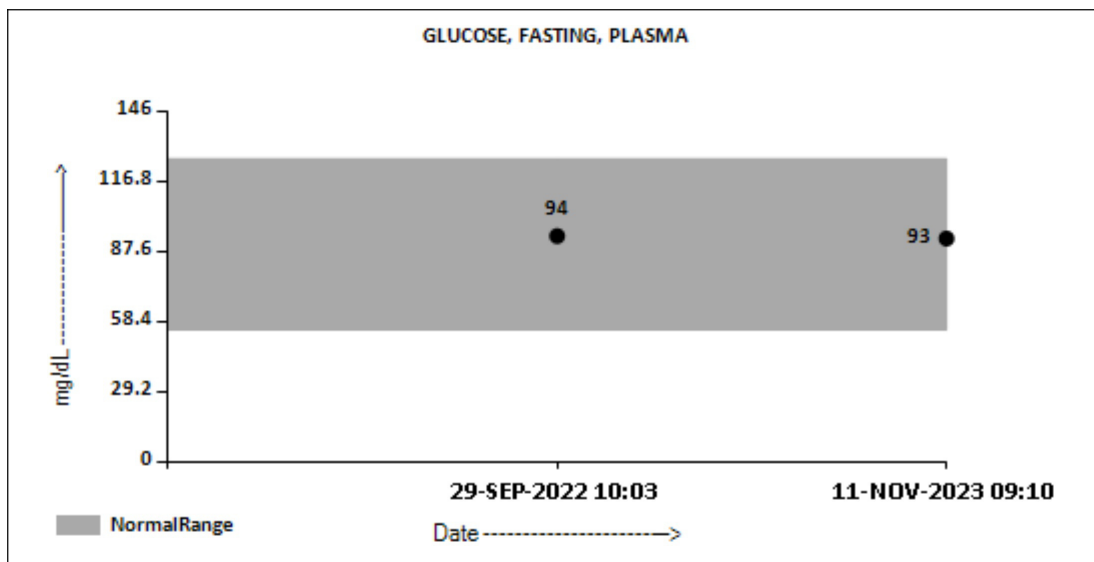
DDRC AGILUS PATHLABS LIMITED
ASTER SQUARE BUILDING, ULLOOR,
MEDICAL COLLEGE P.O
TRIVANDRUM, 695011
KERALA, INDIA
Tel : 93334 93334, Fax : CIN - U85190MH2006PTC161480
Email : customercare.ddrc@agilus.in



Patient Ref. No. 66600006691235

PATIENT NAME : MRS LAKSHMI P V	REF. DOCTOR : SELF
CODE/NAME & ADDRESS : CA00010147 - MEDIWHEEL ARCOFEMI HEALTHCARE LIMITED F701A, LADO SARAI, NEW DELHI,SOUTH DELHI, DELHI, SOUTH DELHI 110030 8800465156	ACCESSION NO : 4182WK004026 PATIENT ID : MRSLF2909824182 CLIENT PATIENT ID: ABHA NO :
	AGE/SEX : 41 Years Female DRAWN : RECEIVED : 11/11/2023 08:03:09 REPORTED : 12/11/2023 08:24:13

Test Report Status	Preliminary	Results	Units
--------------------	-------------	---------	-------



LIVER FUNCTION TEST WITH GGT

BILIRUBIN, TOTAL	0.56	General Range : < 1.1	mg/dL
BILIRUBIN, DIRECT	0.22	General Range : < 0.3	mg/dL
BILIRUBIN, INDIRECT	0.34	General Range : <0.85	mg/dL
TOTAL PROTEIN	7.5	Ambulatory : 6.4 - 8.3 Recumbant : 6 - 7.8	g/dL
ALBUMIN	3.9	20-60yrs : 3.5 - 5.2	g/dL
GLOBULIN	3.6	General Range : 2 - 3.5 Premature Neonates : 0.29 - 1.04	g/dL
ALBUMIN/GLOBULIN RATIO	1.1	General Range : 1.1 - 2.5	RATIO
ASPARTATE AMINOTRANSFERASE (AST/SGOT)	25	Adults : < 33	U/L
ALANINE AMINOTRANSFERASE (ALT/SGPT)	35	Adults : < 34	U/L
ALKALINE PHOSPHATASE	59	Adult (<60yrs) : 35 - 105	U/L
GAMMA GLUTAMYL TRANSFERASE (GGT)	37	Adult (female) : < 40	U/L

TOTAL PROTEIN, SERUM

Astha Yadav

DR. ASTHA YADAV, MD
Biochemistry
(Reg No - DMC/R/20690)
CONSULTANT BIOCHEMIST



View Details



View Report

PERFORMED AT :

DDRC AGILUS PATHLABS LIMITED
ASTER SQUARE BUILDING, ULLOOR,
MEDICAL COLLEGE P.O
TRIVANDRUM, 695011
KERALA, INDIA
Tel : 93334 93334, Fax : CIN - U85190MH2006PTC161480
Email : customercare.ddrc@agilus.in



Patient Ref. No. 66600006691235

PATIENT NAME : MRS LAKSHMI P V

REF. DOCTOR : SELF

CODE/NAME & ADDRESS : CA00010147 -
MEDIWHEEL ARCOFEMI HEALTHCARE LIMITED
F701A, LADO SARAI, NEW DELHI, SOUTH DELHI,
DELHI,
SOUTH DELHI 110030
8800465156

ACCESSION NO : 4182WK004026
PATIENT ID : MRSLF2909824182
CLIENT PATIENT ID:
ABHA NO :

AGE/SEX : 41 Years Female
DRAWN :
RECEIVED : 11/11/2023 08:03:09
REPORTED : 12/11/2023 08:24:13

Test Report Status	Preliminary	Results	Units
--------------------	-------------	---------	-------

TOTAL PROTEIN	7.5	Ambulatory : 6.4 - 8.3 Recumbant : 6 - 7.8	g/dL
---------------	-----	---	------

URIC ACID, SERUM

URIC ACID	5.3	Adults : 2.4-5.7	mg/dL
-----------	-----	------------------	-------

BIOCHEMISTRY - LIPID

MEDIWHEEL HEALTH CHECKUP ABOVE 40(F)2DECHO

LIPID PROFILE, SERUM

CHOLESTEROL	166	Desirable : < 200 Borderline : 200-239 High : >or= 240	mg/dL
TRIGLYCERIDES	138	Normal : < 150 High : 150-199 Hypertriglyceridemia : 200-499 Very High : > 499	mg/dL
HDL CHOLESTEROL	44	General range : 40-60	mg/dL
LDL CHOLESTEROL, DIRECT	105	Optimum : < 100 Above Optimum : 100-139 Borderline High : 130-159 High : 160-189 Very High : >or= 190	mg/dL
NON HDL CHOLESTEROL	122	Desirable : < 130 Above Desirable : 130 -159 Borderline High : 160 - 189 High : 190 - 219 Very high : > / = 220	mg/dL
VERY LOW DENSITY LIPOPROTEIN CHOL/HDL RATIO	27.6 3.8	</= 30.0 Low Risk : 3.3 - 4.4 Average Risk : 4.5 - 7.0 Moderate Risk : 7.1 - 11.0 High Risk : > 11.0	mg/dL
LDL/HDL RATIO	2.4	Desirable/Low Risk - 0.5-3 Borderline/Moderate Risk- 3.1-6	

DR. ASTHA YADAV, MD
Biochemistry
(Reg No - DMC/R/20690)
CONSULTANT BIOCHEMIST



View Details



View Report

PERFORMED AT :

DDRC AGILUS PATHLABS LIMITED
ASTER SQUARE BUILDING, ULLOOR,
MEDICAL COLLEGE P.O
TRIVANDRUM, 695011
KERALA, INDIA
Tel : 93334 93334, Fax : CIN - U85190MH2006PTC161480
Email : customercare.ddrc@agilus.in



Patient Ref. No. 66600006691235

PATIENT NAME : MRS LAKSHMI P V

REF. DOCTOR : SELF

CODE/NAME & ADDRESS : CA00010147 -
MEDIWHEEL ARCOFEMI HEALTHCARE LIMITED
F701A, LADO SARAI, NEW DELHI, SOUTH DELHI,
DELHI,
SOUTH DELHI 110030
8800465156

ACCESSION NO : **4182WK004026**
PATIENT ID : MRSLF2909824182
CLIENT PATIENT ID:
ABHA NO :

AGE/SEX : 41 Years Female
DRAWN :
RECEIVED : 11/11/2023 08:03:09
REPORTED : 12/11/2023 08:24:13

Test Report Status	Preliminary	Results	Units
--------------------	-------------	---------	-------

High Risk- >6.0

HISTOPATHOLOGY

MEDIWHEEL HEALTH CHECKUP ABOVE 40(F)2DECHO RESULT PENDING
CYTOLOGY - CS (PAP SMEAR) RESULT PENDING

SPECIALISED CHEMISTRY - HORMONE**MEDIWHEEL HEALTH CHECKUP ABOVE 40(F)2DECHO****THYROID PANEL, SERUM**

T3	112.00	Non-Pregnant : 80-200	ng/dL
		Pregnant Trimester-wise	
		1st : 81-190	
		2nd : 100-260	
		3rd : 100-260	
T4	11.10	Adults : 4.5-12.1	µg/dl
TSH 3RD GENERATION	6.150	Non-Pregnant : 0.4-4.2	µIU/mL
		Pregnant Trimester-wise :	
		1st : 0.1 - 2.5	
		2nd : 0.2 - 3	
		3rd : 0.3 - 3	

Comments

Kindly correlate clinically.
Kindly contact lab within 2 days, if clinically not correlated.

CLINICAL PATH - URINALYSIS**MEDIWHEEL HEALTH CHECKUP ABOVE 40(F)2DECHO**


DR. ASTHA YADAV, MD
Biochemistry
(Reg No - DMC/R/20690)
CONSULTANT BIOCHEMIST



DR. VAISHALI RAJAN, MBBS DCP
(Pathology)
(Reg No - TCC 27150)
HOD - HAEMATOLOGY

Page 10 Of 12



View Details



View Report

PERFORMED AT :

DDRC AGILUS PATHLABS LIMITED
ASTER SQUARE BUILDING, ULLOOR,
MEDICAL COLLEGE P.O
TRIVANDRUM, 695011
KERALA, INDIA
Tel : 93334 93334, Fax : CIN - U85190MH2006PTC161480
Email : customercare.ddrc@agilus.in



Patient Ref. No. 66600006691235

PATIENT NAME : MRS LAKSHMI P V

REF. DOCTOR : SELF

CODE/NAME & ADDRESS : CA00010147 -
 MEDIWHEEL ARCOFEMI HEALTHCARE LIMITED
 F701A, LADO SARAI, NEW DELHI,SOUTH DELHI,
 DELHI,
 SOUTH DELHI 110030
 8800465156

ACCESSION NO : **4182WK004026**
PATIENT ID : MRSLF2909824182
CLIENT PATIENT ID:
ABHA NO :

AGE/SEX : 41 Years Female
DRAWN :
RECEIVED : 11/11/2023 08:03:09
REPORTED : 12/11/2023 08:24:13

Test Report Status	<u>Preliminary</u>	Results	Units
--------------------	--------------------	---------	-------

PHYSICAL EXAMINATION, URINE

COLOR YELLOW
 APPEARANCE CLEAR

CHEMICAL EXAMINATION, URINE

PH	6.0	4.7 - 7.5
SPECIFIC GRAVITY	1.016	1.003 - 1.035
PROTEIN	NEGATIVE	NOT DETECTED
GLUCOSE	NEGATIVE	NOT DETECTED
KETONES	NEGATIVE	NOT DETECTED
BLOOD	NOT DETECTED	NOT DETECTED
BILIRUBIN	NEGATIVE	NOT DETECTED
UROBILINOGEN	NORMAL	NORMAL
NITRITE	NEGATIVE	NOT DETECTED

MICROSCOPIC EXAMINATION, URINE

RED BLOOD CELLS	NEGATIVE	NOT DETECTED	/HPF
WBC	8-10	0-5	/HPF
EPITHELIAL CELLS	10-15	0-5	/HPF
CASTS	NEGATIVE		
CRYSTALS	NEGATIVE		
REMARKS	NIL		

CLINICAL PATH - STOOL ANALYSIS

MEDIWHEEL HEALTH CHECKUP ABOVE 40(F)2DECH RESULT PENDING

PHYSICAL EXAMINATION,STOOL RESULT PENDING

CHEMICAL EXAMINATION,STOOL RESULT PENDING



View Details



View Report

PERFORMED AT :

DDRC AGILUS PATHLABS LIMITED
 ASTER SQUARE BUILDING, ULLOOR,
 MEDICAL COLLEGE P.O
 TRIVANDRUM, 695011
 KERALA, INDIA
 Tel : 93334 93334, Fax : CIN - U85190MH2006PTC161480
 Email : customercare.ddrc@agilus.in



Patient Ref. No. 66600006691235

PATIENT NAME : MRS LAKSHMI P V		REF. DOCTOR : SELF	
CODE/NAME & ADDRESS : CA00010147 - MEDIWHEEL ARCOFEMI HEALTHCARE LIMITED F701A, LADO SARAI, NEW DELHI,SOUTH DELHI, DELHI, SOUTH DELHI 110030 8800465156	ACCESSION NO : 4182WK004026	AGE/SEX : 41 Years Female	DRAWN :
	PATIENT ID : MRSLF2909824182	RECEIVED : 11/11/2023 08:03:09	REPORTED : 12/11/2023 08:24:13
	CLIENT PATIENT ID:		
	ABHA NO :		

Test Report Status	Preliminary	Results	Units
--------------------	-------------	---------	-------

MICROSCOPIC EXAMINATION,STOOL RESULT PENDING



View Details



View Report

NAME : MR LAKSHMI P V	AGE:41/F	DATE: 11/11/2023
------------------------------	-----------------	-------------------------

CHEST X-RAY REPORT

CHEST X-RAY PA VIEW : Trachea central
 No cardiomegaly
 Normal vascularity
 No parenchymal lesion.
 Costophrenic and cardiophrenic angles clear

➤ **IMPRESSION : Normal Chest Xray**

ELECTRO CARDIOGRAM : NSR: 69/minute
 No evidence of ischaemia.

➤ **IMPRESSION : Normal Ecg.**

Company name: BOB



[Signature]
DR SERIN LOPEZ. MBBS
 Reg No 77656 MEDICAL OFFICER
 DDRC AGILUS PATHLABS LTD.
 Aster Square, Medical College. P.O, TVM