


Diwakar Diagnostic Centre
E-7/636, Arera Colony, Bhopal

654 / MR. YASHPAL SINGH JHALA / 36 Yrs / M / 185 Cms / 94 Kg Date: 09-Jul-2022 Refd By : BOB

Report



Report :

TEST OBJECTIVE	: ROUTINE CHECK UP
RISK FACTOR	: HYPERTENSION
ACTIVITY	: MODERATE ACTIVE
OTHER INVESTIGATION	: ROUTINE BLOOD INVESTIGATION, ECHO, X RAY
REASON FOR TERMINATION	: TEST COMPLETE
EXERCISE TOLERANCE	: GOOD
EXERCISE INDUCED ARRHYTHMIAS	: NO
HAEMODYNAMIC RESPONSE	: NORMAL
CHRONOTROPIC RESPONSE	: NORMAL
FINAL IMPRESSION	: STRESS TEST IS NEGATIVE FOR EXERCISE INDUCED ISCHAEMIC HEART DISEASE



Doctor : Cardiologist



Stage	Time	Duration	Belt Speed (mph)	Elevation	METs	Rate	%THR Achieved	BP	RPP	PVC	Comments
Supine	00:11	0:01	00.0	00.0	01.0	55	30%	130/80	071	00	
Standing	00:15	0:01	00.0	00.0	01.0	55	30%	130/80	071	00	
HV	00:17	0:01	00.0	00.0	01.0	055	30%	130/80	071	00	
Warm Up	00:28	0:03	01.7	10.0	01.1	055	30%	130/80	071	00	
ExStart	00:31	0:06	01.7	10.0	01.1	055	30%	130/80	071	00	
BRUCE Stage 1	03:31	3:00	01.7	10.0	04.7	101	55%	136/80	137	00	
BRUCE Stage 2	06:31	3:00	02.5	12.0	07.1	124	67%	140/90	173	00	
BRUCE Stage 3	09:31	3:00	03.4	14.0	10.2	163	89%	146/90	237	00	
PeakEx	09:33	3:00	03.4	14.0	10.3	163	89%	146/90	237	00	
Recovery	10:32	1:00	00.0	00.0	04.3	132	72%	140/86	184	00	
Recovery	11:32	2:00	00.0	00.0	01.0	105	57%	136/80	142	00	
Recovery	11:41	2:08	00.0	00.0	01.0	104	57%	136/80	141	00	

Findings :

Exercise Time : 09:03
 Max HR Attained : 163 bpm 89% of Target 184
 Max BP Attained : (Sys) 146/90
 Max WorkLoad Attained : 10.3 Good response to induced stress
 Test End Reasons : Test Complete

Doctor : Cardiologist



654 / MR. YASHRAJ SINGH JHALA / 36 Yrs / M / 185 Cms / 94 Kg / HR : 55

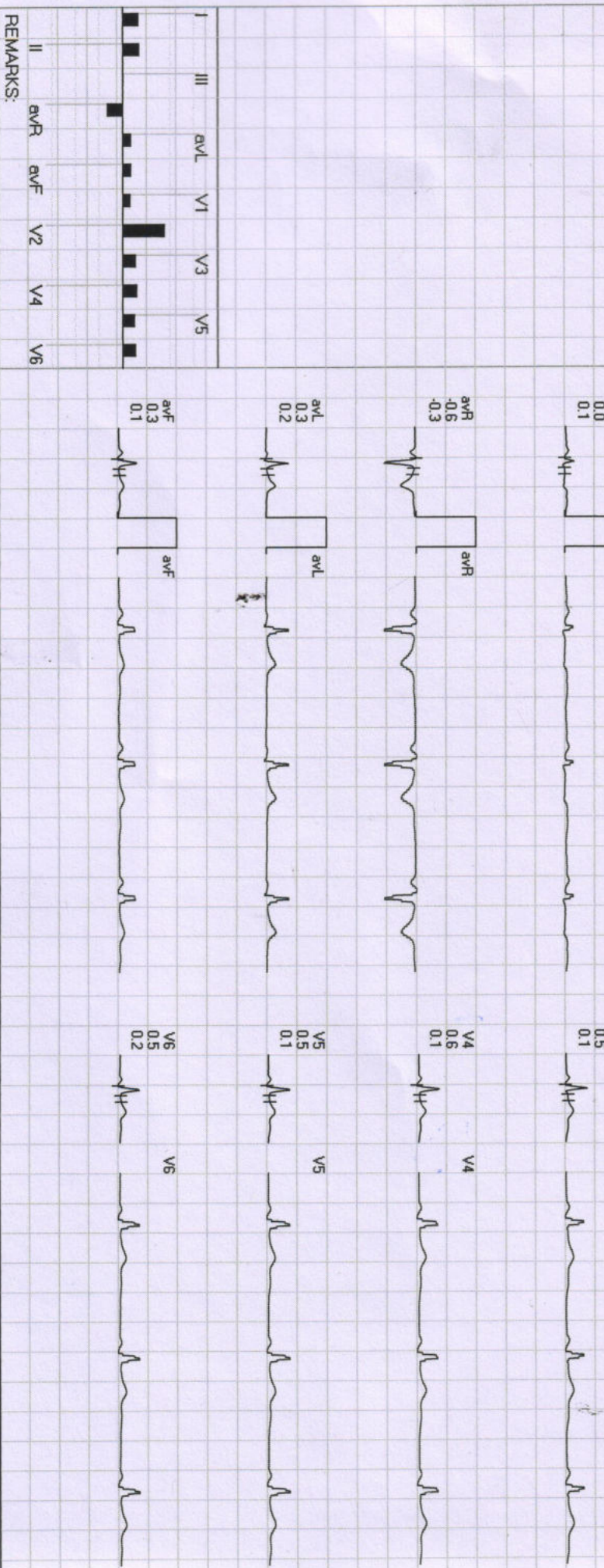
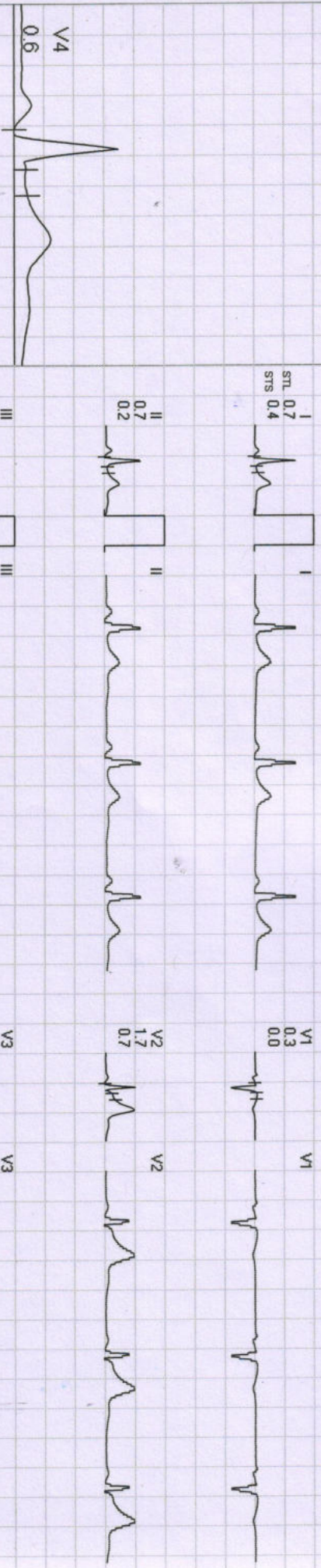
Date: 09-Jul-2022 10:06:02 AM

METS: 1.0/ 55 bpm 29% of THR BP: 130/80 mmHg Raw ECG/ BLC On/ Natch On/ HF 0.05 Hz/LF 20 Hz

EXTime: 00:10 0.0 mph 0.0%

4X 80 ms Post J

25 mm/Sec. 1.0 Cm/mV



REMARKS:



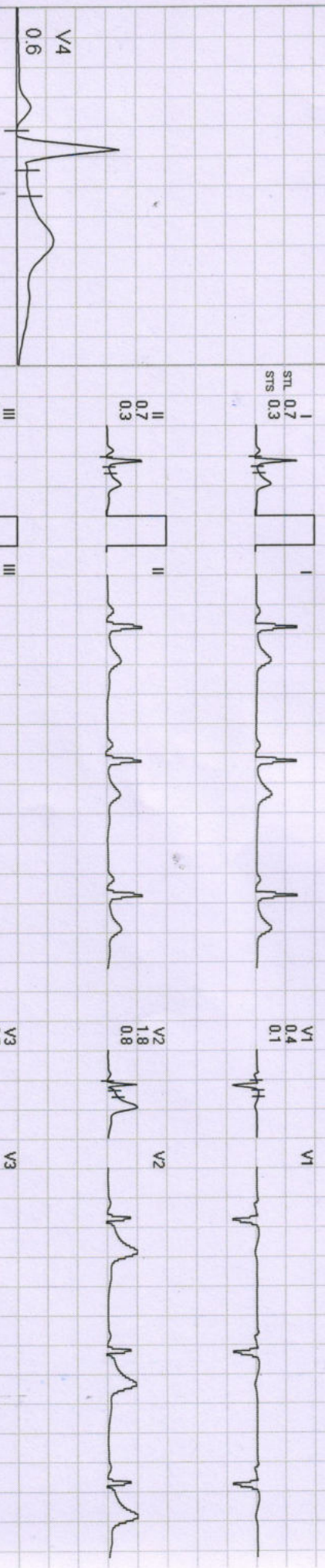
654 / MR. YASHPAL SINGH JHALA / 36 Yrs / M / 185 Cms / 94 Kg / HR : 55

Date: 09-Jul-2022 10:06:02 AM METS: 1.0/ 55 bpm 29% of THR BP: 130/80 mmHg Raw ECG/ BLC On/ Notch On/ HF 0.05 Hz/LF 20 Hz

EXTime: 00:14 0.0 mph, 0.0%

4X 80 mS Post J

25 mm/Sec 1.0 Cm/mV



REMARKS:

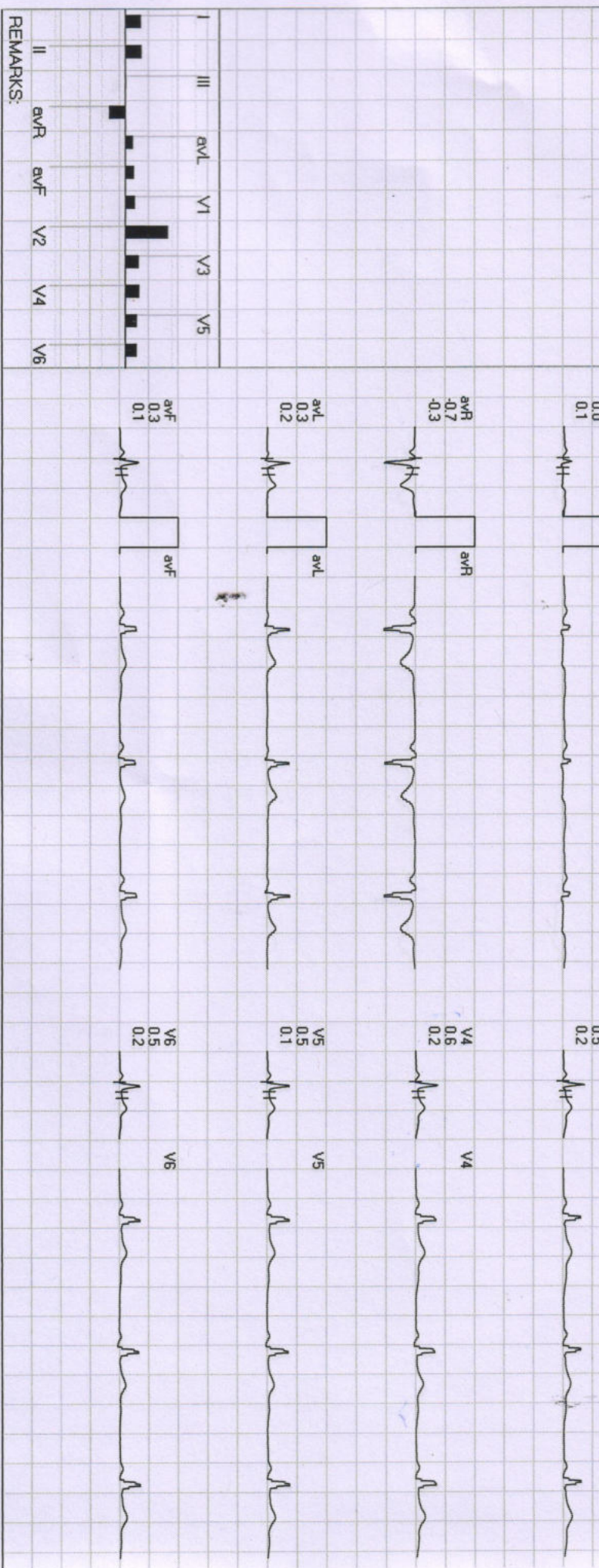
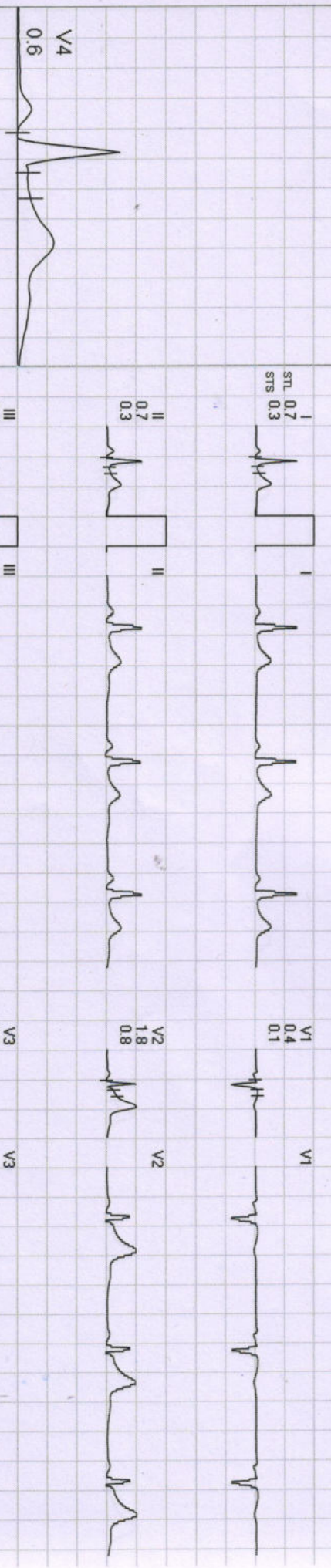
Date: 09-Jul-2022 10:06:02 AM

METS: 1.0/55 bpm 29% of THR BP: 130/80 mmHg Raw ECG/ BLC On/ Notch On/ HF 0.05 Hz/LF 20 Hz

ExTime: 00:16 0.0 mph, 0.0%

4X 80 mS Post J

25 mm/Sec. 1.0 Cm/mV



654 / MR. YASHPAL SINGH JHALA / 36 Yrs / M / 185 Cms / 94 Kg / HR : 55

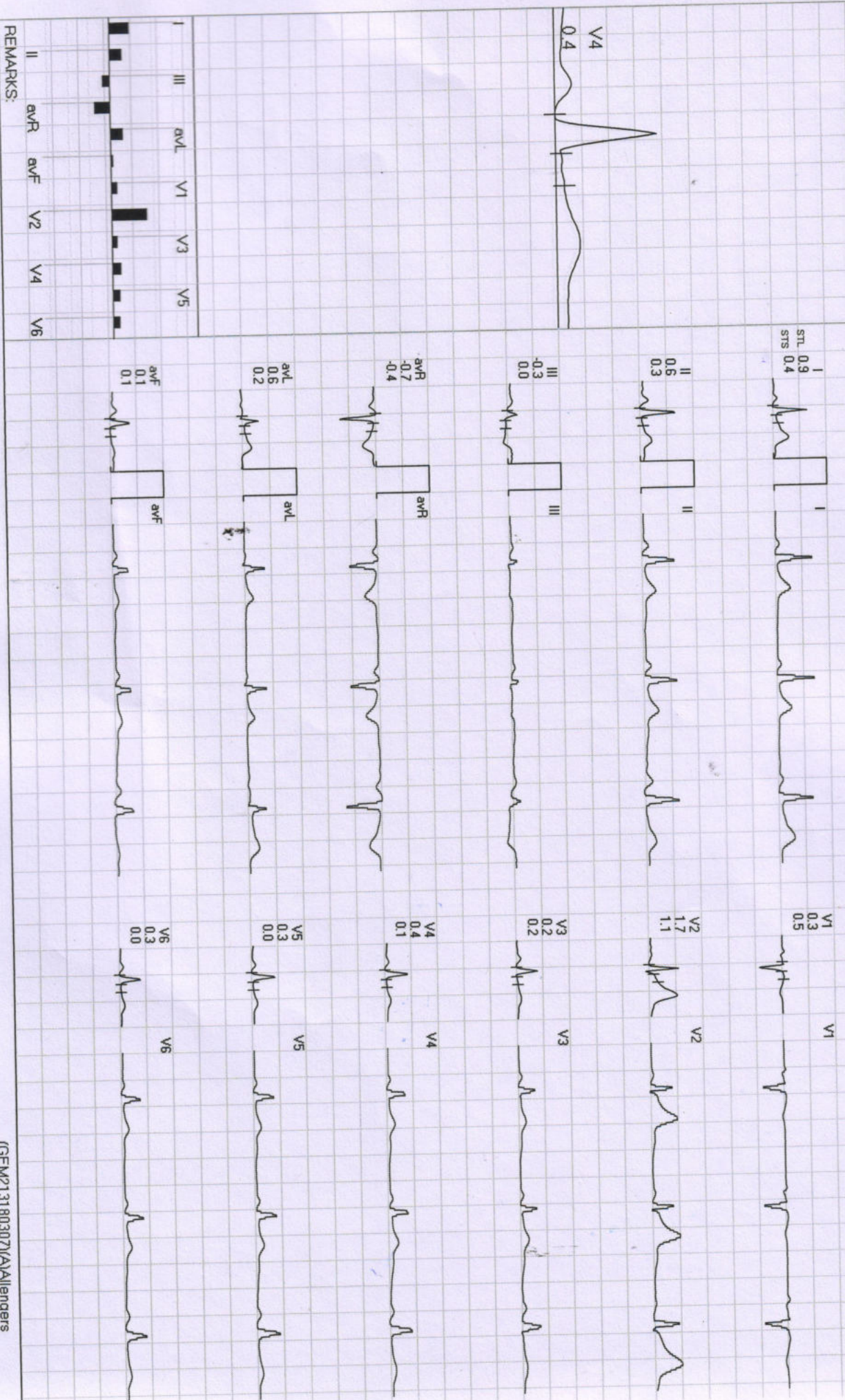
Date: 09-Jul-2022 10:06:02 AM

METS: 1.0/ 55 bpm 23% of THR BP: 130/80 mmHg Raw ECG/ BLC On/ Notch On/ HF 0.05 Hz/LF 20 Hz

EXTime: 00:27 1.0 mph, 0.0%

25 mm/Sec. 1.0 Cm/mV

4X 80 ms Post VJ



REMARKS:



654 / MR. YASHPAL SINGH JHALA / 36 YRS / M / 185 Cms / 94 Kg / HR : 65

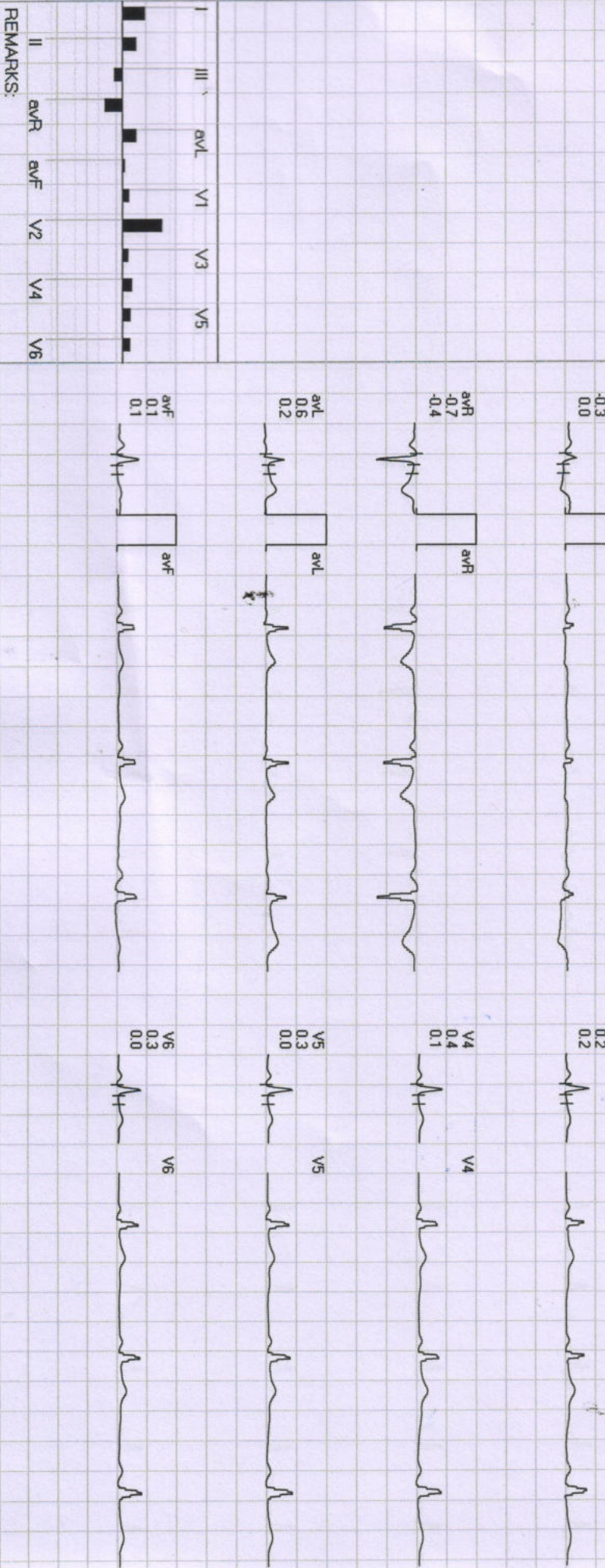
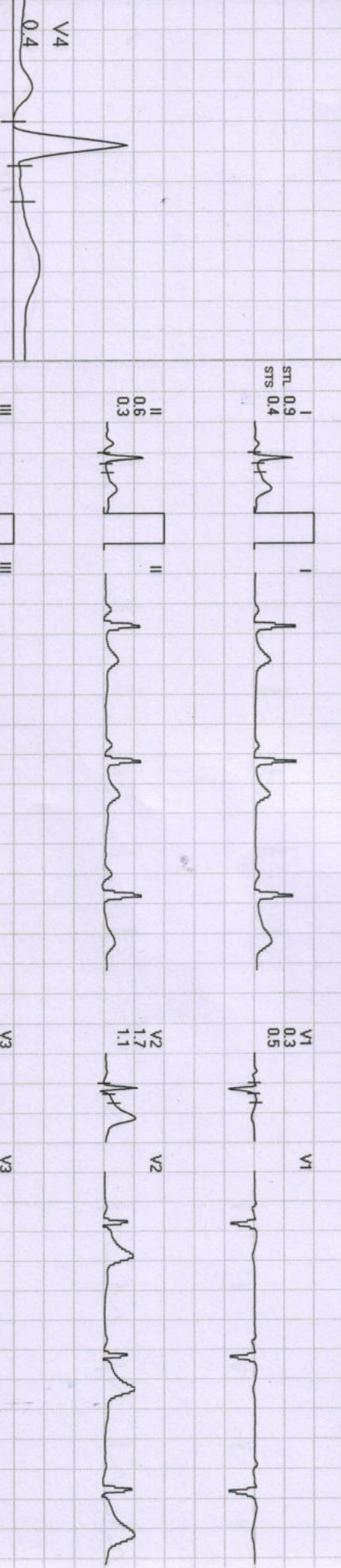
Date: 09-Jul-2022 10:06:02 AM

METS: 1.0/55 bpm 29% of THR BP: 130/80 mmHg Raw ECG/ BLC On/ Notch On/ HF 0.05 Hz/LF 20 Hz

EXTime: 00:00 0.0 mph, 0.0%

4X 90 MS Post J

25 mm/Sec. 1.0 Cm/mV





654 / MR. YASHPAL SINGH JHALA / 36 YRS / M / 185 Cms / 94 Kg / HR : 101

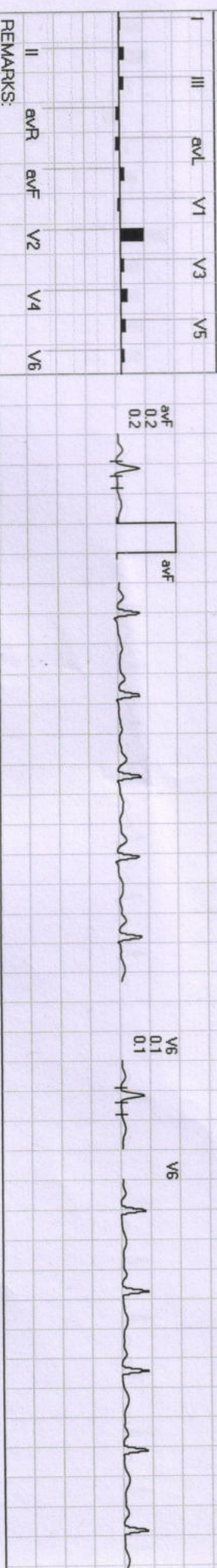
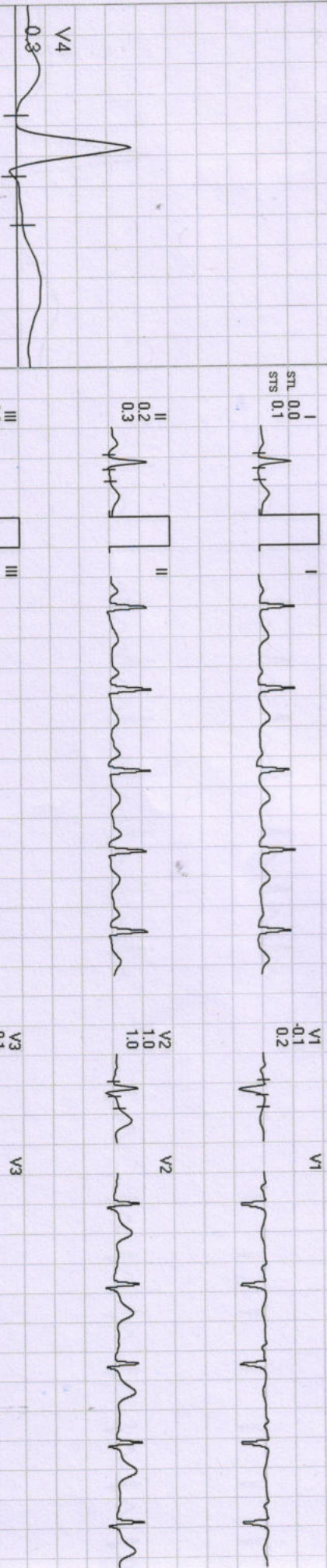
Date: 09-Jul-2022 10:06:02 AM

METS: 4.7 / 101 bpm 54% of THR BP: 136/80 mmHg Raw ECG/ BLC On/ Notch On/ HF 0.05 Hz/LF 20 Hz

EXTime: 03:00 1.7 mph, 10.0%

4X 80 ms Post J

25 mm/Sec. 1.0 Cm/mV



REMARKS:



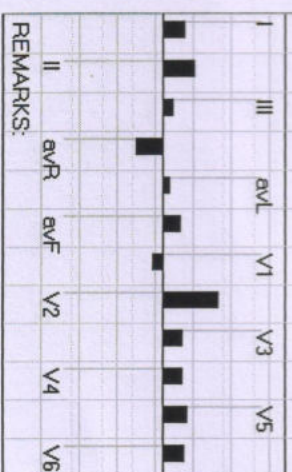




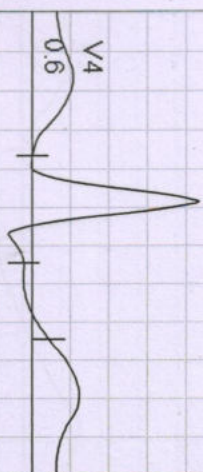
654 / MR. YASHPAL SINGH JHALA / 36 Yrs / M / 185 Cms / 94 Kg / HR : 124

Date: 09-Jul-2022 10:06:02 AM METS: 7.1 / 124 bpm 67% of THR BP: 140/90 mmHg Raw ECG/BLC On/ Natch On/ HF 0.05 Hz/LF 20 Hz

EXTime: 06:00 2.5 mph 12.0%

4X 80 ms Post J

25 mm/Sec 1.0 Cm/mV



REMARKS:

654 / MR. YASHPAL SINGH JHALA / 36 Yrs / M / 185 Cms / 94 Kg / HR : 163

Date: 09-Jul-2022 10:06:02 AM METS: 10.2 / 163 bpm 88% of THR BP: 146/90 mmHg Raw ECG/ BLC On/ Notch On/ HF 0.05 Hz/ LF 20 Hz

EXTime: 09:00 3.4 mph, 14.0%

4X 50 mS Post J

25 mm/Sec. 1.0 Cm/mV



REMARKS:





654 / MR. YASHPAL SINGH JHALA / 36 Yrs / M / 185 Cms / 94 Kg / HR : 163

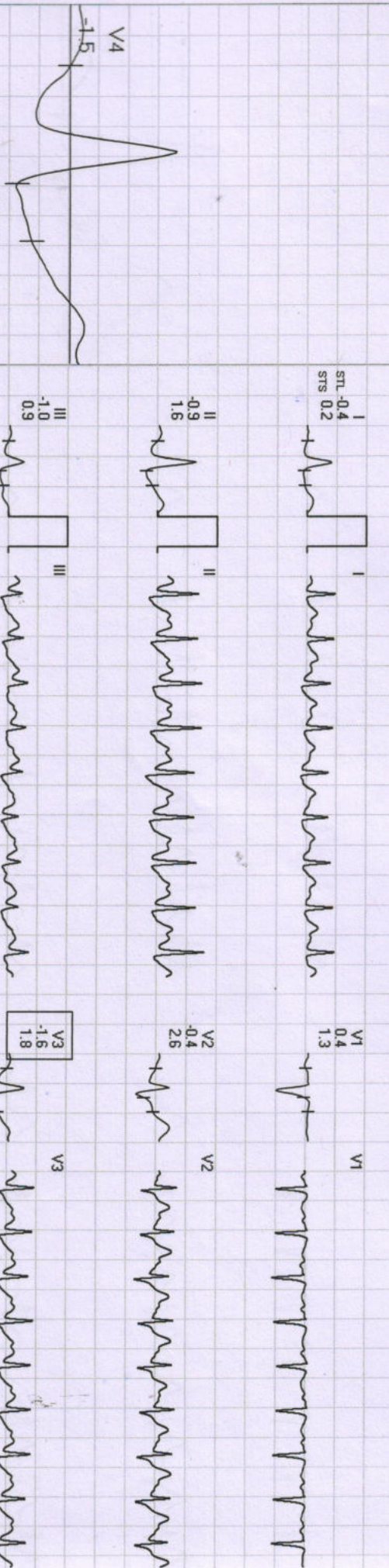Date: 09-Jul-2022 10:06:02 AM

METS: 10.3/163 bpm 88% of THR BP: 146/90 mmHg Raw ECG/BLC On/Notch On/HF 0.05 Hz/LF 20 Hz

EXTime: 09:02 4.2 mph, 16.0%

4X 80 ms Post J

25 mm/Sec. 1.0 Cm/mV



REMARKS:



654 / MR. YASHPAL SINGH JHALA / 36 Yrs / M / 185 Cms / 94 Kg / HR : 132

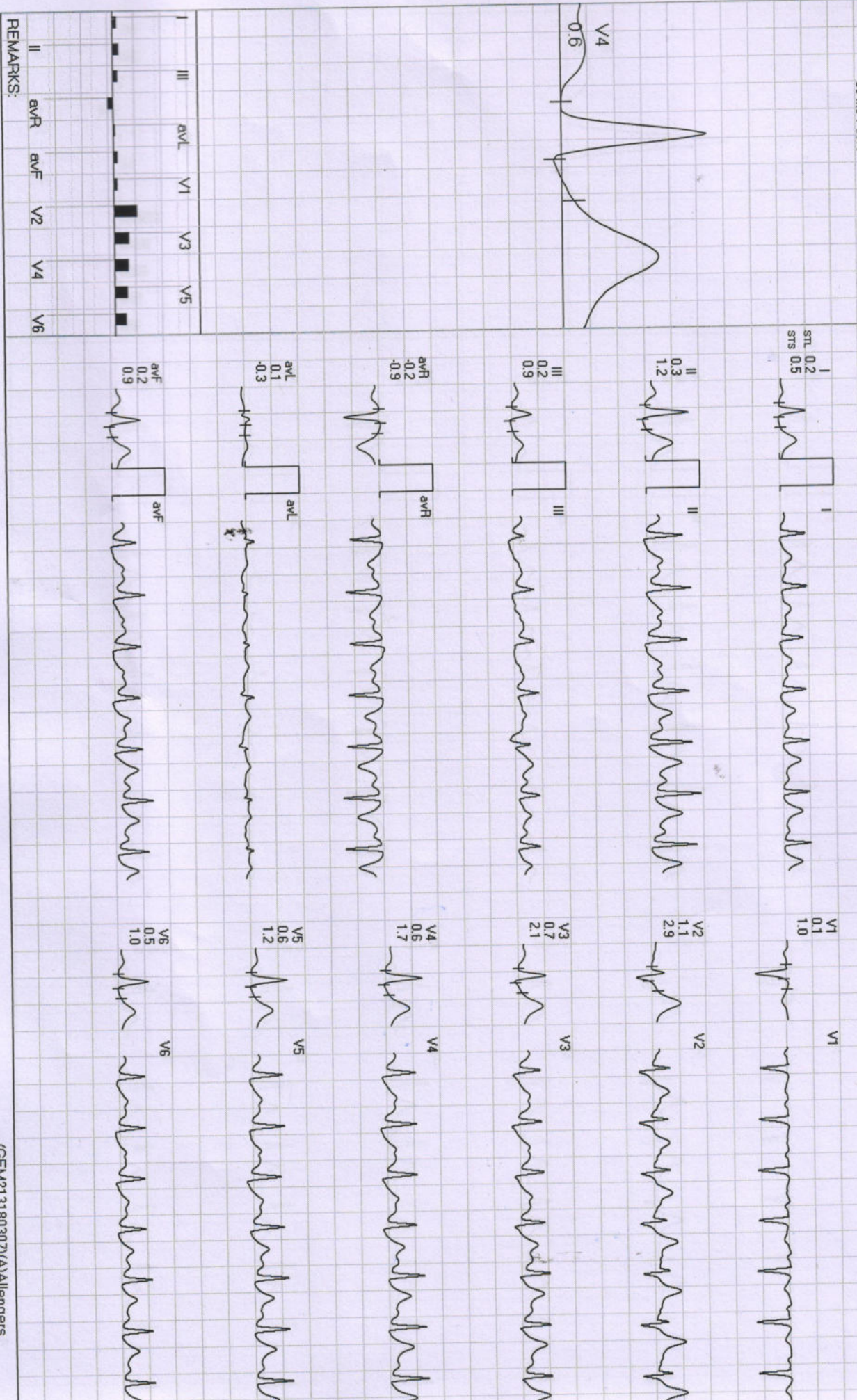
Date: 09-Jul-2022 10:06:02 AM

METS: 4.2 / 132 bpm 71% of THR BP: 140/86 mmHg Raw ECG/ BLC On/ Notch On/ HF 0.05 Hz/LF 20 Hz

ExTime: 09:02 0.0 mph 0.0%

25 mm/Sec. 1.0 Cm/mV

4X 50 ms Post J



REMARKS:



654 / MR. YASHPAL SINGH JHALA / 36 Yrs / M / 185 Cms / 94 Kg / HR : 105


Date: 09-Jul-2022 10:06:02 AM

METS: 1.0/105 bpm 57% of THR BP: 136/80 mmHg Raw ECG/BLC On/Notch On/ HF 0.05 Hz/LF 20 Hz

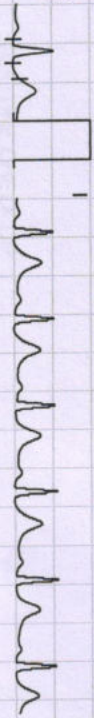EXTime: 09:02 0.0 mph, 0.0%

4X 80 ms Post J

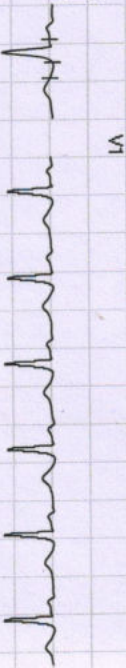25 mm/Sec. 1.0 Cm/mV




I
STL 0.8
STS 1.1



V1
0.0
0.0
-0.4




II
1.0
1.6



V2
2.0
2.1



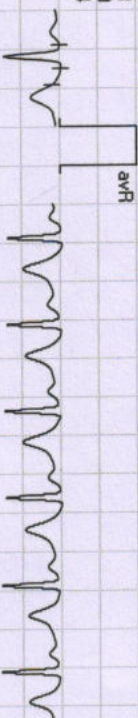
III
0.2
0.5



V3
1.4
1.8




aVR
-0.9
-1.4



V4
1.3
1.7



aVL
0.1
0.1



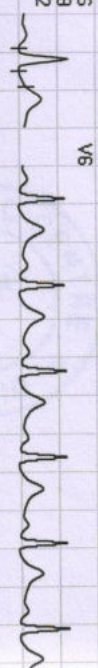V5
1.0
1.4



aVF
0.6
1.1



V6
0.9
1.2



I	III	aVL	V1	V3	V5
II	aVR	aVF	V2	V4	V6

REMARKS:



Divya Diagnostic Centre

डिवाय डायग्नोस्टिक सेंटर | ई.सी.जी. | एको कार्डियो ग्राफी | सोनोग्राफी



GPS Map Camera

Bhopal, Madhya Pradesh, India

636, Champion School Rd, E-7, Arera Colony, Bhopal, Madhya Pradesh 462016, India

Lat 23.205912°

Long 77.431602°

09/07/22 10:35 AM



दिवकर डायग्नोस्टिक सेंटर

E-7/636, पंजाब नेशनल बैंक के पास, मॉन रोड, अरेा कॉलोनी भोपाल (म.प्र.)


फोन: 0755-2465288, 0755-3520545 मो: 9826340190

Pt.Name :-	Mr. Yshpal Singh Jhala
Age :-	34y/M
Refd. By :-	BOB
Lab.pNo.:-	302
Date :-	16/07/2022

EXAMINATION OF BLOOD

TEST	RESULT	NORMAL VALUE
Haemoglobin	15.2mgs%	Female 12-16gms%, Male 14-18gms%
Red Cell count	5.0	4.5-5.6 million /cumm
Platelite Count	2.87	1.5-5.6 Lac/cumm
Leucocytes per.cu.mm	7600/cumm	5000-11000/cumm
Neutrophils	59%	50-70%
Lymphocytes	31%	20-40%
Eosinophils	06%	0-7%
Monocytes	04%	2-8%
PCV	41.6	37-47
MCV	80.0	76-96
MCH	31.6	27-32
MCHC	33.4	31-35
ESR	05	Male 0-9, Female 0-20mm/FHR
Blood Group	"O"Positive	By Slide Method
S.Bilirubin(Total)	0.88	0.2-1.0mg/dl
Direct	0.35	0.0-0.25mg/dl
Indirect	0.53	
SGOT	32.6	5-35U/L
SGPT	35.0	8-40U/L
Alk Phosphatase	10.3	3-13 KA units
S. Protein(Total)	7.2	6.0-8.0mg%
Albumin	4.0	3.7-5.3mg%
Globulin	3.0	1.5 to 3.5 mg%
AG Ratio	1.25	1.-2.0
Blood Urea Nitrogen (BUN)	16.2	7-20 mg/dl
S.Creatine	0.96	0.5-1.4mg/dl
Uric Acid	6.3	4.8 to 7.5 mg/dl
Calcium	9.4	8.5-10.5 gm/dl
GGTP	33.8	5-35 UL/dl
Fasting Blood Sugar	91.6	70 to 110mg/dl
Total Serum Cholesterol	184.3	100-250 mg%
Serum Triglyceride	172.9	Up to 160 mg%
Serum Cholesterol HDL	48.0	Up to 65 mg%
Serum Cholesterol LDL	101.7	Up to 125 mg%
VLDL	34.5	Up to 30 mg%
TC/HDL Ratio	3.38	Bellow 5
Glycosylated Hemoglobin HBA1c	5.5	Below - 6.0 % -Non Diabetic control 6-7 % -Excellent control Above- 8 % -Poor control

All test have technical limitation. Collaborative clinic pathological interpretation is mandatory. In case of disparity test may be repeated immediately. Typographical mistakes should be get correct instantly. This report is not valid for medico legal purpose



Dr. B. M. Agarwal
MBBS, DCP
Consultant Pathologist



दिवाकर डायग्नोस्टिक सेंटर

E-7/636, पंजाब नेशनल बैंक के पास, मैन रोड, अरेरा कॉलोनी भोपाल (म.प्र.)
फोन: 0755-2465288, 0755-3520545 मो: 9826340190

Pt.Name :-	Mr. Yshpal Singh Jhala
Age :-	34y/M
Refd. By :-	BOB
Lab.pNo.:-	302
Date :-	16/07/2022

EXAMINATION OF BLOOD

<u>TEST</u>	<u>RESULT</u>	<u>NORMAL VALUE</u>
PSA	4.85 ng/ml.	0.21-6.77 ng/ml.



B. M. Agarwal
B. M. Agarwal
MBBS, DCP
Consultant Pathologist

All test have technical limitation. Collaborative clinic pathological interpretation is mandatory. In case of disparity test may be repeated immediately. Typographical mistakes should be get correct instantly. This report is not valid for medico legal purpose



द्विवाकर डायग्नोस्टिक सेंटर

E-7/636, पंजाब नेशनल बैंक के पास, मैन रोड, अरेरा कॉलोनी भोपाल (म.प्र.)
फोन: 0755-2465288, 0755-3520545 मो: 9826340190

Pt.Name :-	Mr. Yshpal Singh Jhala
Age :-	34y/M
Refd. By :-	BOB
Lab.pNo.:-	302
Date :-	16/07/2022
Skigram	X Ray Chest PA View
Radiologist	Dr. B.M.Agarwal MD (Radiology)

REPORT

Tricia Central

Thoracic cage normal

Both Lungs Field Clear.

Both hilers normal

Cardiac border normal


Both cp angles clear

Both domes and diaphragm normal

IMPRESSION

-NO CARDIO PULMONARY PATHOLOGY
-COORELATE WITH CLINICAL FINDINGS.




Dr. B. M. Agarwal
MD, Radiology
Consultant Radiologist
Radiologist



दिवकर डायग्नोस्टिक सेंटर

E-7/636, पंजाब नेशनल बैंक के पास, मैन रोड, अरेरा कॉलोनी भोपाल (म.प्र.)
फोन: 0755-2465288, 0755-3520545 मो: 9826340190

Pt.Name :-	Mr. Yshpal Singh Jhala
Age :-	34y/M
Refd. By :-	BOB
Lab.pNo.:-	302
Date :-	16/07/2022

EXAMINATION OF BLOOD

Thyroid profile

<u>TEST</u>	<u>RESULT</u>	<u>NORMAL VALUE</u>
T3 - TOTAL	92.5	82-213 ng/dL
T4 - TOTAL	6.94	6.09-12.23 ug/dL
THYROID STIMULATING HARMONE (TSH)	1.38	0.45-4.25 ul/mL

Interpretation:

TSH Levels will be elevated in primary hypothyroidism, TSH levels will be low in Hyperthyroidism there is decreased production of thyroid hormones by the thyroid hence the person may experience symptoms such as weight gain, constipation, cold intolerance and fatigue. Iodine deficiency and Hashimoto thyroiditis is the most common cause of hypothyroidism It makes Thyroid stimulating hormone. If TSH levels are abnormally high it could mean you have an underactive thyroid or hypothyroidism.



Dr. B. M. Agarwal
MBBS, DCP
Consultant Pathologist

All test have technical limitation. Collaborative clinic pathological interpretation is mandatory. In case of disparity test may be repeated immediately. Typographic mistakes should be get correct instantly. This report is not valid for medico legal purpose



दिवाकर डायग्नोस्टिक सेंटर

E-7/636, पंजाब नेशनल बैंक के पास, मैन रोड, अरेरा कॉलोनी भोपाल (म.प्र.)

फोन: 0755-2465288, 0755-3520545 मो: 9826340190

Pt.Name :-	Mr. Yshpal Singh Jhala
Age :-	34y/M
Refd. By :-	BOB
Lab.pNo.:-	302
Date :-	16/07/2022

URINE ANALYSIS

<u>A. PHYSICALEXAMINATION</u>		<u>C. MICROSCOPIEXAMINATION</u>	
1. Colour	Yellow	Pus Cells	2-4/HPF
2. Appearance	Clear	R.B.C.	Nil
3. Specific Gravity	Q.N.S.	Epithelial Cell	occ/HPF
<u>B. CHEMICAL EXAMINATION</u>		Cast	Nil
1.Reaction	Acidic	Crystals(Cal.Oxa)	Nil
2.Albumin	Absent	Bacteria	Nil
3.Sugar	Nil	Amorphous	Nil
4.Bile Salts	Absent	T. Vaginitis	Nil

URINE COTININE	Negative	By Card method
----------------	----------	----------------


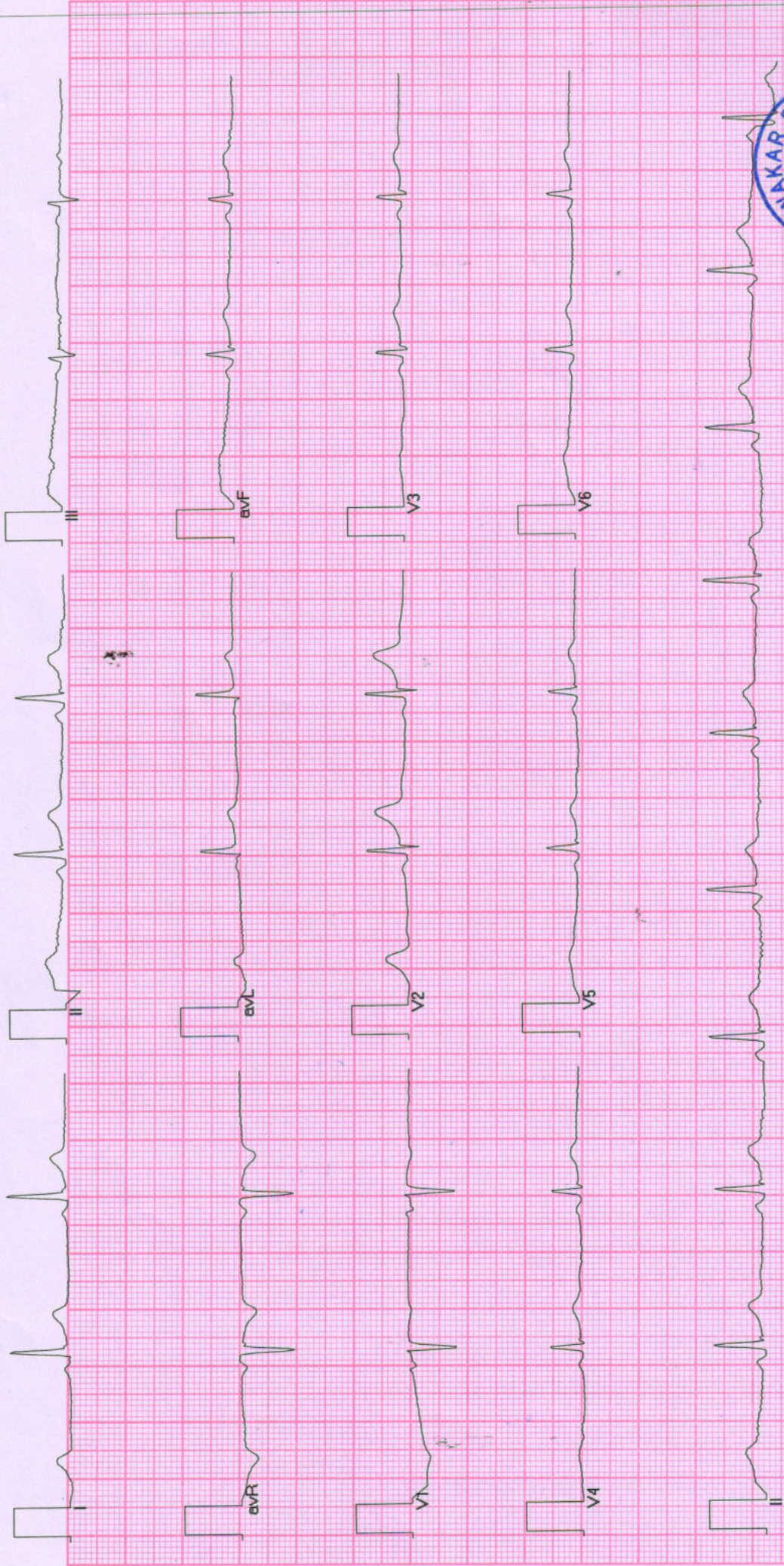


Dr. B. M. Agarwal
MBBS, DCP
Consultant Pathologist
Pathologist



ECG

Allengers Global Healthcare Pvt Ltd.,
 136 / MR, yashpal singh jhala / 34 Yrs / M / 185Cms. / 94Kgs.
 Heart Rate : 56 bpm / Tested On : 09-Jul-22 10:05:09 / HF 0.05 Hz - LF 100 Hz / Notch 50 Hz / Sn 1.00 Cm/mV / Sw 25 mm/s
 / Refd By: BOB



Handwritten signature

BPL-DYNATRAC

Allengers ECG (Pisces)(PIS218180317)



डॉ. सविता क्लिनिक

34, भूतल, मोहिनी अदिति आर्केड, शाहपुरा मस्जिद के पास
भरत नगर रोड, ई-7/194, अरेरा कॉलोनी, भोपाल - 462038

Mob. : 8989649694, 9516333619

Clinic Registration : CL/5392/Jun/2017

PNDT Registration : MPPCPNDT/BPL/2017/206



Name : Mrs. Yadav. 34/male. Age.....YRS./F
R/BNo.Date. 9/7/2022.

WHOLE ABDOMES ULTRASOUND REPORT

Indication: Health Check-up.

Liver appears normal in size and shape with normal outline. ~~Normal/~~
increased perenchymal echogenicity is noted. No E/O focal lesion/ IHBR
dilatation is seen. Hepatic veins and portal veins appear normal. gs I
fatty liver.

No E/O subdiaphragmatic Collection.

Gall Blader is physiologically well distended. No. E/O echogenic foci in GB
lumen. GB wall is normal / ~~thickened.~~ No E/O pericholecystic collection.
Common duct reveals normal course and caliber.

Pancreas appear normal in size, shape and echo texture with smooth
contour. No peripancreatic pathology seen. (~~Not seen due to gases~~)

Spleen is normal in size and echo texture.

IVC and aorta appear to be normal.

No evidence of lymphadenopathy is noted.

No evidence of free fluid is noted.

Right Kidney is normal in size. size, shape and position. Corticomedullary
defferentiation (CMD) is well maintained. Normal cortical thickness is
noted. No E/O hydronephrosis or calculus is noted.

PTO

Left Kidney is normal in size, shape and position. CMD is well maintained. Normal cortical thickness is noted. No E/O hydronephrosis or calculus is noted.

Urinary Bladder is well distended (physiological). its contents are echo free. No E/O bladder wall thickening is noted. Post-void residue is insignificant.

Prostate is normal in size. Shape and echo texture with smooth outline. No E/O focal lesion is noted.


Uterus is ante/ retro verted and normal in size, shape and echotexture with smooth outline. No E/O focal lesion is noted. Endometrial echo appear normal. Cervical and vaginal shadows appear normal.

Right Ovary appears enlarged / Normal in size, shape and echo texture.

Left Ovary appears enlarged / Normal in size, shape and echo texture.

Impression : ~~Normal study.~~ Grade I Fatty Liver.

Advised clinical Correlation.



Dr. P. Savita, MD
MBBS, MD (O&G) Reg. No. 9971
स्त्री रोग विशेषज्ञ

Dr. Jayant Yadav, MD
MBBS, MD (Radiologist) Reg. No. 4166
रेडियोलॉजिस्ट

INDIAN UNION DRIVING LICENCE


MADHYA PRADESH STATE


Number: MPDLH/2012/0586391
 Name: KASHPAL SINGH
 JHALA
 S/O/W of: SH. MAHESHVAR SINGH
 Address: 31 NO. 1 SULTANIYA ZANANA
 HOSPITAL CAMPUS CITS
 BHOPAL, MP

Issued on: 21-08-2012
 DOB: 04-01-1988 - BG-O+ve
 is Licence to drive

Vehicle Class: LMV/BT
 Date of Issue: 21-08-2012

Valid till (Temporary):
 Valid till (Non-Temporary): 20-08-2022

Holder Signature: 

Supervisor for Authentication: 

Auth. by: SATISH PATHAK

Jr. B. M. Agarwal
 MBBS, DCP
 Consultant Pathologist



(Handwritten signature)

