

HISTOPATHOLOGY

--

Name : Mrs. KALPANA MANOHAR PATIL Age : 48Yr Gender : Female
UHID : MHN1.0000123609 / NSKAH27152 W/BNo/RefNo : AHC
Lab No : AHN1.C2200412 LRN : 647892
Ref Doctor : DR. Rajashri Dhongade



Collected on : 29-JUL-2022 02:43:11 PM Received on : 29-JUL-2022 02:43:51 PM Reported on : 30-JUL-2022 11:39:23 AM

MediWheel Full Body Health Checkup Female Below 40 Package

CERVICAL/VAGINAL SMEAR II SLIDE

Brief Clinical History:

Hysterectomy done

SOURCE OF SPECIMEN :

Vaginal Smear-Conventional

I. Specimen Adequacy

Satisfactory for evaluation

Limited by low cellularity

II. General Categorization :

Negative for intraepithelial lesion or malignancy

Other non neoplastic findings:

Smears limited by low cellularity and show Intermediate and para basal squamous cells. Neutrophilic infiltrate is seen. There is no evidence of dysplasia or malignancy. There is no evidence of candida or trichomonas.

Negative for intraepithelial lesion or malignancy . Suggests Atrophic smear with benign cellular changes of inflammation

Adv.: Follow up

Epithelial abnormalities:

HISTOPATHOLOGY

--

Name : Mrs. KALPANA MANOHAR PATIL Age : 48Yr Gender : Female
UHID : MHN1.0000123609 / NSKAH27152 W/BNo/RefNo : AHC
Lab No : AHN1.C2200412 LRN : 647892
Ref Doctor : DR. Rajashri Dhongade



Collected on : 29-JUL-2022 02:43:11 PM Received on : 29-JUL-2022 02:43:51 PM Reported on : 30-JUL-2022 11:39:23 AM

Absent

' Smear limited by low cellularity but negative for intraepithelial lesion or malignancy . Suggests
Atrophic smear with benign cellular changes of inflammation
Adv.: Follow up

* END OF REPORT *

Reported By:

Dr.KISHOR KHODKE

Typed By: 721947

Printed On : 01-AUG-2022 01:33:51 PM

ID: 000123609

Visit:

48years

Asian

Female

Total Exercise time: 7:09

Max HR: 157bpm 92% of max predicted 170bpm

Max BP: 130/80

Maximum workload: 8.7METS

29-Jul-2022
14:13:41


Reason for Termination: Max HR attained

25.0 mm/s
10.0 mm/mV
100hz

Referred by:
Test ind:

Phase Name	Stage Name	Time in Stage	Speed (mph)	Grade (%)	WorkLoad (METS)	HR (bpm)	BP (mmHg)	RPP (x100)
PRETEST	SUPINE	0:37	***	***	1.0	73	110/70	80
	STANDING	0:10	***	***	1.0	73	110/70	80
	HYPERVENT	0:30	0.8	0.0	1.1	73	110/70	80
EXERCISE	STAGE 1	3:00	1.7	10.0	4.6	111		
	STAGE 2	3:00	2.5	12.0	7.0	139	130/80	181
	STAGE 3	1:09	3.4	14.0	8.7	150	130/80	195
RECOVERY	Post	4:31	***	***	1.0	94	130/80	122

TMT Negative for STP





Name : Mrs. KALPANA MANOHAR PATIL (48/F)

Address : NASHIK, NASHIK, NASHIK, MAHARASHTRA, INDIA

Date

29/07/2022

Examined by:

UHID : MHN1.0000123609

Package : MediWheel Full Body Health Checkup Female Below 40
Package

AHC No : NSKAH27152



CHIEF COMPLAINTS

For corporate health checkup
giddiness, chest pain-1 months



DRUG ALLERGY

NO KNOWN ALLERGY

:29/07/2022



SYSTEMIC REVIEW

Cardiovascular system

- Nil Significant



Past medical history

Do you have any allergies? - No

Do you have any drug allergies? - No

Past medical history - nil significant

Covid 19 - No



Surgical history

Hysterectomy - done-20 yrs back



Personal history

Marital status - Married

No. of children - 03

Diet - Mixed Diet

Alcohol - does not consume alcohol

Smoking - No

Chews tobacco - No

Chews paan - No

Uses snuff - No

Illicit substance use - No

Physical activity - Active



Family history

Father - has expired

Aged - 96 yrs

Mother - has expired

Aged - 75 yrs

Brothers - 4

Family history - Nil significant

Coronary artery disease - none

Cancer - None

PHYSICAL EXAMINATION



General

General appearance - normal

Build - normal

Height - 155 Cm

Weight - 69.3 Kg

BMI - 28.84

Pallor - No

Oedema - no

Temperature - 96

SpO2 - 98



Cardiovascular system

Heart rate (Per minute) - 75

Rhythm - Regular

- B.P. Supine

Systolic(mm of Hg) - 120

Diastolic(mm of Hg) - 80

Heart sounds - S1S2+

H Swaminarayan Nagar, Off Mumbai-Agra Highway,
Panchvati, Nashik - 422 003.

+91- 253 - 2510250 / 350 / 450 / 550 / 750

apollonashik@apollohospitals.com
UJID : MHN1.0000123609
www.askapollo.com

QFAHN/BILL/003/V1



Name : Mrs. KALPANA MANOHAR PATIL (48
/F)

Date

29/07/2022

Package : MediWheel Full Body Health Checkup Female Below 40 Package

AHC No : NSKAH27152

Respiratory system

Breath sounds - Normal vesicular breath sounds

Abdomen

Organomegaly - No

Tenderness - No



Printed By : Shweta Sharad Shardul



Name : Mrs. KALPANA MANOHAR PATIL (48 /F)

UHID : MHN1.0000123609

Date

29/07/2022

Package : MediWheel Full Body Health Checkup Female Below 40 Package

AHC No : NSKAH27152

URINE ROUTINE (CUE)

Test Name	Result	Unit	Level	Range
Specific Gravity	1.010 *		●	1.016-1.026
Color,:	Pale Yellow			
Transparency:	Clear			
Reaction:	Acidic			7.2-7.8
Protein :	Nil			
Sugar:	Nil			
pH	5.0		●	4.6-8
Blood:	Negative			
● one	Negative			
Bile Pigments:	Negative			
Bile Salts :	Negative			
Urobilinogen	Normal			
Nitrite	Negative			
RBC	0	/hpf	●	0-2
WBC/Pus Cells	0-1/HPF	/hpf		
Tc/Sqc(Transitional/Squamous epithelial cells)	6-8/HPF	/hpf		

Lymphocytes	38	%	●	20-45
Eosinophils	03	%	●	1-6
Monocytes	03	%	●	1-10
Basophils	00	%	●	0-1
ERYTHROCYTE SEDIMENTATION RATE (ESR)	07	mm/1st hr	●	0-20

BLOOD GROUPING AND TYPING (ABO and Rh)

Test Name	Result	Unit	Level	Range
ABO Group:	B			
Rh (D) Type:	POSITIVE			

LIVER FUNCTION TEST (PACKAGE)

Test Name	Result	Unit	Level	Range
ALT(SGPT) - SERUM / PLASMA	24 *	U/L	●	30-65
ALBUMIN - SERUM	4.4	g/dL	●	3.5-5
GLOBULIN - SERUM: (Calculated)	2.2	g/dL	●	1.8-3.6
ALBUMIN:GLOBULIN - SERUM(RATIO) (Calculated)	2.0 *		●	1.1-1.8
ALKALINE PHOSPHATASE - SERUM/PLASMA	77	U/L	●	0-100
AST (SGOT) - SERUM	25	U/L	●	15-37
BILIRUBIN, TOTAL - SERUM	0.5	mg/dL	●	0.0-1.0

C B C WITH ESR (AUTOMATION + STANDARD METHOD)

Test Name	Result	Unit	Level	Range
Hemoglobin	13.2	g/dl	●	11.0-16.0
Haematocrit	40.3	%	●	34.0-48.0
● C COUNT	4.92	Million/ul	●	3.7-5.6
MCV	81.9	fl	●	75.0-95.0
MCH	26.9	pg	●	26.0-32.0
MCHC	32.8	g/dl	●	31.0-36.0
RDW	15.6	%	●	11-16
Platelet Count(Optical/Impedance)	268	10 ³ /m ³	●	140-440
TLC Count	7.8	10 ³ /m ³	●	4.0-11.0
Neutrophils	56	%	●	40-75

LIPID PROFILE TEST (PACKAGE)

Test Name	Result	Unit	Level	Range
Total Cholesterol	197	mg/dL	●	0-200

CREATININE - SERUM / PLASMA

Test Name	Result	Unit	Level	Range
CREATININE - SERUM / PLASMA	0.6	mg/dL	●	0.6-1.0

LIVER FUNCTION TEST (PACKAGE)

Test Name	Result	Unit	Level	Range
GGTP: GAMMA GLUTAMYL TRANSPEPTIDASE - SERUM	25	U/L	●	0-50

● Within Normal Range ● Borderline High/Low ● Out of Range



Name : Mrs. KALPANA MANOHAR PATIL (48 /F)

UJID : MHN1.0000123609

Date

29/07/2022

Package : MediWheel Full Body Health Checkup Female Below 40 Package

AHC No : NSKAH27152

GLUCOSE - SERUM / PLASMA (FASTING)

Test Name	Result	Unit	Level	Range
Glucose - Plasma (Fasting)	89	mg/dL	●	70-100
URINE GLUCOSE(FASTING): (Strip Method)	Nil			

TOTAL T3: TRI IODOTHYRONINE - SERUM

172

ng/dL

● Healthy Adults: 69 - 215
Pregnant Women: 1st Trimester:121-308
2nd & 3rd Trimesters:152-362

GLUCOSE - SERUM / PLASMA (POST PRANDIAL)

Test Name	Result	Unit	Level	Range
Glucose - Plasma (POST PRANDIAL)	101	mg/dL	●	70-140
URINE GLUCOSE(POST PRANDIAL):(Strip Method)	Nil			

TOTAL T4: THYROXINE - SERUM

8.2

µg/dL

● Healthy Adults: 5.2 - 12.7
Pregnancy:1st Trimester:7.8 - 16.2
2nd & 3rd Trimesters: 9.1 - 18.3

GLYCOSYLATED HEMOGLOBIN (HbA1C) - WHOLE BLOOD

Test Name	Result	Unit	Level	Range
Glycosylated Hemoglobin (HbA1c)	5.6	%	●	0.0-6.0
Mean Plasma Glucose (MPG) Estimate:	122.0600	mg/dL		

LIPID PROFILE TEST (PACKAGE)

Test Name	Result	Unit	Level	Range
Triglycerides - Serum	75	mg/dL	●	0-150

THYROID PROFILE - I (T3, T4 AND TSH)

Test Name	Result	Unit	Level	Range
TSH: THYROID STIMULATING HORMONE - SERUM	3.2	uIU/mL	●	Euthyroid: 0.3 - 4.5 Hypothyroid: 7.1 - >75.0 Pregnancy(All Trimesters):0.2 -3.5

LIPID PROFILE TEST (PACKAGE)

Test Name	Result	Unit	Level	Range
HDL CHOLESTEROL - SERUM / PLASMA	64 *	mg/dL	●	40-60
TOTAL CHOLESTEROL/HDL CHOLESTEROL RATIO(Calculated)	3.1		●	0.0-4.5
LDL Cholesterol (Direct LDL)	138	mg/dL		

UREA - SERUM / PLASMA

Test Name	Result	Unit	Level	Range
UREA - SERUM / PLASMA	16	mg/dL	●	15-38
UREA NITROGEN SERUM/PLASMA: (Calculated)	7	mg/dL	●	7-18

LIVER FUNCTION TEST (PACKAGE)

Test Name	Result	Unit	Level	Range
PROTEIN, TOTAL - SERUM / PLASMA	6.6	g/dL	●	6.4-8.2
PROTEIN, TOTAL - SERUM / PLASMA	6.6	g/dL	●	6.4-8.2

URIC ACID - SERUM

Test Name	Result	Unit	Level	Range
URIC ACID - SERUM	4.2	mg/dL	●	2.6-6.0

THYROID PROFILE - I (T3, T4 AND TSH)

Test Name	Result	Unit	Level	Range
-----------	--------	------	-------	-------

LIVER FUNCTION TEST (PACKAGE)

Test Name	Result	Unit	Level	Range
-----------	--------	------	-------	-------

● Within Normal Range ● Borderline High/Low ● Out of Range

Swaminarayan Nagar, Off Mumbai-Agra Highway,
Panchvati, Nashik - 422 003.

+91- 253 - 2510250 / 350 / 450 / 550 / 750

apollonashik@apollohospitals.com

www.askapollo.com

QFAHN/BILL/003/V1



Name : Mrs. KALPANA MANOHAR PATIL (48 /F)
UHID : MHN1.0000123609

Date

29/07/2022

Package : MediWheel Full Body Health Checkup Female Below 40 Package

AHC No : NSKAH27152

BILIRUBIN CONJUGATED (DIRECT) - SERUM	0.1	mg/dL	●	0.0-0.3
BILIRUBIN UNCONJUGATED - SERUM(Calculated)	0.4	mg/dL	●	0.0-0.7

CARDIAC STRESS TEST - (TMT)

ECG

ULTRASOUND - WHOLE ABDOMEN

A well-defined, complex solid-cystic, mass lesion in the right adnexa with dimensions as described above. The cystic component appears tubular with few incomplete internal septae within. The solid component shows mild vascularity. Right ovary is not seen separately from this solid-cystic mass lesion.

These findings are most likely s/o right sided tubo-ovarian mass lesion--?inflammatory or infective in etiology.

No other significant abnormality is detected.

Suggest : Clinical correlation. Further evaluation with serum Ca-125 levels and MRI pelvis is recommended.

X-RAY CHEST PA

INVESTIGATIONS NOT DONE / NOT YET REPORTED / NOT PART OF PACKAGE(LAB,RADIOLOGY & CARDIOLOGY)

Hematology

STOOL ROUTINE

Histopathology

CERVICAL/VAGINAL SMEAR II SLIDE

● Within Normal Range ● Borderline High/Low ● Out of Range

Swaminarayan Nagar, Off Mumbai-Agra Highway,
Panchvati, Nashik - 422 003.

+91- 253 - 2510250 / 350 / 450 / 550 / 750

apollonashik@apollohospitals.com
www.askapollto.com
UHID : MHN1.0000123609

QFAHN/BILL/003/V1



Name : Mrs. KALPANA MANOHAR PATIL (48 /F)

Date

29/07/2022


Package : MediWheel Full Body Health Checkup Female Below 40 Package

AHC No : NSKAH27152

Printed By :

AHC Physician / Consultant Internal Medicine

- Gynaec Ref.
Neurophysician Ref.



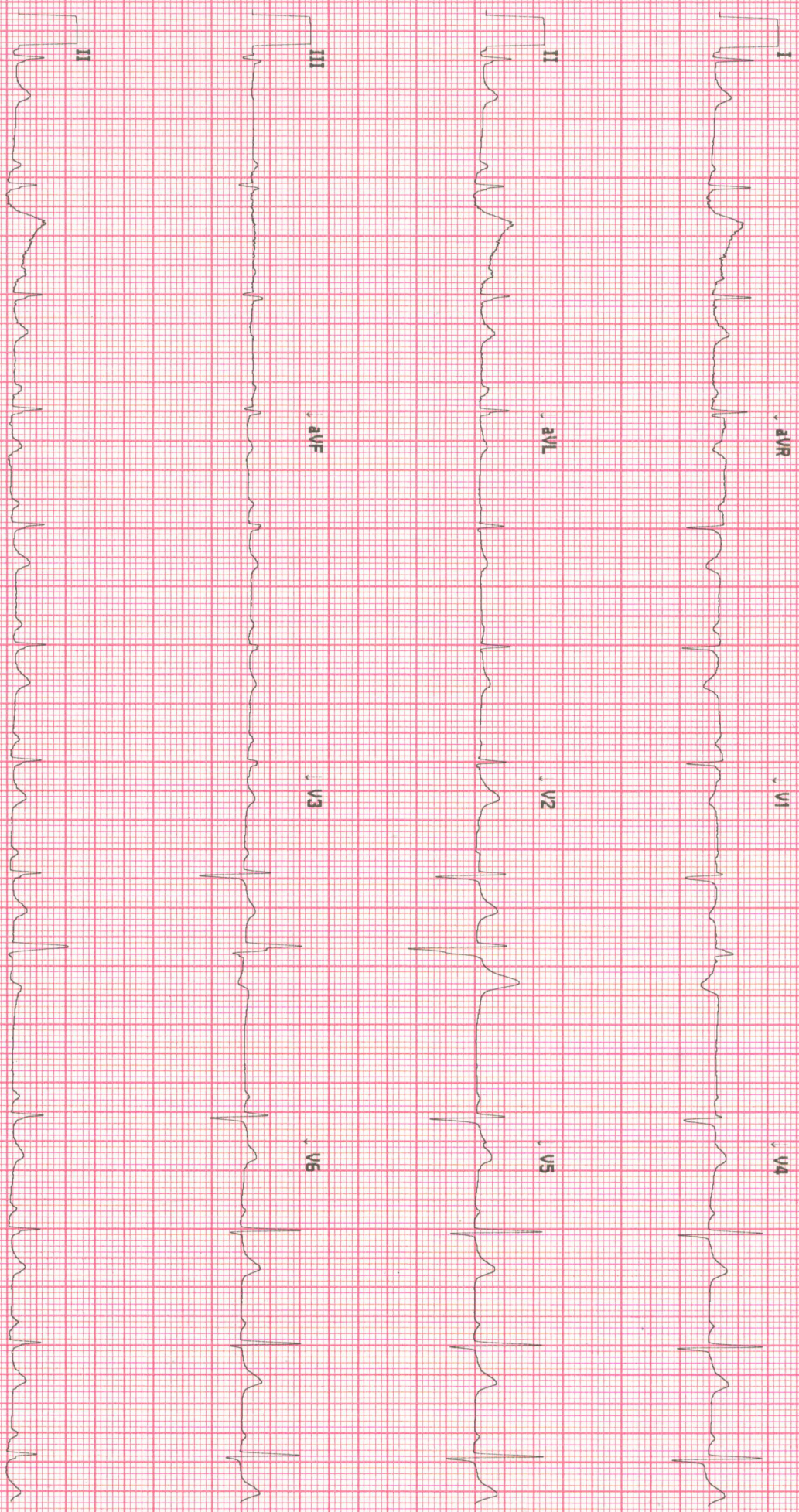
Note :- The Health Check-up examinations and routine investigations have certain limitations and may not be able to detect all the diseases. Any new or persisting symptoms should be brought to the attention of the Consulting Physician. Additional tests, consultations and follow up may be required in some cases.

Patil, Kalpana
ID:
DOB:
49yr, Female

29-Jul-2022 12:57:16

Vent rate: 75 BPM
PR int: 161 ms
QRS dur: 84 ms
QT/QTc: 370/399 ms
P-R-T axes: 49 23 23

SINUS RHYTHM WITH OCCASIONAL VENTRICULAR PREMATURE COMPLEXES
BORDERLINE ECG
UNCONFIRMED REPORT



11350018213

No Site Name

Site # 0 Cart # 2 Version 2.0.4.0 Sequence #19551 25mm/5 10mm/mV 0.05-40 Hz

Radiology

Patient Details : Mrs. KALPANA MANOHAR PATIL | Female | 48Yr 1Mth 28Days

UHID : MHN1.0000123609 **Patient Location:** AHC

Patient Identifier: NSKAH27152



DRN : 122027449 **Completed on :** 29-JUL-2022 12:05

Ref Doctor : DR. Rajashri Dhongade

X-RAY CHEST PA

Mild rotation.

Few tiny radio density is noted in left hilar region - ? calcified lymphnode.

Rest of the lung fields are clear.

Costophrenic angles are clear.

Cardiac size and contour are within normal limits.

Small left cervical rib is noted.

Rib cage is normal.

Soft tissues are normal.

Breast shadow and metal related artefacts are noted.

Suggest : Clinical correlation.

Impression

H Swaminarayan Nagar, Off Mumbai-Agra Highway,
Panchvati, Nashik - 422 003.

+91- 253 - 2510250 / 350 / 450 / 550 / 750

apollonashik@apollohospitals.com

www.askapollo.com

QFAHN/BILL/003/V1



Mrs. KALPANA MANOHAR PATIL

MHN1.0000123609

NSKAH27152

X-RAY CHEST PA

--- END OF THE REPORT ---

A handwritten signature in black ink, appearing to read 'Dr. Gorakhnath T'.

Dr.Gorakhnath T

CONSULTANT-RADIOLOGY





Radiology

Patient Details : Mrs. KALPANA MANOHAR PATIL | Female | 48Yr 1Mth 28Days

UHID : MHN1.0000123609

Patient Location: AHC

Patient Identifier: NSKAH27152



DRN : 222016594

Completed on : 29-JUL-2022 11:08

Ref Doctor : DR. Rajashri Dhongade

ULTRASOUND - WHOLE ABDOMEN

LIVER : Normal in size and measures 14cm. Echotexture is uniform and normal. No I.H.B.D./ focal lesions.

PORTAL VEIN: Normal in size.

GALL BLADDER: Well distended with normal walls and lumen.
No calculi/pericholecystic fluid.

COMMON BILE DUCT: Normal in size.

PANCREAS : Visualized portion of head and body of pancreas appears normal in size and echotexture. Rest of the pancreas is obscured due to bowel gases.

AORTA, IVC and para aortic areas are normal.

SPLEEN : Normal in size (9.7cm) and echotexture.

KIDNEYS: Both kidneys are normal in site, size and echotexture.

No evidence of calculi/ hydronephrosis.

Right kidney measures: 9.4 x 3.8 cm.

Left kidney measures : 10 x 4.8 cm.

URINARY BLADDER: Well distended with normal walls.

No evidence of calculi/ growth/ diverticula .

UTERUS: Not visualized (post-operative status).

A well-defined complex solid-cystic mass lesion measuring 6.5 x 5.5cm is seen in the right

Mrs. KALPANA MANOHAR PATIL

MHN1.0000123609

NSKAH27152

ULTRASOUND - WHOLE ABDOMEN

adnexa. The cystic component appears tubular with few incomplete internal septae within. The solid component shows mild vascularity. Right ovary is not seen separately from this solid-cystic mass lesion.

Left ovary is not visualized.

Visualized bowel loops appear normal.

No evidence of any free fluid in the peritoneal cavity.

Impression


A well-defined, complex solid-cystic, mass lesion in the right adnexa with dimensions as described above. The cystic component appears tubular with few incomplete internal septae within. The solid component shows mild vascularity. Right ovary is not seen separately from this solid-cystic mass lesion.

These findings are most likely s/o right sided tubo-ovarian mass lesion--?inflammatory or infective in etiology.

No other significant abnormality is detected.

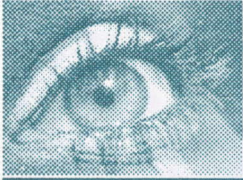
Suggest : Clinical correlation. Further evaluation with serum Ca-125 levels and MRI pelvis is recommended.

---- END OF THE REPORT ----



Dr. Harshal S Dhongade

Consultant - Radiology



OPHTHALMOLOGY



Name : Mrs. Kalpana Patil Date 29/07/22 UNIT _____
 Occupation : _____ Room No. _____ Out Patient
 Age : 49 Sex : Male Female S/M/W/D Ref. Physician : _____
 Address : NSIC Copies to : _____
 _____ Tel. No. _____

REPORT ON OPHTHALMIC EXAMINATION

HISTORY : _____

PRESENT COMPLAINT : (BB) Burning x 3-4 month

PAST HISTORY : DM / HTN / ALLERGY

ON EXAMINATION

VISION :

RE: G16 VA 6/60p.
 LE: N18 VA 6/36p
pn 6/9 6/9

	RIGHT					LEFT				
	PGP	SPH	CYL	AXIS	VA	SPH	CYL	AXIS	VA	
DIST										
NEAR										

R / Retinoscopy :

RIGHT			LEFT		
SPH	CYL	AXIS	SPH	CYL	AXIS
<u>+1.75</u>	<u>+0.75</u>	<u>180°</u>	<u>+1.25</u>	<u>-0.75</u>	<u>4°</u>

Refraction or Acceptance :

	RIGHT				LEFT			
	SPH	CYL	AXIS	VA	SPH	CYL	AXIS	VA
DIST	<u>+1.50</u>	<u>+0.50</u>	<u>180°</u>	<u>6/6</u>	<u>+1.50</u>	<u>+0.50</u>	<u>180°</u>	<u>6/6</u>
NEAR	<u>+2.00</u>	<u>---</u>	<u>---</u>	<u>N16</u>	<u>+2.00</u>	<u>---</u>	<u>---</u>	<u>N16</u>

Add

Handwritten signature


CONSULTANT OPTOMETRIST

Anterior Segment :

RE

Normal pupils NM

LE



Normal

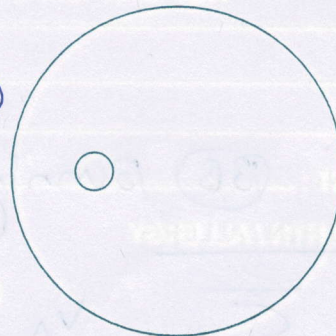
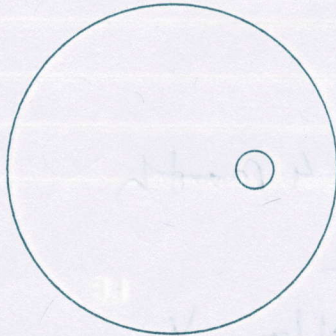


Fundus :

RE

Good @

LE



Diagnosis :

DN

Myopia

= Hyperopia

Advise / Rx:

Myopia cycloph

DN

1 week
OPD

near drop cycloph

DN

regular

ORAL EXAMINATION FORM



Date: 29/7/22

Patient ID: _____ MHC

Patient Name: Ms Kalpana Patil Age: 49 Sex: Male Female

Chief Complaint:

Medical History:

Drug Allergy:

Medication currently taken by the Guest:

Initial Screenign Findings:

Dental Caries: NAD

Missing Teeth:

Impacted Teeth: -

Attrition / Abrasion: Generalized Attrition

Bleeding: -

Pockets / Recession: -

Calculus / Stains: ++

Mobility: -

Restored Teeth: -

Non - restorable Teeth for extraction / Root Stumps:

Malocclusion:

Class B malocclusion

Others: -

Advice:- Scaling Req, Filling Req

Doctor Name & Signature:

[Signature]
Dr Prinyanka Patil

9096986290 / 8275015672