

Mrs. MANJU SHEKHAWAT (49 /F)

UHID : AHIL.0000480233

AHC No : AHILAH198014

Date : 11/03/2023

MEDIWHEEL-FULL BODY CHK-ABOVE40-FEMALE

Namaste Mrs. MANJU SHEKHAWAT,

Thank you for choosing Apollo ProHealth, India's first AI-powered health management program, curated to help you make positive health shifts. Being healthy is about making smart choices, and you have taken the first step with this program. We are privileged to be your healthcare partner. Your health is our priority.

We are with you on your path to wellness by:

Predicting your risk: Artificial Intelligence-powered predictive risk scores are generated, based on your personal, medical, and family history and detailed multi-organ evaluation of your body through diagnostic and imaging tests.

Preventing onset or progress of chronic lifestyle diseases: Your Health Mentor is available to help you understand your physician's recommendations and helping you handle any concerns (complimentary service up to one year)

Overcoming barriers to your wellbeing: Your Health Mentor will help you set your health goals and guide you with tips to stay on track. We will also, digitally remind you to proactively prioritize your health.

Through this report, you will be able to understand your overall health status, your health goals and the recommendations for your path to wellness. Your Health Report will include the following:

- Your medical history and physical examination reports
- Results from your diagnostic and imaging tests
- AI powered health risk scores
- Your physician's impression and recommendations regarding your overall health
- Your personalized path to wellness, including your follow-up assessments and vaccinations

For Enquiry/Appointments Contact +91 76988 15003 / +91 79 66701880

Apollo Hospitals International Limited
Plot No.-1A, Bhat, GIDC, Gandhinagar, Gujarat - 382428, India.
Phone : +91 79 66701800 | Fax No. : +91 79 66701843
E-mail : info@apolloahd.com | www.ahmedabad.apollohospitals.com

Apollo Hospitals - City Centre (NON NASH-IC)
1, Tulsibaug Society, Nr. Parimal Garden, Ahmedabad.
Phone : +91 79 66305800 / 01 or +91 76988 15148
E-mail : info@ahd@apolloahd.com

Regd. Office
19, Bishop Gardens, R.A. Puram, Chennai - 600 028
CIN No. : U85110TN1997PLC039016 | GSTIN : 24AA8CA4150H225
For online appointment : www.askapollo.com

For online appointment : www.askapollo.com
Keep the records carefully and bring them along during your next visit to our Hospital

We have reviewed the results of the tests and have identified some areas for you to act on. We believe that with focus and targeted interventions, you can be healthier and happier.



Scan the QR code to download the Apollo 247 App



Organizational Accredited
by Joint Commission International



You can visit your proHealth physician in person at this center, or you can book a virtual consultation for review via www.apollo247.com or through the Apollo 24*7 mobile app. You can avail 30% discount on additional tests and follow-up tests at Apollo Hospitals within one week. You may call your Health Mentor on 04048492633 or email at prohealthcare@apollohospitals.com

Stay Healthy and happy! 😊
Apollo ProHealth Care team

Disclaimer: The services offered in the program may vary depending on any prior mutual agreements between guests and the facility/unit.

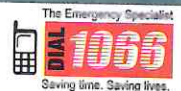For Enquiry/Appointments Contact +91 76988 15003 / +91 79 66701880

Apollo Hospitals International Limited
Plot No.-1A, Bhat, GIDC, Gandhinagar, Gujarat - 382429, India.
Phone : +91 79 66701800 | Fax No. : +91 79 66701843
E-mail : info@apolloahd.com | www.ahmedabad.apollohospitals.com

Apollo Hospitals - City Centre (INDIA NABH-JCI)
1, Tulsiang Society, Nr. Parnimal Garden, Ahmedabad.
Phone : +91 79 66305800 / 01 or +91 76988 15148
E-mail : infoahcc@apolloahd.com

Regd. Office
19, Bishop Gardens R.A. Puram, Chennai - 600 028
CIN No. : U85110TN1997PLC039016 | GSTIN : 24AABC44150H225
For online appointment : www.askapollo.com

For online appointment : www.askapollo.com
Keep the records carefully and bring them along during your next visit to our Hospital





Organization is Accredited
by Joint Commission International

Name : Mrs. MANJU SHEKHAWAT (49 /F)

Date : 11/03/2023

Address : 27 PARVATI PARK SOCIETY, AHMEDABAD, AHMEDABAD, GUJARAT, INDIA



Examined by : Dr. SHASHIKANT NIGAM

UHID : AHIL.0000480233

MEDIWHEEL-FULL BODY CHK-ABOVE40-FEMALE

AHC No : AHILAH198014



Chief Complaints

For Annual health checkup
No specific complaints



System Review

- Cardiovascular system** : - Nil Significant
- Respiratory system** : - Nil Significant
- Oral and dental** : - Nil Significant
- Gastrointestinal system** : - Nil Significant
- Genitourinary system** : - Nil Significant
- Gynaec history** : - Nil Significant
- Central nervous system** : - Nil Significant
- Eyes** : - Nil Significant
- ENT** : - Nil Significant
- Musculoskeletal system** :
- Spine and joints** :
- Nil Significant
- Skin** : - Nil Significant
- General symptoms** : - Nil Significant



Past medical history

- Do you have any allergies? - Yes
- Allergies - dust,pollens
- Do you have any drug allergies? - No
- Covid 19 - Yes
- Hospitalization for Covid 19 - Yes



Surgical history



Name: Mrs. MANJU SHEKHAWAT

UHID : AHIL.0000480233

Date 11/03/2023

MEDIWHEEL-FULL BODY CHK-ABOVE40-FEMALE

AHC No. AHILAH198014



Organization is Accredited by Joint Commission International

Caesarian section - 1998 & 2002

Cataract surgery - LEFT



Personal history

Ethnicity - Indian Asian

Marital status - Married

No. of children - 2

Female - 1

Male - 1

Diet - Vegetarian

Alcohol - does not consume alcohol

Smoking - No

Chews tobacco - No

Physical activity - Moderate



Family history

Father - alive

Aged - 89

Mother - alive

Aged - 85

Brothers - 3

Diabetes - mother

Hypertension - mother

Coronary artery disease - none

Cancer - None

Physical Examination



General

General appearance - normal

Build - normal

Height - 159

Weight - 69.2

BMI - 27.37

Pallor - No



Name: Mrs. MANJU SHEKHAWAT

UHID : AHIL.0000480233

Date 11/03/2023

MEDIWHEEL-FULL BODY CHK-ABOVE40-FEMALE

AHC No. AHILAH198014



Organization is Accredited by Joint Commission International

Edema - no



Cardiovascular system

Heart rate (Per minute) - 80
Rhythm - Regular
- B.P. Supine
Systolic(mm of Hg) - 120
Diastolic(mm of Hg) - 80
Heart sounds - S1S2+

Respiratory system

Breath sounds - Normal vesicular breath sounds



Abdomen

Organomegaly - No
Tenderness - No

Printed By : MUKTA S ADALTI

Page 5 of 12

For Enquiry/Appointments Contact +91 76988 15003 / +91 79 66701880

Apollo Hospitals International Limited
Plot No.-1A, Bhat, GIDC, Gandhinagar, Gujarat - 382429, India.
Phone : +91 79 66701800 | Fax No. : +91 79 66701843
E-mail : info@apolloahd.com | www.ahmedabad.apollohospitals.com

Apollo Hospitals - City Centre (NON NABH-JCI)
1, Tulsi Bhag Society, Nr. Parnal Garden, Ahmedabad.
Phone : +91 79 66306900 / 01 or +91 76988 15148
E-mail : infoahcc@apolloahd.com

Regd. Office
19, Bishop Gardens, R.A. Puram, Chennai - 600 028
CIN No. : U85110TN1997PLC039016 | GSTin : 24AABCA4150H225
For online appointment : www.askapollo.com

For online appointment : www.askapollo.com
Keep the records carefully and bring them along during your next visit to our Hospital





Name: Mrs. MANJU SHEKHAWAT

UHID : AHIL.0000480233

Date 11/03/2023

MEDIWHEEL-FULL BODY CHK-ABOVE40-FEMALE

AHC No. AHILAH198014



Organization is Accredited by Joint Commission International

URINE FOR ROUTINE EXAMINATION

Urinalysis, is the physical, chemical and microscopic examination of the urine and is one of the most common methods of medical diagnosis. It is used to detect markers of diabetes, kidney disease, infection etc.*

Test Name	Result	Unit	Level	Range
Volume	30	mL		
Specific Gravity	1.010			
Colour:	Pale-Yellow			
Transparency:	Clear			
pH	6			
Protein :	Nil			
Sugar:	Nil			
Blood:	Negative			
Ketone	Absent			
Bile Pigments:	Absent			
Urobilinogen	Nil	E.U./dL		
Nitrite	Negative			
Pus Cells	2-4 /h.p.f			0-5
RBC	1-2 /h.p.f	/hpf		0-5/hpf
Epithelial Cells	1-2 /h.p.f			
Casts:	Absent			
Crystals:	Absent			

COMPLETE BLOOD COUNT WITH ESR

Test Name	Result	Unit	Level	Range
Hemoglobin (Photometric Measurement)	10.7 *	gm%	●	12-16
Packed cell volume(Calculated)	35.4 *	%	●	36-46
RBC COUNT (Impedance)	5.51 *	Million/ul	●	3.8-5.2
MCV (From RBC Histogram)	64.3 *	fl	●	80-100
MCH(Calculated)	19.48 *	pg	●	27-32
MCHC(Calculated)	30.3 *	%	●	31-36
RDW(Calculated)	19.3 *	%	●	11.5-14.5
WBC Count (Impedance)	6271	/cu mm	●	4000-11000

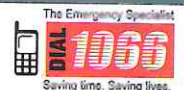● Within Normal Range ● Borderline High/Low ● Out of Range

For Enquiry/Appointments Contact +91 76988 15003 / +91 79 66701880

Apollo Hospitals International Limited
 Plot No.-1A, Bhat, GIDC, Gandhinagar, Gujarat - 382429, India.
 Phone : +91 79 66701800 | Fax No. : +91 79 66701843
 E-mail : info@apolloahd.com | www.ahmedabad.apollohospitals.com

Apollo Hospitals - City Centre (NON NABH-JCI)
 1, Tulsibang Society, Nr. Pannal Garden, Ahmedabad.
 Phone : +91 79 66305800 / 01 or +91 76988 15148
 E-mail : infoahcc@apolloahd.com

Regd. Office
 19, Bishop Gardens, R.A. Puram, Chennai - 600 028
 CIN No. : UB5110TN1997PLC039016 | GSTin : 24AABCA4150H2Z5
 For online appointment : www.askapollo.com



For online appointment : www.askapollo.com
Keep the records carefully and bring them along during your next visit to our Hospital

The Emergency Specialist
Saving time. Saving lives.



Name Mrs. MANJU SHEKHAWAT

UHID : AHIL.0000480233

Date 11/03/2023

AHC No. AHILAH198014



Organization is Accredited by Joint Commission International

Neutrophils

60 % ● 40-75

Lymphocytes

31 % ● 20-40

Monocytes

07 % ● 2-10

Eosinophils

02 % ● 01-06

Basophils

00 % ● 0-1

Platelet Count (Impedance)

171600 /cu mm ● 150000-450000

MPV (Calculated)

8.7 fl ● 7-11

RBC:

Erythrocytosis noted

RBC::

Eliptocytes (+)~Target cells (+)~Hypochromia (+)~Microcytes (+)

ERYTHROCYTE SEDIMENTATION RATE (ESR) (Automated/ optic-electronic)

05 mm/1st hr ● 0-20

SUGGEST :

Hb electrophoresis.~S. Iron Profile is indicated.

URINE GLUCOSE(FASTING)

Test Name	Result	Unit	Level	Range
Urine Glucose (Post Prandial)	Nil			

URINE GLUCOSE(POST PRANDIAL)

Test Name	Result	Unit	Level	Range
Urine Glucose (Post Prandial)	Nil			

BLOOD GROUPING AND TYPING (ABO and Rh)

Test Name	Result	Unit	Level	Range
BLOOD GROUP:	A Positive			

LFT (LIVER FUNCTION TEST)

Liver function tests(LFT), are groups of clinical biochemistry blood assays that give information about the state of a patient's liver. These tests can be used to detect the presence of liver disease, distinguish among different types of liver disorders, gauge the extent of known liver damage, and follow the response to treatment.

Test Name	Result	Unit	Level	Range
ALT(SGPT) - SERUM / PLASMA	26	U/L	●	0-35
ALKALINE PHOSPHATASE - SERUM/PLASMA	115 *	U/L	●	Adult(Female): 35 - 104
AST (SGOT) - SERUM	26	U/L	●	>1 year Female : <32

● Within Normal Range ● Borderline High/Low ● Out of Range



Name Mrs. MANJU SHEKHAWAT

UHID : AHIL.0000480233

Date 11/03/2023

AHC No. AHILAH198014



Organization is Accredited by Joint Commission International

MEDIWHEEL-FULL BODY CHK-ABOVE40-FEMALE

Total Bilirubin	0.385	mg/dL	●	0.300-1.200
Direct Bilirubin	0.19	mg/dL	●	Upto 0.3 mg/dl
Indirect Bilirubin	0.195	mg/dL	●	1 Day ≤5.1 mg/dL 2 Days ≤7.2 mg/dL 3-5 Days ≤10.3 mg/dL 6-7 Days ≤8.4 mg/dL 8-9 Days ≤6.5 mg/dL 10-11 Days ≤4.6 mg/dL 12-13 Days ≤2.7 mg/dL 14 Days - 9 Years 0.2-0.8 mg/dL 10-19 Years 0.2-1.1 mg/dL ≥20 Years 0.2-1.2 mg/dL

CREATININE - SERUM / PLASMA

Test Name	Result	Unit	Level	Range
CREATININE - SERUM / PLASMA	0.5	mg/dL	●	Adult Female: 0.5 - 1.2

LFT (LIVER FUNCTION TEST)

Liver function tests(LFT), are groups of clinical biochemistry blood assays that give information about the state of a patient's liver. These tests can be used to detect the presence of liver disease, distinguish among different types of liver disorders, gauge the extent of known liver damage, and follow the response to treatment.

Test Name	Result	Unit	Level	Range
GGTP: GAMMA GLUTAMYL TRANSPEPTIDASE - SERUM	76 *	U/L	●	Male : 10 - 71 Female : 6 - 42

GLUCOSE - SERUM / PLASMA (FASTING)

Test Name	Result	Unit	Level	Range
Glucose - Plasma (Fasting)	97	mg/dL	●	70 - 100 : Normal 100 - 125 : Impaired Glucose Tolerance ≥ 126 : Diabetes Mellitus

GLUCOSE - SERUM / PLASMA (POST PRANDIAL) - PPBS

Test Name	Result	Unit	Level	Range
Glucose - Plasma (Post Prandial)	117	mg/dL	●	70-140

GLYCOSYLATED HEMOGLOBIN (HBA1C) - WHOLE BLOOD

Test Name	Result	Unit	Level	Range
-----------	--------	------	-------	-------

● Within Normal Range ● Borderline High/Low ● Out of Range

For Enquiry/Appointments Contact +91 76988 15003 / +91 79 66701880

Apollo Hospitals International Limited
 Plot No.-1A, Bhat, GIDC, Gandhinagar, Gujarat - 382429, India.
 Phone : +91 79 66701800 | Fax No. : +91 79 66701843
 E-mail : info@apolleahd.com | www.ahmedabad.apollohospitals.com

Apollo Hospitals - City Centre (NON WASH-JCI)
 1, Tulsiang Society, Nr. Parnimal Garden, Ahmedabad.
 Phone : +91 79 66305800 / 01 or +91 79908 15148
 E-mail : infoahcc@apolleahd.com

Regd. Office
 19, Bishop Gardens, R.A. Puram, Chennai - 600 028
 CIN No. : U85110TN1997PLC039016 | GSTin : 24AABC44150H225
 For online appointment : www.askapollo.com



For online appointment : www.askapollo.com
Keep the records carefully and bring them along during your next visit to our Hospital



Name Mrs. MANJU SHEKHAWAT

UHID : AHIL.0000480233

Date 11/03/2023

AHC No. AHILAH198014



Organization is Accredited by Joint Commission International

Glycosylated Hemoglobin (HbA1c)

5.3

%



Normal < 5.7

%Increased risk for Diabetes 5.7 - 6.4%

Diabetes >= 6.5%

Monitoring criteria for Diabetes Mellitus
<7.0 : Well Controlled Diabetes
7.1 – 8.0 : Unsatisfactory Control
> 8.0 : Poor Control & Needs Immediate Treatment

Estimated Average Glucose.

105.41

LFT (LIVER FUNCTION TEST)

Liver function tests(LFT), are groups of clinical biochemistry blood assays that give information about the state of a patient's liver. These tests can be used to detect the presence of liver disease, distinguish among different types of liver disorders, gauge the extent of known liver damage, and follow the response to treatment.

Test Name	Result	Unit	Level	Range
PROTEIN TOTAL - SERUM / PLASMA	7.22	g/dL		6.00-8.00
PROTEIN TOTAL - SERUM / PLASMA	7.22	g/dL		6.00-8.00
ALBUMIN - SERUM	4.07	g/dL		Adult(18 - 60 Yr): 3.5 - 5.2
ALBUMIN - SERUM	4.07	g/dL		Adult(18 - 60 Yr): 3.5 - 5.2
Globulin-Serum/Plasma	3.15			2.20-4.20
Globulin-Serum/Plasma	3.15			2.20-4.20
A/G ratio	1.29			1.00-2.00
A/G ratio	1.29			1.00-2.00

THYROID PROFILE (T3,T4 AND TSH)

Test Name	Result	Unit	Level	Range
TOTAL T3: TRI IODOTHYRONINE - SERUM	1.5	nmol/L		Adults(20-120 Yrs): 1.2 - 3.1 Pregnant Female : First Trimester : 1.61 - 3.53 Second Trimester : 1.98 - 4.02 Third Trimester : 2.07 - 4.02
TOTAL T4: THYROXINE - SERUM	62 *	nmol/L		Adults(20-100 Yrs) :66 - 181 Pregnant Female : First Trimester : 94.3 - 190 Second Trimester : 102 - 207 Third Trimester : 89 - 202
TSH: THYROID STIMULATING HORMONE - SERUM	3.09	µIU/mL		14-120 years : 0.27 - 4.20



Within Normal Range



Borderline High/Low



Out of Range



Name: Mrs. MANJU SHEKHAWAT

UHID : AHIL.0000480233

Date : 11/03/2023

MEDIWHEEL-FULL BODY CHK-ABOVE40-FEMALE

AHC No: AHILAH198014



Organization is Accredited by Joint Commission International

URIC ACID - SERUM

Uric acid is a product of the metabolic breakdown of purine. High blood concentrations of uric acid can lead to gout. It is also associated with other medical conditions including diabetes and the formation of kidney stones.

Test Name	Result	Unit	Level	Range
URIC ACID - SERUM	3.5	mg/dL	●	Male : 3.4-7.0 Female : 2.4-5.7

BUN (BLOOD UREA NITROGEN)

Test Name	Result	Unit	Level	Range
BUN (BLOOD UREA NITROGEN)	9	mg/dL	●	6-20
UREA - SERUM / PLASMA	20	mg/dL	●	15 - 50

LIPID PROFILE - SERUM

Test Name	Result	Unit	Level	Range
Total Cholesterol	145	mg/dl	●	0 - 200 : Desirable 200 - 240 : Borderline High 240 - 280 : High > 280 : Very High
Triglycerides - Serum	80	mg/dL	●	0-150
HDL CHOLESTEROL - SERUM / PLASMA (Direct Enzymatic Colorimetric)	47 *	mg/dL	●	< 40 : Major risk factor for heart disease 40 - 59 : The higher The better. >=60 : Considered protective against heart disease
LDL Cholesterol (Direct LDL)	94	mg/dL	●	100 : Optimal 100-129 : Near Optimal 130-159 : Borderline High 160-189 : High >=190 : Very High
VLDL CHOLESTEROL	16		●	< 40 mg/dl
C/H RATIO	3		●	0-4.5

X-RAY CHEST PA

X-ray imaging creates pictures of the inside of your body. Chest X-ray can reveal abnormalities in the lungs, the heart, and bones that sometimes cannot be detected by examination.

● Within Normal Range ● Borderline High/Low ● Out of Range



Name: Mrs. MANJU SHEKHAWAT

UHID : AHIL.0000480233

Date : 11/03/2023

MEDIWHEEL-FULL BODY CHK-ABOVE40-FEMALE

AHC No. AHILAH198014



Organization is Accredited by Joint Commission International

Prominent vascular markings seen.

Lung fields are otherwise clear.

Cardio thoracic ratio is normal.

Both costophrenic angles are clear.

Domes of diaphragm are well delineated.

Bony thorax shows no significant abnormality.

ECHO/TMT

Investigations Not Done / Not Yet Reported

Haematology

STOOL ROUTINE

CARDIOLOGY

ECG



Within Normal Range



Borderline High/Low



Out of Range





Name : Mrs. MANJU SHEKHAWAT

UHID : AHIL.0000480233

Date : 11/03/2023

MEDIWHEEL-FULL BODY CHK-ABOVE40-FEMALE

AHC No. AHILAH198014



Organization is Accredited by Joint Commission International

Executive Summary



- .BODY WEIGHT 69.2 KG,DEAL BODY WEIGHT 47-57 KG
- .ECG - NORMAL SINUS RHYTHM
- .ECHO - NORMAL
- .USG ABDOMEN - NO SIGNIFICANT ABNORMALITY
- .CHEST X-RAY - PROMINENT VASCULAR MARKINGS SEEN
- .EYE - NORMAL
- .DENTAL - AS PER DOCTOR ADVICE
- .MAMMOGRAPHY - BIRADS- O

Wellness Prescription

Advice On Diet :-



- BALANCED DIET---
- LOW FAT DIET
- LOW CARBOHYDRATE DIET

Advice On Physical Activity :-



- REGULAR WALK FOR 30 MINS FOR HEALTH,
- 60 MINS WALK FOR WEIGHT REDUCTION
- PRACTICE YOGA AND MEDITATION
- MAINTAIN WEIGHT BETWEEN 47-57 KG

*Adv Hb Electrolysis
to RW R.T.T.*

Printed By : MUKTA S ADALTI

16/3/2023
Dr. SHASHIKANT NIGAM

AHC Physician / Consultant Internal Medicine

Dr. Shashikant Nigam
M.B.B.S, M.D (Gen. Med.)
Apollo Consultant Internal Medicine
Apollo Hospitals International Ltd, Gandhinagar,
Gujarat-382428, INDIA. Reg. No. 16-25-21961

Note :- The Health Check-up examinations and routine investigations have certain limitations and may not be able to detect all the diseases. Any new or persisting symptoms should be brought to the attention of the Consulting Physician. Additional tests, consultations and follow up may be required in some cases.

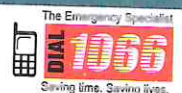For Enquiry/Appointments Contact +91 76988 15003 / +91 79 66701880

Apollo Hospitals International Limited
Plot No.-1A, Bhat, GIDC, Gandhinagar, Gujarat - 382429, India.
Phone : +91 79 66701800 | Fax No. : +91 79 66701843
E-mail : info@apolloahd.com | www.ahmedabad.apollohospitals.com

Apollo Hospitals - City Centre (NON NASH-ICI)
1, TulsiBaag Society, Nr. Panimal Garden, Ahmedabad.
Phone : +91 79 66305800 / 01 or +91 76988 15148
E-mail : infoahcc@apolloahd.com

For online appointment : www.askapollo.com
Keep the records carefully and bring them along during your next visit to our Hospital

Regd. Office
19, Bishop Gardens, R.A. Puram, Chennai - 600 028
CIN No. : U85110TN1997PLC039016 | GSTin : 24AABCA4150H225
For online appointment : www.askapollo.com




The Emergency Specialist
DIAL 1055
Saving time. Saving lives.



Organization is Accredited
by Joint Commission International



RADIOLOGY

Patient Details : Mrs. MANJU SHEKHAWAT | Female | 49Yr 7Mth 1Days
UHID : AHIL.0000480233 **Patient Location:** AHC
Patient Identifier: AHILAH198014 
DRN : 1323004767 **Completed on :** 11-MAR-2023 16:35
Ref Doctor : DR. SHASHIKANT NIGAM

MAMMOGRAPHY BOTH BREAST

FINDINGS :

Breast composition :-

C. Heterogenously dense parenchyma obscuring optimum mammography evaluation.

Both breasts show normal architecture of parenchyma, with glandular and fibrofatty elements.

No evidence of obvious focal lesion seen.

No evidence of any pleomorphic microcalcification.

No evidence of skin thickening or nipple retraction seen.

Retromammary area is normal.

Axillary tail region appear normal.

Nodes with preserved hilum noted in both axillary region.

IMPRESSION :

No significant abnormality.

(BIRADS-0)

In dense breast correlation with USG or previous study suggested.

Printed on : 12-Mar-2023 12:55

Printed By : 153182

Reported By : 717876

Page 1 of 2

For Enquiry/Appointments Contact +91 76988 15003 / +91 79 66701880

Apollo Hospitals International Limited
Plot No.-1A, Bhat, GIDC, Gandhinagar, Gujarat - 382428, India.
Phone : +91 79 66701800 | Fax No. : +91 79 66701843
E-mail : info@apolloaid.com | www.ahmedabad.apollohospitals.com

Apollo Hospitals - City Centre (NON HASH-CD)
1, Tulsibang Society, Nr. Parimal Garden, Ahmedabad.
Phone : +91 79 66305800 / 01 or +91 76988 15148
E-mail : infoahcc@apolloaid.com

Regd. Office
19, Bishop Gardens, R.A. Puram, Chennai - 600 028
CIN No. : U85110TN1997PLC039016 | GSTin : 24AARG4150H225
For online appointment : www.askapollo.com

For online appointment : www.askapollo.com
Keep the records carefully and bring them along during your next visit to our Hospital



Saving time. Saving lives.



Organization is Accredited
by Joint Commission International



Mrs. MANJU SHEKHAWAT

AHIL.0000480233

AHILAH198014

MAMMOGRAPHY BOTH BREAST

— END OF THE REPORT —

Nikita

Dr. NIKITA PANDYA

Consultant Radiologist

Printed on : 12-Mar-2023 12:55

Printed By : 153182

Reported By : 717876

Page 2 of 2

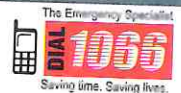For Enquiry/Appointments Contact +91 76988 15003 / +91 79 66701880

Apollo Hospitals International Limited
Plot No.-1A, Bhat, GIDC, Gandhinagar, Gujarat - 382428, India.
Phone : +91 79 66701800 | Fax No. : +91 79 66701843
E-mail : info@apolloahd.com | www.ahmedabad.apollohospitals.com

Apollo Hospitals - City Centre મોન નાશ-સી
1, TulsiBaag Society, Nr. Parimal Garden, Ahmedabad.
Phone : +91 79 66305800 / 01 or +91 76988 15148
E-mail : info@apolloahd.com

Regd. Office
19, Bishop Gardens, R.A. Puram, Chennai - 600 028
CIN No. : U85110TN1997PLC039016 | GSTin : 24AABCA4150H225
For online appointment : www.askapollo.com

For online appointment : www.askapollo.com
Keep the records carefully and bring them along during your next visit to our Hospital




Saving time. Saving lives.



Organization is Accredited
by Jenit Commission International



Radiology

Patient Details : Mrs. MANJU SHEKHAWAT | Female | 49Yr 7Mth 1Days
UHID : AHIL.0000480233 **Patient Location:** AHC
Patient Identifier: AHILAH198014 
DRN : 223013773 **Completed on :** 11-MAR-2023 11:28
Ref Doctor : DR. SHASHIKANT NIGAM

USG WHOLE ABDOMEN

FINDINGS :

Liver appears normal in size and shows uniform normal echotexture. No evidence of focal or diffuse pathology seen. Intra and extra hepatic biliary radicles are not dilated. Portal vein is normal in calibre. Intrahepatic portal radicles appear normal.

Gall bladder appears normal with no evidence of calculus. Wall thickness appears normal. No evidence of pericholecystic collection.

Head, body and tail of pancreas appear normal in size and echotexture. No focal lesions identified Pancreatic duct appears normal in caliber.

Spleen measures 9.8 cms and shows uniform echotexture.

Both kidneys are normal in size and show normal echopattern with good corticomedullary differentiation. Cortical outlines appear smooth. No evidence of calculi. Pelvicalyceal system on both sides appear normal.

No evidence of ascites or lymphadenopathy.

Urinary bladder is normal in contour and outline. Wall thickness appears normal. No evidence of any intraluminal pathology seen.

Uterus is anteverted and appears normal in size and echotexture. No focal lesion is seen. Myometrial and endometrial echopattern appear normal. Endometrial thickness is 3 mm. No free fluid is seen in Pouch Of Douglas.

No definite evidence of adnexal/pelvic mass is seen.

IMPRESSION :

Printed on : 12-Mar-2023 12:56

Printed By : 153182

Reported By : 717876

Page 1 of 2

For Enquiry/Appointments Contact : +91 76988 15003 / +91 79 66701880

Apollo Hospitals International Limited
Plot No.-1A, Bhat, GIDC, Gandhinagar, Gujarat - 382428, India.
Phone : +91 79 66701800 | Fax No. : +91 79 66701843
E-mail : info@apolloahd.com | www.ahmedabad.apollohospitals.com

Apollo Hospitals - City Centre (NON NABH-JCI)
1, Tulsibaug Society, Nr. Parnmal Garden, Ahmedabad.
Phone : +91 79 66305800 / 01 or +91 78988 15148
E-mail : infoahcc@apolloahd.com

Regd. Office
19, Bishop Gardens, R.A. Puram, Chennai - 600 028
CIN No. : U85110TN1997PLC039016 | GSTin : 24AAABC44150H225
For online appointment : www.askapollo.com

For online appointment : www.askapollo.com
Keep the records carefully and bring them along during your next visit to our Hospital



Saving time. Saving lives.



Organization is Accredited
by Joint Commission International



Mrs. MANJU SHEKHAWAT

AHIL.0000480233

AHILAH198014

USG WHOLE ABDOMEN

NO SIGNIFICANT ABNORMALITY DETECTED.

— END OF THE REPORT —

A. A. PATEL

Dr. ALPESH A PATEL

DNB Resident

Printed on : 12-Mar-2023 12:56

Printed By : 153182

Reported By : 717876

Page 2 of 2

Apollo Hospitals International Limited
Plot No.-1A, Bhat, GIDC, Gandhinagar, Gujarat - 382428, India.
Phone : +91 79 66701800 | Fax No. : +91 79 66701843
E-mail : info@apolloahd.com | www.ahmedabad.apollohospitals.com

For Enquiry/Appointments Contact +91 76988 15003 / +91 79 66701880

Apollo Hospitals - City Centre (ગાંધીનગર)
1, Tulsibaug Society, Nr. Parimal Garden, Ahmedabad.
Phone : +91 79 66305800 / 01 or +91 76988 15148
E-mail : infoahcc@apolloahd.com

Regd. Office
19, Bishop Gardens, R.A. Puram, Chennai - 600 028
CIN No. : U85110TN1997PLC039016 | GSTin : 24AABC44150H2Z5
For online appointment : www.askapollo.com

For online appointment : www.askapollo.com
Keep the records carefully and bring them along during your next visit to our Hospital





Organization is Accredited
by Joint Commission International



RADIOLOGY

Patient Details : Mrs. MANJU SHEKHAWAT | Female | 49Yr 7Mth 1Days

UHID : AHIL.0000480233

Patient Location: AHC

Patient Identifier: AHILAH198014



DRN : 123032093

Completed on : 11-MAR-2023 11:27

Ref Doctor : DR. SHASHIKANT NIGAM

X-RAY CHEST PA

IMPRESSION

Prominent vascular markings seen.

Lung fields are otherwise clear.

Cardio thoracic ratio is normal.

Both costophrenic angles are clear.

Domes of diaphragm are well delineated.

Bony thorax shows no significant abnormality.

— END OF THE REPORT —

RAJVEERSINH P CHAVDA

Medical Officer

Printed on : 15-Mar-2023 10:22

Printed By : 153182

Reported By : 717876

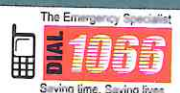Page 1 of 1

For Enquiry/Appointments Contact: +91 76988 15003 / +91 79 66701880

Apollo Hospitals International Limited
Plot No.-1A, Bhat, GIDC, Gandhinagar, Gujarat - 382428, India.
Phone : +91 79 66701800 | Fax No. : +91 79 66701843
E-mail : info@apolloahd.com | www.ahmedabad.apollohospitals.com

Apollo Hospitals - City Centre (NON NABH-JCI)
1, TulsiBaag Society, Nr. Parimal Garden, Ahmedabad.
Phone : +91 79 66305800 / 01 or +91 76988 15148
E-mail : infoahcc@apolloahd.com

Regd. Office
19, Bishop Gardens, R.A. Puram, Chennai - 600 028
CIN No. : UR5110TN199/PLC039016 | GSTIN : 24AAABCA4150H2Z5
For online appointment : www.askapollo.com



For online appointment : www.askapollo.com
Keep the records carefully and bring them along during your next visit to our Hospital


Saving time. Saving lives.



Organization is Accredited
by Joint Commission International



CARDIOLOGY

Patient Details : Mrs. MANJU SHEKHAWAT | Female | 49Yr 7Mth 1Days
UHID : AHIL.0000480233 **Patient Location:** AHC
Patient Identifier: AHILAH198014 
DRN : 5623023776 **Completed on :** 11-MAR-2023 18:20
Ref Doctor : DR. SHASHIKANT NIGAM

ECHO/TMT

FINDINGS :

Normal cardiac chamber dimensions.

Normal LV systolic function, LVEF: 60%

No Regional wall motion abnormalities at rest.

Reduced LV compliance.

All cardiac valves are structurally normal.

IAS/ IVS intact.

No MR, No AR, No PR, No TR.

No PAH.

No clots/ vegetation/ effusion.

MEASUREMENTS (mm) ::

Printed on : 15-Mar-2023 10:21

Printed By : 153182

Reported By : 1010611

Page 1 of 2

For Enquiry/Appointments Contact +91 76988 15003 / +91 79 66701880

Apollo Hospitals International Limited
 Plot No.-1A, Bhat, GIDC, Gandhinagar, Gujarat - 382429, India.
 Phone : +91 79 66701800 | Fax No. : +91 79 66701843
 E-mail : info@apolioahd.com | www.ahmedabad.apollohospitals.com

Apollo Hospitals - City Centre (NON NABH-JCI)
 1, Tulshibaug Society, Nr. Parimal Garden, Ahmedabad.
 Phone : +91 79 66305800 / 01 or +91 79388 15148
 E-mail : infoahcc@apolioahd.com

Regd. Office
 19, Bishop Gardens, R.A. Puram, Chennai - 600 028
 CIN No. : U85110TN1997PLC039016 | GSTin : 24AABCA4150H225
 For online appointment : www.askapollo.com

For online appointment : www.askapollo.com
 Keep the records carefully and bring them along during your next visit to our Hospital



Saving time. Saving lives.



Organization is Accredited
by Joint Commission International



Mrs. MANJU SHEKHAWAT

AHIL.0000480233

AHILAH198014

ECHO/TMT

	LVID diastole
Measurements (mm)	.

IMPRESSION

— END OF THE REPORT —

DR SUBIR GHOSH MD.DM

Interventional Cardiologist

Printed on : 15-Mar-2023 10:21

Printed By : 153182

Reported By : 1010611

Page 2 of 2

For Enquiry/Appointments Contact +91 76988 15003 / +91 79 66701800

Apollo Hospitals International Limited
Plot No.-1A, Bhat, GIDC, Gandhinagar, Gujarat - 382429, India.
Phone : +91 79 66701800 | Fax No. : +91 79 66701843
E-mail : info@apolloahd.com | www.ahmedabad.apollohospitals.com

Apollo Hospitals - City Centre (NON NABH-JCI)
1, TulsiBaag Society, Nr. Parnimal Garden, Ahmedabad.
Phone : +91 79 66305800 / 01 or +91 79366 15148
E-mail : infoahcc@apolloahd.com

Regd. Office
19, Bishop Gardens, R.A. Puram, Chennai - 600 028
CIN No. : U85110TN1997PLC039016 | GSTin : 24AABCA4150H225
For online appointment : www.askapollo.com

For online appointment : www.askapollo.com
Keep the records carefully and bring them along during your next visit to our Hospital



Saving time. Saving lives.



DENTISTRY

Name :	Date : <u>11/3/23</u> Unit No. :
Occupation :	Ref. Physician :
Age : Sex : <input type="checkbox"/> Male <input type="checkbox"/> Female	Copies to :

DENTAL RECORD

ALLERGIES : NAD

PAIN : Score (0-10) 0 Location : _____ Character : _____

DENTAL CLEANING HABIT

<input checked="" type="checkbox"/> Once	<input type="checkbox"/> Twice	<input type="checkbox"/> Occasionally
<input checked="" type="checkbox"/> Brush	<input type="checkbox"/> Finger	<input type="checkbox"/> Stick
<input checked="" type="checkbox"/> Tooth Paste	<input type="checkbox"/> Powder	<input type="checkbox"/> Any other
		<input type="checkbox"/> Any other

DO THE GUMS BLEED WHEN YOU BRUSH YOUR TEETH? Yes No

ARE YOUR TEETH SENSITIVE TO HEAT / COLD? Yes No

ORAL HYGIENE Good Fair Poor

ORAL TISSUE EXAMINATION	PERIODONTAL EXAMINATION	OCCLUSION
NORMAL FINDINGS IN DISEASE Lips : Cheeks : Tongue : Floor of the mouth : Palate : Tonsillar Area : Any other :	MILD MOD SEV Gingivitis <input type="checkbox"/> <input type="checkbox"/> <input type="checkbox"/> Calculus <input type="checkbox"/> <input type="checkbox"/> <input type="checkbox"/> Recession <input type="checkbox"/> <input type="checkbox"/> <input type="checkbox"/> Periodontal Pockets <input type="checkbox"/> <input type="checkbox"/> <input type="checkbox"/> Attrition <input type="checkbox"/> <input type="checkbox"/> <input type="checkbox"/> Erosion <input type="checkbox"/> <input type="checkbox"/> <input type="checkbox"/> Mobility <input type="checkbox"/> <input type="checkbox"/> <input type="checkbox"/>	CLASS I II III CROSSBITE
		Hypoplasia Impaction Non-vital Fracture Abscess Ulcers Caries Missing Teeth Supernumerary Others

PRESENT COMPLAINT :

tooth decay

PRE-MEDICAL HISTORY: DM HTN Thyroid Acidity Pregnancy
 Anticoagulant Under Drug Therapy

NAD.

Rate 81

PR 153
QRSD 103
QT 374
QTc 434

AHIL.0000480233

Mrs. MANJU
SHEKHAWAT

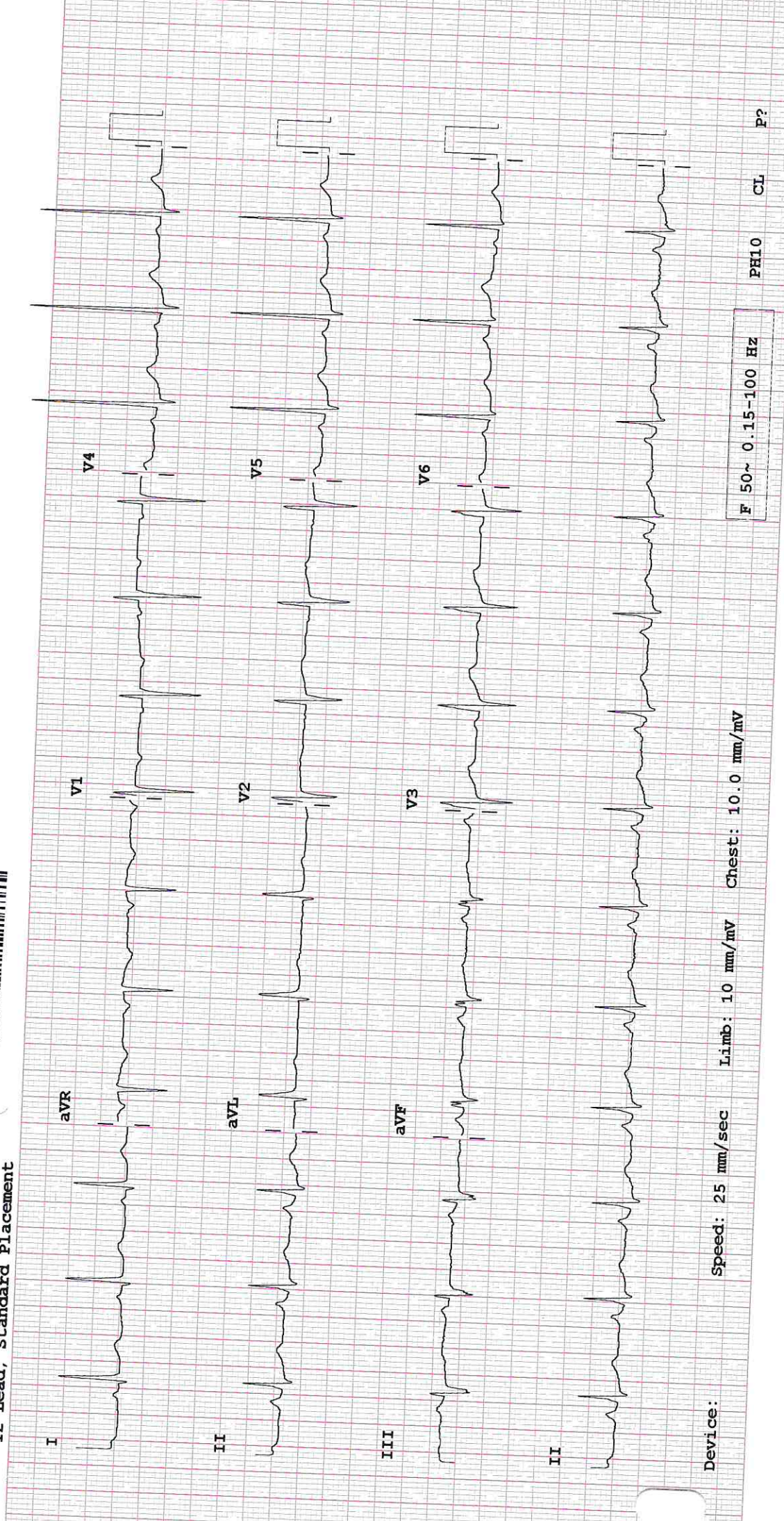
49 Year(s) / Female



--AXIS--

P 68
QRS 6
T 40

12 Lead; Standard Placement



Device: Speed: 25 mm/sec Limb: 10 mm/mV Chest: 10.0 mm/mV

F 50~ 0.15-100 HZ

PH10 CL P?

OPTH

AHIL.0000480233

EXAMINATION RECORDS

Name :

Mrs. MANJU
SHEKHAWAT

UHID :

49 Year(s) / Female

Date :

11/3/23



Distance Vision :

Right Eye -

6/6

Left Eye -

6/6

± glass

Near Vision :

Right Eye :

N6

Left Eye :

N6

± glass

APLN.TN - Right Eye

14

Left Eye -

15

mmHg

Both Eye - Colour Vision

CONL

Both Eye - Anterior Segment Examinations -

NAD

Both Eye Posterior Segment Examinations -

NAD


Doctor's Signature

Ophthalmologist Name