

MYSORE-BALLAL CIRCLE



--- A MEDALL COMPANY ---

CUSTOMER CHECKLIST

Date 25-Feb-2023 7:49 AM

Customer Name : MRS.VISHALAKSHI, A

DOB : 15 Jun 1976

Ref Dr Name : MediWheel

Age : 46Y/FEMALE

Customer Id : MED111517834



Visit ID : 712306228

MED111517834

Email Id :

Phone No : 9451116850

Corp Name : MediWheel

Address :

Package Name : Mediwheel Full Body Health Checkup Female Above 40

S.No	Modality	Study	Accession No	Time	Seq	Signature
1	LAB	BLOOD UREA NITROGEN (BUN)				
2	LAB	GLUCOSE - FASTING				
3	LAB	GLUCOSE - POSTPRANDIAL (2 HRS)				
4	LAB	GLYCOSYLATED HAEMOGLOBIN (HbA1c)				
5	LAB	LIPID PROFILE				
6	LAB	LIVER FUNCTION TEST (LFT)				
7	LAB	URIC ACID				
8	LAB	URINE GLUCOSE - FASTING				
9	LAB	URINE GLUCOSE - POSTPRANDIAL (2 Hrs)				
10	LAB	COMPLETE BLOOD COUNT WITH ESR				

		THYROID PROFILE/ TFT (T3, T4, TSH)				
	LAB	STOOL ANALYSIS - ROUTINE				
13	LAB	URINE ROUTINE				
14	LAB	PAP SMEAR BY LBC (LIQUID BASED CYTOLOGY)	<i>Done 2nd</i>			
15	LAB	CREATININE				
16	LAB	BUN/CREATININE RATIO				
17	LAB	BLOOD GROUP & RH TYPE (Forward Reverse)				
18	OTHERS	physical examination	MYS2768358102651			
19	US	ULTRASOUND ABDOMEN	MYS2768358103462			
20	MAMMOGRAPHY	MAMMOGRAPHY-BOTH BREASTS	MYS2768358116678			
21	OTHERS	Treadmill / 2D Echo	MYS2768358127528			<i>4:30 pm</i>
22	OTHERS	Gynaecologist consultation	MYS2768358128083			
23	OTHERS	Dental Consultation	MYS2768358134969			
24	OTHERS	EYE CHECKUP	MYS2768358135592			<i>Nelkote elhem hospital</i>
25	X-RAY	X RAY CHEST	MYS2768358145199			
26	OTHERS	Consultation Physician	MYS2768358148004			<i>1 floor</i>
27	ECHO	ELECTROCARDIOGRAM ECG	MYS2768358149333			

H - 125 cm

wt - 58 kg

Bp - 120/80

pulse - 73

temp - 40.2

wau - 39 in

Registered By

(A.JAYASHREE)



NETHRADHAMA SUPER SPECIALITY EYE HOSPITAL

(A Unit of Nethradhama Hospitals Pvt. Ltd.)

OPD SHEET

Date : 25/02/2023

Patient's Name : Mrs. U. S. halalash, A

OP No. 1234434

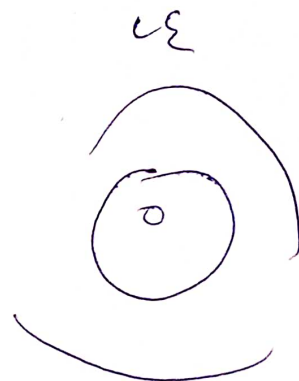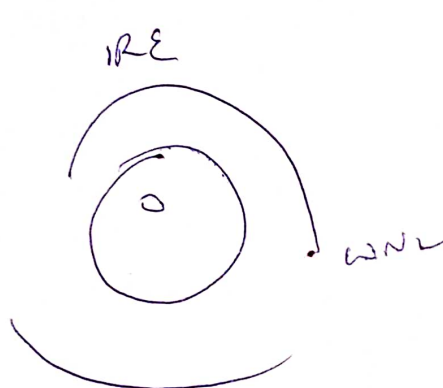
Hb/P

2:00 PM

for medical checkup

Dr. Priya. D
M.B.B.S, MS
Consultant Glaucoma & Cataract
KMC No. 88421

O/E BCVA (BE) 6/6, 26



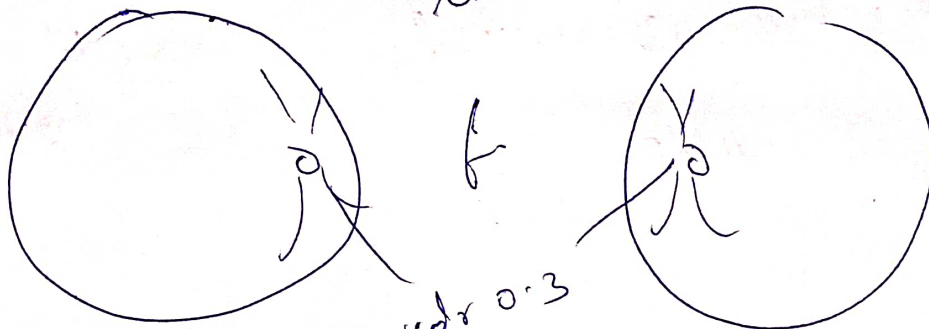
IOPT (NCT) 20 / 17

Colour vision (Ischi) (Ischi)

(BE) 30/38

Fundus

retina



lyg

(BE)

presbyopia

Ad: glasses

RIA lgn 1505

Pr ip

(Dr P-22)

25/2/23

3:10 PM

1mc 84221

Customer Name	MRS.VISHALAKSHI A	Customer ID	MED111517834
Age & Gender	46Y/FEMALE	Visit Date	25/02/2023
Ref Doctor	MediWheel		

2 D ECHOCARDIOGRAPHIC STUDY

M mode measurement:

AORTA	:	2.9cms
LEFT ATRIUM	:	3.0cms
LEFT VENTRICLE (DIASTOLE)	:	4.7cms
(SYSTOLE)	:	2.8cms
VENTRICULAR SEPTUM (DIASTOLE)	:	0.9cms
(SYSTOLE)	:	1.1cms
POSTERIOR WALL (DIASTOLE)	:	0.9cms
(SYSTOLE)	:	1.1cms
EDV	:	81ml
ESV	:	31ml
FRACTIONAL SHORTENING	:	37%
EJECTION FRACTION	:	62%
RVID	:	1.3cms

DOPPLER MEASUREMENTS:

MITRAL VALVE	:	'E' - 0.77m/s	'A' - 0.45 m/s	NO MR
AORTIC VALVE	:	0.98m/s		NO AR
TRICUSPID VALVE	:	'E' - 0.77m/s	'A' - 0.26 m/s	NO TR
PULMONARY VALVE	:	0.77m/s		NO PR



Time of sample
should be correlated
with date solely for
reference

Customer Name	MRS.VISHALAKSHI A	Customer ID	MED111517834
Age & Gender	46Y/FEMALE	Visit Date	25/02/2023
Ref Doctor	MediWheel		

2D ECHOCARDIOGRAPHY FINDINGS:

Left ventricle : Normal size, Normal systolic function.
No regional wall motion abnormalities.

Left Atrium : Normal.

Right Ventricle : Normal.

Right Atrium : Normal.

Mitral valve : Normal, No mitral valve prolapse.

Aortic valve : Normal, Trileaflet.

Tricuspid valve : Normal.

Pulmonary valve : Normal.

IAS : Intact.

IVS : Intact.

Pericardium : No pericardial effusion.

IMPRESSION:

- NORMAL SIZED CARDIAC CHAMBERS.
- NORMAL LV SYSTOLIC FUNCTION. EF:62 %.
- NO REGIONAL WALL MOTION ABNORMALITIES.
- NORMAL VALVES.
- NO CLOTS/ PERICARDIAL EFFUSION VEGETATION.



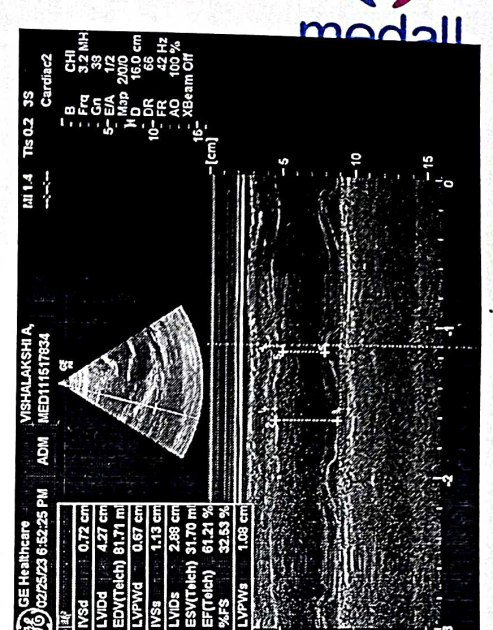
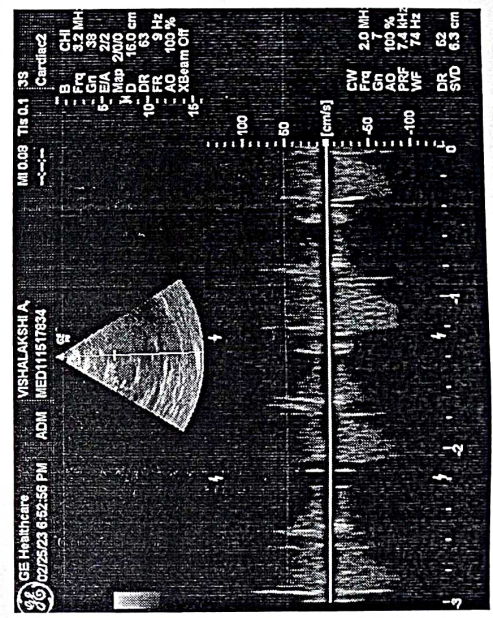
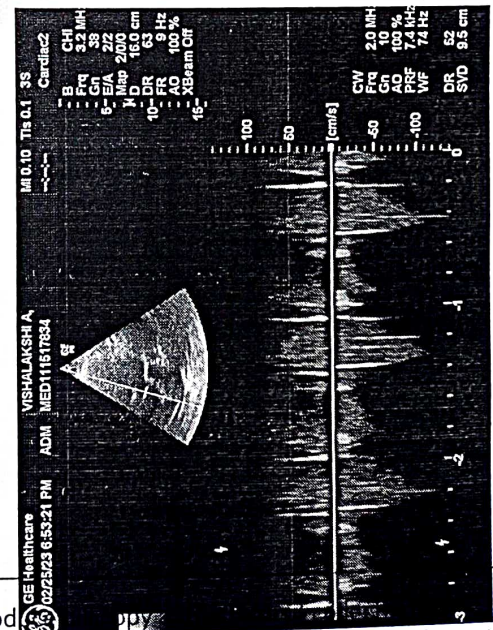
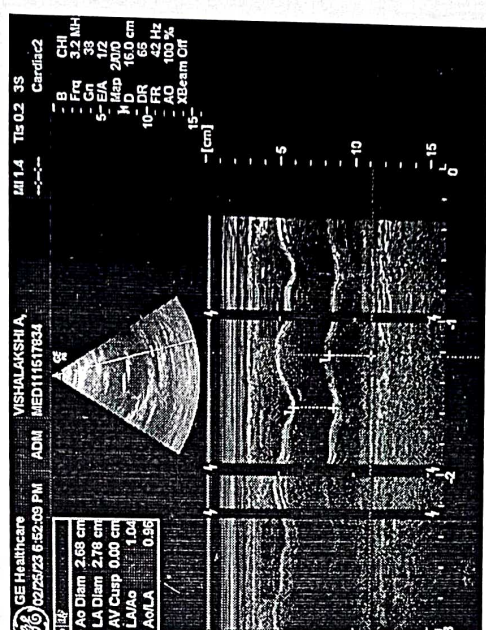
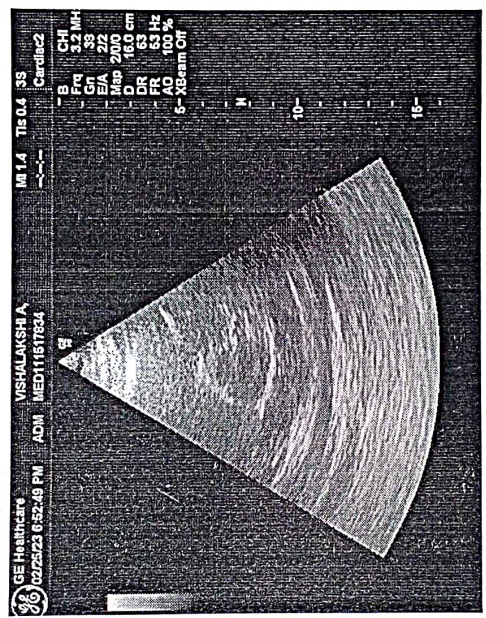
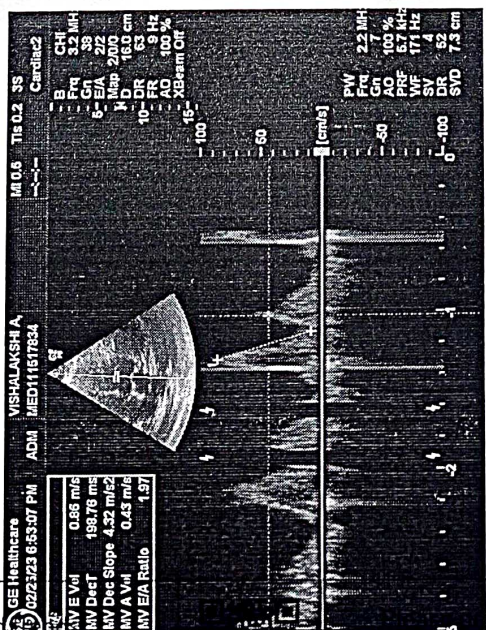
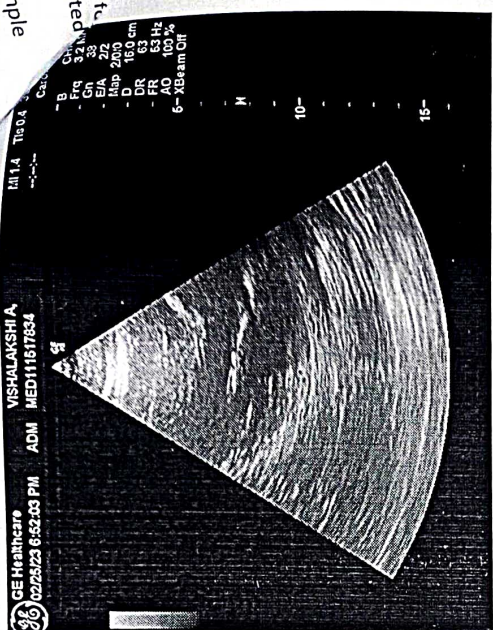
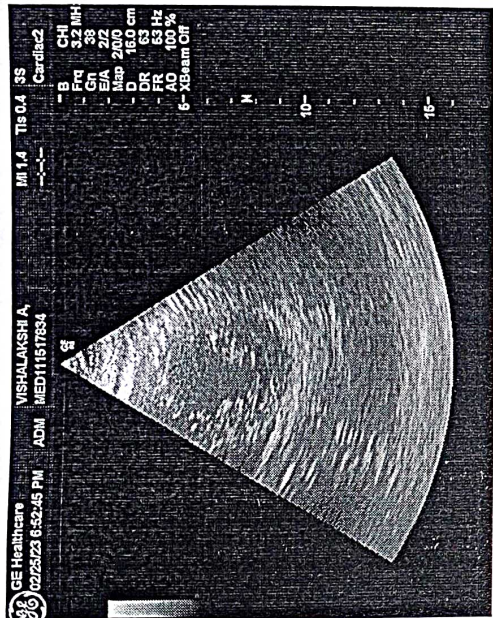
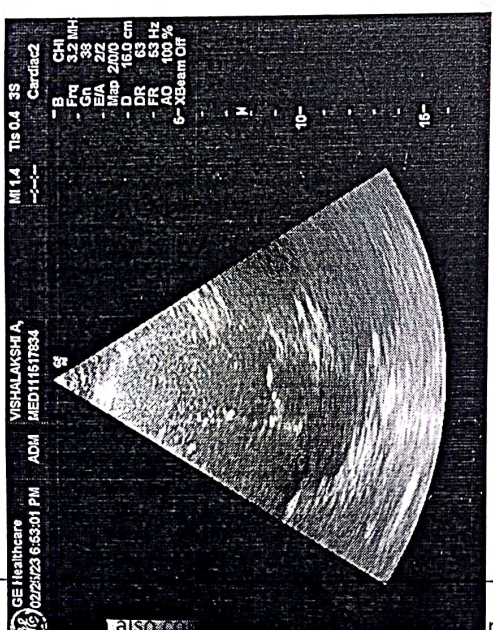
DR. NIKHIL B
INTERVENTIONAL CARDIOLOGIST
NB/SA

You can also conveniently view the reports and trends through our App. Scan QR code to download the App.



Please produce bill copy at the time of collecting the reports. Request you to provide your mobile number or customer id during your subsequent visits.

Time of sample and shall not be correlated.



through our App. Scan QR code to download the App.



reports. Request you to provide your mobile number or customer id during your subsequent visits.



Customer Name	MRS.VISHALAKSHI A	Customer ID	MED111517834
Age & Gender	46Y/FEMALE	Visit Date	25/02/2023
Ref Doctor	MediWheel		

X-ray mammogram (mediolateral oblique and craniocaudal views) followed by Sonomammography was performed.

BILATERAL MAMMOGRAPHY

Bilateral breasts show symmetrical fibroglandular fatty tissue.

No evidence of focal soft tissue lesion.

No evidence of cluster microcalcification.

Subcutaneous fat deposition is within normal limits.

BILATERAL SONOMAMMOGRAPHY

Both the breasts show normal echopattern.

No evidence of focal solid / cystic areas.

No evidence of ductal dilatation.

No evidence of axillary lymphadenopathy on both sides.

IMPRESSION:

➤ **ESSENTIALLY NORMAL STUDY.**

ASSESSMENT: BI-RADS CATEGORY - 1

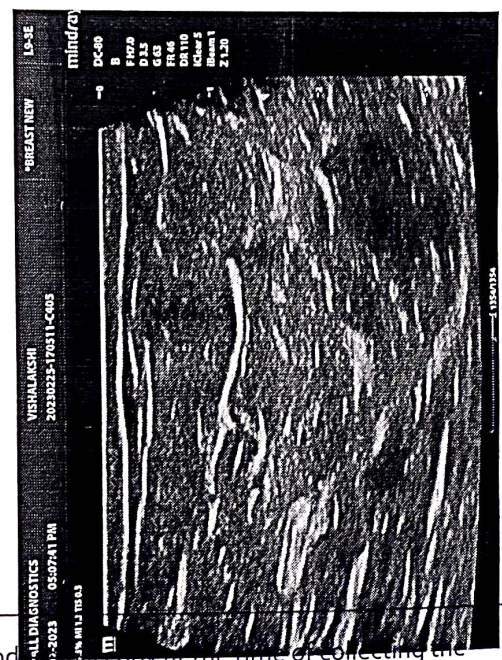
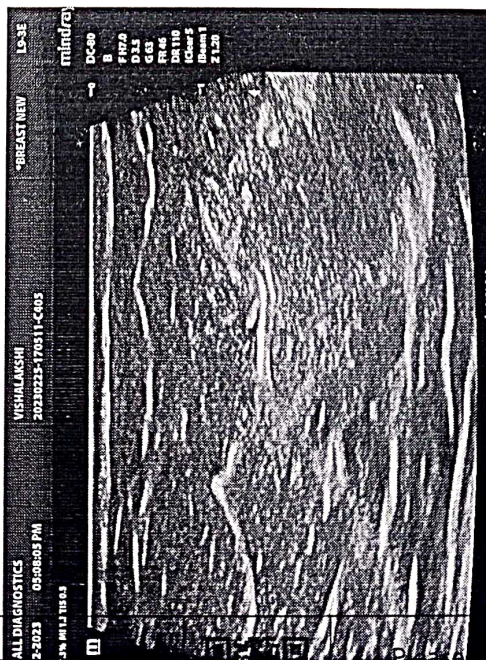
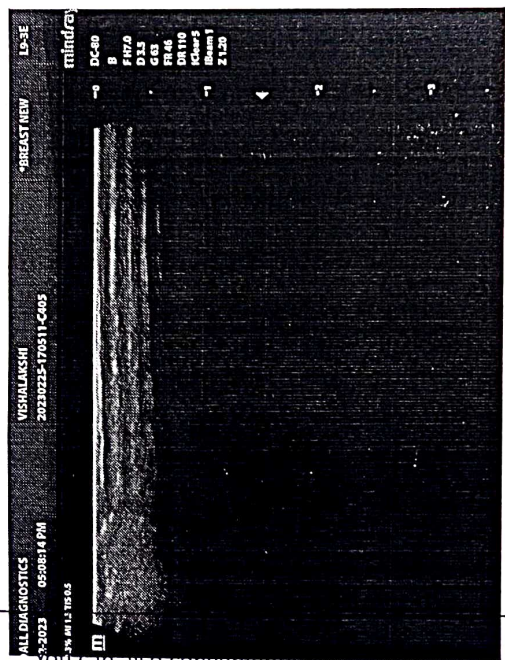
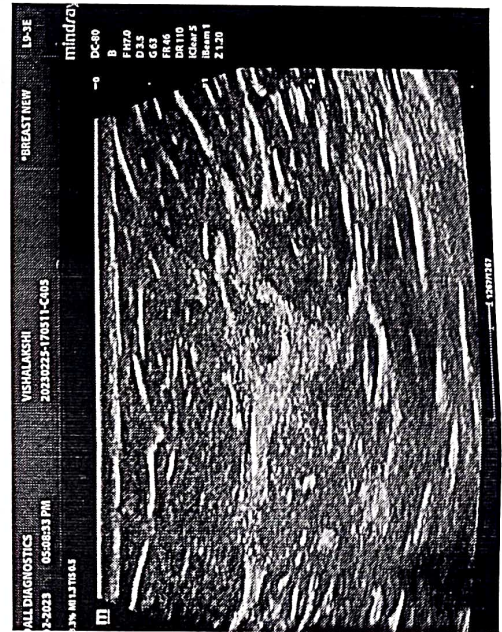
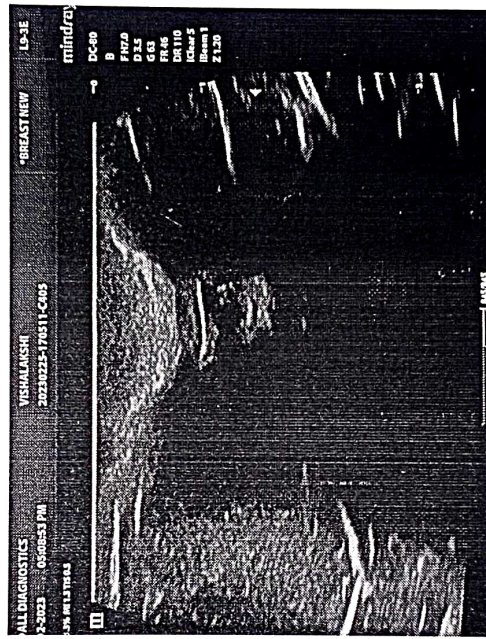
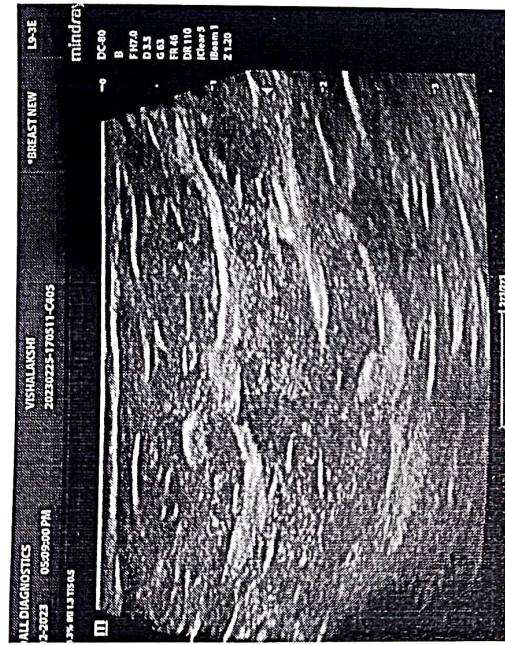
1 Negative. Routine mammogram in 1 year recommended.



DR. ANITHA ADARSH
CONSULTANT RADIOLOGIST
 AA/mm



Indicate, I should be...
 the time of sample...
 re and shall not be...
 or named.
 3 placed.



You can also conveniently view the reports and trends through our App. Scan QR code to download the App.



Please provide a soft copy at the time of collecting the reports. Request you to provide your mobile number or customer id during your subsequent visits.

Customer Name	MRS.VISHALAKSHI A	Customer ID	MED111517834
Age & Gender	46Y/FEMALE	Visit Date	25/02/2023
Ref Doctor	MediWheel		

ABDOMINO-PELVIC ULTRASONOGRAPHY

LIVER is normal in shape, size and has uniform echopattern.
No evidence of focal lesion or intrahepatic biliary ductal dilatation.
Hepatic and portal vein radicals are normal.

GALL BLADDER is contracted. Few calculi are noted within measuring 5-6mm each.

PANCREAS has normal shape, size and uniform echopattern.
No evidence of ductal dilatation or calcification.

SPLEEN show normal shape, size and echopattern.

KIDNEYS move well with respiration and have normal shape, size and echopattern.
Cortico- medullary differentiations are well madeout.
No evidence of calculus or hydronephrosis.

	Bipolar length (cms)	Parenchymal thickness (cms)
Right Kidney	9.6	1.8
Left Kidney	9.1	1.5

URINARY BLADDER show normal shape and wall thickness.
It has clear contents.

UTERUS is anteverted and has normal shape and size. It has uniform myometrial echopattern.
Endometrial echo is of normal thickness 6 mms.
Uterus measures as follows: LS: 6.1cms AP: 3.3cms TS: 4.3cms.

OVARIES are normal size, shape and echotexture.

Right ovary measures: 2.2 x 1.6cms

Left ovary measures: 2.0 x 1.5cms

POD & adnexa are free.

No evidence of ascites.

Divarication of recti noted.

IMPRESSION:

➤ **CONTRACTED GALL BLADDER WITH CHOLELITHIASIS.**

CONSULTANT RADIOLOGISTS

DR. ANITHA ADARSH
MB//MS



DR. MOHAN B

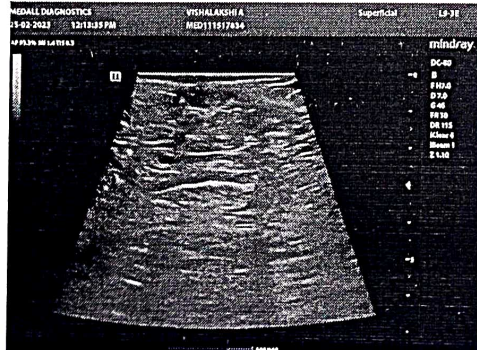
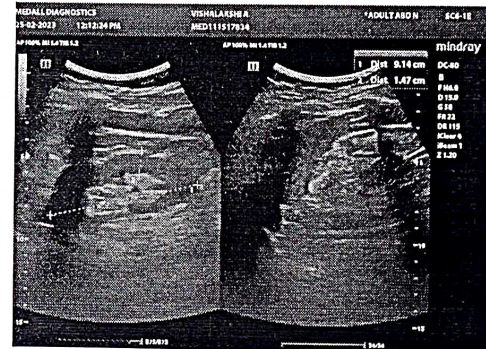
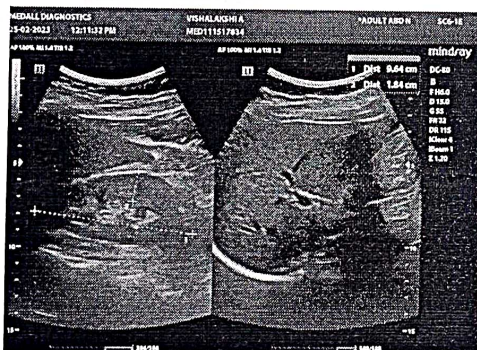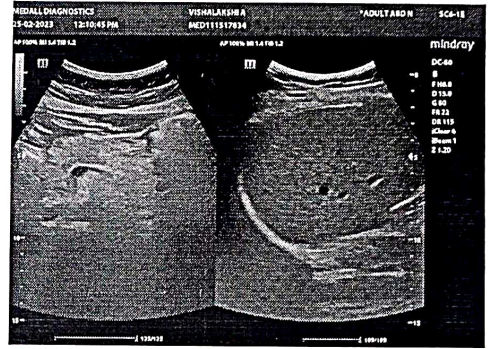
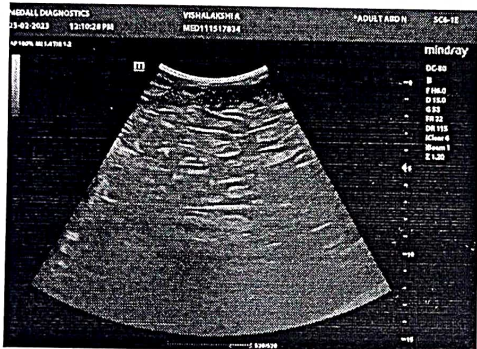
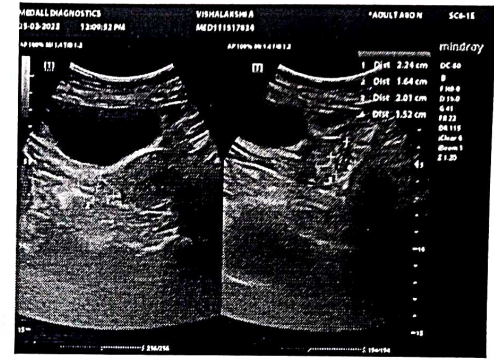
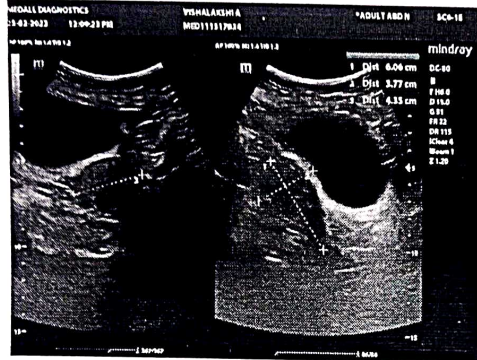


condition at the time of sample representative and shall not be attributed or named.

Medall Diagnostics
Ballal Circle(Ashoka circle) - Mysore



Customer Name	MRS.VISHALAKSHI A	Customer ID	MEDI11517834
Age & Gender	46Y/FEMALE	Visit Date	25/02/2023
Ref Doctor	MediWheel		



GE Healthcare REF: 1019728151

You can also conveniently view the reports and trends through our App. Scan QR code to download the App.

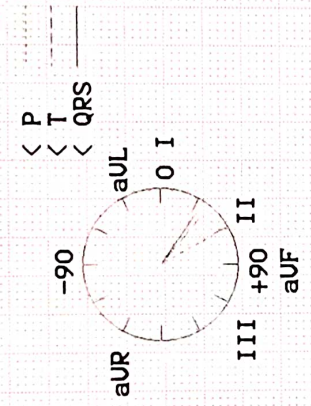


Please produce bill copy at the time of collecting the reports. Request you to provide your mobile number or customer id during your subsequent visits.

GE MAC1200 ST MRS VISHALAKSHI A, 111517834, CLUMAX DIAGNOSTICS, MYSORE

HR 73 bpm

AGE: 46
Measurement Results:
QRS : 390 /
QT/QTcB : 80 ms / 434 ms
PR : 118 ms
P : 90 ms
RR/PP : 808 / 805 ms
P/QRS/T : 60 / 35 / 40 degrees
QTd/QTcBD: 46 / 51 ms
Sokolow : 2.1 mV
NK : 10

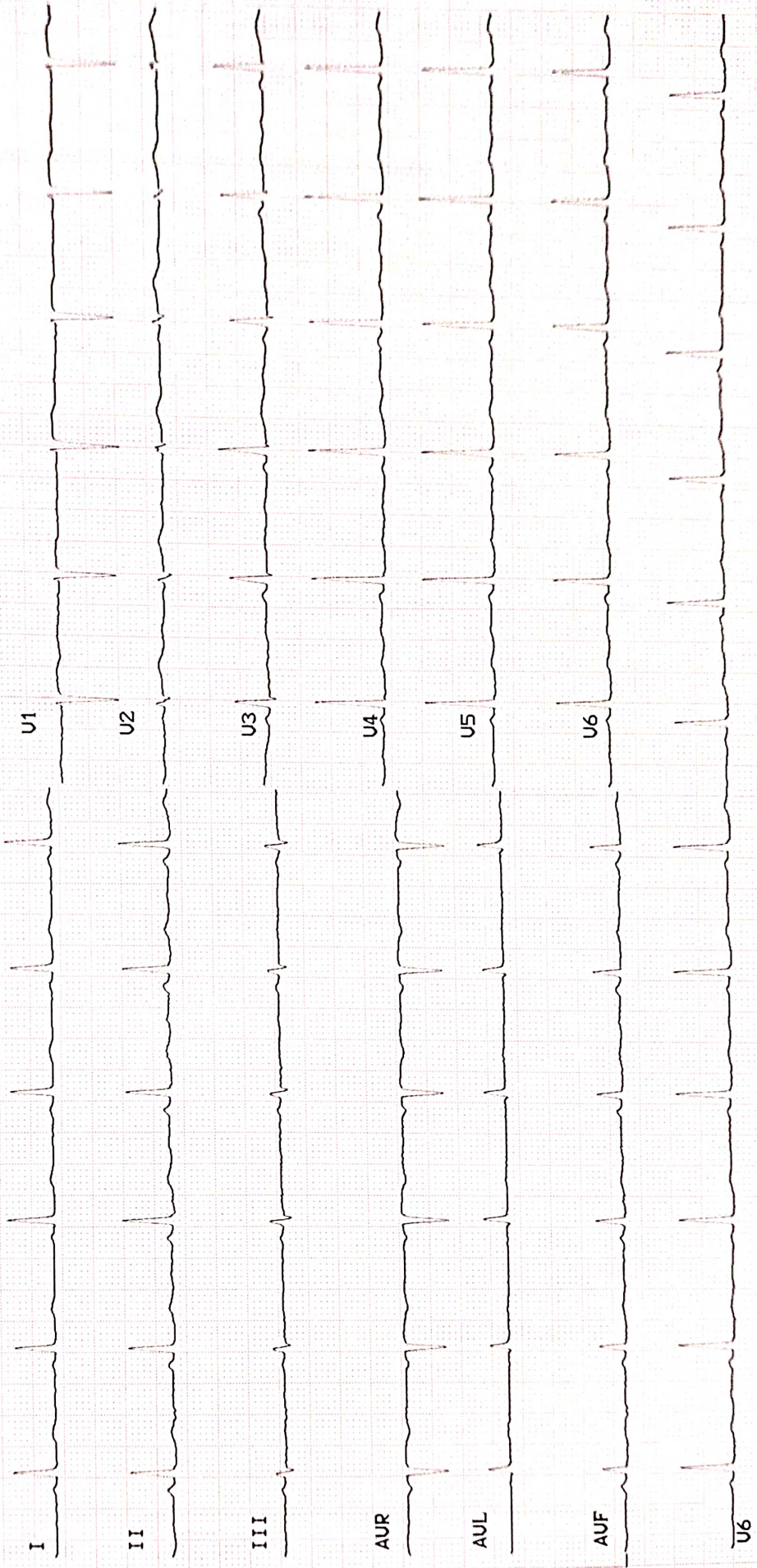


Interpretation:

short PR interval
small positive T wave (anterior)
R/S inversion area between U1 and U2
borderline ECG

Normal sinus rhythm
BB

Unconfirmed report.



Customer Name	MRS.VISHALAKSHI A	Customer ID	MEDI11517834
Age & Gender	46Y/FEMALE	Visit Date	25/02/2023
Ref Doctor	MediWheel		

ABDOMINO-PELVIC ULTRASONOGRAPHY

LIVER is normal in shape, size and has uniform echopattern.
No evidence of focal lesion or intrahepatic biliary ductal dilatation.
Hepatic and portal vein radicals are normal.

GALL BLADDER is not visualised - contracted.

PANCREAS has normal shape, size and uniform echopattern.
No evidence of ductal dilatation or calcification.

SPLEEN show normal shape, size and echopattern.

KIDNEYS move well with respiration and have normal shape, size and echopattern.
Cortico- medullary differentiations are well madeout.
No evidence of calculus or hydronephrosis.

	Bipolar length (cms)	Parenchymal thickness (cms)
Right Kidney	9.6	1.8
Left Kidney	9.1	1.5

URINARY BLADDER show normal shape and wall thickness.
It has clear contents.

UTERUS is anteverted and has normal shape and size. It has uniform myometrial echopattern.
Endometrial echo is of normal thickness 6 mms.
Uterus measures as follows: LS: 6.1cms AP: 3.3cms TS: 4.3cms.

OVARIES are normal size, shape and echotexture.

Right ovary measures: 2.2 x 1.6cms

Left ovary measures: 2.0 x 1.5cms

POD & adnexa are free.

No evidence of ascites.

Divarication of recti noted.

IMPRESSION:

➤ **NO SIGNIFICANT ABNORMALITY DETECTED.**

CONSULTANT RADIOLOGISTS

DR. ANITHA ADARSH
MB//MS

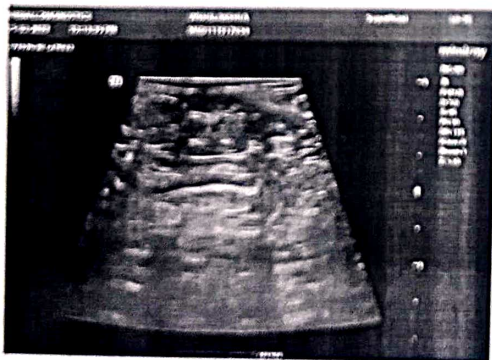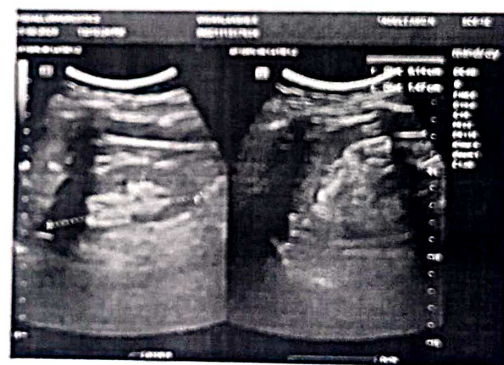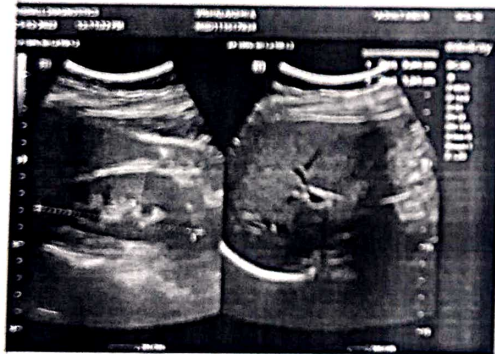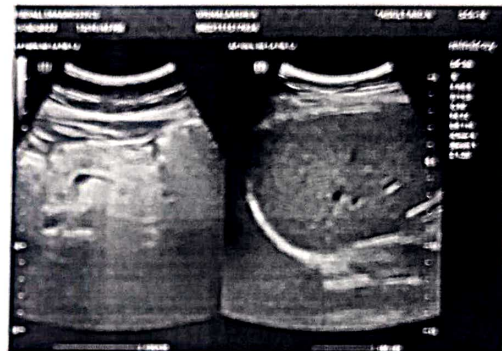
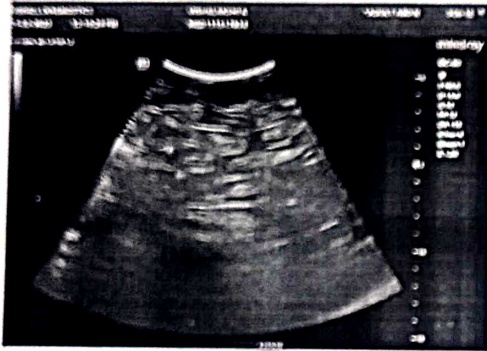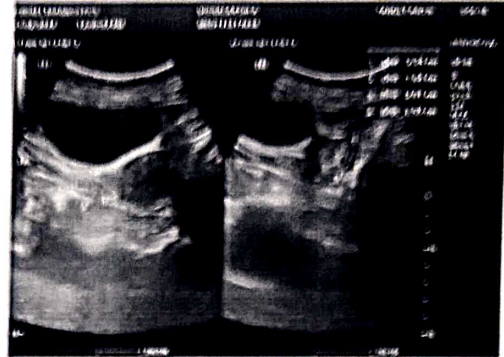
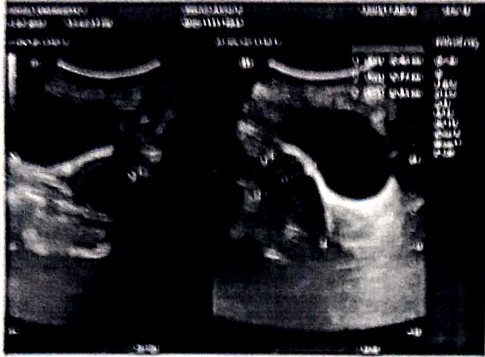


DR. MOHAN B



Indicated area is shown
and should be consistent
at the time of sampling
and should be consistent

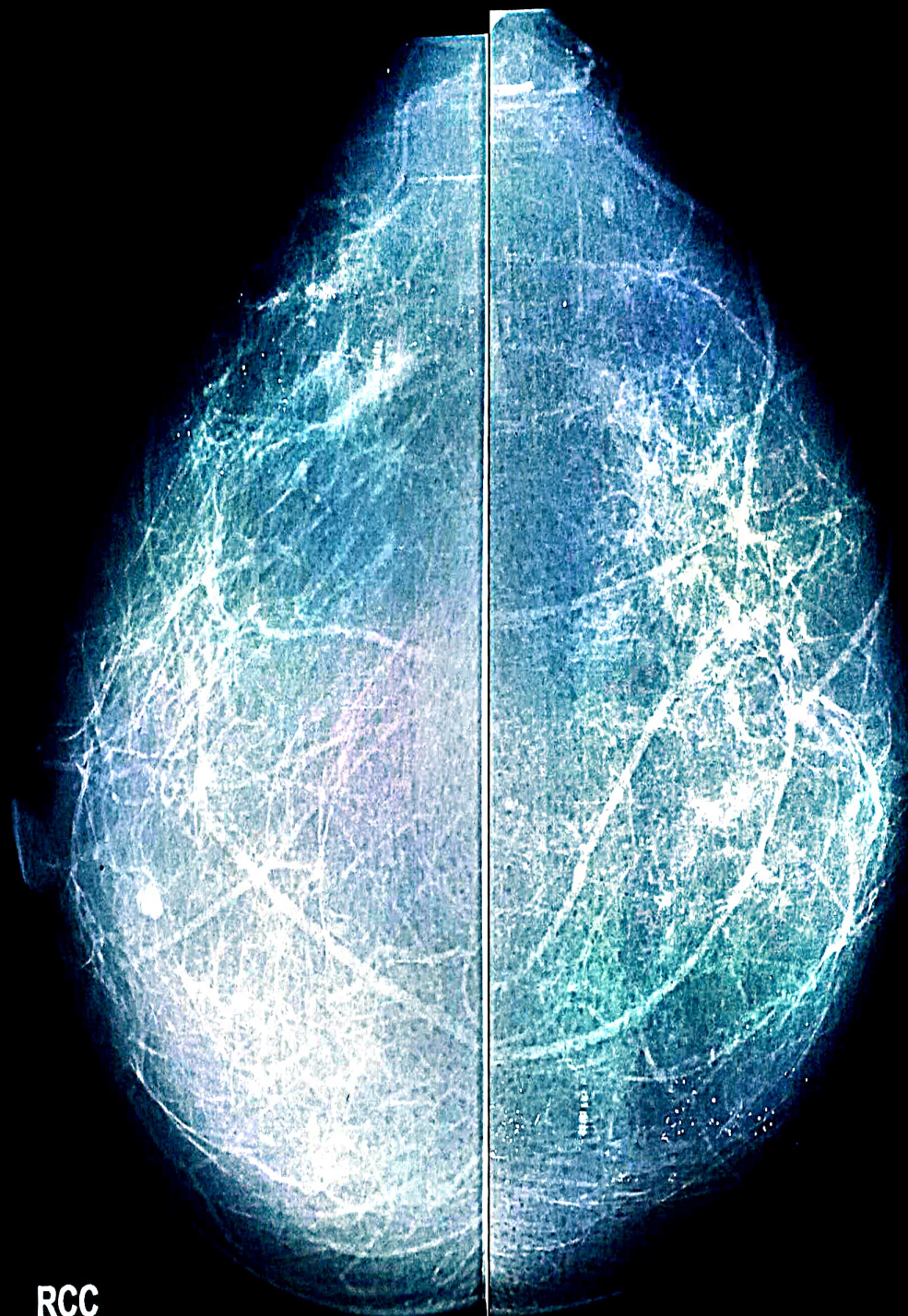
Customer Name	MRS. VISHALAKSHI A	Customer ID	MED11517834
Age & Gender	45Y/FEMALE	Visit Date	25/02/2023
Ref Doctor	MediWheel		



You can also conveniently view the reports and trends through our App. Scan QR code to download the App.



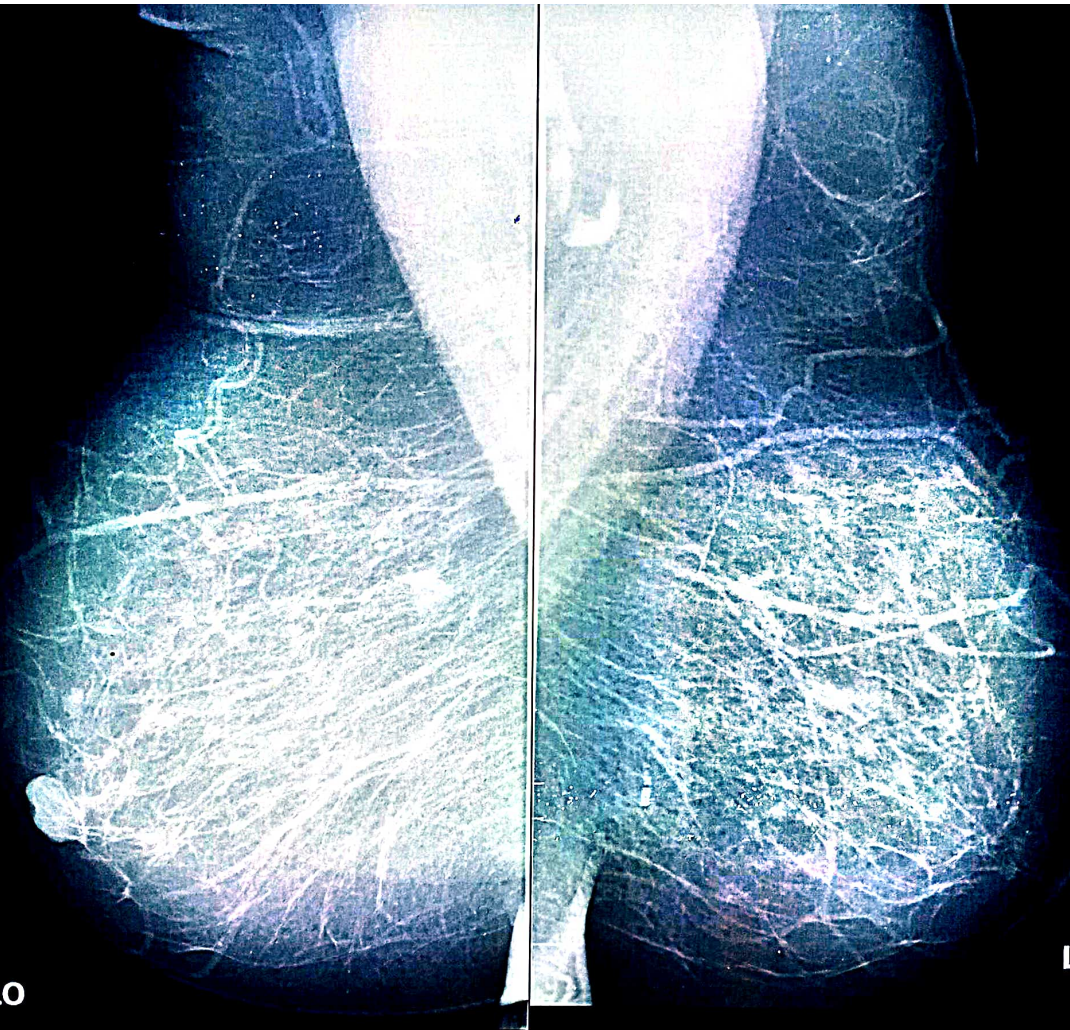
Please produce bill copy at the time of collecting the reports. Request you to provide your mobile number or customer id during your subsequent visits.



RCC

LCC

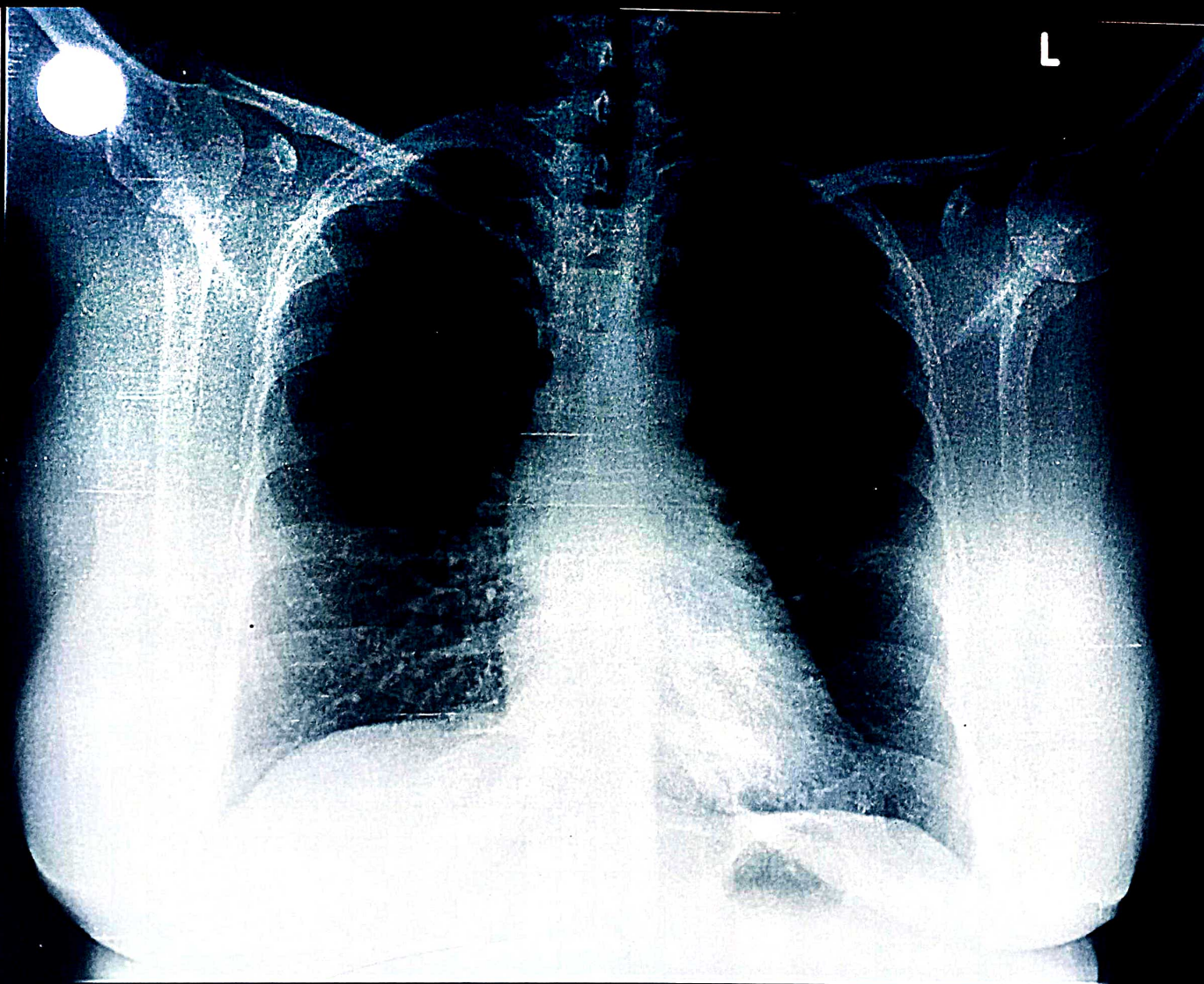
VISHALAKSHI A 46 MED111517834 F L & R MAMMOGRAPHY, CC 2/25/2023
MEDALL CLUMAX DIAGNOSTIC



RMLO

LMLO

VISHALAKSHI A 46 MED111517834 F L & R MAMMOGRAPHY, MLO 2/25/2023
MEDALL CLUMAX DIAGNOSTIC



VISHALAKSHI A 46 MED111517834 F CHEST PA 2/25/2023 10:31 AM
MEDALL CLUMAX DIAGNOSTIC