

Aadhaar - Aam Aadmi ka Adhikar

पता
W/O आनंद जग्गा B-3/2
सैक्टर-16 रोहिणी, रोहिणी
सैक्टर 14, रोहिणी भारत का
दिल्ली, 110089

UNIQUE IDENTIFICATION AUTHORITY OF INDIA
भारतीय पहचान प्राधिकार



[Handwritten signature]

भारत सरकार

GOVERNMENT OF INDIA



नीती जग्गा
Niti Jyoga
जन्म वर्ष/YoB: 1986
महिला / female


[Handwritten signature]
Dr. NITIN AGARWAL
MBBS, MD
Regn. No. DMC-R-1436

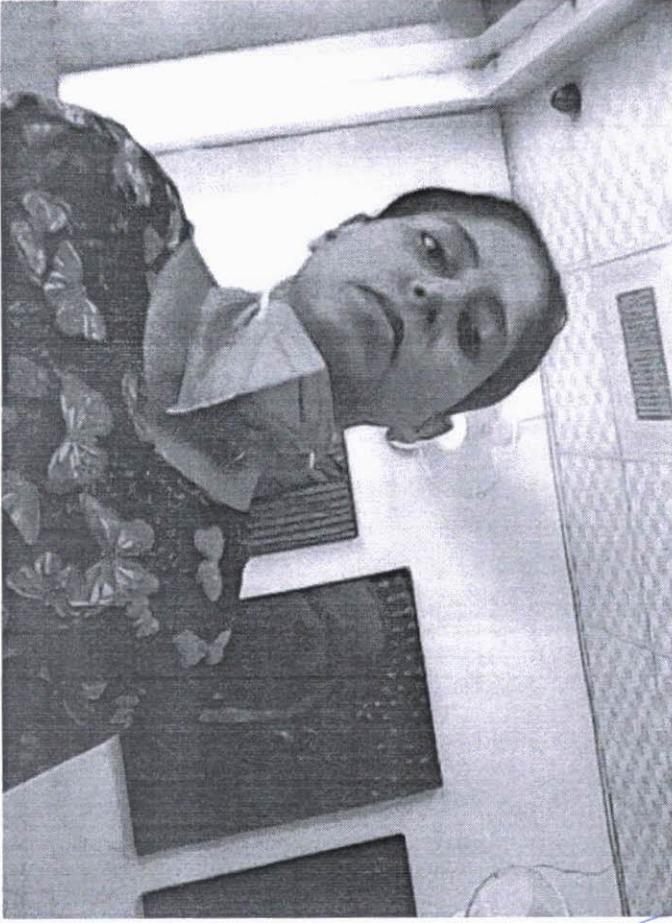


7120 8872 2341

आधार - आम आदमी का अधिकार

ONEPLUS ULTRASOUND LAB
47, Harsh Vihar, Pitam Pura,
Delhi-110034
Ph. 011-42480101, 9599913051
E-mail: oneplusul@gmail.com





Dr. NITIN AGARWAL
MBBS, MD
Regn. No. DMC-R-1436



ONEPLUS ULTRASOUND LAB
47, Harsh Vihar, Pitam Pura,
Delhi-110034
Ph. 011-42480101, 9599913051
E-mail: oneplusul@gmail.com

I, Niti Jagga. has come for full body health
check up.

But, I am not willing for stool sample &
blood sample - 11.

Kindly consider.

Niti Jagga

NITI JAGGA

Ph No- 2076392 443

Doc - 13/3/2022



Dr. NITIN AGARWAL
MBBS, MD
Regn. No. DMC-R-1436

ONEPLUS ULTRASOUND LAB
47, Harsh Vihar, Pitam Pura,
Delhi-110034
Ph. 011-42480101, 9599913051
E-mail: oneplusul@gmail.com

ONEPLUS ULTRASOUND LAB

47, HARSH VIHAR, PITAMPURA, DELHI- 110034

Ms. NITI JAGGA
 Age : 35/F
 Ref. by : MEDIWHEEL
 Indication1 :
 Indication2 :
 Indication3 :
 COMMENTS :

ID : 1913
 HMM : 158/66
 Recorded : 13-3-2022 11:24
 Medication1 :
 Medication2 :
 Medication3 :

N.J.

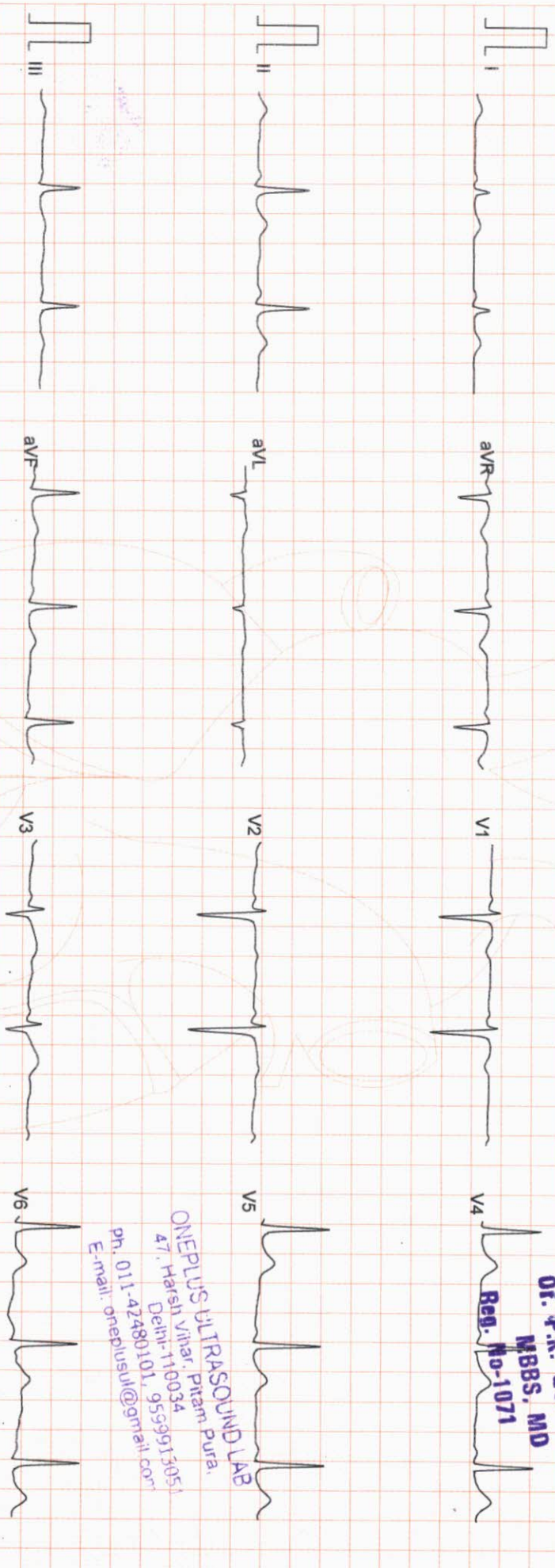
BPM : 79
 BP : 114/70
 P Axis : 67 deg
 QRS Axis : 76 deg
 T Axis : 49 deg

P duration : 93 msec
 PR duration : 106 msec
 QRS duration : 106 msec
 QT Interval : 340 msec
 QTc Interval : 373 msec

Unconfirmed Report Reviewed By:
 Cardiologist

[Signature]

DR. P.K. GUPTA
MBBS, MD
 Reg. No-1071



ONEPLUS ULTRASOUND LAB
 47, Harsh Vihar, Pitam pura,
 Delhi-110034
 Ph. 011-42480101, 9599915051
 E-mail: oneplusul@gmail.com

Filtered

25mm/sec 10mm/mV

CardiCom, INDIA

Academy

ONEPLUS ULTRASOUND LAB

47, HARSH VIHAR PITAMPURA DELHI 110034

Ms. NITI JAGGA
Age : 35/F
Ref. by : MEDIWHEEL

ID : 984
HWT : 158/66
Recorded : 13-3-2022 11:26

TREADMILL TEST SUMMARY REPORT

Protocol: BRUCE
History:
Medication1 :
Medication2 :
Medication3 :

PHASE	PHASE TIME	STAGE TIME	SPEED (Km./Hr.)	GRADE (%)	H.R. (BPM)	B.P. (mmHg)	RPP X100	II	ST LEVEL (mm) V2	V5	METS
SUPINE STANDING					72	114/70	82	0.3	1.0	0.5	
STAGE 1	2:59	2:59	2.70	10.00	72	114/70	82	0.3	1.0	0.5	
STAGE 2	5:59	2:59	4.00	12.00	103	114/70	117	0.5	0.6	-0.4	4.80
STAGE 3	8:59	2:59	5.40	14.00	97	126/74	122	2.7	-0.2	9.9	7.10
STAGE 4	9:29	0:29	6.70	16.00	86	140/80	120	-2.4	1.1	-1.1	10.00
PEAK EXER	9:30	0:30			122	150/90	183	0.3	-0.8	-0.6	10.65
RECOVERY	2:59	2:59	0.00	0.00	124	150/90	186	0.7	-1.4	-0.8	10.67
					99	116/72	114	0.1	1.4	0.0	

RESULTS

Exercise Duration : 9:30 Minutes
Max Heart Rate : 124 bpm 67 % of target heart rate 185 bpm
Max Blood Pressure : 150/90 mmHg
Max Work Load : 10.67 METS
Reason of Termination : Tm Not achieved failure.

negative for valve

[Signature]
P.K. GUPTA
Cardiologist
Reg. No-1071

[Signature]
ONEPLUS ULTRASOUND LAB
47, Harsh Vihar, Pitam Pura,
Delhi-110034
Ph. 011-42480101, 9599913051
E-mail: oneplusul@gmail.com

Ms. NITI JAGGA
I.D. : 984
AGE/SEX : 35/F
RECORDED : 13-3-2022 11:26

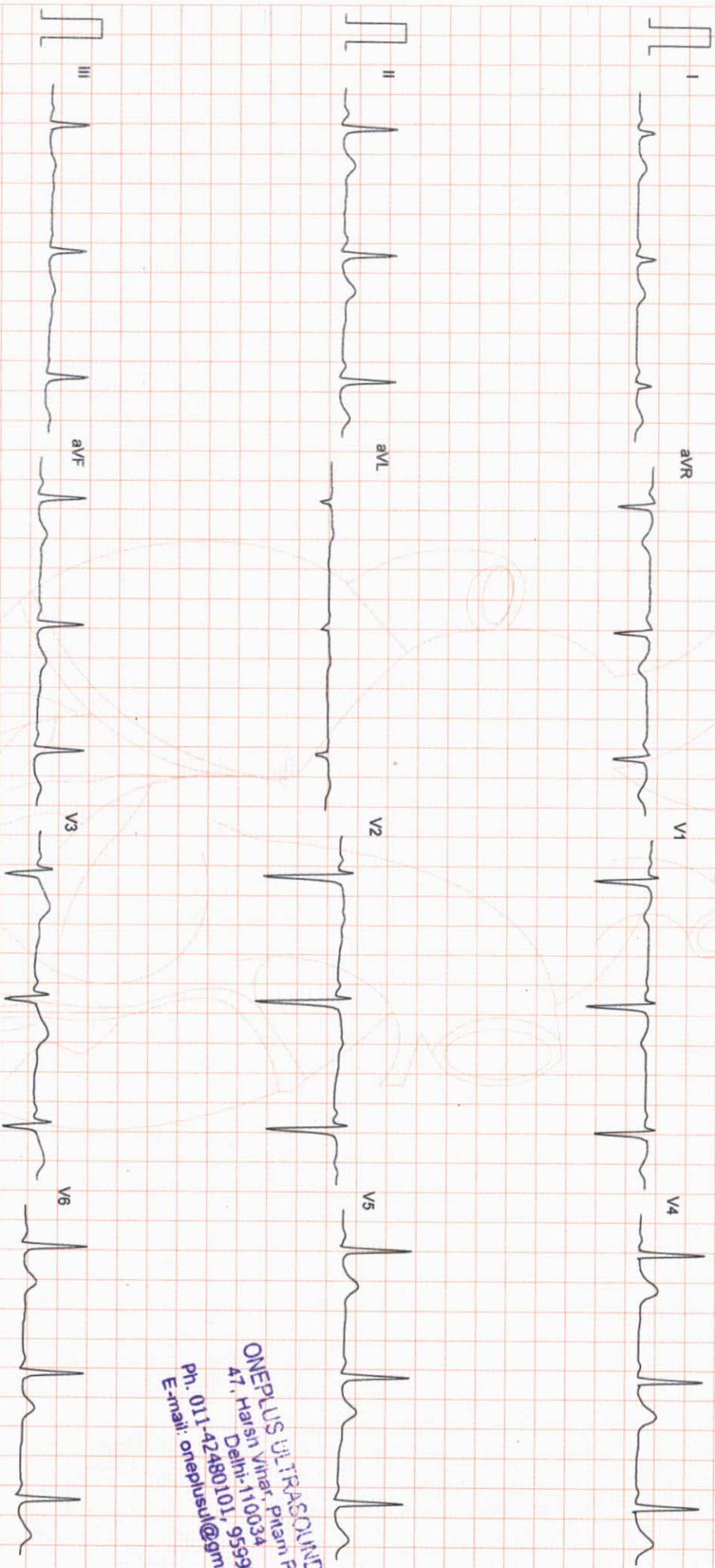
RATE : 72 BPM
B.P. : 114/70 mmHg

ONEPLUS ULTRASOUND LAB

SUPINE
PRETEST

ST @ 10mm/mV
80ms PostJ

RAW E.C.G.



ONEPLUS ULTRASOUND LAB
47, Harsi Vihar, Pitam Pura,
Delhi-110034
Ph. 011-42480101, 9559913051
E-mail: oneplusul@gmail.com

Filtered

25mm/sec 10mm/mV

ARTO

CardiCom, INDIA Ph.:091-731-2620740, Tele/Fax:091-731-2431214

ONEPLUS ULTRASOUND LAB

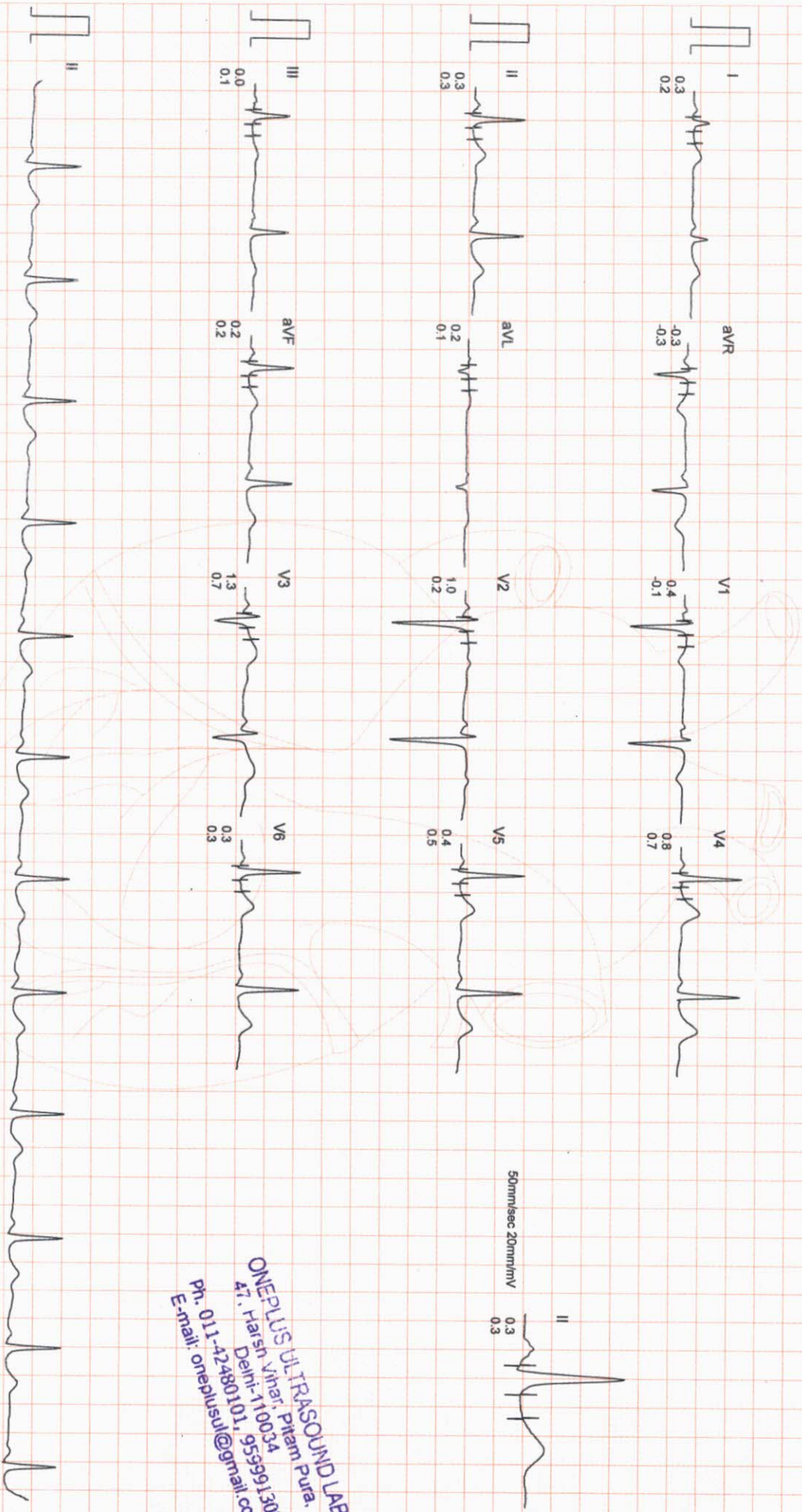
STANDING
PRETEST

ST @ 10mm/mV
80ms PostJ

Ms. NITTI JAGGA
I.D. : 984
AGE/SEX : 35/F
RECORDED : 13-3-2022 11:26

RATE : 72 BPM
B.P. : 114/70 mmHg

LINKED MEDIUM



ONEPLUS ULTRASOUND LAB
47, Harsu Nagar, Pitam Pura,
Delhi-110034
Ph. 011-42480101, 65556613051
E-mail: onepusul@gmail.com

ONEPLUS ULTRASOUND LAB

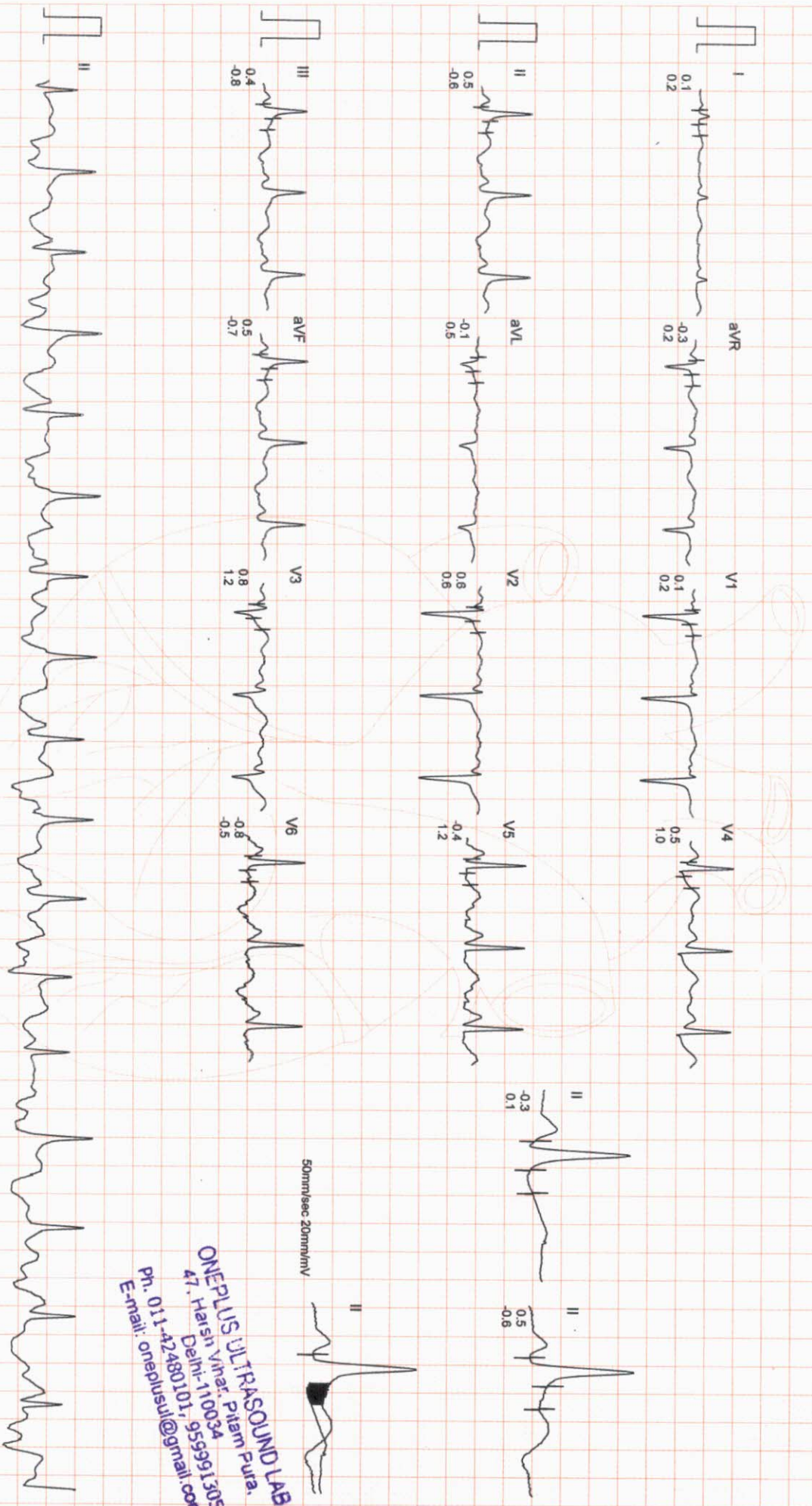
MS. NITI JAGGA
ID : 984
AGE/SEX : 35/F
RECORDED : 13-3-2022 11:26

RATE : 103 BPM
B.P. : 114/70 mmHg

BRUCE
EXERCISE 1
PHASE TIME : 2:59
STAGE TIME : 2:59

ST @ 10mm/mV
80ms PostJ
SPEED : 2.7 Km./Hr.
GRADE : 10.0 %

LINKED MEDIAN



ONEPLUS ULTRASOUND LAB
47, Hansi Vihar, Pitam Pura,
Delhi-110034
Ph. 011-42480101, 95599913051
E-mail: oneplusultrasound@gmail.com

ONEPLUS ULTRASOUND LAB

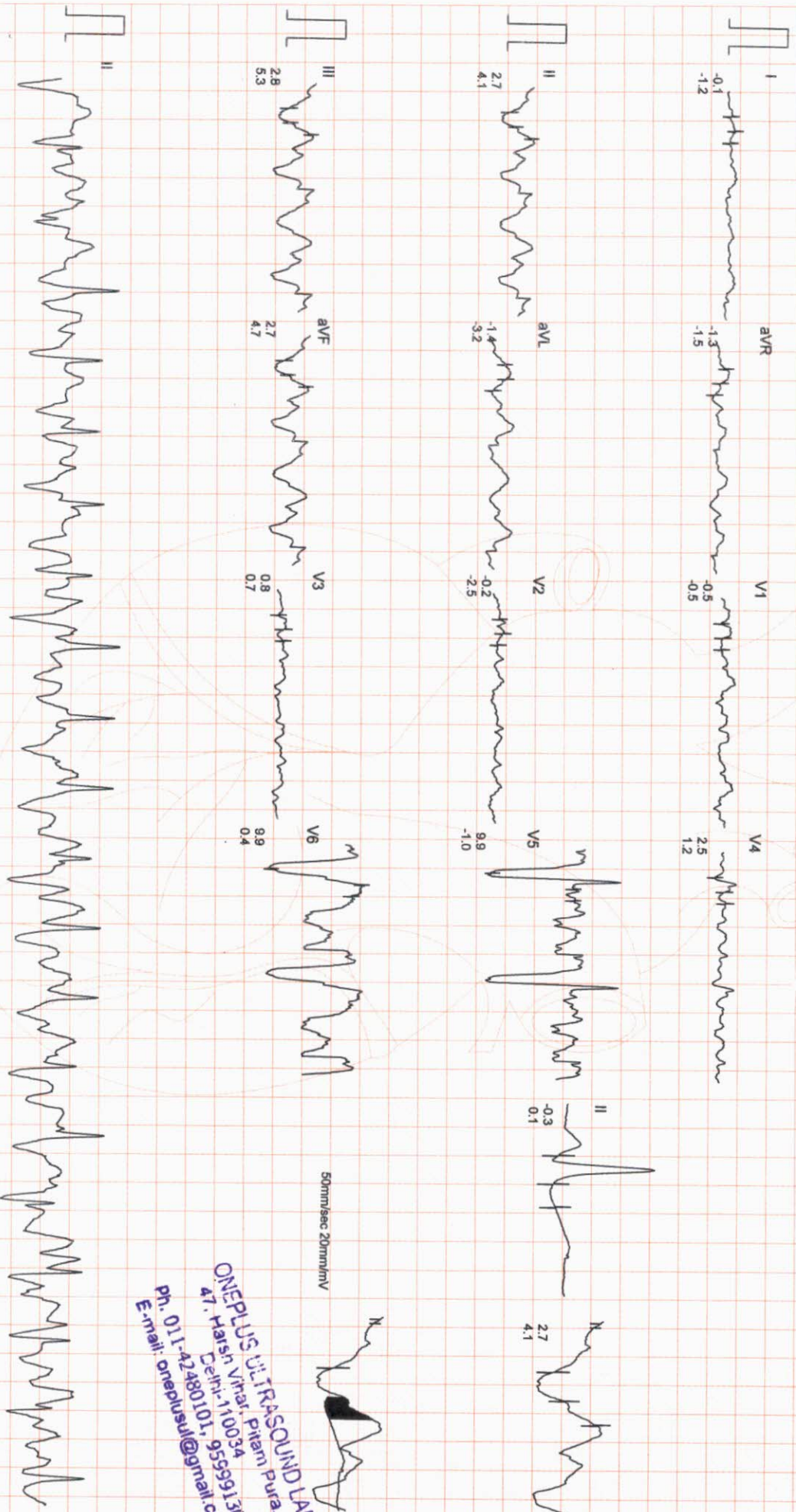
Ms. NITTI JAGGA
I.D. : 984
AGE/SEX : 35/F
RECORDED : 13-3-2022 11:26

RATE : 97 BPM
B.P. : 126/74 mmHg

BRUCE
EXERCISE 2
PHASE TIME : 5:59
STAGE TIME : 2:59

ST @ 10mm/mV
80ms PostJ
SPEED : 4.0 Km./Hr.
GRADE : 12.0 %

LINKED MEDIAN



ONEPLUS ULTRASOUND LAB
47, Harsis C, Sector 11, Gurgaon, Haryana
Ph. 011-42480101, 96566612051
E-mail: onepusul@gmail.com

ONEPLUS ULTRASOUND LAB

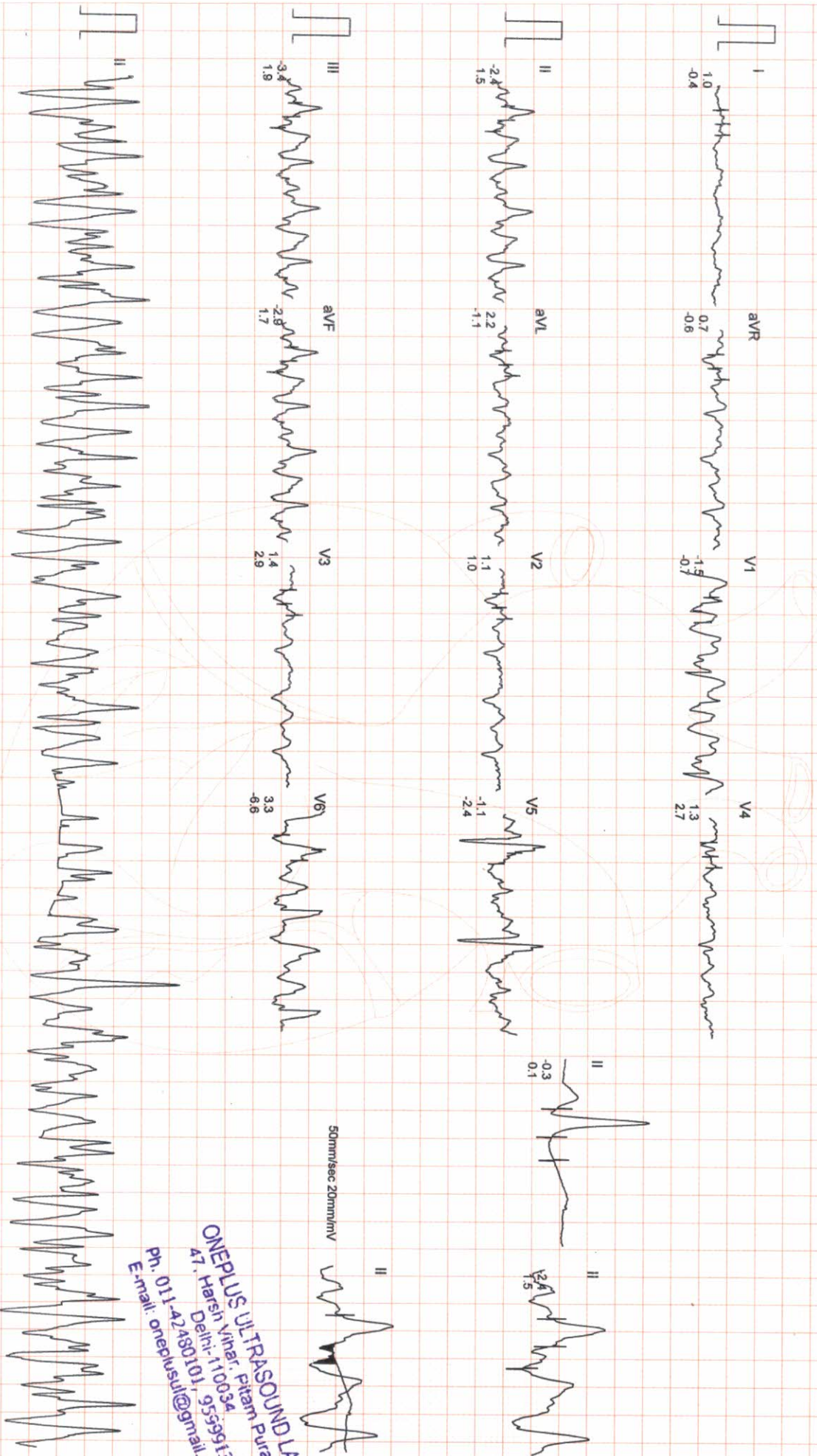
Ms. NITI JAGGA
I.D. : 984
AGE/SEX : 35/F
RECORDED : 13-3-2022 11:26

RATE : 86 BPM
B.P. : 140/80 mmHg

BRUCE
EXERCISE 3
PHASE TIME : 8:59
STAGE TIME : 2:59

ST @ 10mm/mV
80ms PostJ
SPEED : 5.4 Km./Hr.
GRADE : 14.0 %

LINKED MEDIAN



ONEPLUS ULTRASOUND LAB
47, F. Harsh Vihar, Pitam Pura,
Delhi-110034
Ph. 011-42480101, 9559913051
E-mail: oneplusul@gmail.com

ONEPLUS ULTRASOUND LAB

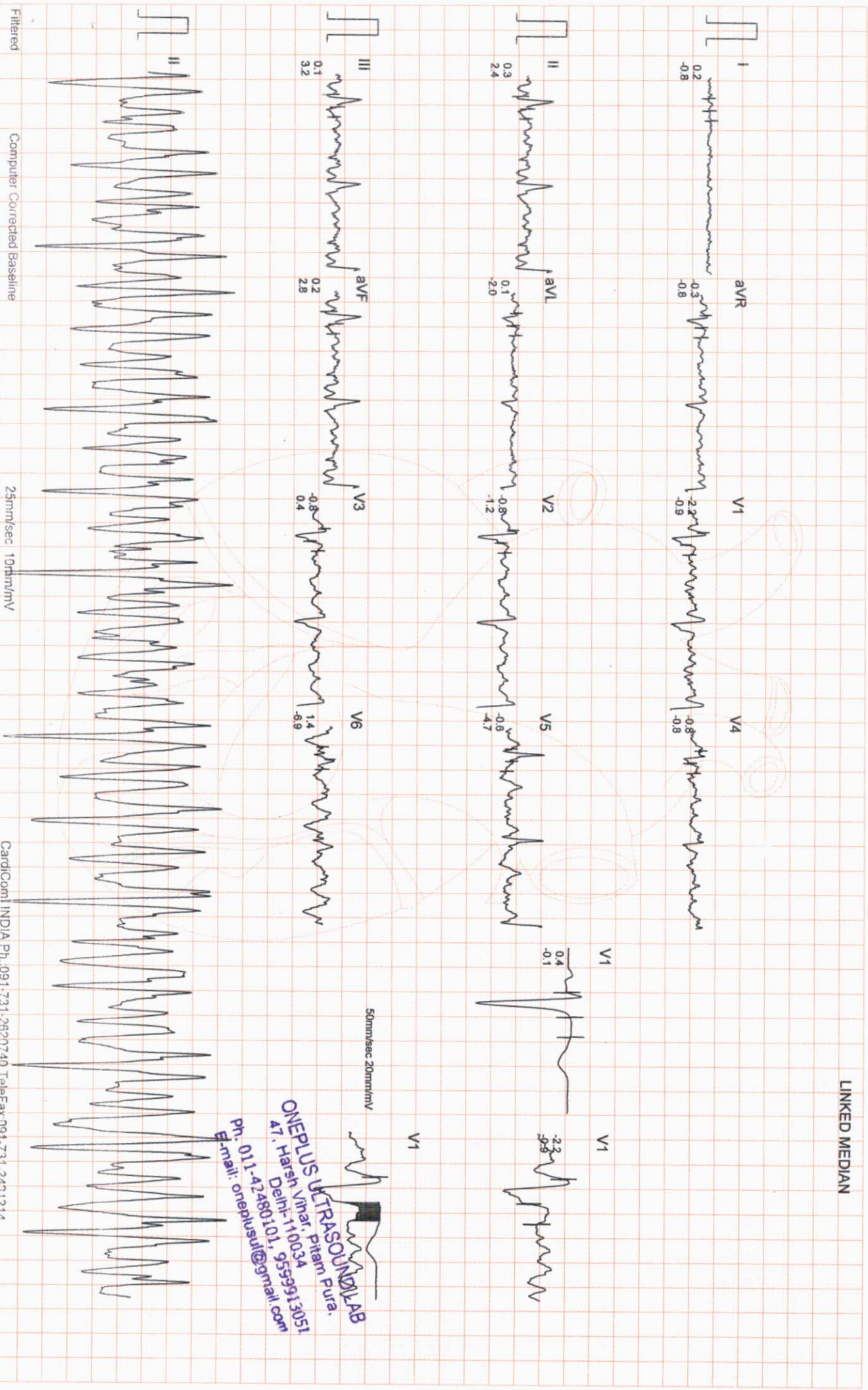
MS. NITI JAGGA
ID : 984
AGE/SEX : 35/F
RECORDED : 13-3-2022 11:26

RATE : 122 BPM
B.P. : 150/90 mmHg

BRUCE
EXERCISE 4
PHASE TIME : 9:29
STAGE TIME : 0:29

ST @ 10mm/mV
80ms PostJ
SPEED : 6.7 Km./Hr.
GRADE : 16.0 %

LINKED MEDIAN



50mmsec 20mm/mV

ONEPLUS ULTRASOUND LAB
Bhatnagar, Vihar, 01100334
47, Harshit, Vihar, 01100334
Delhi-110010, 9555666613130511
www.oneplusultrasoundlab.com
Ph: 011-42448801, 9555666613130511
E-mail: oneplusultrasoundlab@gmail.com

ONEPLUS ULTRASOUND LAB

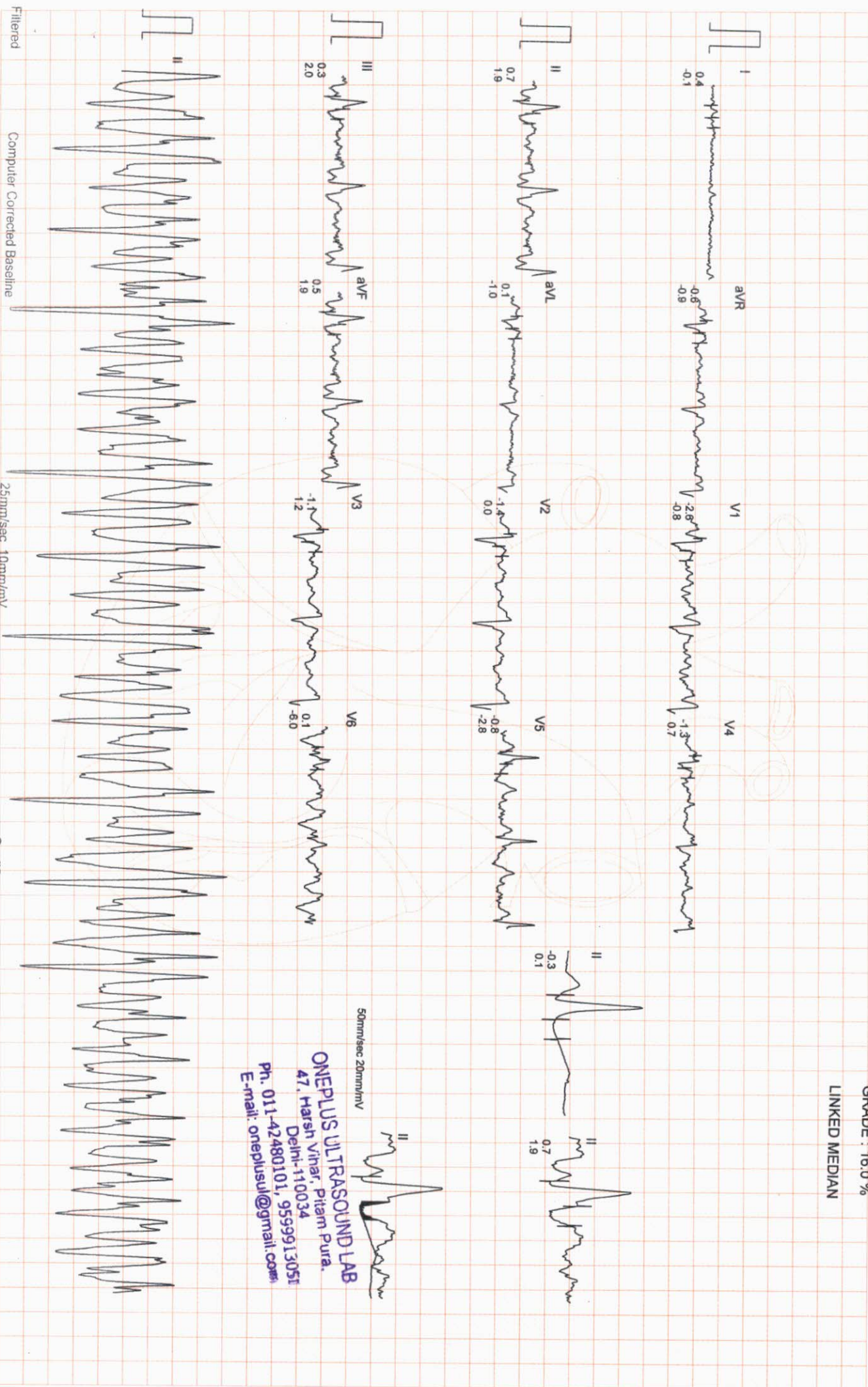
Ms. NITI JAGGA
I.D. : 984
AGE/SEX : 35/F
RECORDED : 13-3-2022 11:26

RATE : 124 BPM
B.P. : 150/90 mmHg

BRUCE
PEAK EXER
PHASE TIME : 9:30
STAGE TIME : 0:30

ST @ 10mm/mV
80ms PostJ
SPEED : 6.7 Km./Hr.
GRADE : 16.0 %

LINKED MEDIAN



50mm/sec 20mm/mV

ONEPLUS ULTRASOUND LAB
47, Harsh Vihar, Pitam Pura,
Delhi-110034
Ph. 011-42480101, 9599913051
E-mail: oneplusul@gmail.com

Filtered

Computer Corrected Baseline

25mm/sec 10mm/mV

ASIA

CardiCom, INDIA Ph.:091-731-2620740, TeleFax:091-731-2431214

ONEPLUS ULTRASOUND LAB

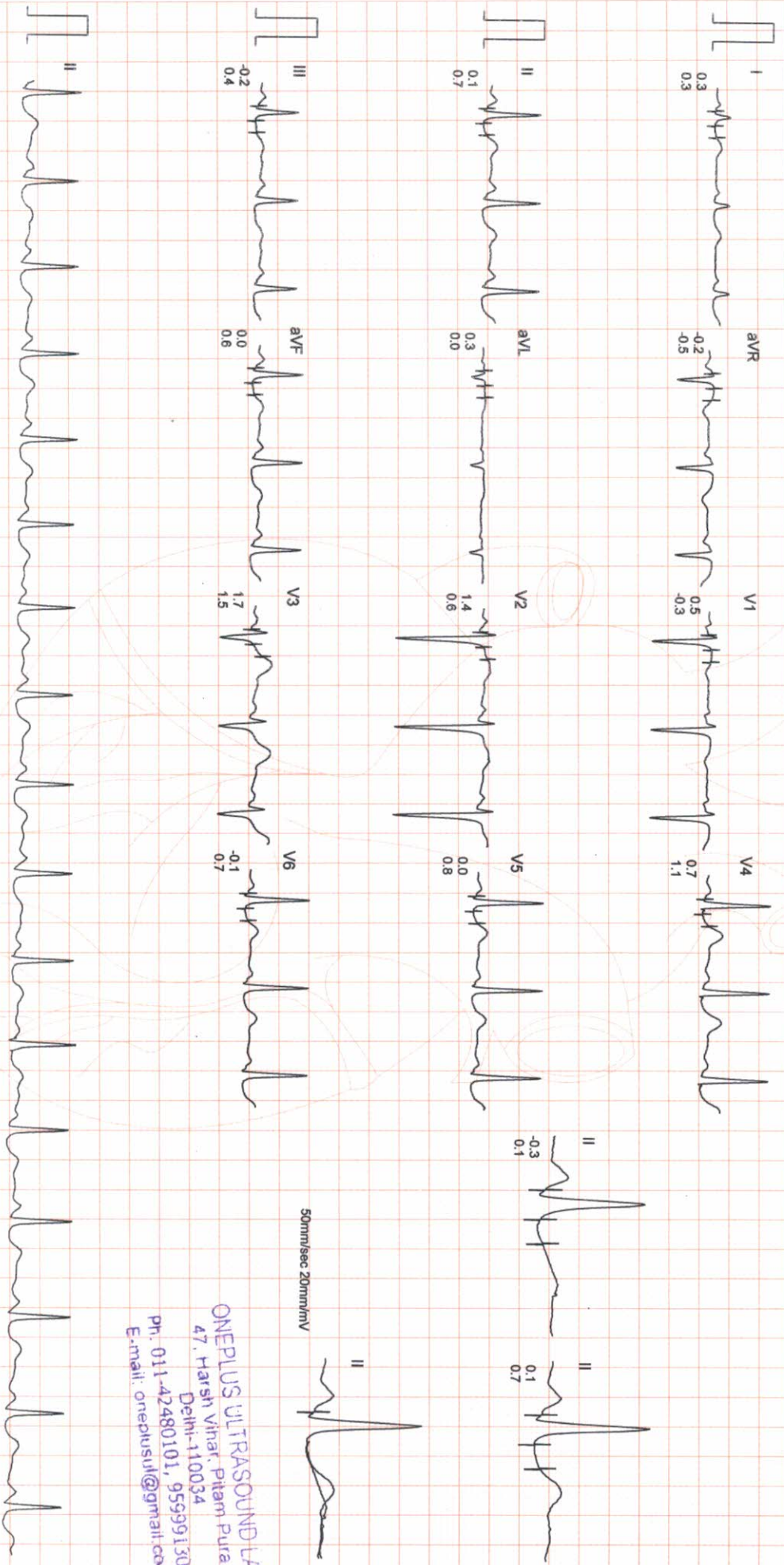
Ms. NITI JAGGA
 ID : 984
 AGE/SEX : 35/F
 RECORDED : 13-3-2022 11:26

RATE : 99 BPM
 B.P. : 116/72 mmHg

BRUCE
 RECOVERY
 PHASE TIME : 2:59

ST @ 10mm/mV
 80ms PostJ
 SPEED : 0.0 Km./Hr.
 GRADE : 0.0 %

LINKED MEDIAN



50mm/sec 20mm/mV

ONEPLUS ULTRASOUND LAB
 47, Harsh Vihar, Pitam Pura,
 Delhi-110034
 Ph: 011-42480101, 959991305
 E-mail: oneplusul@gmail.com

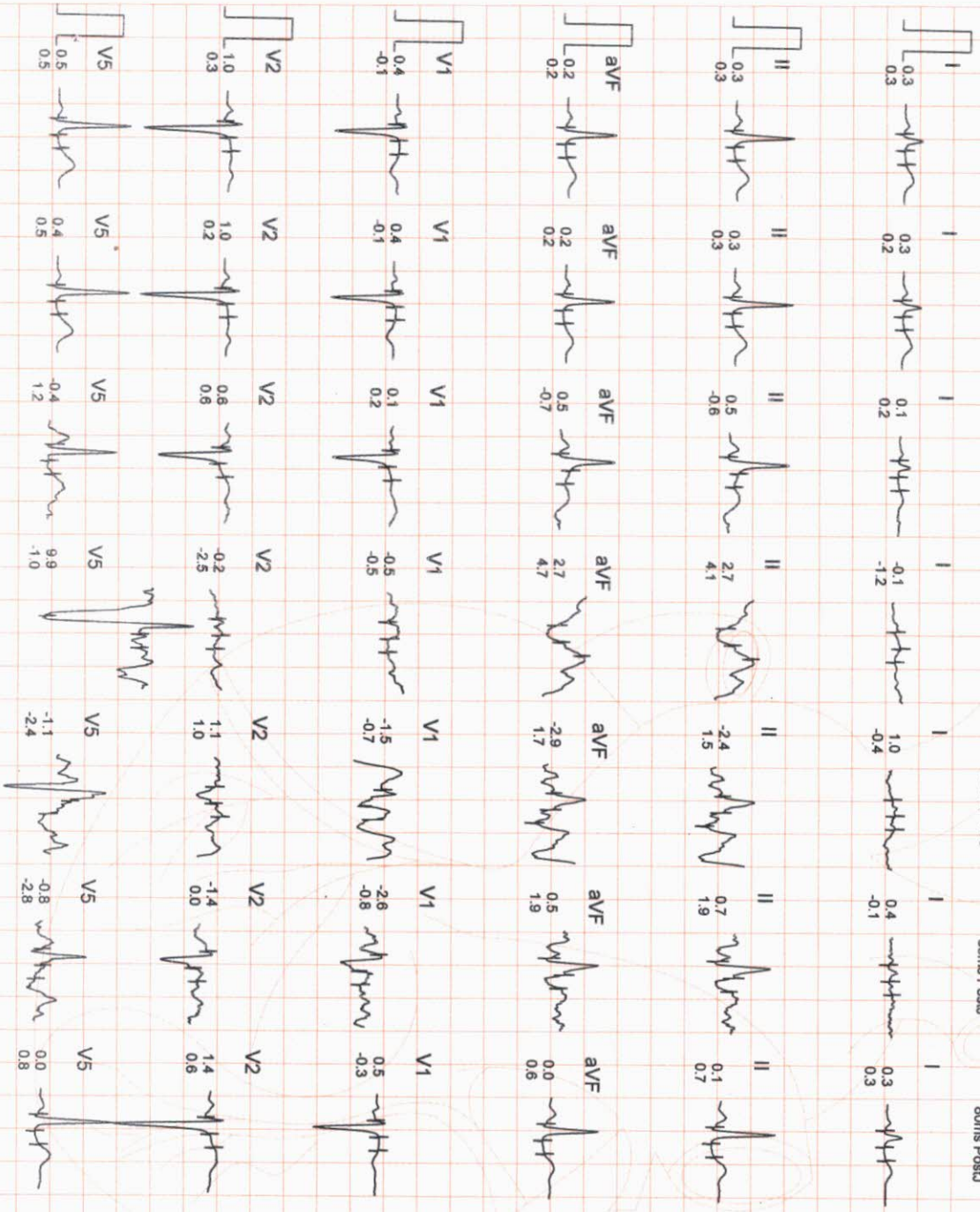
Filtered Computer Corrected Baseline

25mm/sec 10mm/mV

ARROW

CardiCom, INDIA Ph.:091-731-2620740, Tel/Fax:091-731-2431214

STAGE	STAGE 1	STAGE 2	STAGE 3	PEAK EXERCISE	RECOVERY
SUPINE	2:59	5:59	8:59	9:30	2:59
STANDING	2:59	4:00Kmph	5:40Kmph	0:30	0:0Kmph
	2.7Kmph	12.0%	14.0%	6.7Kmph	0.0%
	72 bpm	97 bpm	86 bpm	16.0%	99 bpm
	B.P. 114/70	B.P. 126/74	B.P. 140/80	124 bpm	B.P. 150/90
	80ms PostJ	80ms PostJ	80ms PostJ	80ms PostJ	80ms PostJ



ONEPLUS ULTRASOUND LAB
 47, Harsh Vihar, Pitam Pura.
 Delhi-110034
 Ph. 011-42480101, 9599913051
 E-mail: oneplusul@gmail.com

ONEPLUS ULTRASOUND LAB

AGE/SEX : 35/F

RECORDED : 13-3-2022 11:26

COMPARISON REPORT

STANDING

0.0kmph
0.0%
72 bpm
B.P. 114/70
80ms PostJ

PEAK EXERCISE






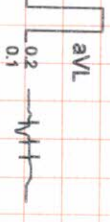
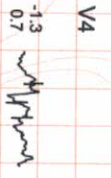


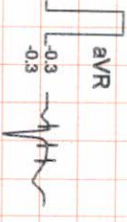



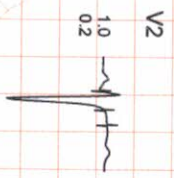




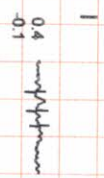

9:30
0:30
6.7kmph
16.0%
124 bpm
B.P. 150/90
80ms PostJ

STANDING

0.0kmph
0.0%
72 bpm
B.P. 114/70
80ms PostJ

PEAK EXERCISE

9:30
0:30
6.7kmph
16.0%
124 bpm
B.P. 150/90
80ms PostJ



ONEPLUS ULTRASOUND LAB
 47, Harsh Vihar, Pitam Pura,
 Delhi-110054
 Ph. 011-42480101, 95599913051
 E-mail: oneplusul@gmail.com



OnePLUS
Ultrasound Lab

— QUALITY FIRST... ALWAYS! —

Dr. Nitin Agarwal
Pathologist & Director
Ex. Sr. Res. MAMC
& Lok Nayak Hospital
Ex. Chief of Lab Dr. Lal Path Labs.

Dr. Pooja (Garg) Agarwal
Radiologist & Director
MAMC & Lok Nayak Hospital

Name	: Mrs. NITI JAGGA	Age/Sex	: 35 YRS/Female
Ref. By	: Dr. MEDIWHEEL	Lab No	: 012203130007
Date	: 13-Mar-2022	Patient ID	: LSHHI92504

ULTRASOUND EXAMINATION----WHOLE ABDOMEN

Liver is normal in size (11.3 cm) and outline with normal echopattern. Intrahepatic biliary radicles are not dilated. No abscess or mass lesion seen. Hepatic veins, portal vein, IVC and aorta are normal. CBD is normal in caliber.

Gall bladder is well distended with anechoic lumen. Wall thickness is normal.

Both kidneys are normal in size, shape, position, outline and echopattern. Corticomedullary differentiation is maintained. No pelvicalyceal dilation or mass lesion is seen.

Renal measurements are --

Rt. Kidney - 10.8 x 4.0 cm.

Lt. kidney - 11.2 x 4.8 cm

Spleen is normal in size (9.3 cm) and echotexture. No mass lesion seen.

Pancreas is normal in size, outline and echotexture.

Urinary bladder is normal in shape and position. No evidence of intravesical stone or mass seen.

Uterus is normal in size, shape, position and echopattern. **An intramural fibroid (sized 5.7 x 5.2 x 4.4 cm) is seen in the left lateral wall of uterus with internal anechoic areas, suggest cystic degeneration.**


Uterine cavity is empty. Endometrial thickness is 3.6 mm

Both ovaries appear normal in size, shape and echopattern. No tubo-ovarian mass seen.

No abnormal bowel wall thickening seen in right iliac fossa.
No free fluid seen anywhere in abdomen.

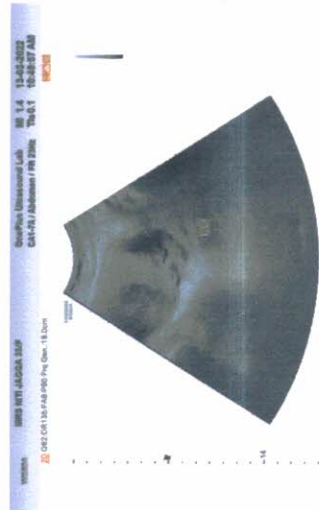
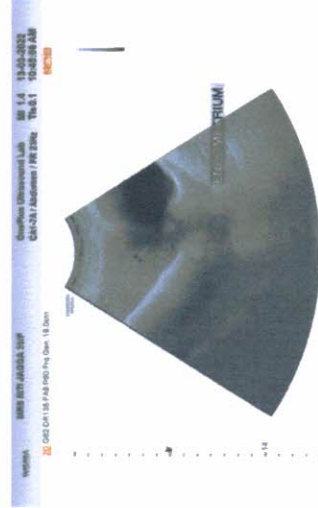
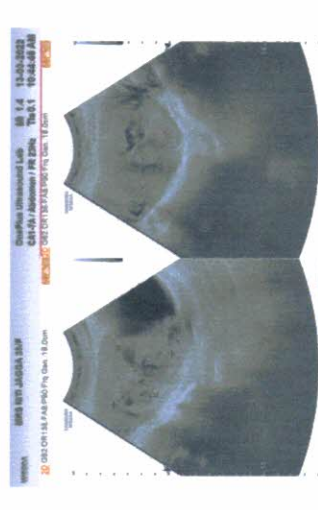
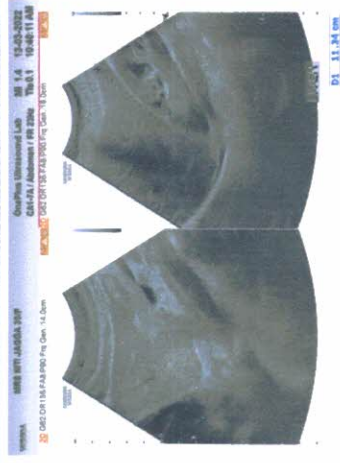
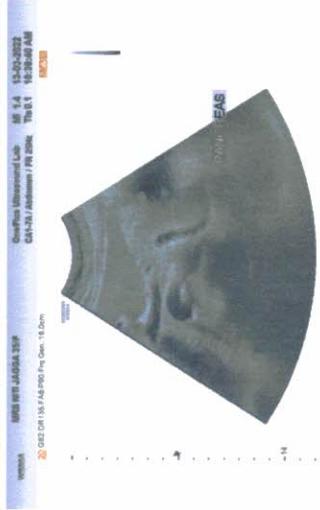IMPRESSION:

- **Intramural uterine fibroid.**
- **Rest within limits.**


Dr. Shubham K
MD RADIODIAGNOSIS
REG NO - DMC/R/99162

Dr SHUBHAM KHATOD
MBBS, MD
Reg. No. DMC/R/99162
Radiologist

47, Harsh Vihar, Pitampura, New Delhi-110034 | Ph.: 011-42480101, 9599913051
E-mail: oneplusul@gmail.com | Web.: www.oneplusul.in





OnePLUS Ultrasound Lab

QUALITY FIRST... ALWAYS!

Dr. Nitin Agarwal
Pathologist & Director
Ex. Sr. Res. MAMC
& Lok Nayak Hospital
Ex. Chief of Lab Dr. Lal Path Labs.

Dr. Pooja (Garg) Agarwal
Radiologist & Director
MAMC & Lok Nayak Hospital



NAME	:Mrs. NITI JAGGA	Barcode No	:10115228
AGE/GENDER	:35 YRS/Female	SPECIMEN DATE	:13/Mar/2022 09:45AM
PATIENT ID	:92504	SPECIMEN RECEIVED	:13/Mar/2022 09:53AM
REFERRED BY	:Dr. MEDIWHEEL	REPORT DATE	:13/Mar/2022 06:01PM
CENTRE NAME	:ONEPLUS ULTRASOUND LAB	LAB NO.	:012203130007

Test Name	Result	Unit	Ref. Range
-----------	--------	------	------------

HAEMATOLOGY

Health checkup 2 Female

Glycosylated Hemoglobin (HbA1c)	4.4	%	Non Diabetic adults <5.7 Prediabetic (at risk) 5.7-6.4 Diabetes >6.4
--	-----	---	--

Estimated average blood glucose (eag) 80

Reference range (mg/dl):

90 - 120:Excellent control, 121 - 150:Good Control, 151 - 180:Average Control, 181 - 210:Action Suggested

>211:Panic value

BLOOD GROUP (ABO)	A
Rh typing	POSITIVE

NOTE :

- * Apart from major A,B,H antigens which are used for ABO grouping and Rh typing, many minor blood group antigens exist. Agglutination may also vary according to titre of antigen and antibody.
- * So before transfusion, reconfirmation of blood group as well as cross-matching is needed.
- * Presence of maternal antibodies in newborns, may interfere with blood grouping.
- * Auto agglutination (due to cold antibody, falciparum malaria, sepsis, internal malignancy etc.) may also cause erroneous result.

CBC

Haemoglobin	8.5	g/dl	11.5-15.0
Total Leucocyte Count	5750	/cumm	4000-10000
Differential leucocyte count			
Neutrophils	49.5	%	40-80
Lymphocyte	32.50	%	20-40
Monocytes	8.10	%	2-10
Eosinophils	9.3	%	1-6
Basophils	0.6	%	0-2
RBC Count	4.33	million/cumm	3.8-4.8

Checked By.

Dr. NITIN AGARWAL
M B B S , MD (Path) (MPP)
DMC/R/01436

47, Harsh Vihar, Pitampura, New Delhi-110034 | Ph.: 011-42480101, 9599913051

E-mail: oneplusul@gmail.com | Web.: www.oneplusul.in

Page 1 of 5

Clinical correlation is essential for final diagnosis. • If test results are unsatisfactory please contact personally or on phone. • This report is for perusal of doctors only. • All disputes Subject to Delhi Jurisdiction only. • Not for medicolegal purposes. • All congenital anomalies in a foetus may not be diagnosed in routine obstetric ultrasound.



OnePLUS Ultrasound Lab

QUALITY FIRST... ALWAYS!

Dr. Nitin Agarwal
Pathologist & Director
Ex. Sr. Res. MAMC
& Lok Nayak Hospital
Ex. Chief of Lab Dr. Lal Path Labs.

Dr. Pooja (Garg) Agarwal
Radiologist & Director
MAMC & Lok Nayak Hospital



NAME	:Mrs. NITI JAGGA	Barcode No	:10115228
AGE/GENDER	:35 YRS/Female	SPECIMEN DATE	:13/Mar/2022 09:45AM
PATIENT ID	:92504	SPECIMEN RECEIVED	:13/Mar/2022 09:53AM
REFERRED BY	:Dr. MEDIWHEEL	REPORT DATE	:13/Mar/2022 06:01PM
CENTRE NAME	:ONEPLUS ULTRASOUND LAB	LAB NO.	:012203130007

Test Name	Result	Unit	Ref. Range
PCV(Hematocrit)	30.5	%	36-46
MCV	70.4	fL	83-101
MCH	19.6	Pg	27-32
MCHC	27.8	G/dL	32-35
Platelet count	160000	/cumm	150000-450000
RDW-CV	18.1	%	11.4-14.0
ESR(WESTEGRENs METHOD)	20	mm/1hr	<20

BIOCHEMISTRY

<u>Blood sugar fasting</u>	74	mg/dL	70-110
<u>Bun (blood urea nitrogen)</u>	12.20	mg/dl	7-18.7
<u>Uric acid, serum</u>	4.8	mg/dl	2.4-5.7
<u>Creatinine, serum</u>	0.58	mg/dl	0.50-0.9


LFT(LIVER FUNCTION TEST)

Bilirubin Total	0.64	mg/dl	0.1-1.2
Bilirubin Conjugated	0.28	mg/dl	0-0.4
Bilirubin Unconjugated	0.36	mg/dl	up to 0.7
SGOT (AST)	14	U/L	0-31
SGPT (ALT)	16	U/L	<34
Alkaline phosphatase	84	U/L	35-104
Gamma glutamyl transpeptidase	22	U/L	<39
Total Protein	7.4	gm/dl	6.60 - 8.70
Albumin	4.2	g/dL	3.8-5.1
Globulin	3.20	gm/dl	1.8-3.4
Albumin/Globulin Ratio	1.31		1.10 - 2.50

LIPID PROFILE

Cholesterol	120	mg/dl	50-200
Triglycerides	34	mg/dL	25-150
HDL Cholesterol	32	mg/dL	30 - 70

Checked By.


Dr. NITIN AGARWAL
M B B S , MD (Path)
DMC/R/01436

47, Harsh Vihar, Pitampura, New Delhi-110034 | Ph.: 011-42480101, 9599913051
E-mail: onepusul@gmail.com | Web.: www.oneplusul.in

Page 2 of 5



OnePLUS Ultrasound Lab

QUALITY FIRST... ALWAYS!

Dr. Nitin Agarwal
Pathologist & Director
Ex. Sr. Res. MAMC
& Lok Nayak Hospital
Ex. Chief of Lab Dr. Lal Path Labs.

Dr. Pooja (Garg) Agarwal
Radiologist & Director
MAMC & Lok Nayak Hospital



NAME	:Mrs. NITI JAGGA	Barcode No	:10115228
AGE/GENDER	:35 YRS/Female	SPECIMEN DATE	:13/Mar/2022 09:45AM
PATIENT ID	:92504	SPECIMEN RECEIVED	:13/Mar/2022 09:53AM
REFERRED BY	:Dr. MEDIWHEEL	REPORT DATE	:13/Mar/2022 06:01PM
CENTRE NAME	:ONEPLUS ULTRASOUND LAB	LAB NO.	:012203130007

Test Name	Result	Unit	Ref. Range
LDL cholesterol	81	mg/dL	< 130
VLDL cholesterol	6.8	mg/dL	5-40
Cholesterol/HDL Ratio	3.8		Low Risk 3.3-4.97 Average Risk 4.4-7.1 Moderate Risk 7.1-11.0 High Risk >11.0
LDL/HDL Ratio	2.5		0 - 3.55

According to ATP III and NCEP guidelines

Parameter	Normal	Desirable	Borderline	High
Total cholesterol	<200	200-239		240
Triglycerides	<150	150-199	200-499	500
LDL	Optimal <100 Near Optimal 100-129	130-159	160-180	190
HDL	<40 : LOW 60 : HIGH			

ENDOCRINOLOGY

THYROID PROFILE(T3,T4,TSH)

Triiodothyronine total [t3]	0.84	ng/dl	0.52-1.9
Thyroxine total [t4]	8.60	µg/dl	4.8-11.6
TSH (Thyroid Stimulating Hormone)	1.24	µIU/ml	0.25-5.0

AGE WISE VARIATION IN TSH

AGE	TSH(µIU/ml)	AGE	TSH(µIU/ml)
1-4 weeks	1.00 - 19.0	16-20 yrs	0.25 - 5.0
1-12 mths	1.70 - 9.1	21 - 80 yrs	0.25 - 5.0
1-5 yrs	0.80 - 8.2	I st trimester	0.25 - 5.0
6-10 yrs	0.25 - 5.0	II nd trimester	0.50 - 5.0
11-15 yrs	0.25 - 5.0	II rd trimester	0.4 - 6.0

Checked By.

Dr. NITIN AGARWAL
M B B S , M D (Path)
DMC/R/01436

47, Harsh Vihar, Pitampura, New Delhi-110034 | Ph.: 011-42480101, 9599913051
E-mail: onepusul@gmail.com | Web.: www.oneplusul.in

Page 3 of 5

Clinical correlation is essential for final diagnosis. • If test results are unsatisfactory please contact personally or on phone. • This report is for perusal of doctors only.
• All disputes Subject to Delhi Jurisdiction only. • Not for medicolegal purposes. • All congenital anomalies in a foetus may not be diagnosed in routine obstetric ultrasound.



OnePLUS Ultrasound Lab

QUALITY FIRST... ALWAYS!

Dr. Nitin Agarwal
Pathologist & Director
Ex. Sr. Res. MAMC
& Lok Nayak Hospital
Ex. Chief of Lab Dr. Lal Path Labs.

Dr. Pooja (Garg) Agarwal
Radiologist & Director
MAMC & Lok Nayak Hospital



NAME	:Mrs. NITI JAGGA	Barcode No	:10115228
AGE/GENDER	:35 YRS/Female	SPECIMEN DATE	:13/Mar/2022 09:45AM
PATIENT ID	:92504	SPECIMEN RECEIVED	:13/Mar/2022 09:53AM
REFERRED BY	:Dr. MEDIWHEEL	REPORT DATE	:13/Mar/2022 06:01PM
CENTRE NAME	:ONEPLUS ULTRASOUND LAB	LAB NO.	:012203130007

Test Name	Result	Unit	Ref. Range
-----------	--------	------	------------

Reference ranges - Interpretation of Diagnostic tests - (Jacques Wallach)

1. Primary hypothyroidism is accompanied by depressed serum T3 and T4 values and elevated serum TSH level.
2. Primary hyperthyroidism is accompanied by elevated serum T3 and T4 levels along with depressed TSH values.
3. Slightly elevated T3 levels may be found in pregnancy and estrogen therapy, while depressed levels may be encountered in severe illness, renal failure and during therapy with drugs like propranolol and propyl thiouracil.
4. Although elevated TSH levels are nearly always indicative of primary hypothyroidism, and may be seen in secondary thyrotoxicosis

CLINICAL PATHOLOGY

URINE ROUTINE

Physical examination

Quantity	40	ML
Colour	PALE YELLOW	
Transparency	SLIGHTLY TURBID	CLEAR
Sp.gravity	1.015	1.010-1.030
pH	6.50	
Reaction	ACIDIC	ACIDIC

Chemical examination

Urine protein	NIL	NIL
Urine sugar	NIL	NIL
Bilirubin, urine	NEGATIVE	NEGATIVE
Urobilinogen	NORMAL	NORMAL
Ketones	NEGATIVE	NEGATIVE

Microscopic examination

Pus cells.	10-12	/HPF	1-2
Epithelial cells	6-8	/HPF	0-5
R.B.C.	NIL	/HPF	NIL
Casts	NIL	/HPF	NIL
Crystals	NIL	/HPF	NIL
Bacteria	NIL	/HPF	NIL
Others.	NIL		NIL

Checked By.

Dr. NITIN AGARWAL
MBBS, MD (Path)
DMC/R/01436
(PATHOLOGIST)

47, Harsh Vihar, Pitampura, New Delhi-110034 | Ph.: 011-42480101, 9599913051

E-mail: oneplusul@gmail.com | Web.: www.oneplusul.in

Page 4 of 5

Clinical correlation is essential for final diagnosis. • If test results are unsatisfactory please contact personally or on phone. • This report is for perusal of doctors only.
• All disputes Subject to Delhi Jurisdiction only. • Not for medicolegal purposes. • All congenital anomalies in a foetus may not be diagnosed in routine obstetric ultrasound.



OnePLUS Ultrasound Lab

Dr. Nitin Agarwal
Pathologist & Director
Ex. Sr. Res. MAMC
& Lok Nayak Hospital
Ex. Chief of Lab Dr. Lal Path Labs.

Dr. Pooja (Garg) Agarwal
Radiologist & Director
MAMC & Lok Nayak Hospital




QUALITY FIRST... ALWAYS!

NAME	:Mrs. NITI JAGGA	Barcode No	:10115228
AGE/GENDER	:35 YRS/Female	SPECIMEN DATE	:13/Mar/2022 09:45AM
PATIENT ID	:92504	SPECIMEN RECEIVED	:13/Mar/2022 09:53AM
REFERRED BY	:Dr. MEDIWHEEL	REPORT DATE	:13/Mar/2022 06:01PM
CENTRE NAME	:ONEPLUS ULTRASOUND LAB	LAB NO.	:012203130007

Test Name	Result	Unit	Ref. Range
-----------	--------	------	------------

*** End Of Report ***

Checked By.


Dr. NITIN AGARWAL
MBBS, MD (Path)
DMC/R/01436
NITIN AGARWAL
(PATHOLOGIST)

47, Harsh Vihar, Pitampura, New Delhi-110034 | Ph.: 011-42480101, 9599913051
E-mail: oneplusul@gmail.com | Web.: www.oneplusul.in

Page 5 of 5

Clinical correlation is essential for final diagnosis. • If test results are unsatisfactory please contact personally or on phone. • This report is for perusal of doctors only.
• All disputes Subject to Delhi Jurisdiction only. • Not for medicolegal purposes. • All congenital anomalies in a foetus may not be diagnosed in routine obstetric ultrasound.



OnePLUS
Ultrasound Lab
— QUALITY FIRST... ALWAYS! —

Dr. Nitin Agarwal
Pathologist & Director
Ex. Sr. Res. MAMC
& Lok Nayak Hospital
Ex. Chief of Lab Dr. Lal Path Labs.

Dr. Pooja (Garg) Agarwal
Radiologist & Director
MAMC & Lok Nayak Hospital

Name	: Mrs. NITI JAGGA	Age/Sex	: 35 YRS/Female
Ref. By	: Dr. MEDIWHEEL	Lab No	: 012203130007
Date	: 13-Mar-2022	Patient ID	: LSHHI92504

X-ray-Chest PA view

Lung fields are clear. No parenchymal lesion seen.

Cardiothoracic ratio is normal.

Mediastinum is normal.


Both hila are normal.

Both costophrenic angles are clear.

Both domes of diaphragm are normal.

Bony cage and soft tissues are normal.

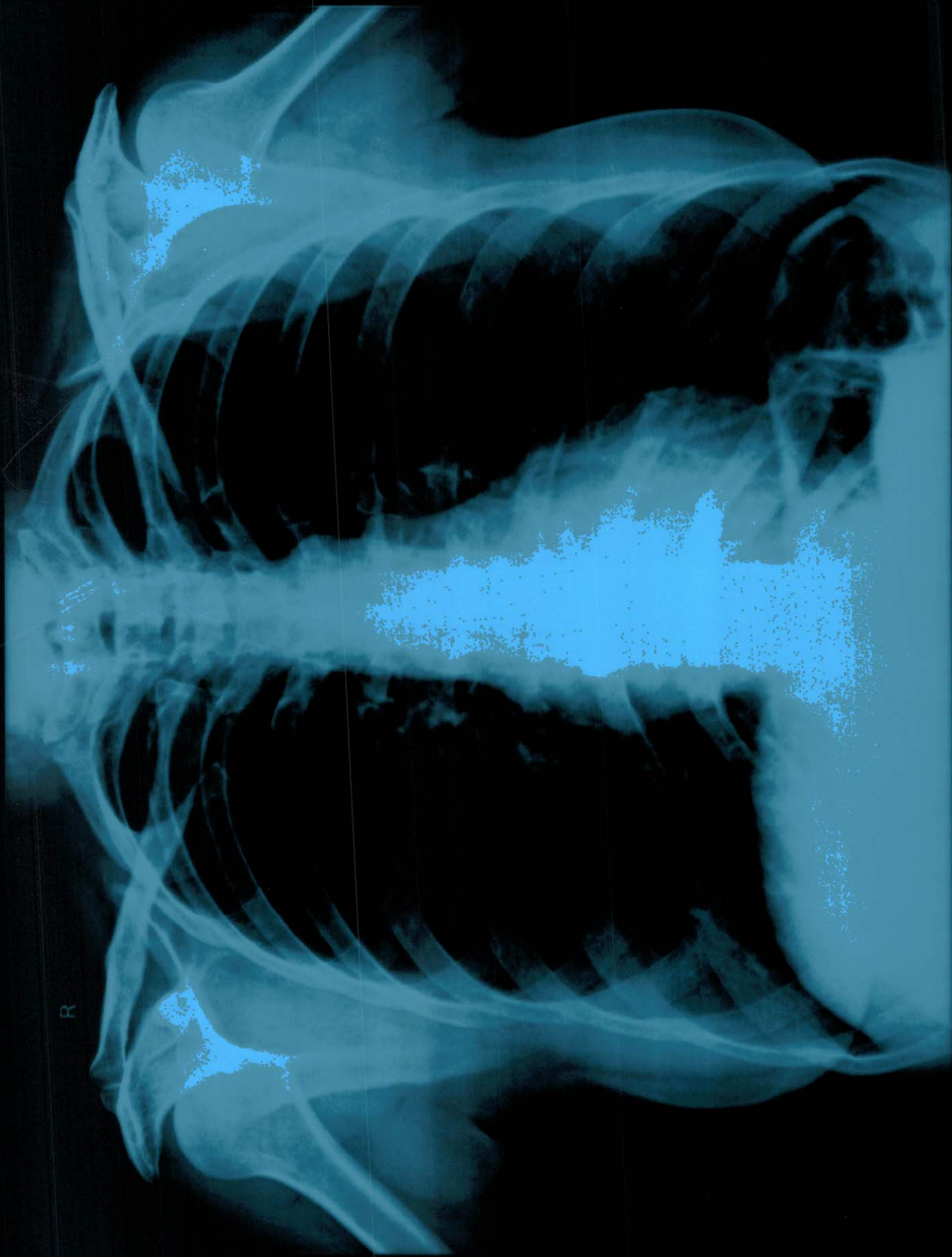
IMPRESSION: Normal Study.


Dr. Shubham K
MD RADIODIAGNOSIS
REG NO – DMC/R/99162

Dr SHUBHAM KHATOD
MBBS, MD
Reg. No. DMC/R/99162
Radiologist

47, Harsh Vihar, Pitampura, New Delhi-110034 | Ph.: 011-42480101, 9599913051
E-mail: oneplusul@gmail.com | Web.: www.oneplusul.in

Clinical correlation is essential for final diagnosis. • If test results are unsatisfactory please contact personally or on phone. • This report is for perusal of doctors only.
• All disputes Subject to Delhi Jurisdiction only. • Not for medicolegal purposes. • All congenital anomalies in a foetus may not be diagnosed in routine obstetric ultrasound.

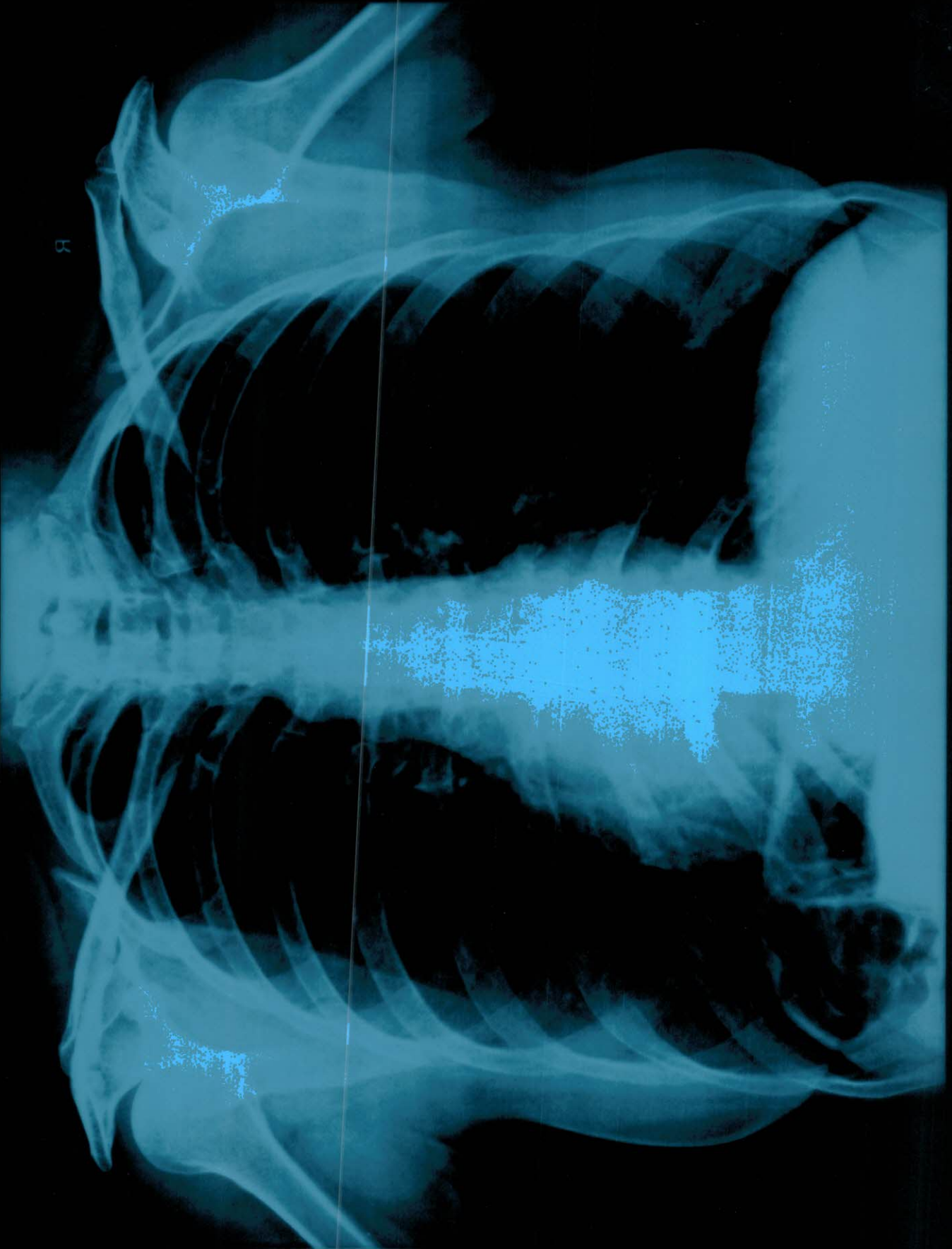


R

MRS.NITI JAGGA 35 YRS 13-03-2022 F CHEST PA VIEW 3/13/2022

ONEPLUS ULTRASOUND LAB.47-HARSH VIHAR,PITAMPURA

ONEPLUS ULTRASOUND LAB 41-HARSH NIVAR PITALAMPUR
MRS. NILI JAGGA 32 YRS 13-03-5055 F CHEST PA VIEW 31/3/5055



R