



M.V.R. MURTHY

Age: 48 yr / m

Dr. P. LALITHA 12/3/22

Gr. medicane

DR. P. Lalitha.

Reg.No:40050 MBBS, M.D.,
Consultant Physician & Diabetologist
SENTINI HOSPITALS
VIJAYAWADA-520008
Cell No 9848340244

Wt. 60kg

DM x 12yr

Ht 5'10"

T- glycomet hp3 / 850
1 - + -
T- Pioglit 15mg
- 1 -
T- Telinta 20mg

Came for routine check up.

FBS 200mg.

BP - 120/80 mmHg

CVL - S/S 2+

hr - b/c air entry +.

Rx ① T. glycomet hp3 / 850mg
1 ————— 1
BBP BD.

② T. Pioglit 15mg
1 ————— 1

③ T. Instanet 100mg (30)
— before lunch.

RA muthu FBS / PFS 12



Department Of Laboratory

Date :

Name : Mr. MURTHY .M.V.R.	Age /Sex : 48 Y(s)/Male
Bill Date : 12-Mar-2022 08:27 AM	UMR No. : UMR2203202
Rept. Dt : 12-Mar-2022 10:37 AM	Bill No. : BIL22004663
Ref By : Dr.GENERAL HEALTH CHECK UP	Result No : 0 / RES22004734

Parameter	Result	Normal Values
LFT(LIVER FUNCTION TEST)		
Total Bilirubin	: 1.2 mg/dl	0.1 - 1.2 mg/dl
Direct Bilirubin	:* 0.4 mg/dl	0.0 - 0.3 mg/dl
Indirect Bilirubin	: 0.8 mg/dl	
SGOT	: 22 IU/L	5 - 55 IU/L
SGPT	: 24 IU/L	5 - 55 IU/L
Alkaline Phosphatase	: 60 IU/L	Adult : 35 - 125 IU/L Children : 125 - 330 IU/L
Total Protein	: 6.8 gm/dl	6.0 - 8.3 gm/dl
Albumin	: 3.8 gm/dl	3.2 - 5.0 gm/dl
Globulin	: 3.0 gm/dl	2.5 - 3.0 gm/dl
A / G RATIO	:* 1.2	1.51 - 1.81
CBC (COMPLETE BLOOD COUNT)		
HAEMOGLOBIN	: 13.7 g/dl	12.0 - 17.0 g/dl
Total WBC Count	: 6,600 cells/cumm	4000 - 11000 cells/cumm
DC COUNT		
Neutrophils	: 70 %	50 - 70 %
Lymphocytes	: 25 %	15 - 40 %
Eosinophils	: 03 %	0 - 7 %
Monocytes	: 02 %	0 - 4 %
Basophils	: 00 %	0 - 1 %
RBC COUNT	: 4.5 millions/cumm	4.5 - 6.5 millions/cumm
PLATELET COUNT	: 1.6 lakhscells/cumm	1.5 - 4.0 lakhscells/cumm

*** End Of Report ***

Lab Tech

Bio-Chemist

Lab In-Charge

Incharge Pathologist

Correlate Clinically, We use only sterilised disposable syringes & needles.

Discrepancies due to technical or typing errors should be reported within 3 days for correction.

This report is to help you for better management of patient and not valid for medicolegal purpose.



Department Of Laboratory

Date :

Name : Mr. MURTHY .M.V.R.
Bill Date : 12-Mar-2022 08:26 AM
Rept. Dt : 12-Mar-2022 10:37 AM
Ref By : Dr.GENERAL HEALTH CHECK UP


Age /Sex : 48 Y(s)/Male
UMR No. : UMR2203202
Bill No. : BIL22004663
Result No : 0 / RES22004734

Parameter	Result	Normal Values
RFT (RENAL FUNCTION TEST)		
BLOOD UREA	: 19 mg/dl	13 - 45 mg/dl
Serum Creatinine	: 0.7 mg/dl	0.7 - 1.4 mg/dl
LIPID PROFILE		
Fasting Blood Sugar	:* 200 mg/dl	70 - 110 mg/dl
Total Cholesterol	: 185 mg/dl	150 - 240 mg/dl
Triglycerides	: 150 mg/dl	50 - 200 mg/dl
HDL Cholesterol	: 37 mg/dl	35 - 80 mg/dl
LDL Cholesterol	: 118 mg/dl	80 - 160 mg/dl
VLDL	: 30 mg/dl	10 - 50 mg/dl
Cholesterol / HDL ratio	: 5.0	< 6
LDL / HDL	: 3.1	< 4
URINE ROUTINE EXAMINATION		
Sugar	: +	
Albumin	: Nil	
Microscopic Examination		
Pus cells	: 1-2 /HPF	
Epithelial cells	: 1-2 /HPF	
RBC	: Nil /HPF	
Blood Grouping & Rh Typing	: "A" POSITIVE	

*** End Of Report ***

Lab Tech. 

Bio-Chemist

Lab In-Charge 

Incharge Pathologist



Department Of Laboratory

Date :

Name : Mr. MURTHY .M.V.R.	Age /Sex : 48 Y(s)/Male
Bill Date : 12-Mar-2022 08:26 AM	UMR No. : UMR2203202
Rept. Dt : 12-Mar-2022 01:50 PM	Bill No. : BIL22004663
Ref By : Dr.GENERAL HEALTH CHECK UP	Result No : 0 / RES22004783

<u>Parameter</u>	<u>Result</u>	<u>Normal Values</u>
HB A1C	: 9.5 %	Non Diabetic : < 6.0 % Good Control : 6.0 - 7.5 % Fair control : 7.5 - 8.5 % Poor Control : > 8.5 %
Post Prandial Blood Sugar	: * 255 mg/dl	80 - 199 mg/dl
TFT (THYROID FUNCTION TEST)		
T3 (TRI IODO THYRONINE)	: 122 ng/dl	80 - 200 ng/dl
T4 (THYROXINE)	: 8.9 ug/dl	5.1 - 14.1 ug/dl
TSH (THYROID STIMULATING HORMONE)	: * 5.34 mIU/l	0.3 - 4.2 mIU/l
PSA	: <2 ng/ml	0.0 - 4.0 ng/ml

*** End Of Report ***

[Signature]
Lab Tech.
Correlate Clinically

Bio-Chemist

Lab In-Charge

Incharge Pathologist

We use only sterilised disposable syringes & needles.

This report is to help you for better management of patient and not valid for medicolegal purpose.
Discrepancies due to technical or typing errors should be reported within 3 days for correction.



M.V.R. MURTHY

Date: 12/03/2022

UNIDate203202

Age/Sex: 48Y/M

Ref : GENERAL


REAL TIME ULTRASONOGRAPHY OF THE ABDOMEN

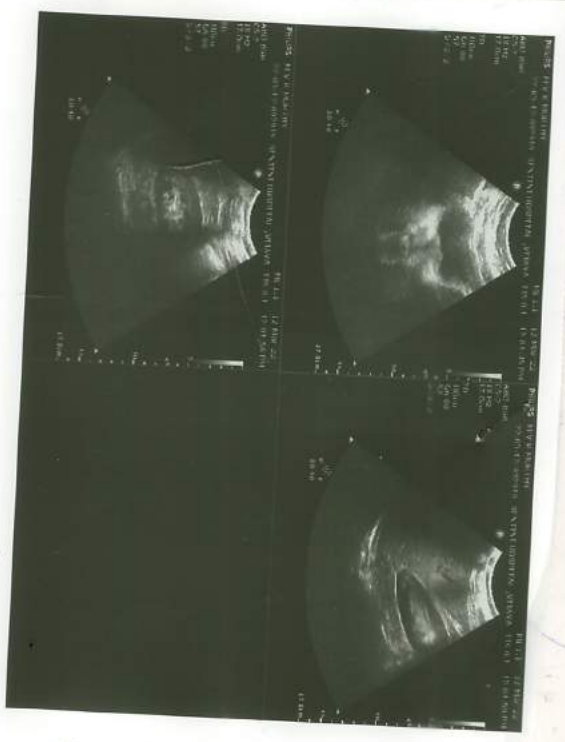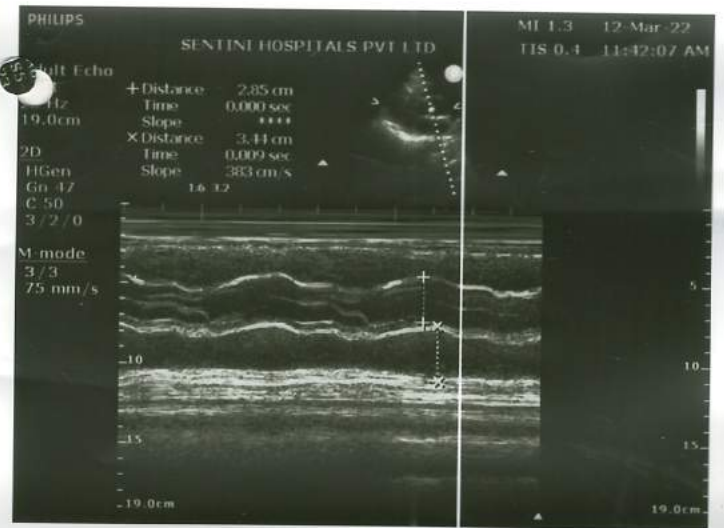
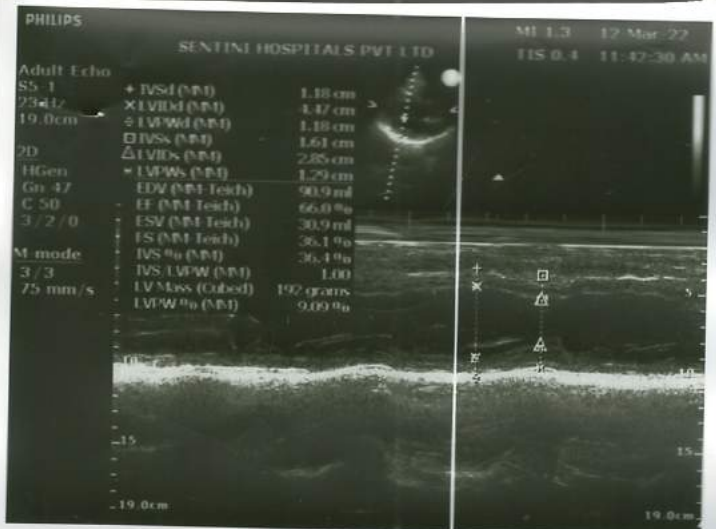
- LIVER:** Normal in size, shape and outline. Parenchymal texture is increased
No focal cystic or solid mass lesion. No intrahepatic biliary dilatation. Intrahepatic portion of IVC is normal.
Portal vein is normal. Porta hepatis is normal.
- G. B:** Normal.
C.B.D: Not dilated.
- PANCREAS:** Parenchymal texture normal. No ductal dilatation. No calculi.
- SPLEEN:** Normal in size & echotexture.
- AORTA:** Normal.
- KIDNEYS:** **Right kidney** measures 8.9 x 3.2cm .
Normal in size, shape and outline. Parenchymal texture normal.
Corticomedullary differentiation is well made out and is normal.
No evidence of calculi/ Hydronephrosis.
- Left kidney** measures 9.5 x 4.3cm
Normal in size, shape and outline. Parenchymal texture normal.
Corticomedullary differentiation is well made out and is normal.
No evidence of calculi / Hydronephrosis.
- U.B:** Normal.
Prostate : Normal in size & echotexture.
* No evidence of free fluid / lymphadenopathy.

IMPRESSION:

➤ **GRADE I FATTY LIVER**

- For clinical correlation & follow up.


Dr. P.JAYA RAM MD RD.,
[Consultant Radiologist]





Sentini Hospitals (P) Limited

Cardiology Department

ECHOCARDIOGRAM REPORT

Name : MR M.V.R.MURTHY	UMR/OP/IP No : 2203202
Age : 48 Years	Sex : M
Date : 12 /03/2022	Echo No : 255
Technician: Srinivas/Chetansai	

MITRAL VALVE : Normal
AORTIC VALVE : Normal
TRICUSPID VALVE : Normal
PULMONARY VALVE : Normal
AORTA : 28 mm
LEFT ATRIUM : 34 mm
LEFT VENTRICLE : Normal
RWMA : No LV RWMA
IVS : 11 mm LV IDd : 44 mm
PW : 10 mm LVIDs : 28 mm
LV EF : 64 %
RIGHT ATRIUM : Normal
RIGHT VENTRICLE : Normal
PULMONARY ARTERY : Normal
PULMONARY VEINS : Normal
IAS : Intact
IVS : Intact
PERICARDIUM : Normal
PERICARDIAL EFFUSION : No Effusion

DOPPLER STUDY

MITRAL FLOW : A>E
TRICUSPID FLOW : TRJV- m/s TR Gr :10 mmHg RVSP: 20 mmHg
AORTIC JET VELOCITY : 1.1 m/s AV Gr: mmHg
PULMONARY JET VELOCITY : 0.8 m/s
COLOUR DOPPLER : 1+ MR 1+ TR No AR No PR
IVC : Normal
SVC : Normal
OTHERS :
CONCLUSION : Normal Sized Cardiac Chambers,
No LV RWMA,
Trivial MR, TR, No PAH,
Normal LV Systolic Function,
Grade-I LV Diastolic Dysfunction,
No Pericardial Effusion,
No Clot/Vegetation/Masses.

Dr. MADHURI MD.DM

CONSULTANT CARDIOLOGIST

Dr. A.RAVI KUMAR MD.DM

CONSULTANT CARDIOLOGIST

Dr. P.V. SIVA PRASAD MD. DM.FESC

CHIEF CARDIOLOGIST

12-03-2022 09:45:46 AM

ID : 9

Name :

Age :

Years :

Gender : Male

HR

P Dur

PR int

QRS Dur

QT/QTc int

P/QRS/T axis

RV5/SV1 amp

RV5+SV1 amp

RV6/SV2 amp

77 BPM

96 ms

155 ms

104 ms

367/415 ms

30/60/66 °

0.699/0.894 mV

1.593 mV

0.607/1.179 mV


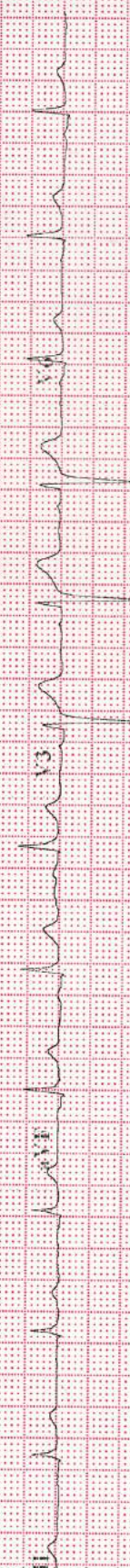
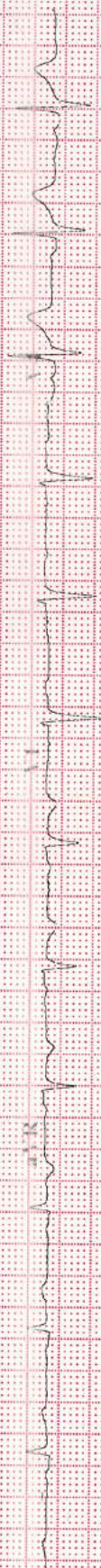
Diagnosis Information:

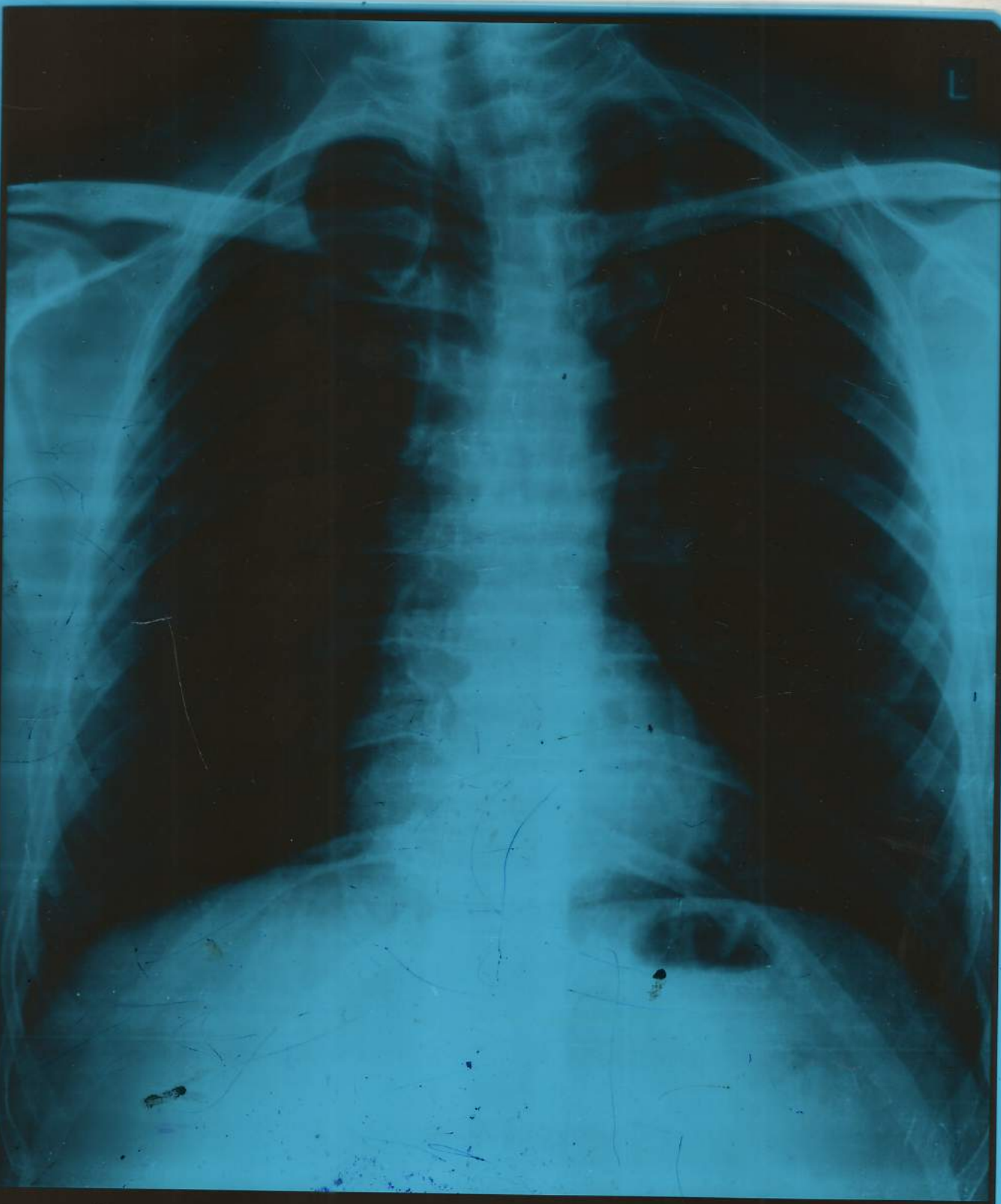500: Sinus Rhythm

Normal ECG

M.V.R. Murray

Report Confirmed by:





M V R MURTHY 48/M

Chest PA

12-Mar-22 9:38:18 AM

2203202

Male

MHC

SFNTINI HOSPITAL S. VIJAYAWADA