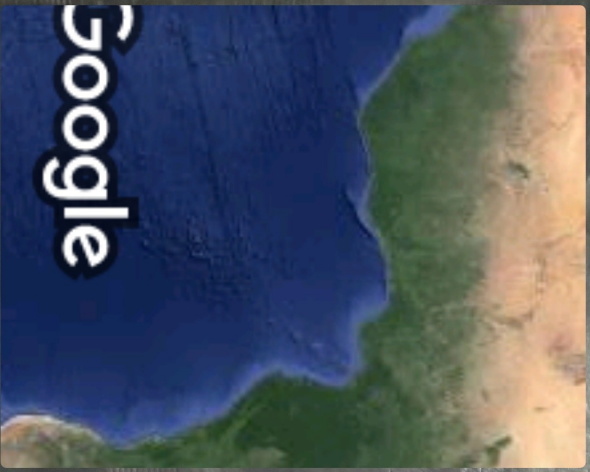



Google

Varanasi, Uttar Pradesh, India

44-B3, Durgakund, Bhelupur, Varanasi, Uttar Pradesh

221001, India

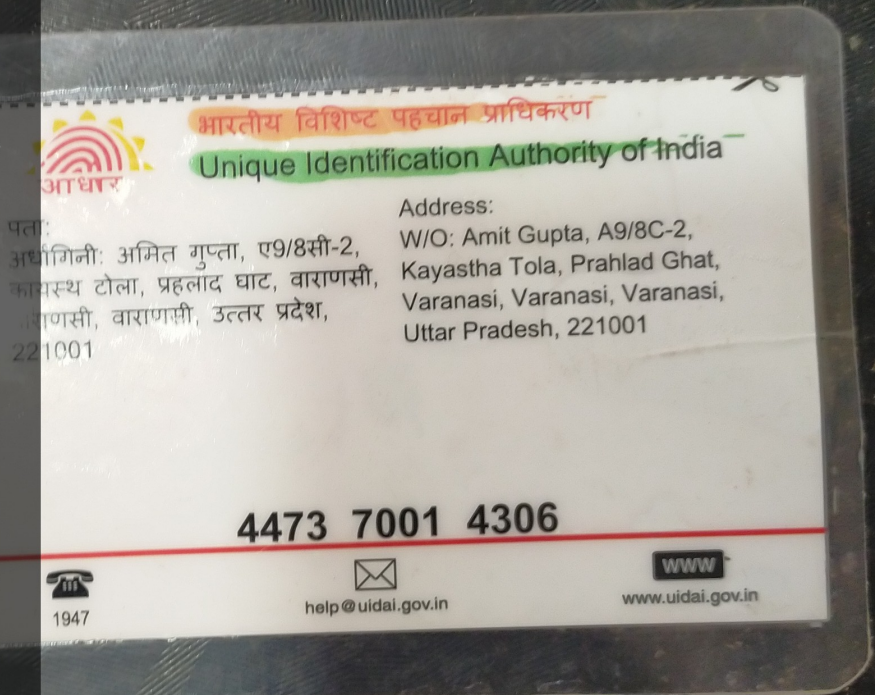
Lat 25.289209°

Long 82.99329°

05/04/23 09:45 AM GMT +05:30



GPS Map Camera



भारतीय विशिष्ट पहचान प्राधिकरण

Unique Identification Authority of India



पता:

अधिकािनी: अमित गुप्ता, ए9/8सी-2,
कायस्थ टोला, प्रहलाद घाट, वाराणसी,
वाराणसी, वाराणसी, उत्तर प्रदेश,
221001

Address:

W/O: Amit Gupta, A9/8C-2,
Kayastha Tola, Prahlad Ghat,
Varanasi, Varanasi, Varanasi,
Uttar Pradesh, 221001

4473 7001 4306



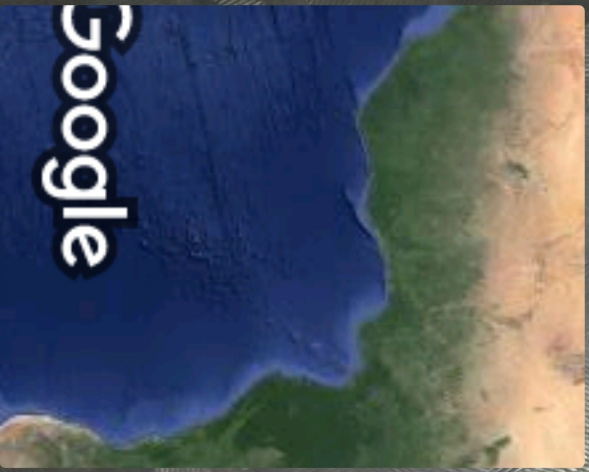1947



help@uidai.gov.in

www

www.uidai.gov.in



Varanasi, Uttar Pradesh, India

44-B3, Durgakund, Bhelupur, Varanasi, Uttar Pradesh

221001, India

Lat 25.289209°

Long 82.99329°

05/04/23 09:45 AM GMT +05:30



GPS Map Camera

Facilities:

All clinical Biomedical & Hematology Investigations including Bone Marrow Examination
 VPT, Podiascan & Complete Foot Care (First Time in Purvanchal)
 All Hormonal Investigation by Chemiluminescent Method
 Visceral Fat by (AB-140) Ambulatory BP Monitoring
 CGMS & Insulin Pump Available
 PFT, 2D-ECHO (Color Doppler), Holter, TMT, Cardiac-3 available
 VIA, VILI, Colposcopy available
 Special Endocrinological Investigation Protocols.

ISO 9001:2008 Certified
 Mobile: 9389994334, 9554572190, 9453837595



Panacea Pathology

Clinical Reference Lab

Persistence, Preparedness and Precision
 EQAS (CMC Vellore Attached) & IQAS System
 पूर्वांचल की सर्वोत्तम गुणवत्ता वाली पैथोलॉजी

PATIENT NAME : PREETI GUPTA

AGE/GENDER : 31YRS/FEMALE

REFD BY DR. : ARCO FEMI HEALTHCARE LTD.

RECEIVED DATE : 05-04-2023 (10:00 AM)

SAMPLE : BLOOD & URINE

REPORT DATE : 05-04-2023 (07:00 PM)

PATHOLOGY REPORT

COMPLETE BLOOD COUNT (CBC)

TEST	LAB TEST VALUES	NORMAL RANGE
HEMOGRAM		
HEMOGLOBIN (FLOW CYTOMETRY)	11.1	
TOTAL LEUCOCYTE COUNT (TLC)	8,100	13 – 16 gm/dl
RBC COUNT	4.14	4000 – 11000
PCV (HCT)	36.4	3.5 – 5.5
MCV	87.9	37 – 47
MCH	26.8	80 – 95
MCHC	30.5	28 – 34
PLATELET COUNT	2,26,000	30 – 36
E.S.R. (WINTROBE FIRST HOURS)	22.0	1,50,000 – 4,00,000
DIFFERENTIAL LEUCOCYTE		20 mm/1 st hr
NEUTROPHILS	59	
LYMPHOCYTES	37	40 – 75%
EOSINOPHILS	02	20 – 45%
MONOCYTES	02	1 – 6%
BASOPHILS	00	2 – 8%
		< 2 %

RANDOM/FASTING BLOOD SUGAR

TEST	LAB TEST VALUES	NORMAL RANGE
RBS/FBS		
RANDOM BLOOD SUGAR	98.0	125-140 mg/dl
FASTING BLOOD SUGAR	77.7	70-125 mg/dl

GLYCOSYLATED HEMOGLOBIN (HBA1C)

TEST	LAB TEST VALUES	NORMAL RANGE
HBA1C	5.3	Normal : <5.97 % Good Control : 5.97 – 6.81% Fair Control : 6.81 – 7.65% Poor Control : >7.65%

PAGE 1

PANACEA HOSPITAL

(UNIT OF AAROHYA HEALTH CARE PVT. LTD.)

M.D. Pathology

REG. NO. 1000

B.36/44, B-4, KABIR NAGAR

BURGARH, JALPAIGURI

WEST BENGAL

Lab Technician

Timing : 8.00 a.m. to 9.00 p.m. (Sunday 8.00 a.m. to 3.00 p.m.)

This Report is not valid for medico-legal purpose

Note: These tests have technical limitations. Clinico-pathological interpretation is necessary. In case of any disparity test

Facilities:

All clinical Biomedical & Hematology Investigations including Bone Marrow Examination
 VPT, Podiascan & Complete Foot Care (First Time in Purvanchal)
 All Hormonal Investigation by Chemiluminescent Method
 Visceral Fat by (AB-140) Ambulatory BP Monitoring
 CGMS & Insulin Pump Available
 PFT, 2D-ECHO (Color Doppler), Holter, TMT, Cardiac-3 available
 VIA, VILI, Colposcopy available
 Special Endocrinological Investigation Protocols.

ISO 9001:2008 Certified
 Mobile: 9389994334, 9554572190, 9453837595



Panacea Pathology

Clinical Reference Lab

Persistence, Preparedness and Precision
 EQAS (CMC Vellore Attached) & IQAS System
 पूर्वांचल की सर्वोत्तम गुणवत्ता वाली पैथोलॉजी

PATIENT NAME : PREETI GUPTA

AGE/GENDER : 31YRS/FEMALE

REFD BY DR. : ARCO FEMI HEALTHCARE LTD.

RECEIVED DATE : 05-04-2023 (10:00 AM)

SAMPLE : BLOOD & URINE

REPORT DATE : 05-04-2023 (07:00 PM)

PATHOLOGY REPORT

LIPID PROFILE, SERUM

TEST	LAB TEST VALUES	NORMAL RANGE
BLOOD CHEMISTRY		
TOTAL CHOLESTEROL (SERUM)	168.0	Desirable:- < 200 mg/dl Borderline:- 200 – 239 mg/dl High:- > 240 mg/dl
TRIGLYCERIDES (SERUM)	136.0	35 – 170 mg/dl
HDL CHOLESTEROL(SERUM)	44.0	35.30 – 79.50 mg/dl
LDL CHOLESTEROL (SERUM)	96.8	< 130 mg/dl
VLDL	27.2	< 40 mg/dl
CHOLESTROL/HDL RATIO	3.81	< 3.0 Low Risk Ratio 3.0 – 5.0 Avg Risk < 5.0 High Risk
LDL/HDL RATIO	2.20	< 3 Ratio

BLOOD GROUP

TEST	LAB TEST VALUES
BLOOD GROUP ABO & RH FACTOR	
BLOOD GROUP	"O"
RH FACTOR	POSITIVE

LIVER PROFILE TEST, SERUM

TEST	LAB TEST VALUES	NORMAL RANGE
BIO CHEMISTRY		
TOTAL BILIRUBIN	0.76	0.0 – 1.1 mg/dl
DIRECT BILIRUBIN	0.24	0.0 – 0.2 mg/dl
INDIRECT BILIRUBIN	0.52	< 0.90 mg/dl
SGOT (AST)	22.4	0 – 52 mg/dl
SGPT (ALT)	23.0	0 – 39 mg/dl
GGT (GYT)	18.6	< 55 U/L

THYROID PROFILE (T3, T4, TSH)

TEST	LAB TEST VALUES	NORMAL RANGE
THYROID FUNCTION TEST		
T3	1.16	0.60 – 1.81 ng/ml
T4	7.56	4.50 – 10.90 ug/dl
TSH	2.07	0.39 – 6.10 uIU/ml

PAGE 2

Lab Technician

Timing : 8.00 a.m. to 9.00 p.m. (Sunday 8.00 a.m. to 3.00 p.m.)

This Report is not valid for medico-legal purpose

Note: These tests have technical limitations. Clinico-pathological interpretation is necessary. In case of any disparity test

PANACEA HOSPITAL
 M.D. Pathology
 UNIT OF AARON HEALTH CARE PVT. LTD.)
 REG. NO. AL-1500
 DURGAKUND, VARANASI

Facilities:

All clinical Biomedical & Hematology Investigations including Bone Marrow Examination
VPT, Podiascan & Complete Foot Care (First Time in Purvanchal)
All Hormonal Investigation by Chemiluminescent Method
Visceral Fat by (AB-140) Ambulatory BP Monitoring
CGMS & Insulin Pump Available
PFT, 2D-ECHO (Color Doppler), Holter, TMT, Cardiac-3 available
VIA, VILI, Colposcopy available
Special Endocrinological Investigation Protocols.

ISO 9001:2008 Certified

Mobile: 9389994334, 9554572190, 9453837595

**Panacea Pathology****Clinical Reference Lab**

Persistence, Preparedness and Precision
EQAS (CMC Vellore Attached) & IQAS System
पूर्वाचल की सर्वोत्तम गुणवत्ता वाली पैथोलॉजी

PATIENT NAME : PREETI GUPTA

AGE/GENDER : 31YRS/FEMALE

REFD BY DR. : ARCO FEMI HEALTHCARE LTD.

RECEIVED DATE : 05-04-2023 (10:00 AM)

SAMPLE : BLOOD & URINE

REPORT DATE : 05-04-2023 (07:00 PM)

PATHOLOGY REPORT**RENAL & KIDNEY PROFILE, SERUM**

TEST	LAB TEST VALUES	NORMAL RANGE
RENAL FUNCTION TESTS		
BLOOD UREA NITROGEN (BUN)	10.0	10 – 50 mg/dl
SERUM CREATININE	0.72	0.60 – 1.60 mg/dl
URIC ACID	3.91	3.60 – 7.70 mg/dl
ALKALINE PHOSPHATASE (ALP)	71.0	142 – 353 mg/dl
TOTAL PROTEINS	7.40	0 – 39 mg/dl
ALBUMIN	4.20	3.8 – 5.4 mg/dl
SERUM GLOBULIN	3.20	2.1 – 3.5 mg/dl
AG RATIO	1.31	-
CALCIUM	9.75	8.80 – 10.20
PHOSPHORUS	3.24	2.50 – 5.00
SERUM SODIUM NA+	142.6	135.00 – 155.00 mEq/Ltr
SERUM POTASIAM K+	4.32	3.60 – 5.50 mEq/Ltr
ICALCIUM	1.24	1.10 – 1.35 mmol/L
SERUM CHLORIDE CL+	98.6	98.00 – 110.00 mEq/Ltr

URINE ROUTINE EXAMINATION

TEST	LAB TEST VALUES	NORMAL RANGE
PHYSICAL EXAMINATION		
QUANTITY	30	ML
COLOUR	STRAW	PALE YELLOW
APPEARANCE	CLEAR	CLEAR
SPECIFIC GRAVITY	1.015	1.01 – 1.03
PH	6.0	4.7 – 7.5
CHEMICAL EXAMINATION		
GLUCOSE	Not Detected	Not Detected
PROTEIN	NIL	Not Detected
MICROSCOPIC EXAMINATION		
PUS CELLS	01-02	0-5
RBC	Not Detected	Not Detected
EPITHELIAL CELLS	01-02	0-5
CASTS	Not Detected	Not Detected
CRYSTALS	Not Detected	Not Detected
BACTERIA	Not Detected	Not Detected

----- End of Report -----

Lab Technician

PANACEA HOSPITAL
M.D., Pathology
UNIT OF AAROHA HEALTH CARE PVT. LTD.)

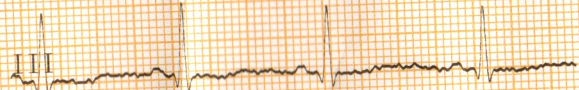
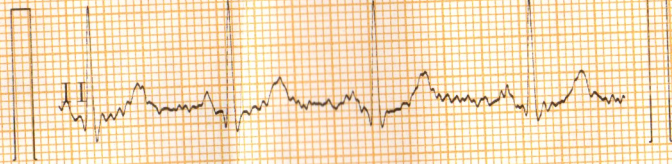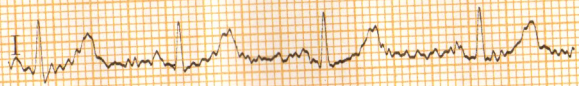
Timing : 8.00 a.m. to 9.00 p.m. (Sunday 8.00 a.m. to 3.00 p.m.)

This Report is not valid for medico-legal purpose

Note: These tests have technical limitations. Clinico-pathological interpretation is necessary in case of any discrepant test

REG. NO. AL1500
D-36/44, B-1, KABIR NAGAR
SURGAKUND, VARANASI

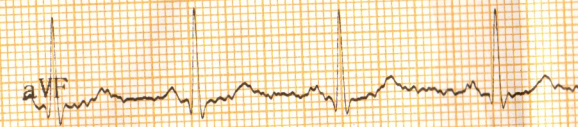

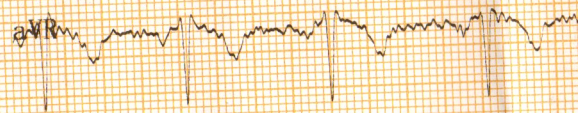
AUTO 20mm/mV



25mm/s AC50Hz+EMG25Hz+DFT

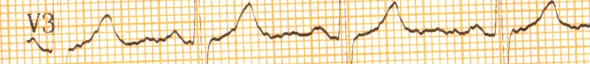
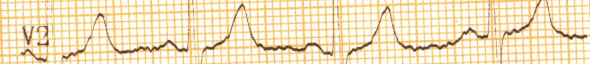
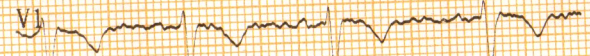CARDIART

20mm/mV

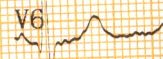



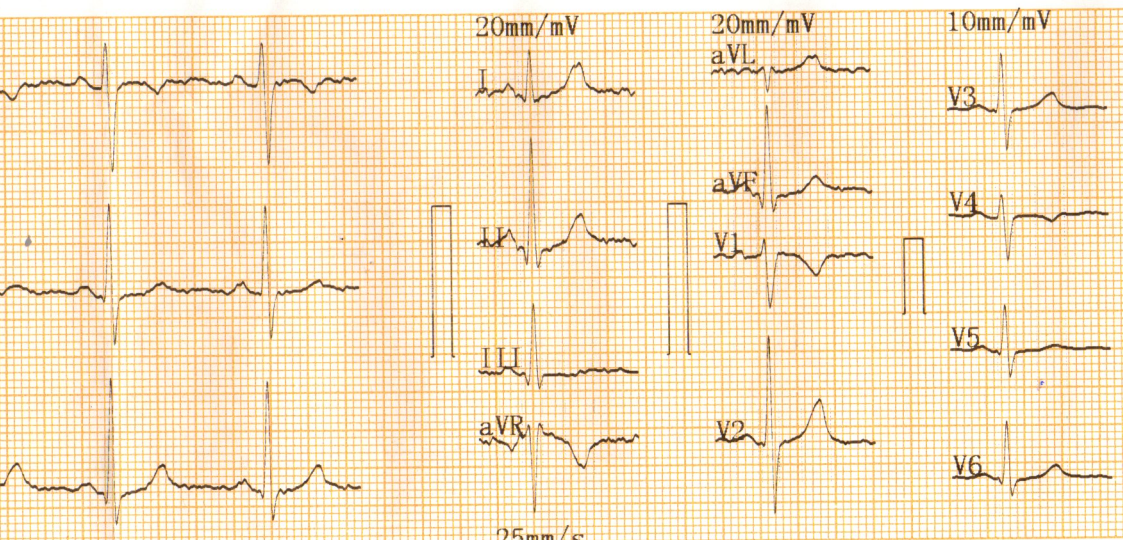
BPL

20mm/mV



20mm/mV





20mm/mV

20mm/mV

10mm/mV

25mm/s

CARDIART

2023-04-05 11:35

ID :
 Name : **PREETI GUPTA**
 Sex : **FEMALE** Age : **31 Yrs**
 Height : Weight : kg
 SYS :
 DIA :

HR bpm : 77
 PR Interval ms : 140
 P Duration ms : 120
 QRS Duration ms : 91
 T Duration ms : 157
 QT/QTc ms : 371/419
 P/QRS/T Axis deg : 46.7/66.2/29.7
 R(V5)/S(V1) mV : 0.62/0.34
 R(V5)+S(V1) mV : 0.96

BPL
 << Conclusions >>

Normal Sinus Rhythm;
 Cardiac electric axis normal;
 III V4 V5 Abnormal T wave;

****Report need physician confirm****

Pallavi
DR. PALLAVI MISHRA
 MBBS,MD (GENERAL MEDICINE)
 MCI Reg.No. 52033

Physician



Call Now - 1800-123-3070

PANACEA HOSPITAL

A shelter for many hearts A Home for many lives

(An ISO 9001:2008 Certified Organisation)

Lab Attached with CMC Vellore Under EQAS Scheme

PATIENT'S NAME : MRS.PREETI GUPTA
REF. BY : Dr. ASHUTOSH MISHRA(MD)
AGE/SEX: 31 Y/F
Wednesday, April 05, 2023

Echo - Cardiography


MITRAL VALVE Doppler	AML - normal morphology MV Flow - E - 0.8 A-0.6 E/A=1.38	PML - normal morphology MVA - 3.0 cm ² Mitral Regurgitation - No
TRICUSPID VALVE Doppler	Normal TV Flow -No	Tricuspid Regurgitation - No
PULMONARY VALVE Doppler	Normal PV Flow -No	Pulmonary Regurgitation - No
AORTIC VALVE Doppler	Trileaflet-No AV Flow - no	Aortic Regurgitation - no
MEASUREMENT	Aorta - 26.8 (20-38) mm IVS ed - 13.7 (6-12) mm LVID ed -53.1 (35-55) mm LVPW ed - 12.0 (6-12) mm OA - 7 (> 5) mm	LA - 29.7 (24-32) mm IVS es -14.3 (6-12) mm LVID es - 36.0 (24-40) mm LVPW es -15.4 (6-12) mm EPSS - 4 (< 9) mm

CONCLUSION All cardiac chamber dimensions are WNL
No valvular abnormalities
Normal LV systolic function present Modified Simpson's method (4C, 2C) (LVEF=60%)
No diastolic dysfunction present (E/A = 1.38) by tissue Doppler (E/e'=6.2)
No RWMA
No pericardial effusion
Intact IAS / IV
No PAH
No intra cardiac mass /thrombus /vegetation

IMPRESSION

Normal Echocardiogram

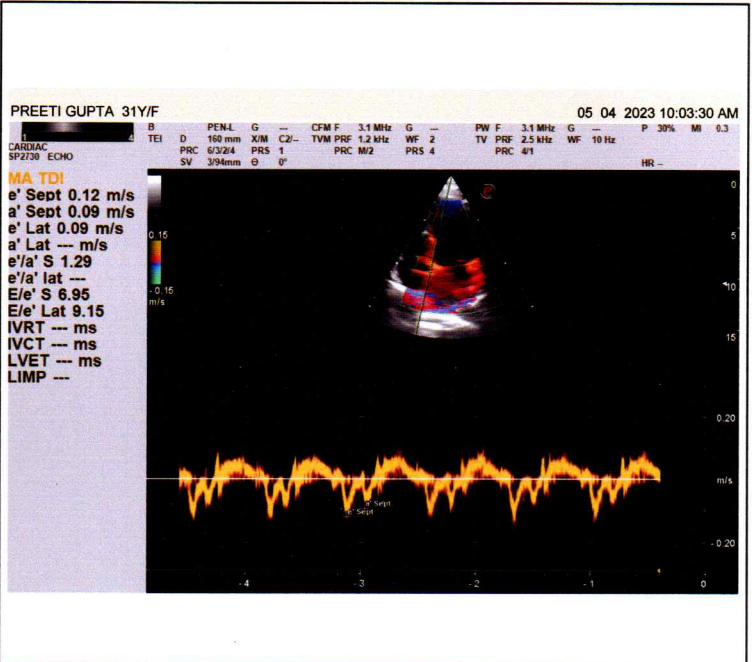
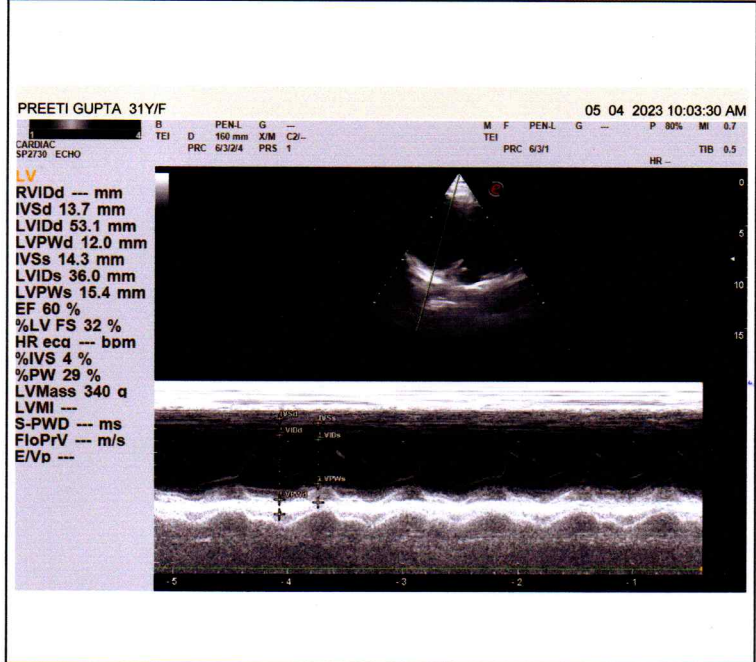
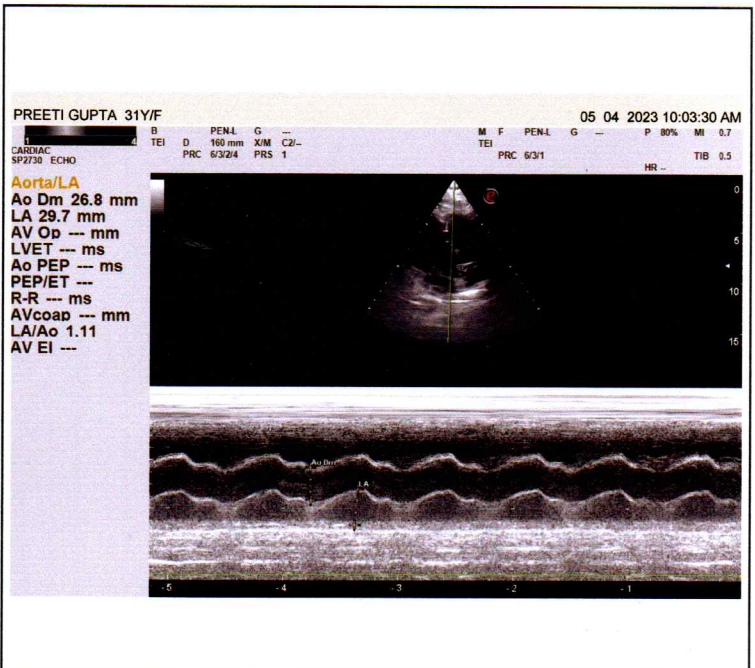
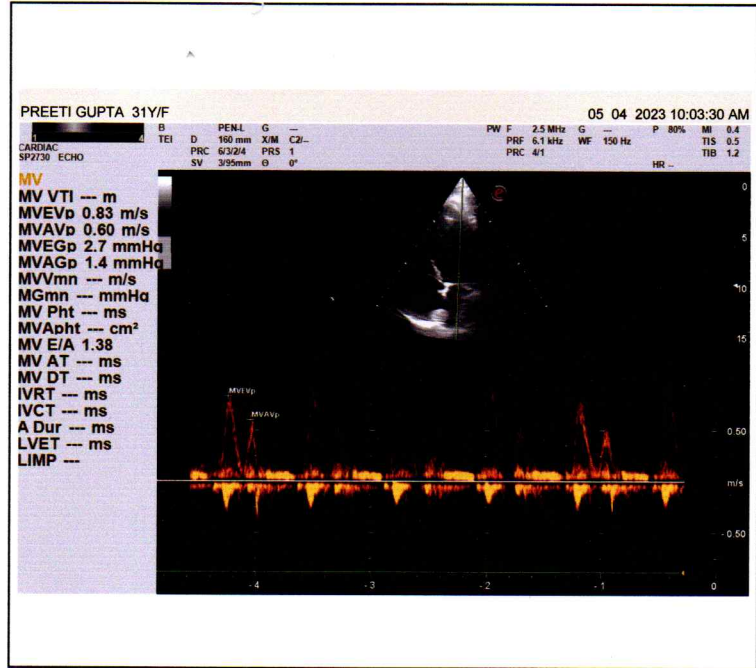

Niraj Mishra
Physician Assistant
(PIIRE)

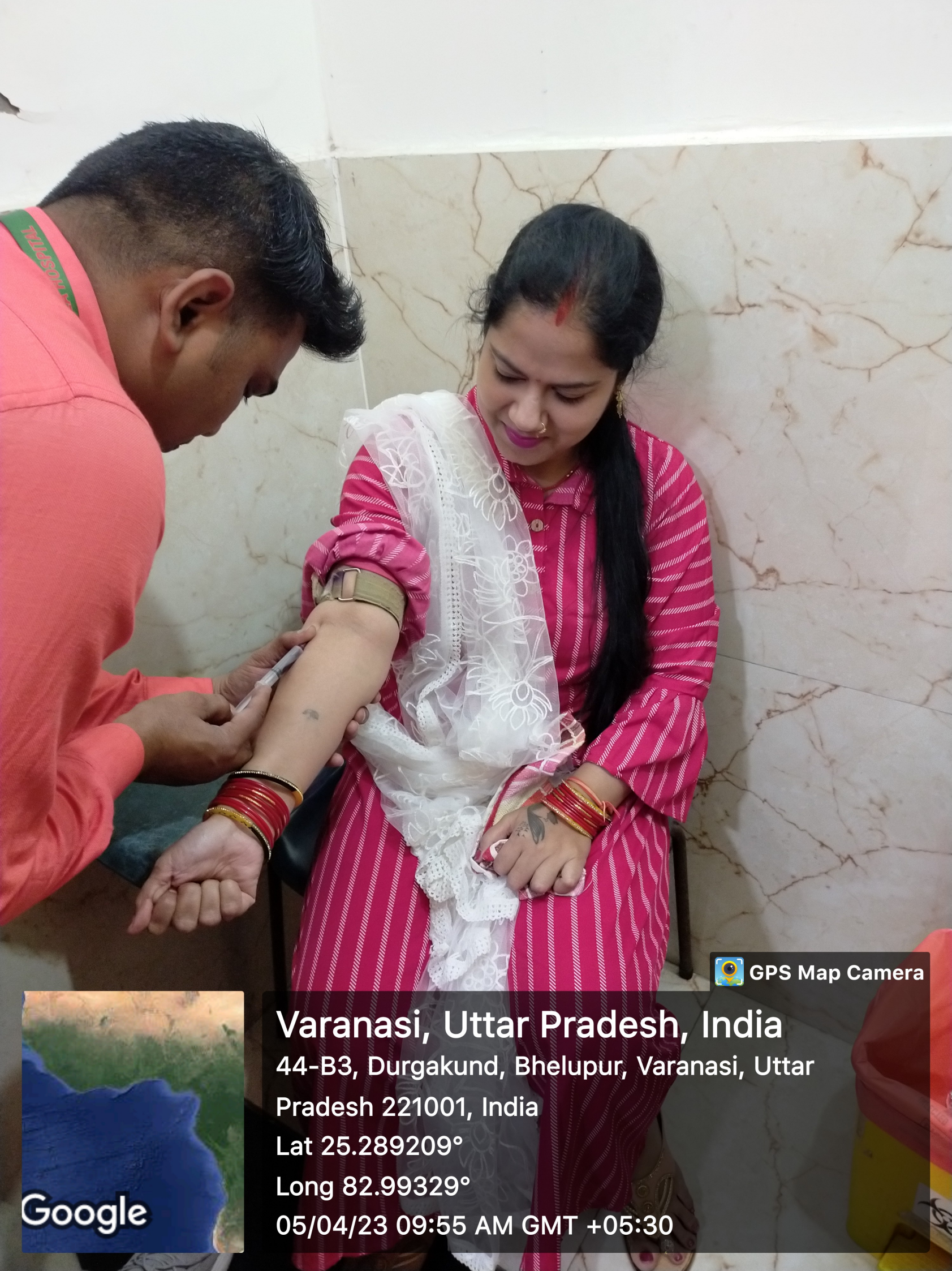
DR. PALLAVI MISHRA
MBBS, MD (GENERAL MEDICINE)
MCI Reg.No. 52033
Dr. Pallavi Mishra
MBBS, MD (MED) Lucknow
Echocardiography Specialist, MIAE
Non-invasive cardiologist
Women Cardiologist
Diabetocardiologist


Address : Kabir Nagar (Near Sanjay Shiksha Niketan), Durgakund, Varanasi

Mobile : 9554572190 / 9453837595 / Recpn. 9389994334

E-mail : dramishra@gmail.com, drpallaviojha@gmail.com, Website: www.piire.org





 GPS Map Camera

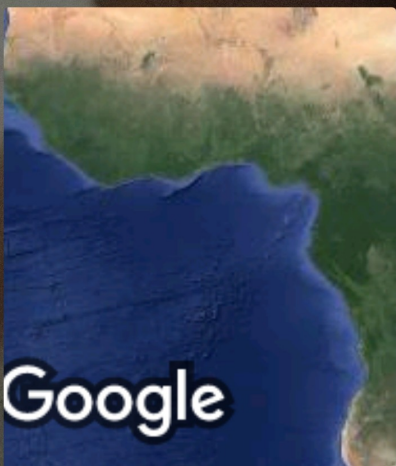Varanasi, Uttar Pradesh, India

44-B3, Durgakund, Bhelupur, Varanasi, Uttar Pradesh 221001, India

Lat 25.289209°

Long 82.99329°

05/04/23 09:55 AM GMT +05:30



Google

Panacea Hospital

Diabetes Care Organisation

A Sinner For Many Hear
Many Lives

महत्वपूर्ण सूचना
किसी भी अस्पताल/बर्निंग होम/
क्लीनिक/हिल्व सेक्टर में तोड़-फोड़
करना या डाक्टर एवं स्टाफ के साथ
अभद्र व्यवहार अथवा मारपीट
करना गैर जमानती अपराध है।
कानून
U.P. Medical Protection Act - 2013

1. शिकायत, घटना, संकेत की जानकारी अथवा
2. 3 घण्टे की समय में 20000- रूप प्रदान।
3. भारतीय कानून प्रचुर से मुफ्त की सेवकी परिचर को प्रदान।

सम्बन्धित अधिकार-अधिकार प्रकोष्ठ/प्रकार। आई.ए.ए. प्रारम्भिक

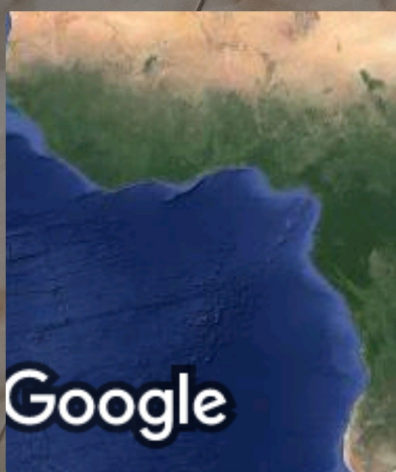EMPLOYEE GRIEVANCE PROCEDURE
EMPLOYEE GRIEVANCE
DISCUSS WITH HOD
APPROACH THE GRIEVANCE APPEALS COMMITTEE (GAC)
PLEASE WAIT FOR GAC DECISION
APPEAL TO NICE CHAIRMAN
LEGAL APPROACH

ओ. पी. डी. पंजीकरण
O.P.D. REGISTRATION

IPD BILLING

GPS Map Camera

Varanasi, Uttar Pradesh, India
44-B3, Durgakund, Bhelupur, Varanasi, Uttar
Pradesh 221001, India
Lat 25.289209°
Long 82.99329°
05/04/23 09:46 AM GMT +05:30





Call Now - 1800-123-3070

PANACEA HOSPITAL

A shelter for many hearts A Home for many lives


(An ISO 9001:2008 Certified Organisation)

Lab Attached with CMC Vellore Under EQAS Scheme

PATIENT'S NAME : PREETI GUPTA AGE/SEX: 31 Y/F
REF. BY : Dr. ASHUTOSH MISHRA(MD) Wednesday, April 05, 2023

U/S. WHOLE ABDOMEN

- LIVER** : Liver is normal in size, shape & echotexture. Intra hepatic biliary radicals are normal. Portal venous channels are normal.
- G. B.** : Gall bladder is normal in size, lumen is clear. Wall thickness normal.
- C.B.D.** : C.B.D. is normal in caliber.
- PANCREAS** : Pancreas is normal in size, shape and echotexture. No evidence of any inflammatory disease or mass.
- SPLEEN** : Spleen is normal in size, shape and echotexture.
- Rt. KIDNEY** : Normal in size, shape and echotexture. Renal sinus is normal
Cortico medullary differentiation is normal. P. C. system is normal.
- Lt. KIDNEY** : Normal in size, shape and echotexture. Renal sinus is normal
Cortico medullary differentiation is normal. P. C. system is normal.
- URI. BLADDER** : Urinary bladder is normal in size, position. Wall thickness normal.
No evidence of calculus or mass.
- UTERUS** : Normal in size, shape & echotexture. Endometrial echo is normal(5.0 cm).
- OVARIES** : Rt. Ovary:- Normal in size 33x22mm.
Lt. Ovary:-Normal in size 36x24mm.
No free fluid seen in P. O. D.
- IMPRESSION** : **NO OBVIOUS SONOLOGICAL ABNORMALITY SEEN**

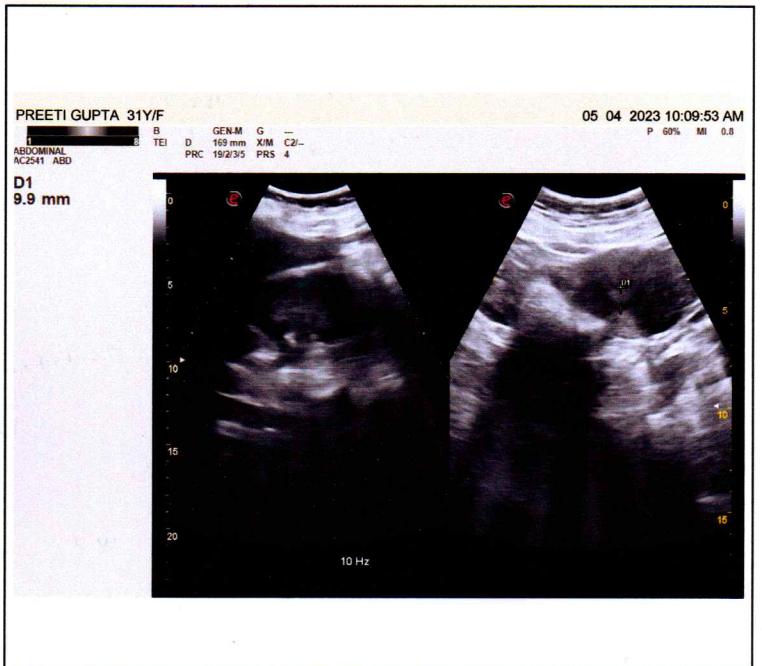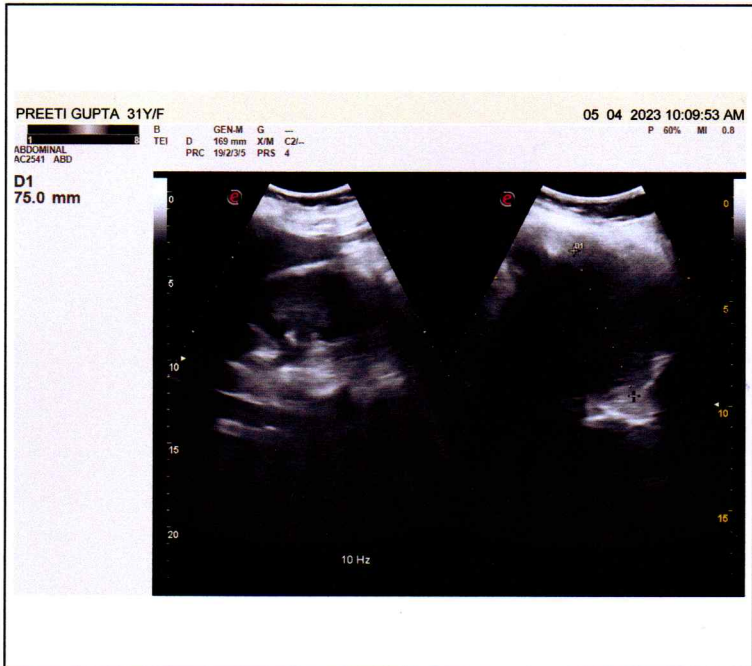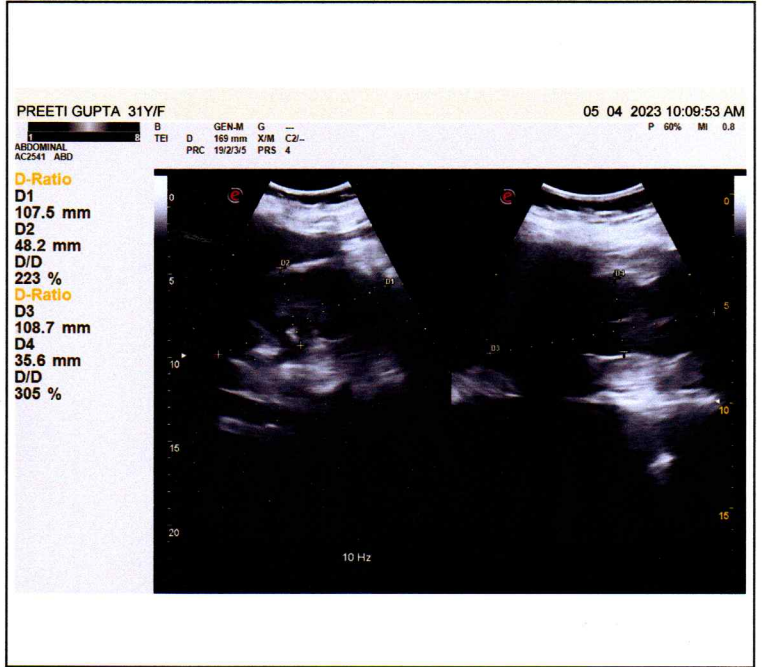
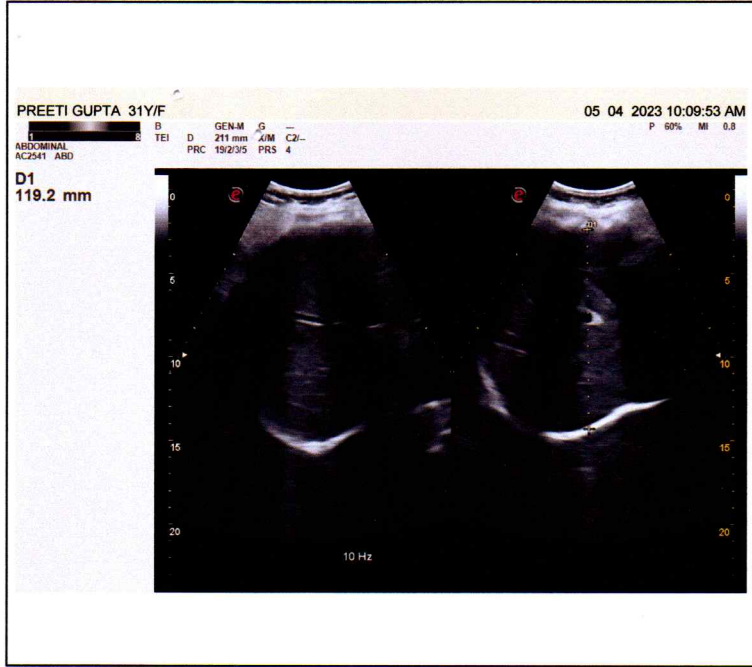

DR. R. K. TIWARI
Consultant radiologist
MBBS MD (GOLD MEDALIST)
King George Medical University, Lucknow

Thanks for reference.

Address : Kabir Nagar (Near Sanjay Shiksha Niketan), Durgakund, Varanasi

Mobile : 9554572190 / 9453837595 / Recpn. 9389994334

E-mail : dramishra@gmail.com, drpallaviojha@gmail.com, Website: www.piire.org





GPS Map Camera

Varanasi, Uttar Pradesh, India

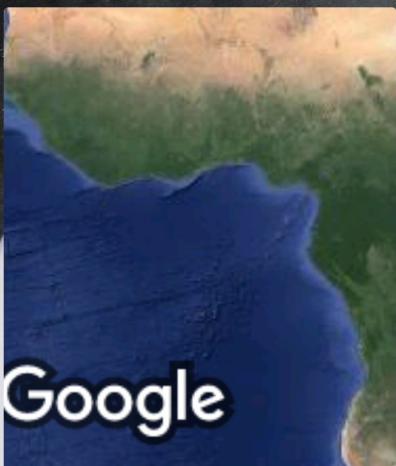44-B3, Durgakund, Bhelupur, Varanasi, Uttar

Pradesh 221001, India

Lat 25.289209°

Long 82.99329°

05/04/23 09:48 AM GMT +05:30



Google

TESTS
FOR FEM
Blood Group & Rh
Urine Sugar Fasting
and PP
Lipid Profile
Cholesterol



Call Now - 1800-123-3070

PANACEA HOSPITAL

A shelter for many hearts A Home for many lives

(An ISO 9001:2008 Certified Organisation)

Lab Attached with CMC Vellore Under EQAS Scheme

NAME: MRS. PREETI GUPTA

AGE/SEX: 31 YRS / FEMALE

REFBY: DR. ASHUTOSH MISHRA (MD)

DATE: 05/04/2023

X-RAY CHEST PA

BOTH LUNG FIELDS AND PLEURAE:

Both lungs show normal bronchovascular pattern.

Right & left hila are normal

No focal mass or calcification is seen

There is no evidence of any fluid in the both the pleural cavities.

Both domes of diaphragms are normal in position.

MEDIASTINUM:

Trachea is central in position.

Cardiac silhouette is of normal size and configuration.

No evidence of pericardial effusion.

No significant lymphadenopathy is seen.

Visualized skeleton is normal.

NO SIGNIFICANT RADIOGRAPHIC ABNORMALITY.

§
REPORTED BY

DR. Rahul Kumar Tiwari

MBBS, MD (Radio Diagnosis)

Reg.No. 57557

Address : Kabir Nagar (Near Sanjay Shiksha Niketan), Durgakund, Varanasi

Mobile : 9554572190 / 9453837595 / Recpn. 9389994334

E-mail : dramishra@gmail.com, drpallaviojha@gmail.com, Website: www.piire.org

R
PA

PREETI GUPTA 32Y/F 0 0 CHEST P.A. 05-Apr-23 11:03 AM

PANACEA HOSPITAL, KABIR NAGAR, DURGAKUND, VARANASI