



Name : Mr. KAILASH CHAND MEENA

Age/Gender: 38 Y/Male

Patient ID : 012202260021

BarcodeNo : 10037778

Referred By : Self

Registration No: 24856

Registered : 26/Feb/2022 09:11AM

Analysed : 27/Feb/2022 09:06AM

Reported : 27/Feb/2022 09:06AM

Panel : Medi Wheel (ArcoFemi
Healthcare Ltd)

DIGITAL X-RAY CHEST PA VIEW

Soft tissue shadow and bony cages are normal.

Trachea is central.

Bilateral lung field and both CP angle are clear.


Domes of diaphragm are normally placed.

Transverse diameter of heart appears with normal limits.

IMPRESSION:- NO OBVIOUS ABNORMALITY DETECTED.

*** End Of Report ***





Dr. Neera Mehta
M.B.B.S., D.M.R.D.
RMCNO.005807/14853

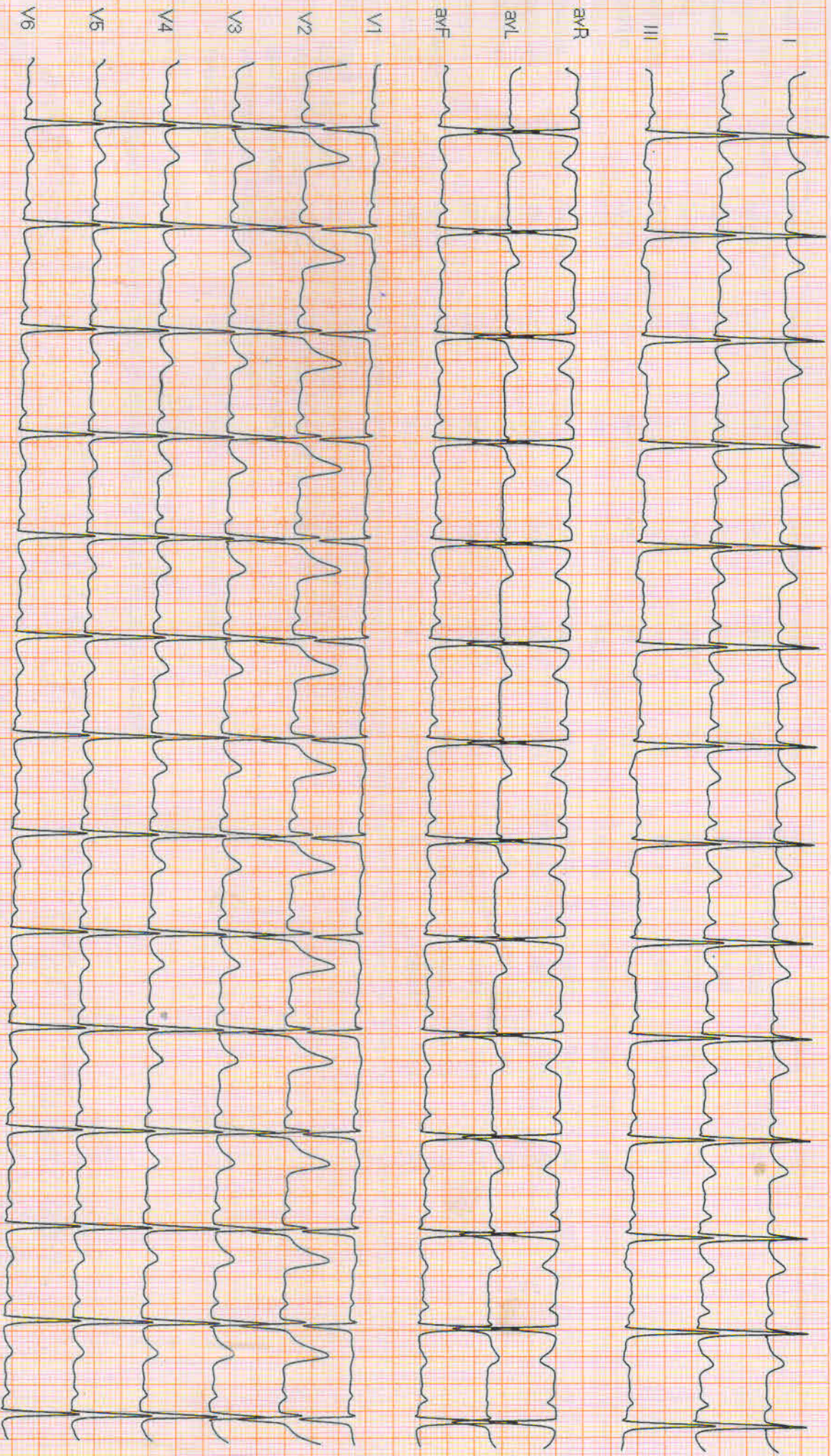
PATIENT NAME: MR KAILASH CHAND MEENA	AGE & SEX: 38Y/M
REF. by: MEDI WHEEL	DATE: 26.02.2022

USG: WHOLE ABDOMEN (Male)

- LIVER** : Is normal in size & shape with **bright** echogenecity.
The IHBR and hepatic radicals are not dilated.
No evidence of focal echopoor/echorich lesion seen.
Portal vein diameter and common bile duct appear normal.
- GALL** : Is normal in size, shape and echotexture. Walls are smooth and
BLADDER regular with normal thickness. There is no evidence of cholelithiasis.
- PANCREAS** : Is normal in size, shape and echotexture. Pancreatic duct is not dilated.
SPLEEN : Is normal in size, shape and echogenecity. Splenic hilum is not dilated.
- KIDNEYS** : Right Kidney:-Size: 101x42 mm, Left Kidney:-Size: 94x46 mm.
Bilateral Kidneys are normal in size, shape and echotexture,
corticomedullary differentiation is fair and ratio appears normal.
Pelvi calyceal system is normal. No evidence of hydronephrosis/ nephrolithiasis.
- URINARY** : Bladder walls are smooth, regular and normal thickness.
BLADDER : No evidence of mass or stone in bladder lumen.
- PROSTATE**: Is normal in size, shape and echotexture,
measures: 28x24x24 mm, wt: 8 gms.
Its capsule is intact and no evidence of focal lesion.
- SPECIFIC** : No evidence of retroperitoneal mass or free fluid seen in peritoneal cavity.
: NO evidence of lymphadenopathy or mass lesion in retroperitoneum.
: Visualized bowel loop appear normal. Great vessels appear normal.

IMPRESSION:- Fatty liver


DR NEERA MEHTA
MBBS, DMRD
RMCNO.005807/14853



Turn

Dr. NITIZ GOYAL
M.B.B.S., M.D.
RMC - 0233319
(GEM/21170525) Gemini A-DX by Allengers

	Time	Duration	Belt Speed (mph)	Elevation	METS	Rate	% THR Achieved	BP	RPP	PVC	Comments
Supine	00:03	0:01	01.1	00.0	01.0	90	49%	136/86	122	00	
Standing	00:06	0:01	00.0	00.0	01.0	86	47%	136/86	116	00	
HV	00:16	0:01	00.0	00.0	01.0	119	65%	136/86	161	00	
Warm Up	00:23	0:04	01.7	10.0	01.1	118	64%	136/86	160	00	
ExStart	00:25	0:06	01.7	10.0	01.1	122	67%	136/86	165	00	
BRUCE Stage 1	03:25	3:00	01.7	10.0	04.7	150	82%	136/86	204	00	
PeakEx	04:31	1:06	02.5	12.0	05.6	158	86%	136/86	214	00	
Recovery	05:30	1:00	00.0	00.0	01.0	121	66%	136/86	164	00	
Recovery	06:30	2:00	00.0	00.0	01.0	099	54%	164/81	162	00	
Recovery	07:30	3:00	00.0	00.0	01.0	094	51%	164/81	154	00	
Recovery	08:30	4:00	00.0	00.0	01.0	094	51%	164/81	154	00	
Recovery	08:33	4:02	00.0	00.0	01.0	093	51%	164/81	152	00	

Findings :

Exercise Time : 04:07
 Max HR Attained : 158 bpm 86% of Target 183
 Max BP Attained : (Sys) 164/81
 Max Workload Attained : 5.6
 Test End Reasons : Test Complete, Heart Rate Achieved

FINAL IMPRESSION - TEST IS NEGATIVE FOR INDUCIBLE ISCHAEMIA

POSITIVE
 ST-T changes in Recovery Phase
 seen
 - no vessel clinically
 Dr. NITIZ GOYAL
 M.B.B.S., M.D.
 RMC - 023319
 Doctor : DR. NITIZ GOYAL