



SUBHAM IMAGING & A.L.C. DIAGNOSTICS CENTRE

H.O. : Ajay Market, Bank of Baroda Building, East Ashok Nagar, Kankarbagh, Patna - 20

B.O. : Khanpura Road (Below Gyan Sharowar School), Paliganj, Patna.

e-mail : shubham.pat.usg@gmail.com # website : www.pkarogayamhealthcheckup.com

OPINION MUST BE CORRELATES WITH CLINICAL & OTHER INVESTIGATION FOR DIAGNOSIS NOT FOR MEDICO LEGAL PURPOSE

Pt. Name :- ARCHANA KUMARI

Ref. By :- DR. /BOB

Date:- 30-Mar-22

Age / Sex - Yrs. F.

Thanks for your kind referral

X-RAY CHEST (P.A. VIEW)

The lungs on the either side show equal translucency.

The peripheral pulmonary vasculature is normal.

No focal lung lesion is seen.

The pleural spaces are normal.

Both hila are normal in size, have equal density and bear normal relationship.

The heart and trachea are central in position and no mediastinal abnormality is visible.

The cardiac size is normal.

The domes of the diaphragms are normal in position, and show smooth outline.

IMPRESSION

- NO EVIDENCE OF PULMONARY OR CARDIAC PATHOLOGY IS NOTED.

Dr. Ranjeet Kumar
MBBS, PGDCC
Consultant Cardiologist
Consultant Radiologist
Reg. No. 48722

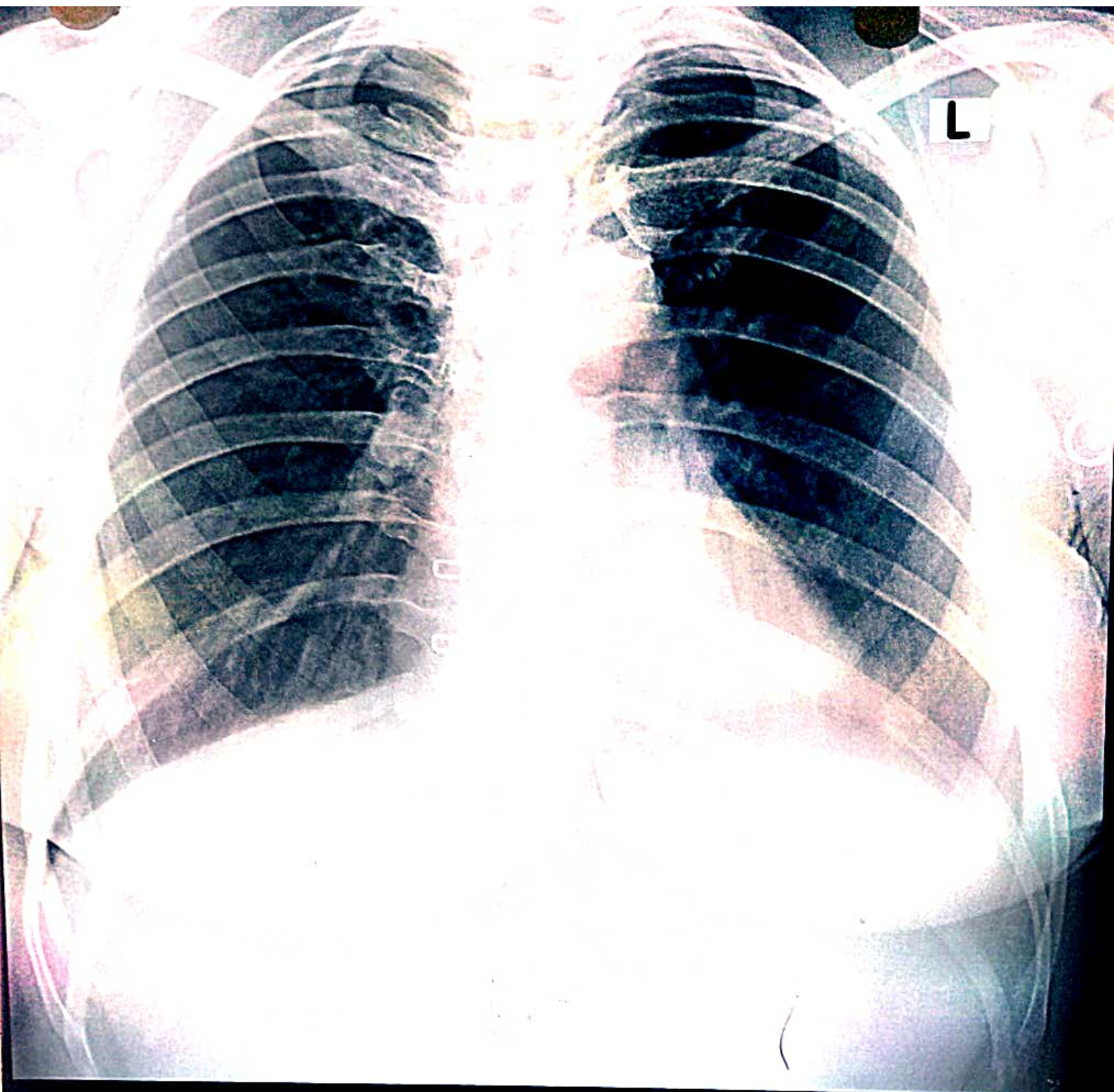
Y:-

P. K. Tiwari
M.Sc (Radio Imaging)
(Alt Nuclear Medicine)
Consultant Imagiologist & Sonologist

Dr. S. Kumar
MD, (Pat)
Consultant Pathologist

Dr. A. K. Singh
MBBS, PGDMCH
Consultant Radiologist & Sonologist

ING MISTAKE SHOULD BE REPORTED BACK IMMEDIATELY/ यहाँ जन्म से पहले भ्रुण का लिंग जाँच नहीं होता है ।



ARCHANA KUMARI AGE 28 YEARS 4317 RF BY DR. BOB CHEST,FRN P->A 3/30/2022
A.L.C. Advance Imaging Diagnostics Centre PATNA - 20

ID: 4317 CASE: 1
AGE: 28Y 0M 08D
5 CMS 57KG

ARCHANA KUMARI
FEMALE

30/03/2022 12:12:40
ALC ADVANCE IMAGING DIAGNOSTICS
E95 PC COLONY KANKARBAGH PATNA

RATE : 65 bpm SINUS RHYTHM
R-R : 910 ms POSSIBLE LEFT ATRIAL ABNORMALITY
P-R : 132 ms QRS CHANGES MAY BE DUE TO LVH BUT CANNOT RULE OUT ANTEROSEPTAL INFARCT
QRS : 66 ms
QT : 404 ms
QTc : 413 ms

--AXIS--
P : 39°
QRS : 54°
T : 39°
ABNORMAL ECG

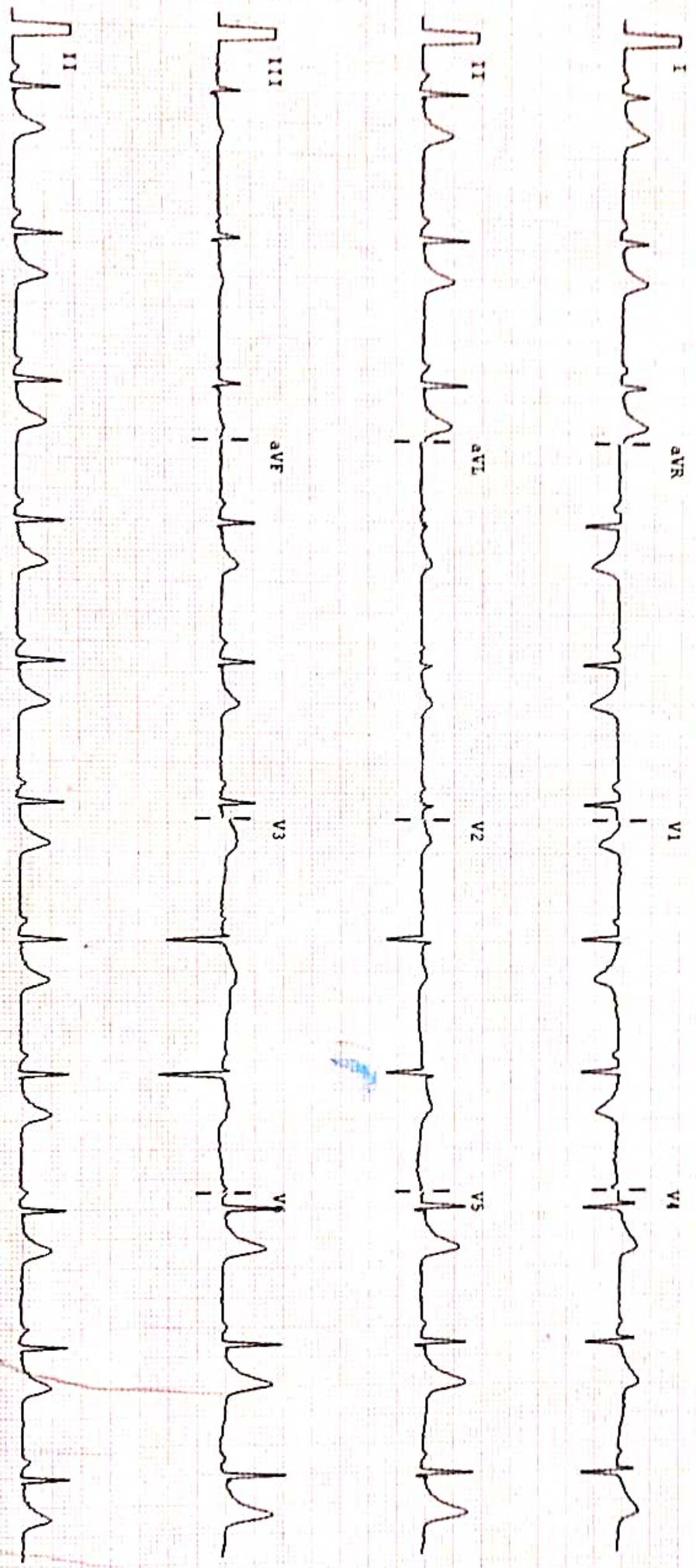
12 SL: REPORT FORMAT: 3X4+1L SQ

REF: DR B O B

Dr. Dr. ABHISHEK KUMAR MBBS MD



Dr. Abhishek Kumar
MBBS, MD





A.L.C. Advance Imaging Diagnostics

ISO 9001:2015 Certified Center

(A Unit of P.K. Argyam Health & Wellness Center)

E-95, P.C. Colony, Near Sai Netryalaya Transformer, Karkarbagh, Patna - 20

alcdiagnostics@gmail.com

www.pkargyamhealthcheckup.com

7511011111, 9271511111

OPINION MUST BE CORRELATES WITH CLINICALLY & OTHER INVESTIGATION FOR FINAL DIAGNOSIS. NOT FOR MEDICAL LEGAL PURPOSE.

PATIENT NAME : Mrs. ARCHANA

PATIENT ID: 4227

COL DATE : 30/03/2022

REPORTING DATE: 30/03/2022 AGE SEX: 72 YRS/F

REF.BY : DR / MEDIWHEAL

TEST NAME	RESULT	Unit	REF. RANGE
Total Triiodothyronin T3	1.04	ng/mL	0.80 - 2.00 ng/mL
Total Thyroxin T4	7.14	µg/dL	5.10 - 14.10 µg/dL
Serum TSH	1.38	µIU/mL	0.27 - 4.20 µIU/mL

THYROID DISORDER (>: Increase: < Decrease: n Normal

1. T3(n) T4(n) TSH(n) :EUTHYROID STATE:
2. T3(>) T4(>) TSH(<): HYPERTHYROIDISM:
3. T3(<)T4(<) TSH(>): HYPOTHYROIDISM:
4. T3(n)T4(n) TSH(>) : SUB-CLINICAL HYPO-THYROIDISM:
5. T3(n)T4(n) TSH(<): SUB-CLINICAL HYPER-THYROIDISM:
6. T3(>) T4(n) TSH(<): T3 THYROTOXICOSIS:

Total T3/T4 level is dependent on Level:

So determination of free T3/T4is a better MARKER of Thyroid Function.



Dr. Ankur Kumar
MBBS, MD
Consultant Radiologist
Reg. No 39540

Consultant Radiologist

ESTB BY:-

Dr. P. K. Tiwari
MD (Pat) Neurologist

Dr. S. Kumar
MD (Pat) Neurologist

Dr. Abhishek Kumar
MBBS, MD
Consultant Neurophysiologist

Dr. Anjali
MBBS, MD
Consultant (TMT, EEG Specialist)

Dr. Kumari Suman
MBBS, DGO, MD
Consultant (TVS & HSG Specialist)



A.L.C. Advance Imaging Dignostics

ISO 9001:2015 Certified Center

(A Unit of P.K. Arogyam Health & Wellness Center)

E-95, P.C. Colony, Near Sai Netryalaya Transformer, Kankarbagh, Patna - 20

alcdiagnostics@gmail.com

www.pkarogyamhealthcheckup.com

7030037694 8271206196

OPINION MUST BE CORRELATES WITH CLINICALLY & OTHER INVESTIGATION FOR FINAL DIAGNOSIS. NOT FOR MEDICO LEGAL PURPOSE

PATIENT NAME : Mrs. ARCHANA PATIENT ID: 4317
COL DATE : 30/03/2022 REPORTING DATE: 30/03/2022 AGE SEX:- 28 YRS/F
REF. BY : DS. / MEDIWHEEL.

TEST NAME	RESULT	Unit	REF.RANGE
ESR	5 mm/hr		<20 mm/hr
CBC			
Total W.B.C. Count	7000 /cumm		4000-11,000 /cumm
R B C COUNT	4.02 Million/ CUmm		4 - 7 Million/ CUmm
Platelets count	2.16 Lakh/ cumm		1.5-5.0 Lakh/ cumm
Differential Count of W.B.C.			
Neutrophils	63 %		40-70%
Lymphocytes	33 %		25-40%
Eosinophils	03 %		01-05%
Mnonocytes	01 %		00-02%
Basophiles	00 %		00-0%
HAEMOGLOBIN	11.3 gm/dl (77.3 %)		14.6 gm/dl = 100%
PCV	34.2 %		35-47 %
MCV	85.2 fl		76-96 fl
MCH	28.1 pg		29-35 pg
MCHC	33.0 %		30-38 %

ESTD BY:-

Dr. P. K. Tiwari
MD, M.Sc (Radio Imaging)
Ph.D (Ab Nuclear Medicine)
Consultant Imaginologist & Sonologist

Dr. S. Kumar
MD (Pat)
Consultant Pathologist

Dr. Abhishek Kumar
MBBS, MD
Consultant Neuropatho Physiologist

Dr. Anjali
MBBS, MD
Consultant(TMT,EEG Specialist)

Dr. Kumari Suman
MBBS, DGO, MD
Consultant (TVS & HSG Specialist)

Dr. Ankur Kumar
MBBS, MD
Consultant Radiologist
Reg No 39540



A.L.C. Advance Imaging Dignostics

ISO 9001:2015 Certified center

(A Unit of P.K. Arogyam Health & Wellness Center)

E-95, P.C. Colony, Near Sai Netryalaya Transformer, Kankarbagh, Patna - 20

alcdiagnostics@gmail.com

www.pkarogyamhealthcheckup.com

91222271494, 92712261194

OPINION MUST BE CORRELATES WITH CLINICALLY & OTHER INVESTIGATION FOR FINAL DIAGNOSIS. NOT FOR MEDICO LEGAL PURPOSE

PATIENT NAME : Mrs. ARCHANA PATIENT ID: 4317
COL DATE : 30/02/2022 REPORTING DATE: 12/03/2022 AGE SEX: 28 YRS/F
REF.BY : DR./ MEDIWHEEL

TEST NAME	RESULT	Unit	REF. RANGE
LFT:-			
SGPT	45.2	IU/L	5 - 48 IU/L
SGOT	30.0	IU/L	5 - 40 IU/L
ALKALINE PHOSPHATASE	96.1	IU/L	M - 53 - 165 U/L F - 42 - 136 U/L
TOTAL PROTIN	7.4	g/dl	6.0 - 8.7 g/dl
SERUM ALBUMIN	4.6	g/dl	3.5 - 5.4 g/dl
SERIUM GLUBLINE	2.8	g/dl	2.3 - 3.6 g/dl
AG RATIO	1.6	: 1	1.0 - 2.3 g/dl
BILIRUBIN			
TOTAL	0.54	mg/dl	0.1 - 1.1 mg/dl
IRECT	0.22	mg/dl	0.0 - 0.32 mg/dl
INDIRECT	0.32	mg/dl	0.0 - 0.78 mg/dl
KFT/RFT			
URIC ACID	4.3	mg/dl	3.2 - 7.0 mg/dl
SERUM CREATNINE	0.7	mg/dl	0.6 - 1.5 mg/dl
BLOOD URIA	31.0	mg/dl	5 - 45 mg/dl
BLOOD URIA NITROZEN(BUN).	14.4	mg/dl	13 - 39 mg/dl

Dr. Ankur Kumar
MBBS, MD
Consultant Pathologist
Reg. No 39540

Consultant Radiologist

ESTB BY:-

Dr. P. K. Tiwari
MD, M.Sc (Radio Imaging)
Ph.D (AI) Nuclear Medicine
Consultant Imaginologist & Sonologist

Dr. S. Kumar
MD (Pat)
Consultant Pathologist

Dr. Abhishek Kumar
MBBS, MD
Consultant Neuropatho Physiologist

Dr. Anjali
MBBS, MD
Consultant (TMT, EEG Specialist)

Dr. Kumari Suman
MBBS, DGO, MD
Consultant (TVS & HSG Specialist)

PRINTING MISTAKE SHOULD BE REPORTED BACK IMMEDIATELY/ यहाँ जन्म से पहले भ्रुण का लिंग जाँच नहीं होता है



A.L.C. Advance Imaging Dignostics

ISO 9001:2015 Certified center

(A Unit of P.K.Arogyam Health & Wellness Center)

E-95, P.C. Colony, Near Sai Netryalaya Transformer, Kankarbagh, Patna - 20

alcdiagnostics@gmail.com

www.pkarogyamhealthcheckup.com

7050037694, 8271206196

OPINION MUST BE CORRELATES WITH CLINICALLY & OTHER INVESTIGATION FOR FINAL DIAGNOSIS. NOT FOR MEDICO LEGAL PURPOSE

PATIENT NAME : Mrs. ARCHANA

PATIENT ID: 4317

COL DATE : 30/03/2022

REPORTING DATE: 30/03/2022

AGE SEX : 28 YRS/F

REF.BY : DR. /MEDIWHEEL.

TEST NAME	RESULT	Unit	REF.RANGE
BLOOD SUGAR (F)	98.0 mg/dl		70 - 110 mg/dl
LIPID PROFILE:-			
TOTAL CHOLESTROL	159.0 mg/dl		130 -250 mg/dl
TRIGLYCERIDE	108.6 mg/dl		50 -160 mg/dl
HDL CHOLESTROL	41.0 mg/dl		30 - 60 mg/dl
LDL CHOLESTROL	96.3 mg/dl		80 -130 mg/dl
VLDL CHOLESTROL	21.7 mg/dl		15 - 40 mg/dl
T.CH./HDL RATIO	3.8:1		Upto 5:1
LDL/HDL RATIO	2.3:1		2 - 4:1

Dr. Ankur Kumar
MBBS/MD
Consultant/Pathologist
Reg. No 39540

Consultant Radiologist

ESTD BY-

Dr. P. K. Tiwari
MD, M.Sc (Radio Imaging)
Ph.D (AI) Nuclear Medicine
Consultant Imagingologist & Sonologist

Dr. S. Kumar
MD (Pat)
Consultant Pathologist

Dr. Abhishek Kumar
MBBS, MD
Consultant Neuropatho Physiologist

Dr. Anjali
MBBS, MD
Consultant(TMT,EEG Specialist)

Dr. Kumari Suman
MBBS, DGO, MD
Consultant (TVS & HSG Specialist)

PRINTING MISTAKE SHOULD BE REPORTED BACK IMMEDIATELY/यहाँ जन्म से पहले भुन का लिंग जीव नहीं होता है ।



A.L.C. Advance Imaging Dignostics

ISO 9001:2015 Certified center

(A Unit of P.K.Arogyam Health & Wellness Center)

E-95, P.C. Colony, Near Sai Netryalaya Transformer, Kankarbagh, Patna - 20

alcdiagnostics@gmail.com

www.pkarogayamhealthcheckup.com

7990037694, 8271206196

OPINION MUST BE CORRELATES WITH CLINICALLY & OTHER INVESTIGATION FOR FINAL DIAGNOSIS. NOT FOR MEDICO LEGAL PURPOSE

PATIENT NAME : Mrs. ARCHANA

PATIENT ID: 4317

COL DATE : 30/03/2022 REPORTING DATE: 30/03/2022 AGE SEX : 28 YRS/F

REF.BY : DR./ MEDIWHEEL.

GLYCOSYLATED HEMOGLOBIN

TEST NAME	RESULT	Unit	REF.RANGE
HbA1c	3.9 %		Below 5.7 % : Normal 5.7 - 6.4 % : Prediabetic > = 6.5 % : Diabetic
AVERAGE PLASMA GLUCOSE	91.0 mg/dl		90 - 120 mg/dl : Good Control 121 - 150 mg/dl : Fair Control 151- 180 mg/dl: Unsatisfactory Control >180 mg/dl : Poor Control

Dr. Ankur Kumar
MBBS, MD
Consultant Pathologist
Reg. No 39540

Consultant Radiologist

ESTD BY:-

Dr. P. K. Tiwari

MD, M.Sc (Radio Imaging)
Ph.D (AI Nuclear Medicine)

Consultant Imaginologist & Sonologist

Dr. S. Kumar

MD (Pat)
Consultant Pathologist

Dr. Abhishek Kumar

MBBS, MD
Consultant Neuropatho Physiologist

Dr. Anjali

MBBS, MD
Consultant(TMT,EEG Specialist)

Dr. Kumari Suman

MBBS, DGO, MD
Consultant (TVS & HSG Specialist)

PRINTING MISTAKE SHOULD BE REPORTED BACK IMMEDIATELY/ यहाँ जन्म से पहले भ्रुग का लिंग जाँच नहीं होता है ।



A.L.C. Advance Imaging Dignostics

ISO 9001:2015 Certified center

(A Unit of P.K.Arogyam Health & Wellness Center)

E-95, P.C. Colony, Near Sal Netryalaya Transformer, Kankarbagh, Patna - 20

alcdiagnostics@gmail.com

www.pkarogyamhealthcheckup.com

7050037694, 8271206196

OPINION MUST BE CORRELATES WITH CLINICALLY & OTHER INVESTIGATION FOR FINAL DIAGNOSIS. NOT FOR MEDICO LEGAL PURPOSE

PATIENT NAME : Mrs . ARCHANA PATIENT ID: 4317
 COL DATE : 30/03/2022 REPORTING DATE: 30/03/2022 AGE SEX:- 28 YRS/F
 REF.BY : DR. / MEDIWHEEL.

ROUTINE EXAMINATION OF URINE

PHYSICAL EXAMINATION

Quantity	20 ml	Colour....	Straw
Appearance...	Clear	Sediment ...	Nil
Specific gravity....	1.010		

CHEMICAL EXAMINATION

Reaction	6.0	Nitrite.....	Not done
Sugar	Nil	Bile Pigment	Not done
Albumin	Nil	Urobilinogen....	Not done
Excess of Phosphate....	Nil	Chile.....	Not done
Bile Salt	Not Done	Acetone...	Not done

MICROSCOPIC EXAMINATION

Erythrocytes....	Nil	Casts	Nil
Leucocytes	1-4 / HPE	Crystals....	Nil
Epith. Cell	A, Few	Others	Nil

Dr. Ankur Kumar
 MBBS, MD
 Consultant Pathologist
 Reg. No. 39540

Consultant Radiologist

ESTD BY:-

Dr. P. K. Tiwari
 MD, M.Sc (Radio Imaging)
 Ph.D (Air Nuclear Medicine)
 Consultant Imaginologist & Sonologist

Dr. S. Kumar
 MD (Pat)
 Consultant Pathologist

Dr. Abhishek Kumar
 MBBS, MD
 Consultant Neuropatho Physiologist

Dr. Anjali
 MBBS, MD
 Consultant(TMT,EEG Specialist)

Dr. Kumari Suman
 MBBS, DGO, MD
 Consultant (TVS & HSG Specialist)

PRINTING MISTAKE SHOULD BE REPORTED BACK IMMEDIATELY/ यहाँ जन्म से पहले भ्रुण का लिग जाँच नहीं होता है ।



SUBHAM IMAGING & A.L.C. DIAGNOSTICS CENTRE

H.O. : Ajay Market, Bank of Baroda Building, East Ashok Nagar, Kankarbagh, Patna - 20

B.O. : Khanpura Road (Below Gyan Sharowar School), Paliganj, Patna.

e-mail : shubham.pat.usg@gmail.com # website : www.pkarogayamhealthcheckup.com

OPINION MUST BE CORRELATES WITH CLINICAL & OTHER INVESTIGATION FOR DIAGNOSIS NOT FOR MEDICO LEGAL PURPOSE

Pt. Name :- ARCHANA KUMARI

Ref. By :- DR. / BOB

Date:- 30-Mar-22

Age / Sex :- Yrs. F.

REAL TIME U.S.G. OF WHOLE ABDOMEN

Thanks for your kind referral

(Report.)

- LIVER** :- Measures 11.73 cm Normal in shape , size and echo texture.I.H.B.R. are not dilated Hepatic veins are normal No SOL seen.
- GBL** :- Lumen is echo free Wall thickness appears normal
- C.B.D.** :- Measures 3.3 mm in diameter with echo free lumen No calculi or mass seen.
- P.V.** :- Measures 7.2 mm in diameter. Appears normal. No thrombus seen.
- PANCREAS** :- Normal in shape, size and echo texture. No calcification mass seen.
- SPLEEN** :- Measures 9.80 cm. Normal in shape, size and echo texture. No SOL seen.
- KIDNEY** :- Both kidney shows normal shape, size & echotexture. C.M.D.intact. P.C.S is not dilated. No calculi, cyst or hydronephrosis seen on either side.
Right Kidney :- Measures 9.30 X 4.1 cm.
Left Kidney :- Measures 9.0 X 4.2 cm.
- URETER** :- Not dilated .No apparent calculi seen.
- U.BLADDER**:- Shows normal in outline with echo free lumen. No calculi or mass seen.
Pre void – 310 ml. Post void – is in significant
- UTERUS** :- Is Enlarged and bulky in size measures 9.30 X 6.10 cm and in Position Echogenicity of Myometrium is increased
Endometrial thickness is 8.2 mm IUCD seen in Uterine cavity
No focal mass lesion seen cervix appear normal.
- ADNEXA** :- Both ovary appears normal in size and shape.
Rt.Ovary Measures- 2.40 cm. Lt.Ovary Measures ovary – 2.60 cm.
- P.O.D** :- Mild collection seen in P.O.D.
- R.I.F.** :- Son graphically no appendicular mass or collection seen.
- OTHERS** :- No ascites , lymph adenopathy. No pleural effusion seen on either side

IMPRESSION

- **Enlarged Bulky Uterus With Intrauterine IUCD and Mild Collection Seen In POD -?PID**
- **Adv:-further work up other investigation**
Otherwise son graphically normal scan. of rest organs.

ESTD BY:-

Dr. P. K. Tiwari

MD, M.Sc (Radio Imaging)

Ph.D (Alt Nuclear Medicine)

Consultant Imaginologist & Sonologist

Dr. S. Kumar

MD. (Pat)

Consultant Pathologist

Dr. Ranjeet Kumar

MBBS, PGDS, CCBB, Consultant Radiologist

Consultant Cardiologist

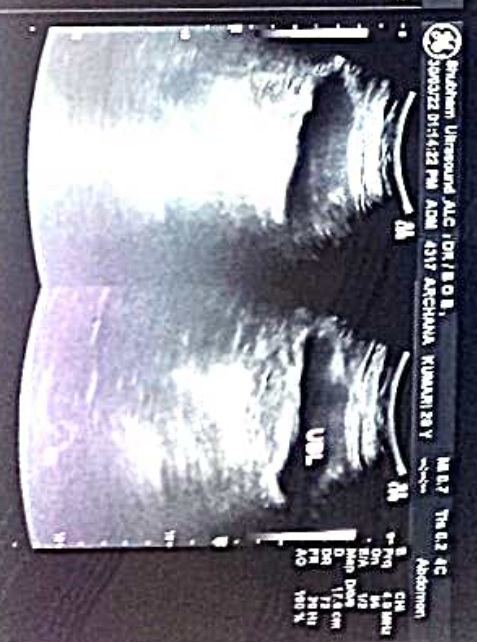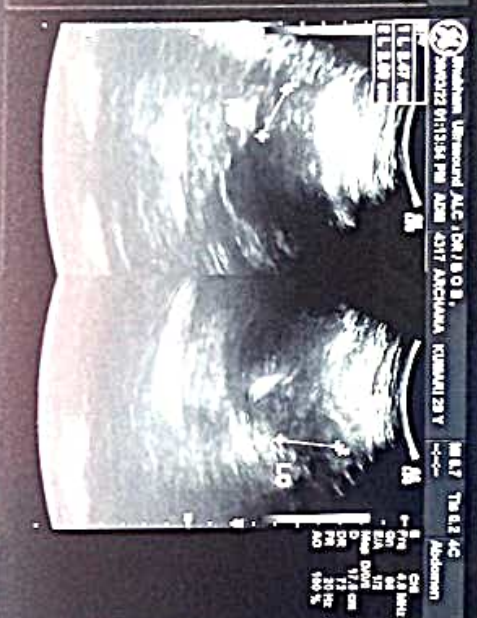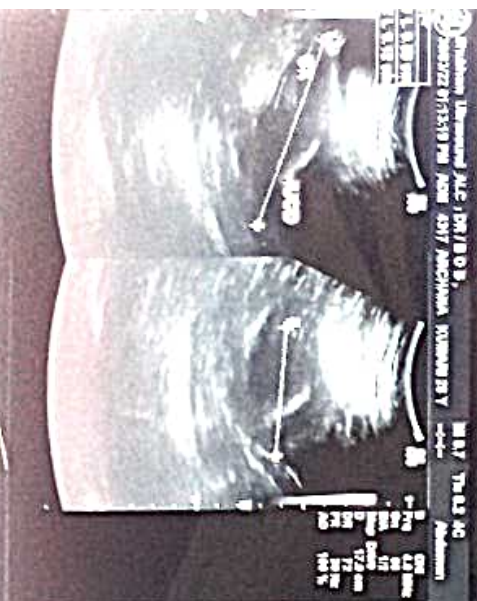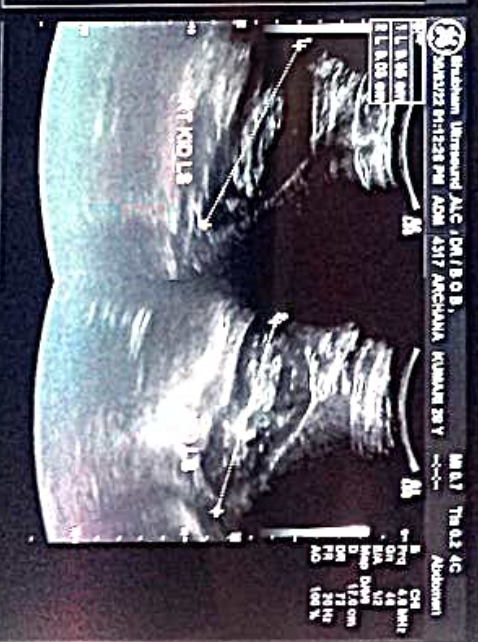
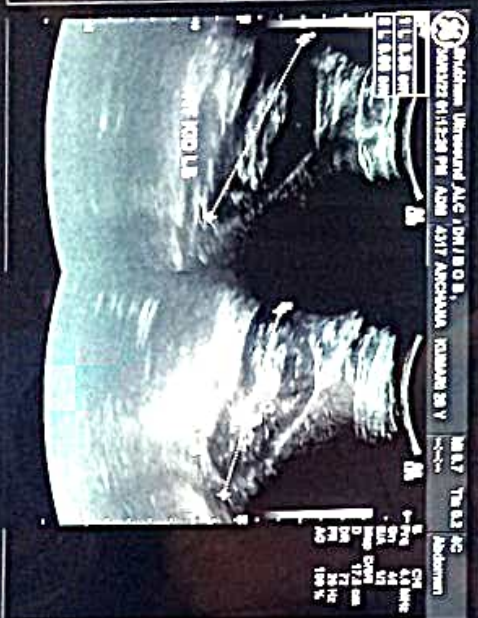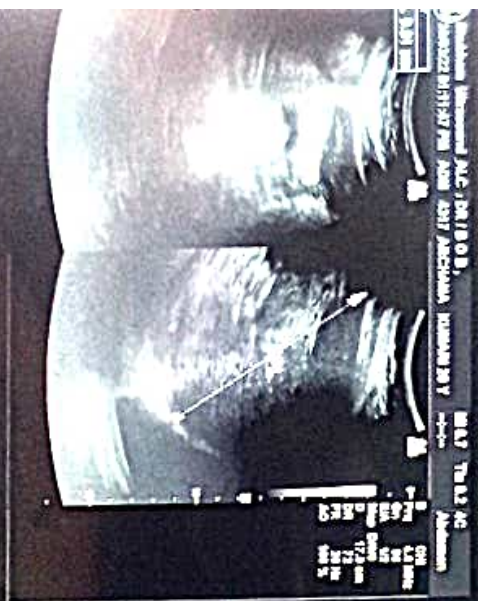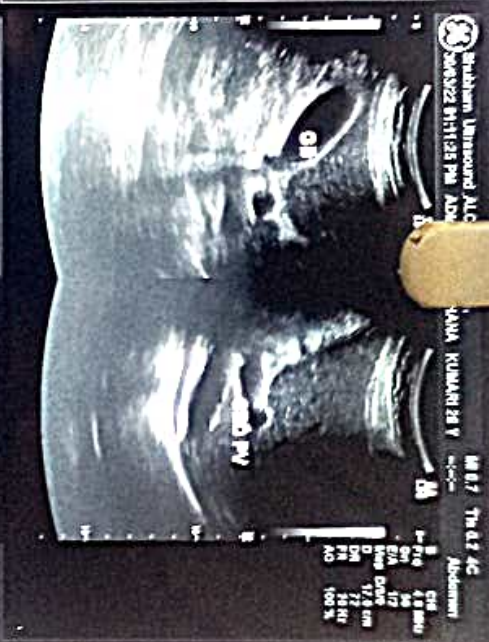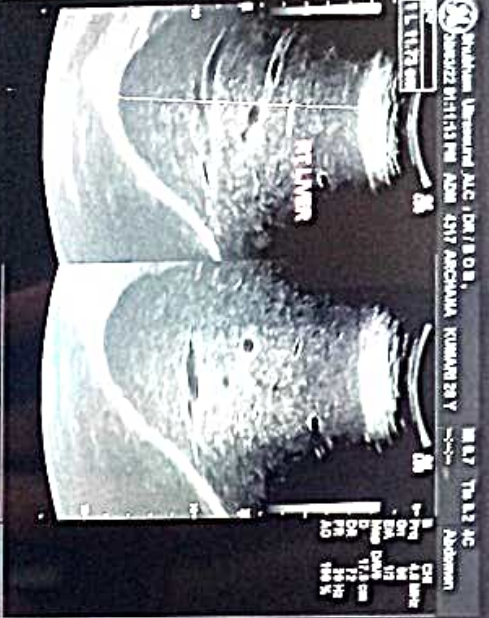
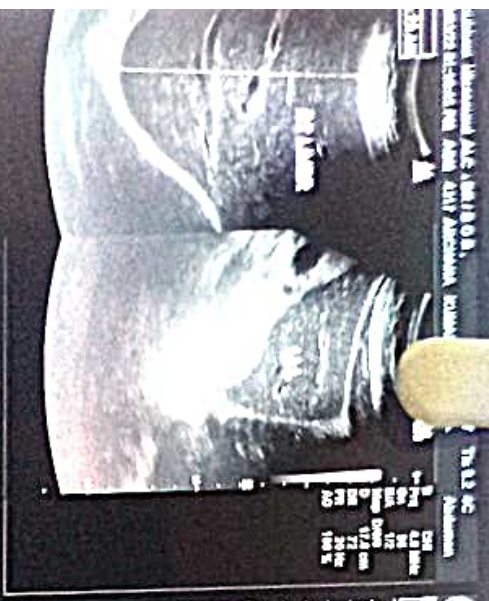Reg. No. 1870840 **A. K. Singh**

MBBS, PGDMCH

Consultant Radiologist & Sonologist

30/3/22

PRINTING MISTAKE SHOULD BE REPORTED BACK IMMEDIATELY/ यहाँ जन्म से पहले भ्रूण का लिंग जाँच नहीं होता है ।



ALC. MURKIN (including Diabetes Mellitus) (CANTO PATN-1)



Date: 30-Mar-2022 01:08:34 PM

Protocol: END TEST

	I	II	III	avR	avL	avF	V1	V2	V3	V4	V5	V6	I	II	III	avR	avL	avF	V1	V2	V3	V4	V5	V6	
STL(mm) Standing	1.2	2.1	0.9	-1.7	0.1	1.6	1.5	1.3	1.0	0.7	1.0	0.3	0.9	1.8	0.9	-1.3	0.0	1.3	1.0	1.0	1.0	0.8	0.6	0.9	0.4
60 @ms Warm Up	1.3	2.5	1.3	-1.9	0.0	1.9	1.7	1.7	1.2	0.7	1.2	0.4	1.2	2.3	1.1	-1.8	0.1	1.7	1.0	1.0	0.9	0.7	1.0	0.5	
ExStart	0.1	0.2	-0.1	-0.2	0.1	0.1	0.7	0.8	0.4	-0.1	0.3	0.0	-0.2	-0.1	0.1	0.1	-0.1	0.0	0.7	1.9	1.0	-0.2	0.6	-0.4	
Stage 1	0.5	0.7	0.3	-0.6	0.1	0.5	0.9	1.0	0.6	-0.2	0.5	-1.3	1.0	2.0	0.9	-1.5	0.1	1.5	1.4	2.0	1.2	0.4	1.2	-0.5	
Stage 2	0.1	-0.1	-0.2	0.0	0.1	-0.1	1.9	3.0	-0.1	0.0	-0.3	1.1	-0.6	0.1	0.8	0.3	-0.7	0.5	1.6	5.4	1.4	0.2	0.6	1.5	
PeakEx	-0.1	-0.7	-0.6	0.4	0.2	-0.6	0.2	0.7	-0.1	-0.5	-0.3	-0.5	0.0	0.4	0.4	-0.2	-0.2	0.4	0.7	2.6	1.6	0.1	1.0	0.1	
Recovery	0.4	0.6	0.2	-0.5	0.1	0.4	1.5	1.6	1.0	-0.2	0.5	-0.2	1.1	2.2	1.1	-1.6	0.0	1.6	1.6	2.0	1.6	0.5	1.3	0.4	
Recovery	0.4	0.6	0.2	-0.5	0.1	0.4	1.5	1.6	1.0	-0.2	0.5	-0.2	1.1	2.2	1.1	-1.6	0.0	1.6	1.6	2.0	1.6	0.5	1.3	0.4	
STI(μVs)	I	II	III	avR	avL	avF	V1	V2	V3	V4	V5	V6	I	II	III	avR	avL	avF	V1	V2	V3	V4	V5	V6	
Standing	10.3	19.0	8.7	-14.8	1.0	13.9	12.5	10.8	7.9	5.9	8.6	3.2	10.3	19.0	8.7	-14.8	1.0	13.9	12.5	10.8	7.9	5.9	8.6	3.2	
Warm-Up	10.4	20.4	10.1	-15.3	0.1	15.3	12.7	12.2	8.9	6.1	9.3	3.8	10.4	20.4	10.1	-15.3	0.1	15.3	12.7	12.2	8.9	6.1	9.3	3.8	
ExStart	1.0	0.9	-0.5	-1.1	0.9	0.2	3.3	3.7	1.2	-0.3	0.9	0.4	1.0	0.9	-0.5	-1.1	0.9	0.2	3.3	3.7	1.2	-0.3	0.9	0.4	
Stage 1	1.0	0.2	-0.3	-0.3	0.4	0.0	2.6	0.3	1.0	-2.3	1.0	-7.0	1.0	0.2	-0.3	-0.3	0.4	0.0	2.6	0.3	1.0	-2.3	1.0	-7.0	
Stage 2	1.5	-1.9	-3.4	0.2	2.4	-2.6	8.6	8.6	-2.0	-0.6	-3.0	3.8	1.5	-1.9	-3.4	0.2	2.4	-2.6	8.6	8.6	-2.0	-0.6	-3.0	3.8	
PeakEx	-1.6	-6.0	-4.3	3.8	1.3	-5.2	-0.7	0.7	-2.4	-3.5	-3.5	-3.5	-1.6	-6.0	-4.3	3.8	1.3	-5.2	-0.7	0.7	-2.4	-3.5	-3.5	-3.5	
Recovery	0.4	-0.6	-0.7	0.2	0.5	-0.7	5.6	5.9	3.0	-1.9	0.5	-1.6	0.4	-0.6	-0.7	0.2	0.5	-0.7	5.6	5.9	3.0	-1.9	0.5	-1.6	
Recovery	0.4	-0.6	-0.7	0.2	0.5	-0.7	5.6	5.9	3.0	-1.9	0.5	-1.6	0.4	-0.6	-0.7	0.2	0.5	-0.7	5.6	5.9	3.0	-1.9	0.5	-1.6	



E-95, PC COLONY KANKARBAGH PATNA-20

4037 / ARCHANA KUMARI / 27 Yrs / Female / 153 Cm / 57 Kg

Interval measurement Summary

Time (Min.)	HR (bpm)	PR Int (ms)	QRS Wid (ms)	QRS Axis (Deg)	QTc (ms)	P(V) (Max)	Q(V) (Max)	S(V) (Min)	T(V) (Max)	Min. J Leads for (V) (I & P)	Min. Post JRR Var (V)	VEB (Counts)	Missed Beats (Counts)
00:30	85	128	54	72	442	159	900	-657	516	4	-8	0	0
01:00	88	138	54	83	359	179	920	-606	428	125	-22	0	0
01:30	89	180	56	78	354	196	845	-628	345	150	-7	0	0
02:00	131	158	52	75	363	175	884	-662	253	157	-15	0	0
02:30	133	162	54	81	324	167	813	-631	252	12	-53	0	0
03:00	133	146	54	78	330	169	886	-665	253	128	-52	0	0
03:30	146	146	54	78	172	179	886	-656	311	193	-59	0	0
04:00	147	120	76	77	311	186	776	-651	272	33	-135	0	0
04:30	147	118	76	76	378	211	877	-656	284	62	-109	0	0
05:00	153	144	58	78	327	186	844	-710	370	1	-112	0	0
05:30	151	146	52	77	324	169	794	-692	274	166	-74	0	0
06:00	167	96	58	77	213	189	785	-680	187	-79	-121	0	0
06:30	167	132	70	77	297	193	771	-717	453	-21	-141	0	0
07:00	170	118	72	75	320	242	872	-692	438	381	-139	0	0
07:30	155	116	56	78	316	226	785	-773	286	6	-77	0	0

ACB

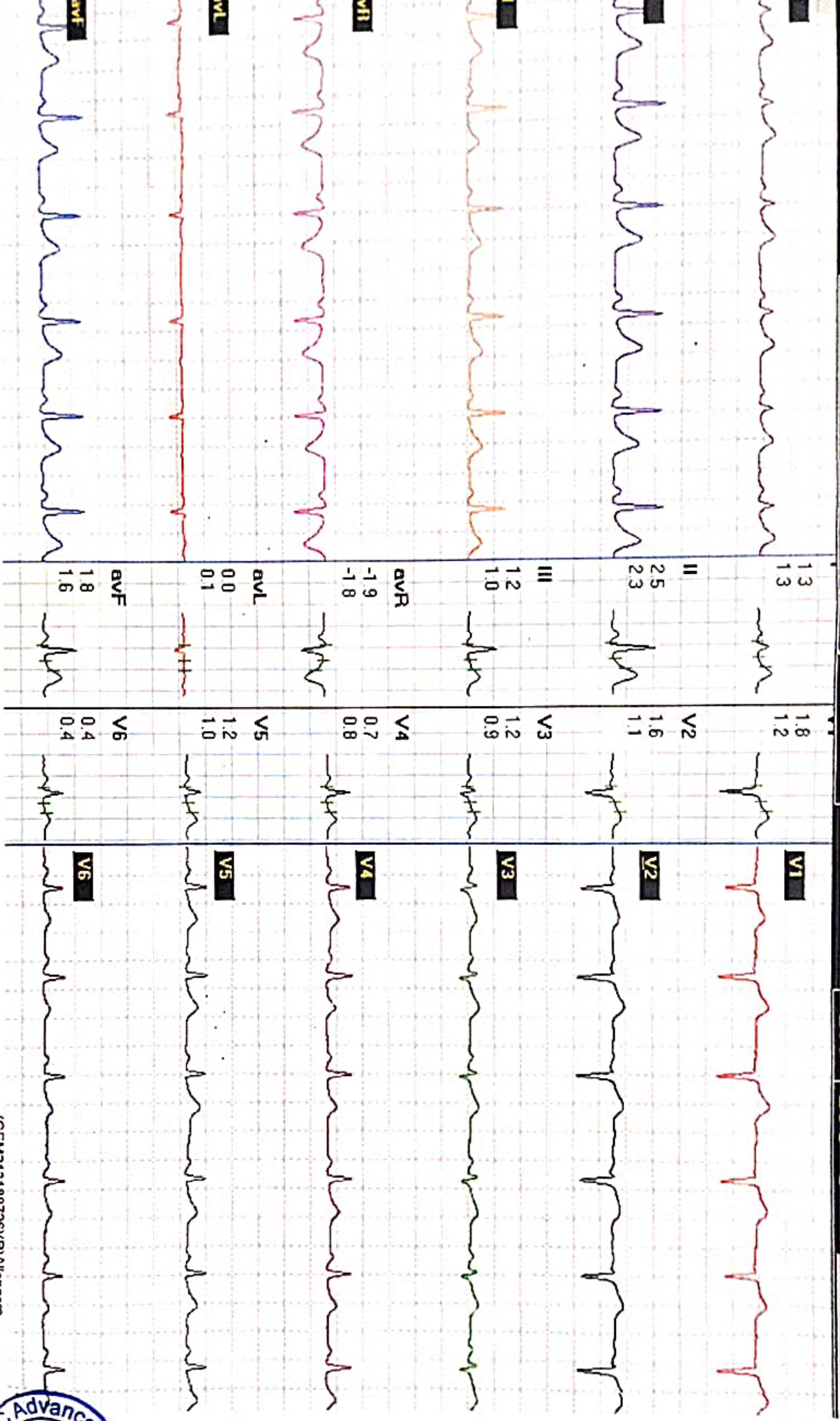
C. ADVANCE IMAGING DIGNOSTICS

12L+ MEDIAN



7 / ARCHANA KUMARI / 27 Yrs / F / 153 Cms / 57 Kg / HR : 95

30-Mar-2022 01:06:34 PM METS: 1.0/ 95 bpm 49% of THR BP: 120/80 mmHg mph, Raw ECG/ BLC On/ Notch On/ HF 0.05 Hz/LF 20 Hz ExTime: 00:27 0.0 mph, 0.0%



EM213180726(R)Allengers

(GEM213180726(R)Allengers



C. ADVANCE IMAGING DIGNOSTICS

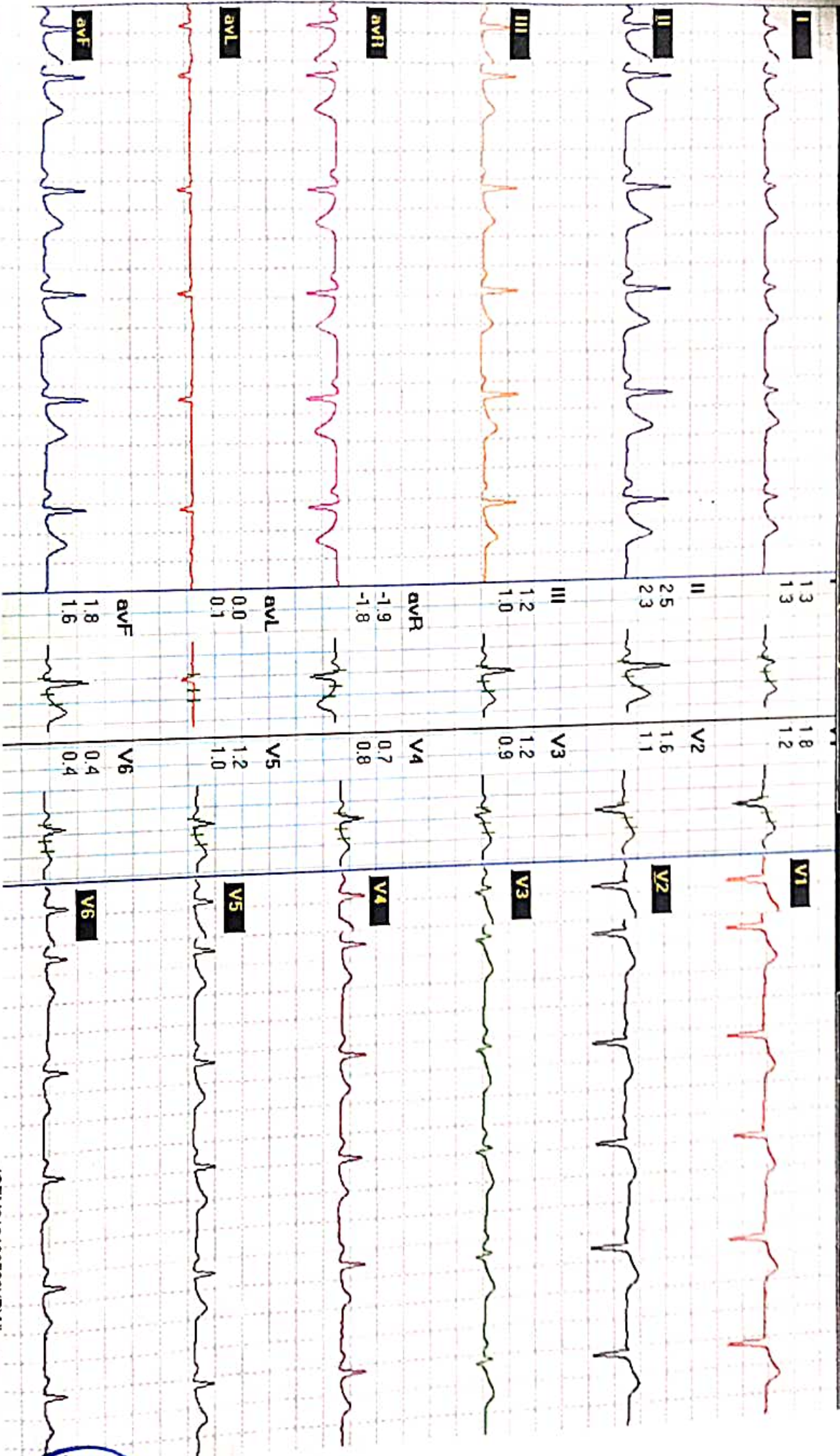
12L+ MEDIAN



037 / ARCHANA KUMARI / 27 Yrs / F / 153 Cms / 57 Kg / HR : 84

Date: 30-Mar-2022 01:06:34 PM METS: 1.0/ 84 bpm 43% of THR BP: —/— mmHg mph, Raw ECG/ BLC On/ Notch On/ HF 0.05 Hz/LF 20 Hz

ExTime: 00:19 0.0 mph, 0.0%



(GEM213180726)(R)Allengers

(GEM213180726)(R)Allengers



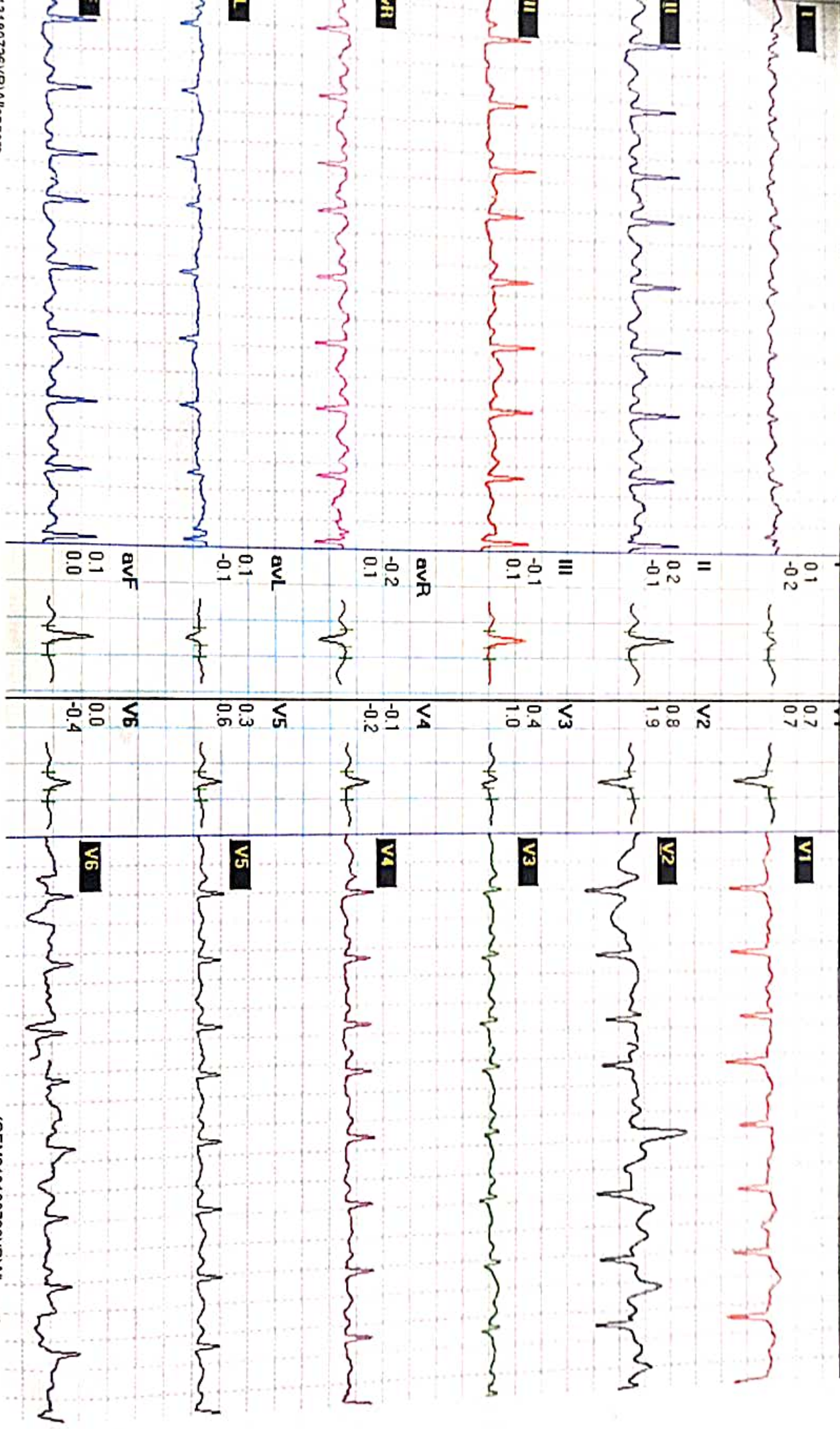
C. ADVANCE IMAGING DIAGNOSTICS

12L+ MEDIAN



037 / ARCHANA KUMARI / 27 Yrs / F / 153 Cms / 57 Kg / HR : 134

Date: 30-Mar-2022 01:06:34 PM METS: 1.1/ 134 bpm 69% of THR BP: 120/80 mmHg mph, Raw ECG/ BLC Ov Noich Ov/ HF 0.05 Hz/LF 20 Hz ETime: 00:05 1.7 mph, 10.0%



3180726(R)Allengers

(GEM213180726)(R)Allengers



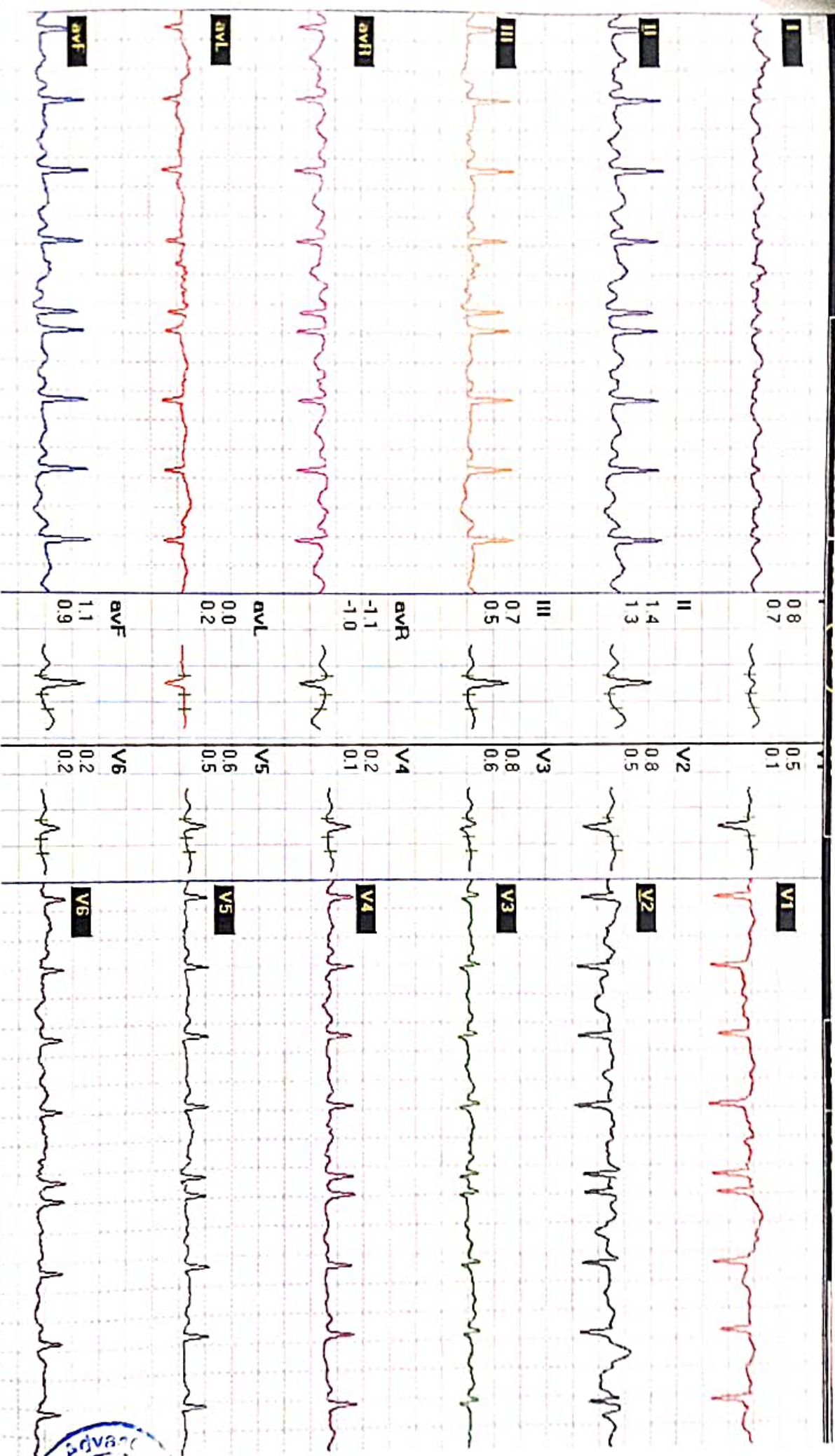
C. ADVANCE IMAGING DIAGNOSTICS

12L + MEDIANS



037 / ARCHANA KUMARI / 27 Yrs / F / 153 Cms / 57 Kg / HR : 124

Date: 30-Mar-2022 01:06:34 PM METS: 1.0/ 124 bpm 64% of THR BP: 120/80 mmHg mph, Raw ECG/ BLC On/ Notch On/ HF 0.05 Hz/LF 20 Hz ExtTime: 01:25 1.0 mph, 0.0%



(GEM213180726)(R)Allengers

(GEM213180726)(R)Allengers



A.L.C. ADVANCE IMAGING DIAGNOSTICS

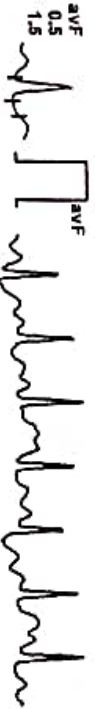
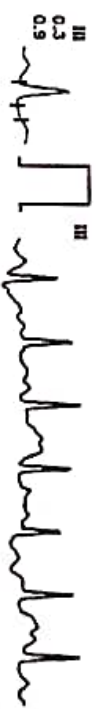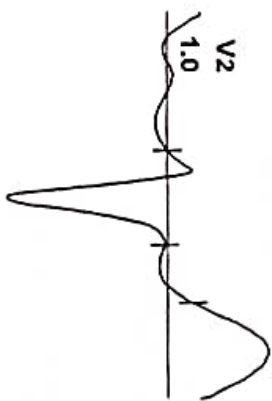
4037 / ARCHANA KUMARI / 27 Yrs / F / 153 Cms / 57 Kg / HR : 145

Date: 30-Mar-2022 01:06:34 PM METS 4.7/145 bpm 75% of THR BP 130/89 mmHg Raw ECG/ ELC On/Match On/ HF 0.05 Hz/ LF 20 Hz
 4X 60 ms Post J

BRUCE: Stage 1(3:00)

ACD

EFT: 03:56 1.7 mV 10.0%
 25 mm/Sec. 1.5 Cm/mV



(GEM213180726)(R)Allengers

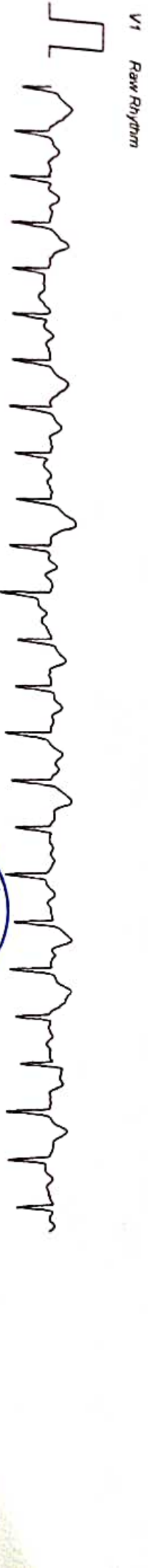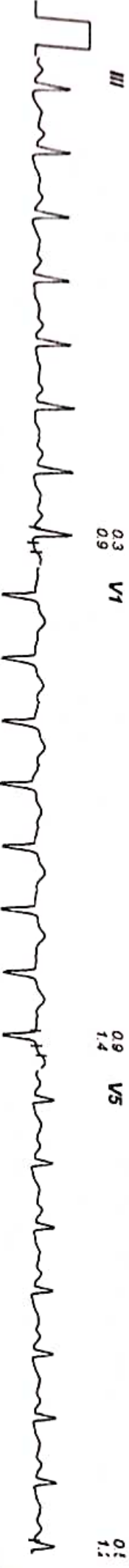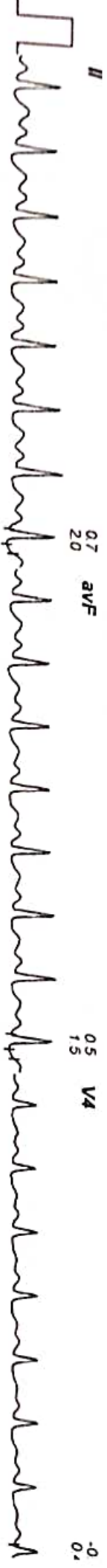A.L.C. ADVANCE IMAGING DIAGNOSTICS

E-95, P.C COLONY KANKARBAGH PATNA-20
4037 / ARCHANA KUMARI / 27 Yrs / Female / 153 Cm / 57 Kg

Date: 30/03/2022 01:06:34 PM METS: 0470 HR: 145 Target HR: 75% of 193 BP: 130/89 Post J @ 100mSec ExtTime: 03:00 1.7 mph Grade 10.00% 25 mm/Sec 1.0 Cm/mV

Linked Medians Report
BRUCE: Stage 1(3:00)

ACHP



Allegors Global Healthcare Pvt. Ltd (GEM213180726)(R)Allegors

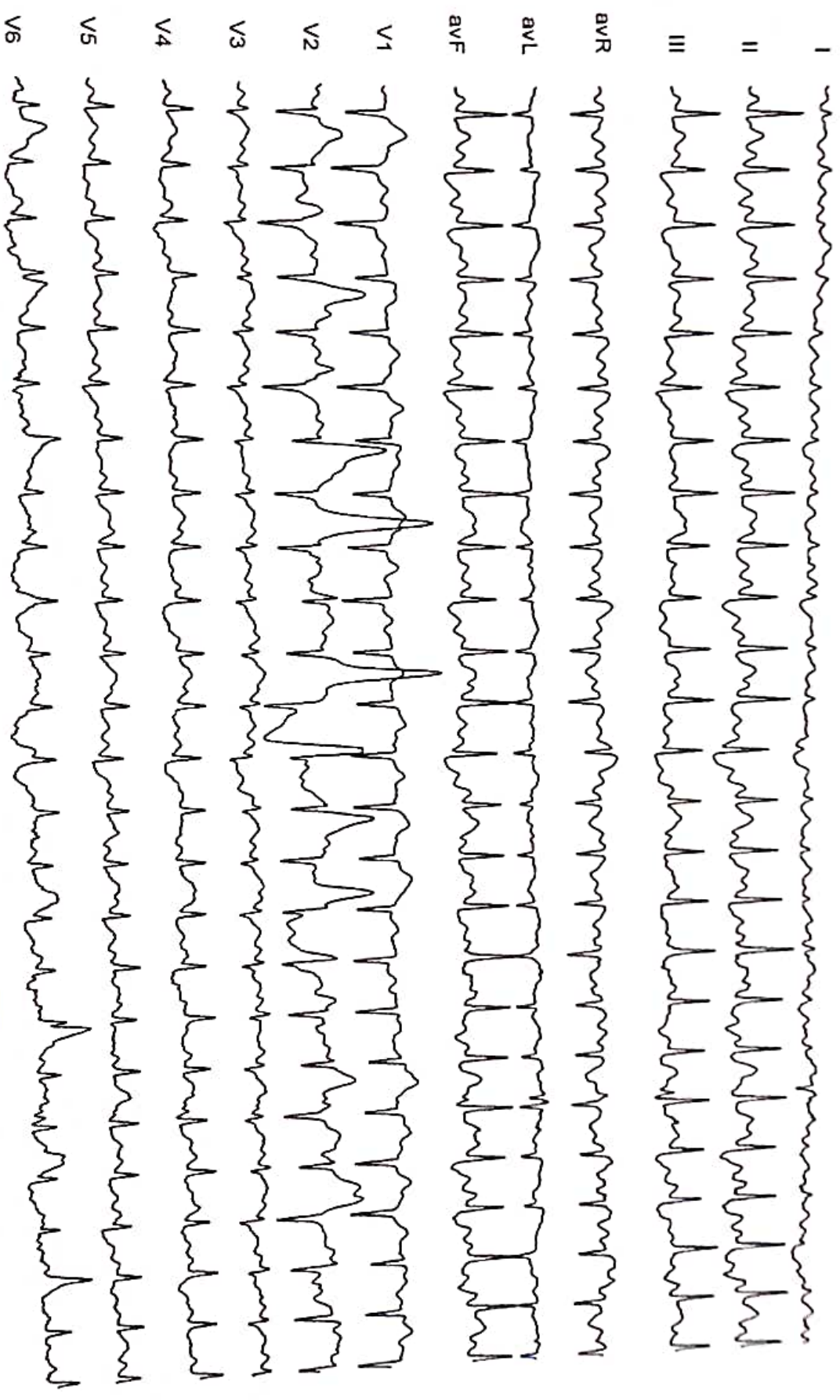


E-95, PC COLONY KANKARBAGH PATNA-20
4037 / ARCHANA KUMARI / 27 Yrs / Female / 153 Cm / 57 Kg

Date: 30/03/2022 01:06:34 PM METs: 04.70 HR: 145 Target HR: 75% of 193 BP: 130/89

Extm: 03:00 1.7 mph 10.0% 25 mm/sec 1.0 cm/mV ECG ON/HOLD ON HF 0.05 HZ LF 20 HZ

12L Rhythm
BRUCE: Stage 1 (3:00)



(GEM213180726)(R)Allengers

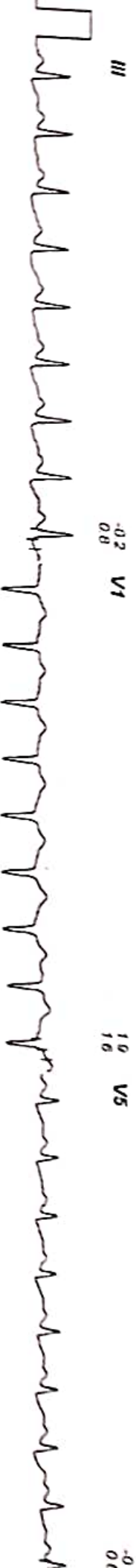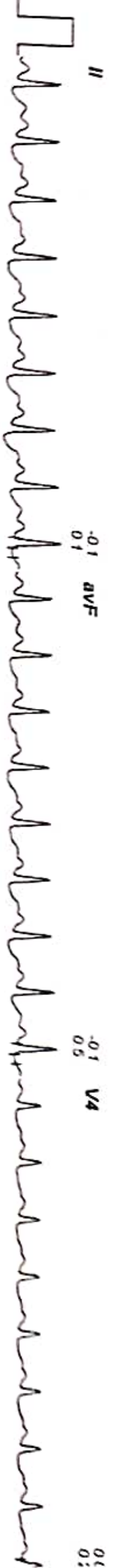
A.L.C. ADVANCE IMAGING DIAGNOSTICS

E-85, PC COLONY KANKARBAGH PATNA-20
4037 / ARCHANA KUMARI / 27 Yrs / Female / 153 Cm / 57 Kg

Date: 30/03/2022 01:06:34 PM METs: 06/10 HR: 170 Target HR: 88% of 193 BP: 130/90 Post J @ 100mSec Extm: 04/47 2.5m/s Grade 12/00% 25mm/Sec 1.0 Cm/mV

Linked Medians Report
BRUCE: Stage 2(1:47)

AGHP



Aliengers Global Healthcare Pvt. Ltd (GEM213180726)(R)Aliengers



ALC. ADVANCE IMAGING DIAGNOSTICS


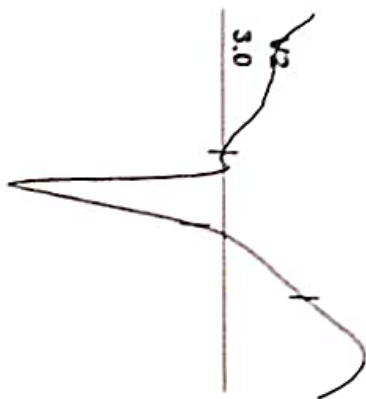
4037 / ARCHANA KUMARI / 27 YRS / F / 153 CMHS / 57 KG / HR : 170

Date: 30-Mar-2022 01:06:34 PM METS: 6.4/170 bpm 88% of THR BP: 130/90 mmHg Raw ECG ELC ON Natch ON HF 0.05 Hz LF 20 Hz 4X 60 ms Post J

BRUCE: Stage 2(1:47)



ExTime: 04:47 2.5 mph 12.0%
25 mm/sec. 1.0 cm/mV



REMARKS:



(GEM213180726)(R)Allengers

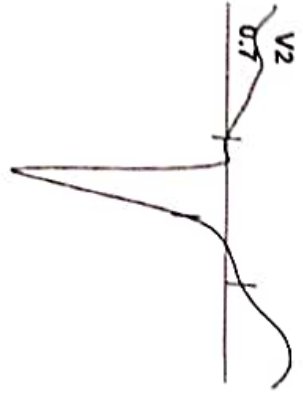
ALC. ADVANCE IMAGING DIAGNOSTICS

4037 / ARCHANA KUMARI / 27 Yrs / F / 153 Cms / 57 Kg / HR : 164

Date: 30-Mar-2022 01:06:34 PM METS: 72/164 bpm 84% of THR BP: 130/90 mmHg Raw ECG/ BLC ON/ Natch ON/ HF 0.05 Hz/ LF 20 Hz

PeakEx
 ESTIME 05:07 0.0 mm
 25 mm/sec. 1.0 Cm/mV

4X 60 ms Post J



I
 STI -4.1
 STS 0.0



V1
 0.2
 0.7



II
 -0.7
 0.4



V2
 0.7
 2.5



III
 -0.5
 0.4



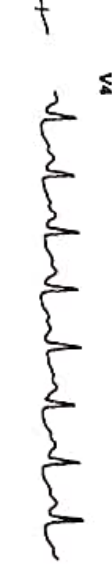V3
 -0.1
 1.5



aVR
 0.4
 0.2



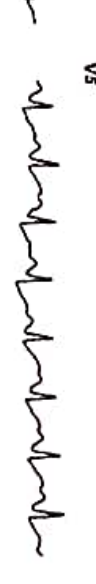V4
 -0.5
 0.1



aVL
 0.2
 0.2




V5
 -0.3
 1.0



aVF
 -0.6
 0.4



V6
 -0.5
 0.1



REMARKS:



(GEM213180729(R))Allengers

A.L.C. ADVANCE IMAGING DIAGNOSTICS

Recovery(0:29)

ACIIP

4037 / ARCHANA KUMARI / 27 Yrs / F / 153 Cms / 57 Kg / HR : 144

Date: 30-Mar-2022 01:06:34 PM METS: 4.2/144 bpm 74% of THR BP: 130/90 mmHg RAW ECG/ BLC ON/ Notch ON/ HF: 0.05 Hz/ LF: 20 Hz

ExTime: 05:08 0.0 mps, 0.0%
25 mm/sec, 1.0 cm/mV

4X 60 ms Post J

I
aVR 0.4
aVL 1.4



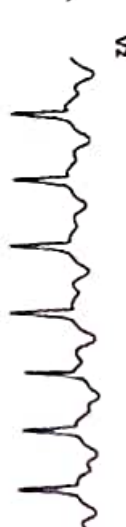
V1
1.6
1.5



II
0.6
0.2
2.2



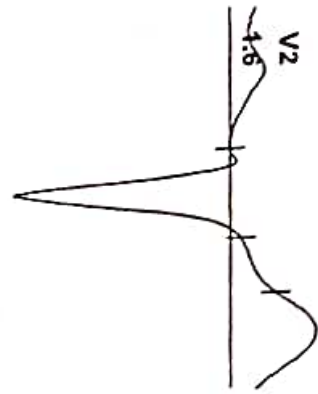
V2
1.6
1.6
2.0




III
0.2
1.1



V3
1.0
1.0
1.8



aVR
-0.5
-1.6



V4
-0.2
0.5



aVL
0.1
0.0




V5
0.5
1.3



aVF
0.4
1.6



V6
-0.2
0.4



REMARKS:



(GEM213180726)(R)Allergers

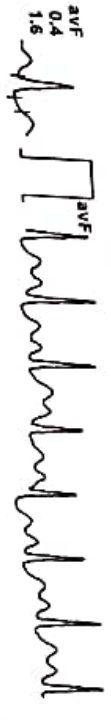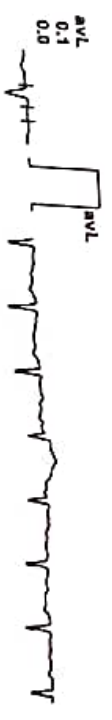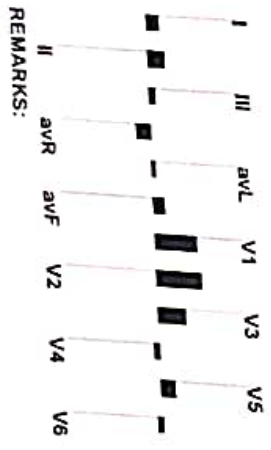
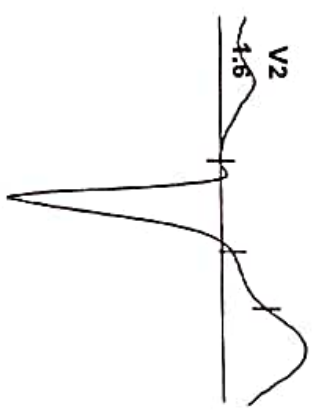
A.L.C. ADVANCE IMAGING DIAGNOSTICS

4037 / ARCHANA KUMARI / 27 Yrs / F / 153 CMS / 57 Kg / HR : 144

Date 30-Mar-2022 01:06:34 PM METS: 4.1/144 bpm 74% of THR BP: 130/90 mmHg Raw ECG/ BLC On/ Natch On/ HF 0.05 Hz/ LF 20 Hz
 4X 60 ms Post J

Recovery(0:30)

ESTIME 05:08 0.0 mV, 0.0%
 25 mm/s, 1.5 cm/mV



(GEM213180726)(R)Allengers

ARCHANA KUMARI / 27 Yrs / Female / 153 Cm / 57 Kg

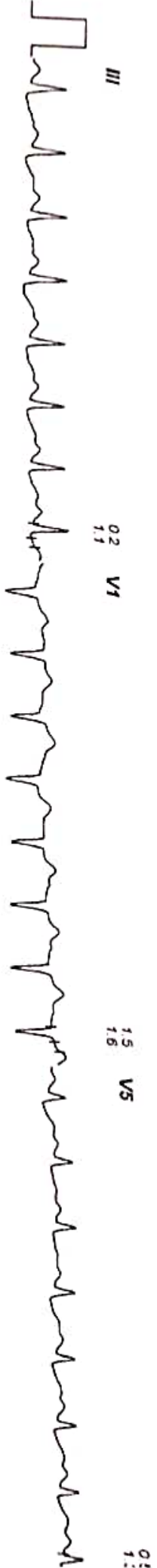
Date: 30/03/2022 01:06:34 PM METS: 04 10 HR: 144 Target HR: 74% of 193 BP: 130/80 Post J @100mSec

ExtIme: 05:08 0.0 mph Grade: 00.00% 25 mm/Sec 1.0 Cm/mV

Linked Medians Report

Recovery(0:30)

W.P.S. AGD



Alengra's Global Healthcare Pvt. Ltd (GEM213180726)(R)Alengra's



A.L.C. ADVANCE IMAGING DIAGNOSTICS
E-95, P.C COLONY KANKARBAGH PATNA-20

4037 / ARCHNA KUMARI / 27 Yrs / F / 153 Cms / 57 Kg Date: 30-Mar-2022 Technician : MR TRILOKI

Stage	Time	Duration	Belt Speed (mph)	Elevation	METs	Rate	% THR Achieved	BP	RPP	PVC	Comments
Standing	00:09	0:01	00.0	00.0	01.0	87	45 %	—/—	000	00	
Warm Up	00:38	0:01	01.0	00.0	01.0	93	48 %	120/80	111	00	
ExStart	02:06	0:07	01.7	10.0	01.1	130	67 %	120/80	156	00	
BRUCE Stage 1	05:06	3:00	01.7	10.0	04.7	145	75 %	130/89	188	00	
BRUCE Stage 2	06:53	1:47	02.5	12.0	06.1	170	88 %	130/90	221	00	
PeakEx	07:13	0:20	00.0	14.0	07.2	164	85 %	130/90	213	00	
Recovery	07:42	0:29	00.0	00.0	04.2	144	75 %	130/90	187	00	
Recovery	07:43	0:30	00.0	00.0	04.1	144	75 %	130/90	187	00	

Findings :

- Exercise Time : 05:08
- Max HR Attained : 170 bpm 88% of Target 193
- Max BP Attained : (Sys) 130/90
- Max Workload Attained : 7.2 Fair response to induced stress
- Max ST Dep Lead & Value : V6 & -1.3 mm In Stage 1 mm
- Test End Reasons : Test Complete

Report :



Dr. Ranjeet Kumar
 MBBS, PGDCC CCEBDM
 Consultant Cardiologist
 Doctor Reg. No. **DIAGNOSTIC**