



PARKLINE DIAGNOSTICS PVT. LTD.

L.G. 3, 4 & 5, Bhuvana Towers, S.D. Road, Secunderabad - 500 003.
Tel : +91 40-2784 5852, 6649 1787, 7995421787, 7093445852, Fax : +91 40 2784 7864
Email parklinediagnostics@gmail.com www.parklinediagnostics.com



NABL Accredited
Certificate No.MC-256

MEDICAL EXAMINATION REPORT

Name	Ms. P. Nyma		Date	27/11/2021
Company	Clo: Medi wheel		Reg. No. :	1532004
Contact No.	9550149664		Sex	<input checked="" type="checkbox"/> F
			Age	<input type="checkbox"/> 58
Type	Pre-Emp		Emp. No.:	Spouse
	Overseas		Height	154cm
	Annual	<input checked="" type="checkbox"/>	Weight	84 kgs
Remarks	<p><u>Mammography</u> :</p> <p>(Rt) Breast nodule - likely fibroadenoma - BI-RADS-II</p> <p>Advice FNAC & follow up c Reports c Surgeons Consultation.</p> <p>- Borderline elevated cholesterol levels, advice follow up.</p> <p>- Microcytic Hypochromic Anemia ? Cause c Anisocytosis, advice follow up. Repeat after 2-4 wks</p> <p>- ↑ ESR count, advice follow up.</p>			
Fitness Status	Medically Fit / Unfit		Physician's Signature DR. PRIYANKA SANNIDHI MBBS	

COMPREHENSIVE MEDICAL EXAMINATION REPORT

NAME Ms. P. Kuma
 AGE 78 yrs | F
 MARITAL STATUS Married CHILDREN : M F
 IDENTIFICATION (IF ANY) A mole on (R+) Forehead



PAST HISTORY

Any family H/o : High Blood Pressure, Heart Disease, Tuberculosis, Diabetes, Asthma, Cancer

Mother ^{late} Late Father Mother ^{late}

Any personal H/o Major illness like : Typhoid..... 1997 Jaundice..... No Etc.

Any H/o STD..... NIL Skin infection..... NIL

H/o Blood Transfusion..... NIL Recent Vaccination..... COVISHIELD 1 dose taken

H/o Epilepsy..... NIL Giddiness..... Nil

H/o Surgery..... NIL Fracture in the past..... Hairline # of olecranon f. Tarsal joints.

Any Personal H/O.

High Blood Pressure, Heart Disease Tuberculosis, Diabetes, Asthma, Cancer

X 30 yrs

Drug Abuse, Drug Allergy, Micturition, Bowels, Alcohol, Smoking, Sleep, MC, Wt. Loss/Wt. Gain

- -

Present illness / Medication T. LOSAR-H, T. PREFER, T. TEXZINE-10, T. THYRONOR 100mg

GENERAL EXAMINATION

Conjunctiva :

Skin :

Ears :

Nose :

Throat & Oral Cavity :

} NAD

Bone, Joints : ? OA Ankle.

Nutritional Status : Well Nourished

Lymph Nodes : (N)

Edema Feet : NIL

Varicose Veins : NIL

Distant Vision : Near Vision :

Right Eye: 6/24 + 1.50 sph 6/6

With glasses / Without glasses

left Eye: 6/24 + 1.50 sph 6/6

with glasses / without glasses

Right Eye: N/D Add +3.00 sph N/6

With glasses / Without glasses

left Eye: N/D Add +3.00 sph N/6

with glasses / without glasses

Colour Vision : POE only

Ophthalmologist's Signature

Right Ear

Hearing :

(N)

Rinee's Test ;

Weber Test :

Discharge :

NIL

Left Ear

(N)

NIL

SYSTEMIC EXAMINATION

Pulse :

88 bpm

B.P. :

150 / 90 mmHg

Lungs :

- A. Shape of Chest □/c symmetrical
- B. Breath Sounds B/c - clear
- C. Adventitious Sounds No

Heart :

- A. Sounds 4 S2 ⊕
- B. Murmurs No murmurs

Nervous System

Abdomen :

- A. Liver Palpable
- B. Spleen Palpable
- C. Piles No piles
- D. Any Lump No

A. Higher Function :

B. Cranial Nerves :

C. Sensory System :

D. Motor System :

E. Jerks :

(N)

General :

- A. Hernia
- B. Hydrocele
- C. Varicocele

} NAD

Breast :

Rt

(N)

Lt.

(N)

CANDIDATE'S DECLARATION

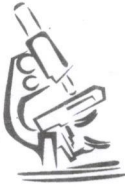I hereby solemnly declare that I am not suffering from Asthma, Hypertension, Diabetes, Occult Psychological disorders or any other ailment which can be suppressed without my voluntary declaration.

Date :

P. Hyman
Signature

Place :

Note : General Physical Examination and Investigation included in the health check-up Have certain limitations and may not be able to detect all latent and asymptomatic diseases. Any new symptoms developing after the health check-up or persisting thereafter should be brought to the attention of the treating physician.



PARKLINE DIAGNOSTICS PVT. LTD.

L.G. 3, 4 & 5, Bhuvana Towers, S.D. Road, Secunderabad - 500 003. Tel : +91 40-2784 5852, 6649 1787, 7995421787,
7093445852, Fax : +91 40 2784 7864 Email parklinediagnostics@gmail.com www.parklinediagnostics.com



NABL Accredited
Certificate No.MC-2566

ENT CONSULTATION

S.No. 1532004 Emp.No. spouse Date 27/11/2021
 Name MS. P Numa Age 58 Yrs Sex M/F ✓

EARS :

	Right	Left
EAC	: patent. Cerumen (+)	- do.
TM	: Intact, pearly white. Cone of light (+)	- do.
TFT	: Rinne's +ve	Rinne's +ve.

Weber's - Central

NOSE : Septum (+). Bil. Turbinates (+). Pass. (+). Mucosa (+).

THROAT : Oropharynx (+). Bil. v. c's (+) mainly Anteriorly bil.

NECK : (+)

IMPRESSION: ENT = Clinically NAD.

D.H.K. Reddy
Dr. D. Hari Krishna Reddy
 MS (ENT)
 Head & Neck Surgeon
 Reg. No: 88379



PARKLINE DIAGNOSTICS PVT. LTD.

L.G. 3, 4 & 5, Bhuvana Towers, Sarojini Devi Road, Secunderabad - 500 003 Tel. +91 40-2784 5852
6649 1787 Fax : +91 40 2784 7864 Email : parklinediagnostics@gmail.com www.parklinediagnostics.com



NABL Accredited
Certificate No. MC-2566

TEST REPORT

Name : Ms . P HYMA [SPOUSE]
Age / Gender : 58 Years / Female
Ref.By : Medi Wheel
Req. No : BIL1532004

TID : UMR0600995
Registered on : 27-Nov-2021 07:57 AM
Reported On : 27-Nov-2021 11:16 AM

DEPARTMENT OF ULTRASOUND Ultrasound Whole Abdomen

LIVER : Normal in size and increased echotexture. No focal lesions.
No IHBD /CBD dilatation. Portal vein is normal.

SPLEEN : Normal in size and echotexture. No focal lesion seen.

GALL BLADDER : Well distended. No sludge / gall stones / sol.
Gall bladder - Wall thickness is normal.
No pericholecystic oedema.

PANCREAS : Normal in size and echotexture. No calcification / sol.
Pancreatic duct is normal. No peripancreatic fluid collection.

RIGHT KIDNEY : 9.81 x 4.84 cms.
Normal in size and echotexture.
Cortical thickness is normal.
No evidence of calculi / sol.
Pelvi calyceal system is normal.

LEFT KIDNEY : 10.85 x 4.61 cms.
Normal in size and echotexture.
Cortical thickness is normal.
No evidence of calculi / sol.
Pelvi calyceal system is normal.

URINARY BLADDER : Well distended. Normal in contour.
Wall thickness is normal. No calculus / sol.

UTERUS : Anteverted measuring 5.25 x 3.33 x 3.98 cms - Normal in size and echotexture.
No space occupying lesion is seen.
Cervix is normal in size and echopattern.

ENDOMETRIUM : Normal.

OVARIES : Right ovary : 1.09 x 1.01 cms and Left ovary : 2.95 x 1.04 cms.
Both ovaries normal in size and echotexture.
No adnexal mass seen.
No fluid in POD.

IMPRESSION : Grade I fatty liver.
Clinical correlation.

Dr. D.J. MOHAN
MD DMRD
(Reg No. 8995)
Consultant Radiologist

The Test marked with*are not accredited by NABL

Lab Timings (Weekdays) : 7.00 am to 8.30 pm
Sundays & Holidays : 7.00 am to 1.00 pm

Radiologists Timings (Weekdays) : 7.30 am to 1.30 pm
& 5.30 pm to 7.45 pm
Sundays & Holidays : 7.30 am to 9.30 am

Free Home Visit for Sample Collection.

Call : 7995421787, 7093445852, 8121147282, 9885202212



PARKLINE DIAGNOSTICS PVT. LTD.

L.G. 3, 4 & 5, Bhuvana Towers, Sarojini Devi Road, Secunderabad - 500 003 Tel. +91 40-2784 5852
6649 1787 Fax :+91 40 2784 7864 Email : parklinediagnostics@gmail.com www.parklinediagnostics.com



NABL Accredited
Certificate No. MC-2566

TEST REPORT

Name : MS.P HYMA [SPOUSE]

Age / Gender : 58 Years / Female

Ref.By : -

Req.No



BIL1532004

TID/SID : UMR0600995/

Registered on : 27-Nov-2021 / 07:57 AM

Collected on : 27-Nov-2021 / 07:57 AM

Reported on : 27-Nov-2021 / 09:33 AM

Reference : Medi Wheel

DEPARTMENT OF CARDIOLOGY

2D Echo/Doppler Study

Mitral Valve	Normal
Aortic valve	Normal
Tricuspid valve	Normal
Pulmonary valve	Normal
Aorta	2.24 cm
Left Atrium	2.97 cm
Left Ventricle	LVDd: 3.47 cm IVSd : 0.9 cm EF: 60 % LVDs: 2.43 cm LVPwd: 1.0 cm FS: 30 %
RWMA	Nil
Right Atrium	Normal
Right Ventricle	Normal
Pulmonary Artery	Normal
IAS	Intact
IVS	Intact
Pericardium	Normal
Svc / Ivc	Normal
Intracardiac Masses	Nil
Doppler Study	Mitral flow: E: 0.71 m/sec A: 0.54 m/sec E/A ratio : 1.32 Aortic flow : 0.9 m/sec Pulmonary flow : 0.75 m/sec
Colour Doppler	No MR / AR / TR / PR
Conclusion	No RWMA. Normal valves/ Normal chambers. No MR/ AR/ TR / PR Good LV/ RV function. No PE/ clot/ vegetation.

* Sample processed at Parkline

--- End Of Report ---

Page 1 of 2

The Test marked with*are not accredited by NABL

Dr PANDURANGA
MD., DM
Consultant Interventional Cardiologist
Reg No TSMCI 1532004

Lab Timings (Weekdays) : 7.00 am to 8.30 pm

Sundays & Holidays : 7.00 am to 1.00 pm

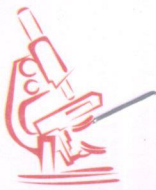Radiologists Timings (Weekdays) : 7.30 am to 1.30 pm

& 5.30 pm to 7.45 pm

Sundays & Holidays : 7.30 am to 9.30 am

Free Home Visit for Sample Collection.

Call : 7995421787, 7093445852, 8121147282, 9885202212



PARKLINE DIAGNOSTICS PVT. LTD.

L.G. 3, 4 & 5, Bhuvana Towers, Sarojini Devi Road, Secunderabad - 500 003 Tel. +91 40-2784 5852
6649 1787 Fax :+91 40 2784 7864 Email : parklinediagnostics@gmail.com www.parklinediagnostics.com



NABL Accredited
Certificate No. MC-2566

TEST REPORT

Name : Ms . P HYMA [SPOUSE]
Age / Gender : 58 Years / Female
Ref.By : Medi Wheel
Req. No : BIL1532004

TID : UMR0600995
Registered on : 27-Nov-2021 07:57 AM
Reported On : 27-Nov-2021 12:03 PM

DEPARTMENT OF ULTRASOUND Mammography

Bilateral CC and MLO views done.

Fairly well defined soft tissue opacity is noted in upper and outer quadrant of right breast.

Rest of Both breasts show normal fibro-glandular parenchyma.

No dominant mass /pleomorphic micro calcifications /skin thickening /
Nipple retraction on either side.

No architectural distortion.

No evidence of duct dilatation.

No axillary lymphadenopathy.


Ultrasound screening : A well defined isoechoic nodule measuring 2.7 x 1.3 cms is noted in right breast 9 'o' clock position - BIRADS-II -
Likely fibroadenoma.

No axillary lymphnodes seen.

IMPRESSION : Right breast nodule - Likely fibroadenoma - BIRADS- II

Advised : FNAC / Comparison with previous reports.

Note: Please bring previous reports on next visit.


Dr. PRAJAKTA SUKHADEVE
DNB RADIOLOGY
Reg. No. 68493

The Test marked with*are not accredited by NABL

Lab Timings (Weekdays) : 7.00 am to 8.30 pm
Sundays & Holidays : 7.00 am to 1.00 pm

Radiologists Timings (Weekdays) : 7.30 am to 1.30 pm
& 5.30 pm to 7.45 pm
Sundays & Holidays : 7.30 am to 9.30 am

Free Home Visit for Sample Collection.

Call : 7995421787, 7093445852, 8121147282, 9885202212

PARKLINE DIAGNOSTICS PVT. LTD.

L.G. 3, 4 & 5, Bhuvana Towers, Sarojini Devi Road, Secunderabad - 500 003 Tel. +91 40-2784 5852
6649 1787 Fax :+91 40 2784 7864 Email : parklinediagnostics@gmail.com www.parklinediagnostics.com



NABL Accredited
Certificate No. MC-2566

TEST REPORT

Name : Ms . P HYMA [SPOUSE]
Age / Gender : 58 Years / Female
Ref.By : Medi Wheel
Req. No : BIL1532004

TID : UMR0600995
Registered on : 27-Nov-2021 07:57 AM
Reported On : 27-Nov-2021 12:03 PM

BIRADS ASSESSMENT CATEGORIES

- 0 - Needs additional imaging.
- 1 - Negative - There is nothing the comment on.
- 2 - Benign finding.
- 3 - Probably benign finding - followup after 3 months suggested.
- 4 - Suspicious abnormality. Biopsy should be considered
[4A - Low suspicion ,4B - Intermediate suspicion, 4C- Moderate concern]
- 5 - Highly suggestive of malignancy.
- 6 - Known biopsy proven malignancy.

The Test marked with*are not accredited by NABL

Lab Timings (Weekdays) : 7.00 am to 8.30 pm
Sundays & Holidays : 7.00 am to 1.00 pm

Radiologists Timings (Weekdays) : 7.30 am to 1.30 pm
& 5.30 pm to 7.45 pm
Sundays & Holidays : 7.30 am to 9.30 am

Free Home Visit for Sample Collection.

Call : 7995421787, 7093445852, 8121147282, 9885202212



PARKLINE DIAGNOSTICS PVT. LTD.

L.G. 3, 4 & 5, Bhuvana Towers, Sarojini Devi Road, Secunderabad - 500 003 Tel. +91 40-2784 5852
6649 1787 Fax : +91 40 2784 7864 Email : parklinediagnostics@gmail.com www.parklinediagnostics.com



NABL Accredited
Certificate No. MC-2566

TEST REPORT

Name : Ms . P HYMA [SPOUSE]
Age / Gender : 58 Years / Female
Ref.By : Medi Wheel
Req. No : BIL1532004

TID : UMR0600995
Registered on : 27-Nov-2021 07:57 AM
Reported On : 27-Nov-2021 08:55 AM

DEPARTMENT OF X-RAY X-Ray Chest PA View

Lung fields are clear.

Cardia is normal.

Hila are normal.

C P angles are free.

Bony cage is normal.

Soft tissues are normal.

IMPRESSION : NORMAL CHEST XRAY.

Dr. D.J. MOHAN
MD DMRD
(Reg No. 8995)
Consultant Radiologist

The Test marked with*are not accredited by NABL

Lab Timings (Weekdays) : 7.00 am to 8.30 pm
Sundays & Holidays : 7.00 am to 1.00 pm

Radiologists Timings (Weekdays) : 8.00 am to 1.30 pm
& 5.30 pm to 7.45 pm
Sundays & Holidays : 7.30 am to 9.30 am

Free Home Visit for Sample Collection.

Call : 7995421787, 7093445852, 8121147282, 9885202212

MS.PHYMA

Female 58Years

HR : 75 bpm
 P : 101 ms
 PR : 155 ms
 QRS : 65 ms
 QT/QTc : 389/436 ms
 P/QRS/T : 62/52/68 °
 RV5/SV1 : 0.893/1.045 mV

Diagnosis Information:

Sinus Rhythm
 Poor R Wave Progression(V4)
 Inverted T Wave(V5)

① TL V5 V6
 B in ARK

CO release
 C. Panduranga

DR PANDURANGA
 MD., DM
 Consultant Interventional Cardiologist
 No TSMC/FMR/09054

Report Confirmed by: