

Health Check up Booking Request(bobE39566), Beneficiary Code-38296

1 message

Mediwheel <wellness@mediwheel.in>
 To: vidhidiagnostics@gmail.com
 Cc: customercare@mediwheel.in

22 May 2023 at 14:42



Mediwheel
 ...Your wellness partner



011-41195959

Email:wellness@mediwheel.in

Dear **VIDHI DIAGNOSTICS**,

City : Ahmedabad . **Address** : L-86 Swatantra - Senanj Nagar , Opp- Akhbarnagar Bus Terminals, New Wadaj , Ahmedabad -13,

We have received the confirmation for the following booking .

Name : MS. AGRAWAL MEHA M
Age : 34
Gender : Female
Package Name : Medi-Wheel Metro Full Body Health Checkup Female Below 40
Contact Details : 9909130908
Booking Date : 22-05-2023
Appointment Date : 27-05-2023

Member Information			
Booked Member Name	Age	Gender	Cost(In INR)
MS. AGRAWAL MEHA M	34	Female	Cashless
Total amount to be paid			Cashless

We will get back to you with confirmation update shortly. Please find the package details as attached for your reference.

Package Name : Medi-Wheel Metro Full Body Health Checkup Female Below 40 - Includes (37)Tests

Tests included in this Package : Ecg, TSH, X-ray Chest, Stress Test (tmt)/ 2d Echo, Blood Sugar Postprandial, A:g Ratio, Blood Group, Total Cholesterol, Triglycerides, Fasting Blood Sugar, Ultrasound Whole Abdomen , Glycosylated Haemoglobin (hba1c), Hdl, Vldl, Urine Analysis, LDL, Total Protine, General Consultation, HDL/ LDL ratio, GGT(Gamma-glutamyl Transferase), Eye Check-up consultation, ALP (ALKALINE PHOSPHATASE), Uric Acid, AST/ALT Ratio, Serum Protein, CBC with ESR, Stool Analysis, Urine Sugar Fasting, Urine Sugar PP, T3, T4, Cholesterol Total / HDL Ratio, BUN, BUN/Creatinine Ratio, Bilirubin Total & Direct and Indirect, Albumin, Globulin

Medical Examination Report

Date : 27/05/2023

1. Personal Particulars

Name : Mehul Agarwal









Age : 37 years Gender : ~~Male~~ / Female

Marital Status : ~~married~~

Past & Present Medical History : H/O LSCS on 22/11/2015
HTN since 8 yrs taking Telikmor od
H/O Asthma taking Spiraflo Inhalers

2. Clinical Medical Examination

Height : 164 cm Weight : 83 kg
Blood Pressure : 104/90 mmHg Pulse : 74 p/min

General Condition :  Skin : 
Central Nervous System :  Head & Neck : 
Cardiovascular System :  Chest : 
Abdomen :  Limbs : 
Last menstrual period : -

Vision: : Right: 6/6 with spears NIG Left: 6/6 with spears NIG

Colour vision : Normal/Colour Blind

Personal Habit : NO

Remarks : Fit / Unfit for employment

Dr. Vidhi D. Modh
MBBS
Reg. No. 074540

Dr's name, signature & chop

Vidhi Diagnostics
L-88, Swatantra-Senani Nagar,
Opp. Akharnagar Bus Terminals,
Nr. Akharnagar Circle,
New Wadaj, Ahmedabad-13.

Dr. Dinesh S. Modh

M.D., D.M.R.E. (Radiodiagnosis)

Consultant Radiologist & Sonologist

Ex. Junior Lecturer, B.J. Medical College, Civil Hospital, A'bad.

Panel Doctor of L.I.C.



Patient's name : MEHAAGRAWAL

Reg. ID : R-2263-23

Referred by : Dr. MEDIWHEEL

Age/Sex : 37 Years/Female

Accession : 6278

Date : 27/05/2023

X-RAY CHEST (PA VIEW)

Both lung fields appear normal.
No e/o consolidation or cavitations is seen.
Both costo-phrenic angles appear clear.
Cardiac size is with in normal limits.
Both domes of diaphragm appear normal.
Bony thoracic cage appears normal.

Thanks for reference.

Dr. Dinesh S. Modh

MD DMRE (Radiodiagnosis)

DR DINESH S. MODH

M.D. DMRE(RADIODIAGNOSIS)

ISO 9001:2015 Certified Diagnostics Center

Vidhi Imaging Center

L-86, Swatantra Senani Nagar, Opp. Indian Oil Petrol Pump, Akhbarnagar Circle, Nava Vadaj, Ahmedabad - 380 013.

Phone : (Radiology) 079-2762 1406 | M. 98799 29406, 98250 09406 | Time (Radiology) : Mon. to Sat. 9 am to 2 pm, 5 to 9 pm, Sunday 9 am to 12 Noon

E-mail : vidhidiagnostics@gmail.com, Website : www.vidhidiagnostics.com

Multislice CT Scan | CBCT-Dental Scan | Live 3D-4D Sonography | Colour Doppler | Echo Cardiography | Interventional Radiology | Maxillofacial Radiology | Fetal Medicine
Digital X-Ray | Digital Mammography | Digital OPG/TMJ | ECG/TMT/PFT/EEG/EMG | Audiometry | Pathology Laboratory | Health Check Up Plans | Pre Employment Check Up

CT SCAN & CBCT FACILITY NOW AVAILABLE

Dr. Dinesh S. Modh

M.D., D.M.R.E. (Radiodiagnosis)

Consultant Radiologist & Sonologist

Ex. Junior Lecturer, B.J. Medical College, Civil Hospital, A'bad.

Panel Doctor of L.I.C.



Patient's name: MEHA AGRAWAL

Reg. ID : R-2263-23

Referred by : Dr. MEDIWHEEL

Age/Sex : 37 Years/Female

Accession : 6278

Date : 27/05/2023

2D- ECHO REPORT

FINAL CONCLUSION:

LV IS NORMAL SIZE. GOOD LV SYSTOLIC FUNCTION NO RWMA.

LVEF - 60%. NO CONCENTRIC LVH.

NORMAL LV COMPLANCE.

LA IS NORMAL SIZE. NO LA CLOT.

RV IS NORMAL SIZE. GOOD RV SYSTOLIC FUNCTION.

RA IS NORMAL SIZE.

MITRAL VALVE IS NORMAL. NO MS. NO MR. NO MVP.

AORTIC VALVE IS NORMAL. NO AS. NO AR.

TRICUSPID VALVE IS NORMAL. NO TR. RVSP-26 mmHg. NO PAH.

NO CLOT, NO VEGETATION, NO PERICARDIAL EFFUSION.

DIMENSIONS:

AORTA	2.6 C.M
LEFT ATRIUM	2.7 C.M
LVDD	4.1 C.M.
IVSD	1.0 C.M
PWD	1.0 C.M
LVDS	2.6 C.M.

COLOUR DOPPLER FINDING:

STRUCTURE	VELOCITY m/sec
	Max
PULMONARY VALVE	0.7
MITRAL VALVE	E : 0.7 A: 0.4
AORTIC VALVE	1.0

Avinash Bhaskar
Dr. Avinash Bhaskar
M.B.B.S. D Cardio,
Reg. No.: G-45946
DR AVINASH BHASKAR

ISO 9001:2015 Certified Diagnostics Center

Vidhi Imaging Center

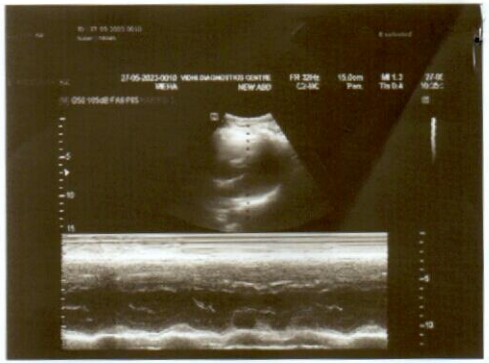
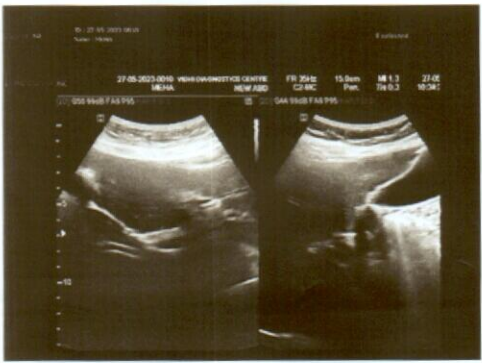
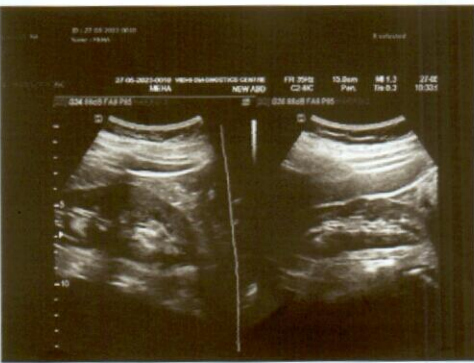
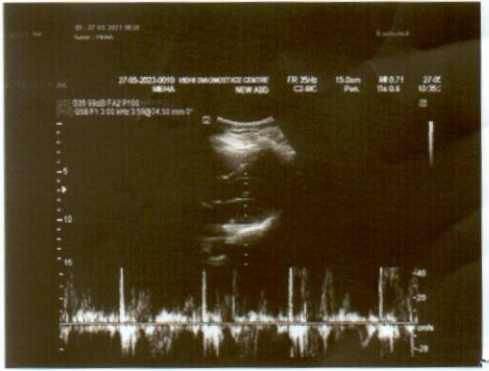
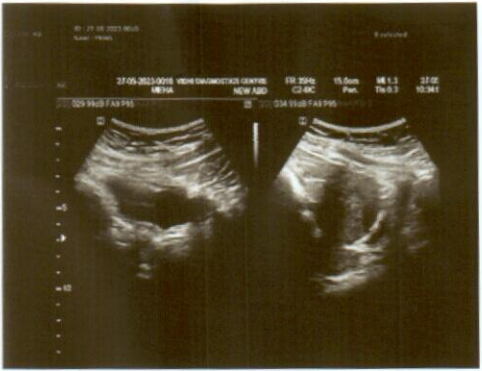
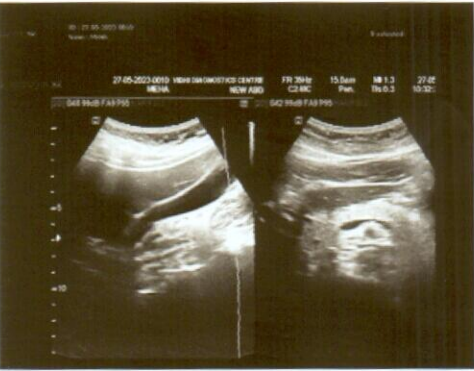
L-86, Swatantra Senani Nagar, Opp. Indian Oil Petrol Pump, Akhbarnagar Circle, Nava Vadaj, Ahmedabad - 380 013.

Phone : (Radiology) 079-2762 1406 | M. 98799 29406, 98250 09406 | Time (Radiology) : Mon. to Sat. 9 am to 2 pm, 5 to 9 pm, Sunday 9 am to 12 Noon

E-mail : vidhidiagnostics@gmail.com, Website : www.vidhidiagnostics.com

Multislice CT Scan | CBCT-Dental Scan | Live 3D-4D Sonography | Colour Doppler | Echo Cardiography | Interventional Radiology | Maxillofacial Radiology | Fetal Medicine
Digital X-Ray | Digital Mammography | Digital OPG/TMJ | ECG/TMT/PFT/EEG/EMG | Audiometry | Pathology Laboratory | Health Check Up Plans | Pre Employment Check Up

CT SCAN & CBCT FACILITY NOW AVAILABLE



Dr. Dinesh S. Modh

M.D., D.M.R.E. (Radiodiagnosis)
Consultant Radiologist & Sonologist
Ex. Junior Lecturer, B.J. Medical College, Civil Hospital, A'bad.
Panel Doctor of L.I.C.



Patient's name : MEHA AGRAWAL
Reg. ID : R-2263-23
Referred by : Dr. MEDIWHEEL

Age/Sex : 37 Years/Female
Accession : 6278
Date : 27/05/2023

USG ABDOMEN

LIVER: - Liver appears normal in size & show normal echotexture. No evidence of diffuse or focal lesion is seen. Intrahepatic biliary radicals appear normal. Portal vein and CBD appear normal. No e/o calculus is seen in bile duct.

GALL BLADDER: - Gall bladder is distended & appears normal. No evidence of calculus or cholecystitis is seen. No evidence of pericholecystic fluid is seen.

SPLEEN: - Spleen appears normal in size & shows normal echotexture. No evidence of diffuse or focal lesion is seen.

PANCREAS: - Pancreas appears normal size and echopattern. No e/o diffuse or focal lesion is seen. Main pancreatic duct appears normal.

KIDNEY: - Both Kidneys appear normal in size & echotexture.

No e/o calculus or hydronephrosis or hydroureter is seen in either side.

Cortico-medullary differentiation is maintained on either side.

Both suprarenal regions appear normal.

RIF & BOWEL LOOPS (By high frequency probe): - Gaseous bowel loops noted.

No evidence of pre & para aortic lymphadenopathy is seen.

No evidence of free fluid is seen in abdomen.

No evidence of dilated or thickened bowel loops is seen.

Urinary bladder: - appears normal. No e/o calculus or mass lesion is seen in bladder.

Uterus appears normal in size and echopattern.

No evidence of diffuse or focal lesion is seen.

Cervical region appears normal.

Endometrial thickness is 6.4mm.

Both ovaries and adnexal regions appear normal.

No e/o free fluid is seen in pouch of Douglas.

Thanks for reference.

Dr. Dinesh S. Modh
MD DMRE (Radiodiagnosis)
DR DINESH S. MODH
M.D. DMRE (RADIODIAGNOSIS)

ISO 9001:2015 Certified Diagnostics Center

Vidhi Imaging Center

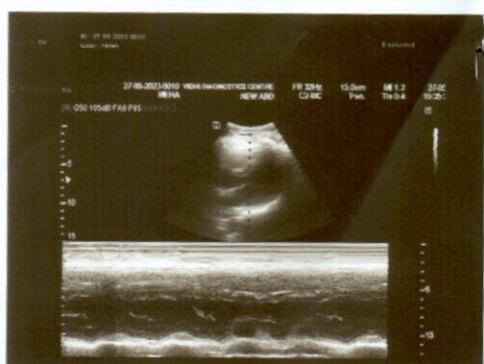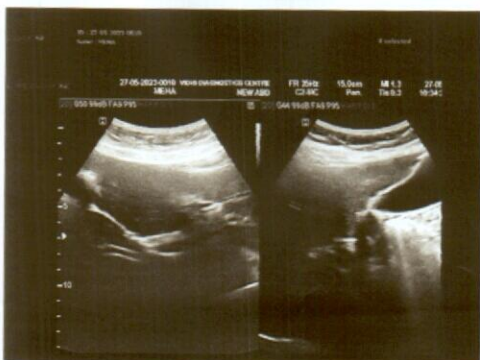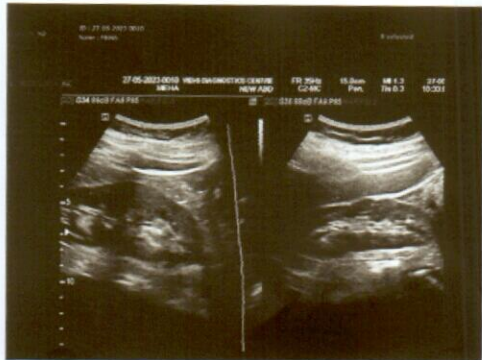
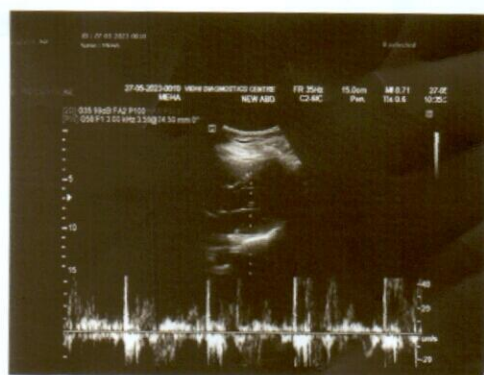
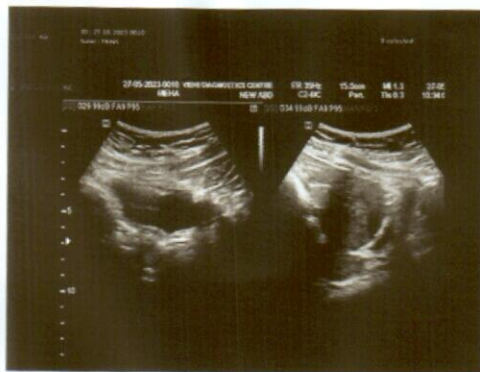
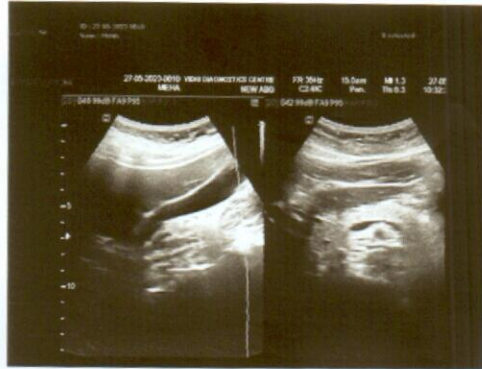
L-86, Swatantra Senani Nagar, Opp. Indian Oil Petrol Pump, Akhbarnagar Circle, Nava Vadaj, Ahmedabad - 380 013.

Phone : (Radiology) 079-2762 1406 | M. 98799 29406, 98250 09406 | Time (Radiology) : Mon. to Sat. 9 am to 2 pm, 5 to 9 pm, Sunday 9 am to 12 Noon

E-mail : vidhidiagnostics@gmail.com, Website : www.vidhidiagnostics.com

Multislice CT Scan | CBCT-Dental Scan | Live 3D-4D Sonography | Colour Doppler | Echo Cardiography | Interventional Radiology | Maxillofacial Radiology | Fetal Medicine
Digital X-Ray | Digital Mammography | Digital OPG/TMJ | ECG/TMT/PFT/EEG/EMG | Audiometry | Pathology Laboratory | Health Check Up Plans | Pre Employment Check Up

CT SCAN & CBCT FACILITY NOW AVAILABLE



27-05-2023 10:10:24

ID: 9452

Name: meha agraval

Age: 37 yrs.

Sex: Female

Hospital:

Department:

Dr. Avinash Bhoskar
M.B.B.S. D.Cardio

Reg. No.: G-45946

HR : 75 bpm

PR : 144 ms

QRS : 92 ms

QT/QTc : 410/458 ms

P/QRS/T : 68/32/2 deg.

RV5/SV1 : 0.846/-1.069 mv

RV5+SV1 : 1.915 mv

<< Analysis Result >>

** borderline ECG **

Sinus rhythm

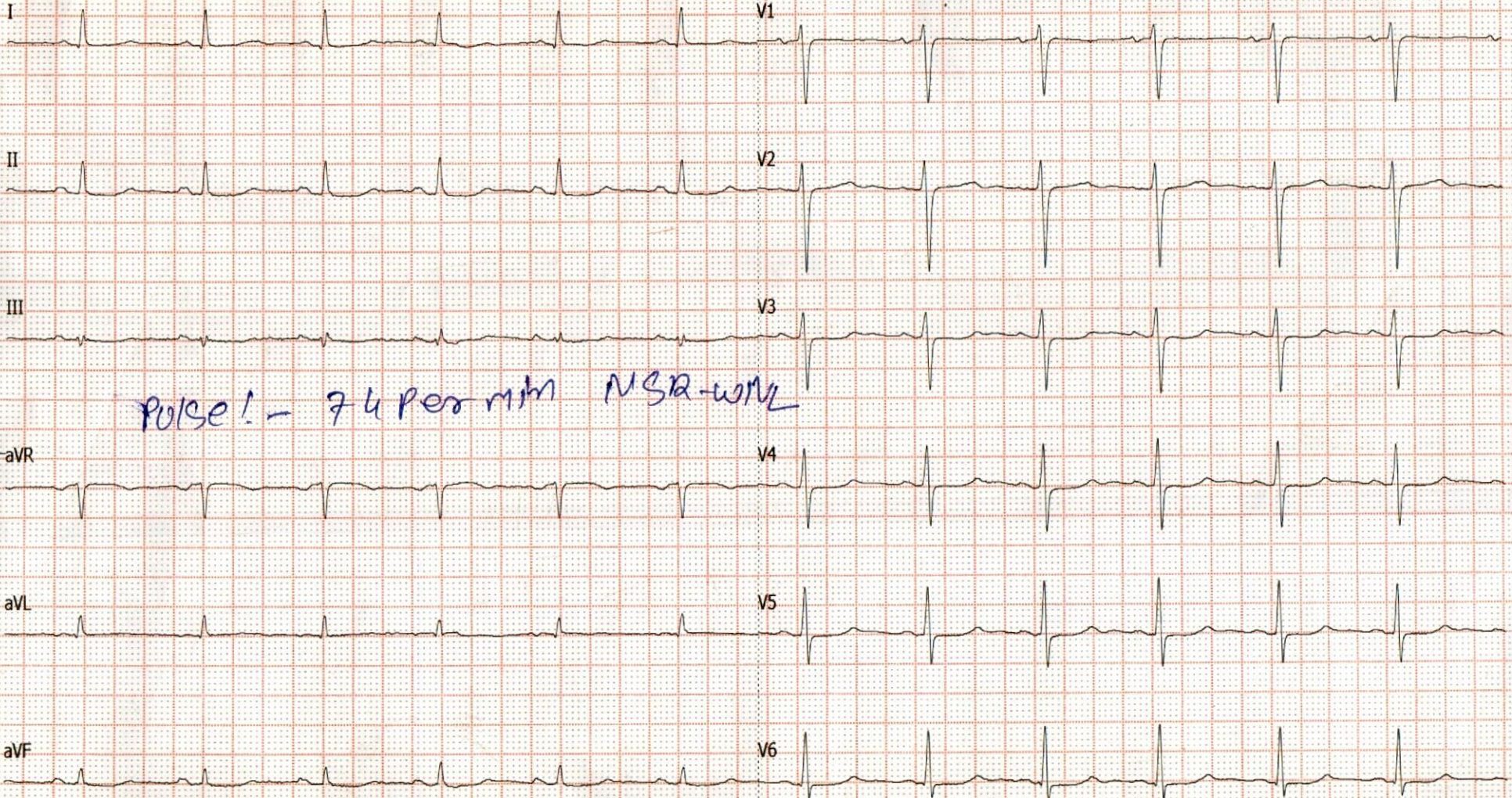
Nonspecific T wave abnormality

Vidhi Diagnostics

1-85, Swatantra-Senani Nagar,
Opp. Ad. Barnagar Bus Terminals,
Jr. Jkbarnagar Circle,
New Wadaj, Ahmedabad-13.

Need to be confirmed by doctor. Doctor Name: _____

0.67Hz - 35Hz AC 50Hz 25 mm/s 10 mm/mv



Dr. Dinesh S. Modh

M.D., D.M.R.E. (Radiodiagnosis)

Consultant Radiologist & Sonologist

Ex. Junior Lecturer, B.J. Medical College, Civil Hospital, A'bad.

Panel Doctor of L.I.C.

VIDHI
DIAGNOSTICS



27-05-2023

Respected Sir,

I Meha M. Agrawal from BOB
(EC No. 161556) was having ~~her~~^{my} menstruation
cycle, so I didn't provide my urine & stool
sample for any urine test & stool test.

Thanking you

Meha
2

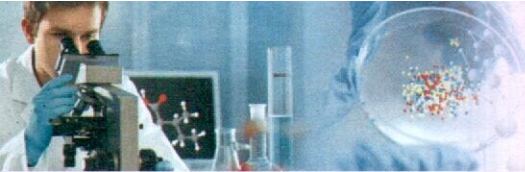Vidhi Diagnostics
L-86, Swatantra-Senani Nagar,
Opp. Akhbarnagar Bus Terminals,
Nr. Akhbarnagar Circle,
New Wadaj, Ahmedabad-13.

ISO 9001:2015 Certified Diagnostics Center

Vidhi Imaging Center, L-86, Swatantra Senani Nagar, Opp. Akhbarnagar Petrol Pump, Nr. Akhbarnagar Circle, Nava-Vadaj, Ahmedabad - 380 013.

Phone : 079-2762 1406, Mobile : 98799 29406, 98250 09406, E-mail : vidhidiagnostics@gmail.com, Website : www.vidhidiagnostics.com

FACILITIES : Live 3D-4D Sonography | Colour Doppler | Echo Cardiography | Interventional Radiology | Fetal Medicine | Digital X-Ray
Digital Mammography | Digital OPG / TMJ | ECG / TMT / PFT / EEG / EMG | Pathology Laboratory | Health Check Up Plans | Pre Employment Check Up



Pathology Department

VIDHI
DIAGNOSTICS



Patient's name : MEHA AGRAWAL
Age/Sex : 37 Years/Female
Referred by : Dr. MEDIWHEEL
Collection Time : 09:20

Reg. ID : P-1045-23
Accession : 6268
Order Dt/time : 27/05/2023 09:20

Complete Blood Count

Sample Type: EDTA

Test Name	Result	Units	Biological Reference Interval
<u>Blood Counts</u>			
Haemoglobin :	13.7	Gms%	12.5 - 16.0
Total R.B.C. :	4.23	mill/c.mm	4.2 - 5.4
Total W. B. C. :	8940	/cu mm	4000 - 10500
Platelet Count :	70000	/cu.mm	1,50,000 - 4,50,000
<u>Differential Count</u>			
Neutrophils :	53	%	40 - 70
Lymphocytes :	38	%	20 - 40
Eosinophils :	04	%	1 - 4
Monocytes :	05	%	2 - 6
Basophils :	00	%	0 - 01
<u>Blood Indices</u>			
P. C. V :	40.9	%	37 - 47
M. C. V. :	96.8	fl	78 - 100
M.C.H :	32.3	pg	27 - 31
M. C. H. C :	33.4	%	32 - 36
R.D.W :	14.9	%	11.5 - 14.0
<u>E.S.R.(Westergren Method)</u>			
After one hour :	08	mm/hr	3 - 12

TESTS DONE ON FULLY AUTOMATED HEMATOLOGY ANALYZER.

Dr. Gayatri M. Mehta

M. D. (Patho)

Reg. No. G-32215

DR GAYATRI MEHTA
MD(PATHOLOGY)

DR. ANAND D. PARIKH
MD(PATHOLOGY)

LAB USE ONLY (Entered by :GM Enter Date/Time:27/05/2023 4:09:00 PM) (Verify by :GM Verify Date/Time:27/05/2023 4:09:00 PM)

ISO 9001:2015 Certified Diagnostics Center

Vidhi Imaging Center | Pathology Department

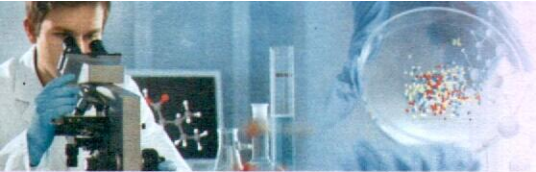L-86, Swatantra Senani Nagar, Opp. Akhbarnagar Petrol Pump, Nr. Akhbarnagar Circle, Nava-Vadaj, Ahmedabad - 380 013.

Ph. (Pathology) : 079-2762 1406, 8849893954 M. 98799 29406, 98250 09406, E-mail : vidhidiagnostics@gmail.com, Web. : www.vidhidiagnostics.com

Time (Pathology) : Mon. to Sat. 8.30 am to 8.00 pm, Sunday 9 am to 12 Noon

Pathology means science behind medicine

CT SCAN & CBCT FACILITY NOW AVAILABLE



Pathology Department



Patient's name : MEHA AGRAWAL
Age/Sex : 37 Years/Female
Referred by : Dr. MEDIWHEEL
Collection Time : 09:20

Reg. ID : P-1045-23
Accession : 6268
Order Dt/time : 27/05/2023 09:20

Blood Glucose

Sample Type: Serum

Test Name	Result	Units	Biological Reference Interval
Fasting Blood Glucose : <i>GOD-POD Method.</i>	101	mg/dl	70 - 110

Blood Glucose

Sample Type: Serum

Test Name	Result	Units	Biological Reference Interval
Post Prandial Blood Glucose After 2hr. : <i>GOD-POD Method.</i>	129	mg/dl	80 - 140

Dr. Gayatri M. Mehta

M. D. (Patho)

Reg. No. G-32215

DR GAYATRI MEHTA
MD(PATHOLOGY)

DR. ANAND D. PARIKH
MD(PATHOLOGY)

LAB USE ONLY (Entered by :GM Enter Date/Time:27/05/2023 4:10:00 PM) (Verify by :GM Verify Date/Time:27/05/2023 4:21:00 PM)

ISO 9001:2015 Certified Diagnostics Center

Vidhi Imaging Center | Pathology Department

L-86, Swatantra Senani Nagar, Opp. Akhbarnagar Petrol Pump, Nr. Akhbarnagar Circle, Nava-Vadaj, Ahmedabad - 380 013.

Ph. (Pathology) : 079-2762 1406, 8849893954 M. 98799 29406, 98250 09406, E-mail : vidhidiagnostics@gmail.com, Web. : www.vidhidiagnostics.com

Time (Pathology) : Mon. to Sat. 8.30 am to 8.00 pm, Sunday 9 am to 12 Noon

Pathology means science behind medicine

CT SCAN & CBCT FACILITY NOW AVAILABLE



Pathology Department



Patient's name : MEHA AGRAWAL
Age/Sex : 37 Years/Female
Referred by : Dr. MEDIWHEEL
Collection Time : 09:20

Reg. ID : P-1045-23
Accession : 6268
Order Dt/time : 27/05/2023 09:20

Blood Group

Sample Type: EDTA sample.

Test Name	Result
BG :	" O "
RH :	POSITIVE
Remarks	Done by forward grouping method.

Dr. Gayatri M. Mehta
M. D. (Patho)

Reg. No. G-32215

DR GAYATRI MEHTA
MD(PATHOLOGY)

DR. ANAND D. PARIKH
MD(PATHOLOGY)

LAB USE ONLY (Entered by :GM Enter Date/Time:27/05/2023 4:16:00 PM) (Verify by :GM Verify Date/Time:27/05/2023 4:16:00 PM)

ISO 9001:2015 Certified Diagnostics Center

Vidhi Imaging Center | Pathology Department

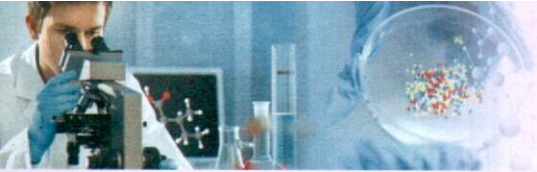L-86, Swatantra Senani Nagar, Opp. Akhbarnagar Petrol Pump, Nr. Akhbarnagar Circle, Nava-Vadaj, Ahmedabad - 380 013.

Ph. (Pathology) : 079-2762 1406, 8849893954 M. 98799 29406, 98250 09406, E-mail : vidhidiagnostics@gmail.com, Web. : www.vidhidiagnostics.com

Time (Pathology) : Mon. to Sat. 8.30 am to 8.00 pm, Sunday 9 am to 12 Noon

Pathology means science behind medicine

CT SCAN & CBCT FACILITY NOW AVAILABLE



Pathology Department

Patient's name : MEHA AGRAWAL
Age/Sex : 37 Years/Female
Referred by : Dr. MEDIWHEEL
Collection Time : 09:20

Reg. ID : P-1045-23
Accession : 6268
Order Dt/time : 27/05/2023 09:20

Lipid Profile

Sample Type: Serum

Test Name	Result	Units	Biological Reference Interval
S. Cholesterol : Oxidase-esterase method.	183	mg/dl	0 - 200
S. Triglyceride : Enzymatic Colorimetry method	126.9	mg/dL	0 - 200
S. HDL - Cholesterol : Serum by Enzymatic method.	35.0	mg/dL	35 - 65
S. LDL - Cholesterol : Serum by Enzymatic method	122.62	mg/dL	0 - 130
S. VLDL - Cholesterol :	25.38	mg/dL	0 - 30
S. Chole/HDL.Ratio :	5.23		1 - 6
S. LDL / HDL Cholesterol Ratio :	3.5		0 - 3.5

Dr. Gayatri M. Mehta
M. D. (Patho)

Reg. No. G-32215

DR GAYATRI MEHTA
MD(PATHOLOGY)

DR. ANAND D. PARIKH
MD(PATHOLOGY)

LAB USE ONLY (Entered by :GM Enter Date/Time:27/05/2023 4:10:00 PM) (Verify by :GM Verify Date/Time:27/05/2023 4:10:00 PM)

ISO 9001:2015 Certified Diagnostics Center

Vidhi Imaging Center | Pathology Department

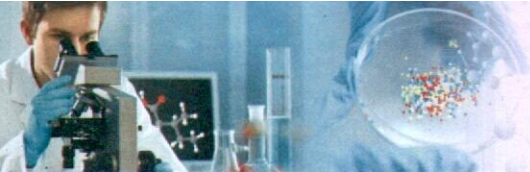L-86, Swatantra Senani Nagar, Opp. Akhbarnagar Petrol Pump, Nr. Akhbarnagar Circle, Nava-Vadaj, Ahmedabad - 380 013.

Ph. (Pathology) : 079-2762 1406, 8849893954 M. 98799 29406, 98250 09406, E-mail : vidhidiagnostics@gmail.com, Web. : www.vidhidiagnostics.com

Time (Pathology) : Mon. to Sat. 8.30 am to 8.00 pm, Sunday 9 am to 12 Noon

Pathology means science behind medicine

CT SCAN & CBCT FACILITY NOW AVAILABLE



Pathology Department

VIDHI
DIAGNOSTICS



Patient's name : MEHA AGRAWAL
Age/Sex : 37 Years/Female
Referred by : Dr. MEDIWHEEL
Collection Time : 09:20

Reg. ID : P-1045-23
Accession : 6268
Order Dt/time : 27/05/2023 09:20

HbA1C

Sample Type: Serum

Test Name	Result	Units	Biological Reference Interval
HbA1C :	5.2	%	Non-diabetic: 4.2-6.2 Pre-diabetic : 6.3-7.2 Diabetic : 7.3-8.2
Mean Blood Glucose of Last 03 months.	103	mg/dl	

Comment

*As per the new 2009 update of American Diabetes Association regarding HbA1C & Mean Blood Glucose relationship.

NOTE:

This test is used to monitor diabetic patients compliance with the therapeutic regimen and log It's level is proportional to both the average blood glucose concentration and the life span of the red blood cells (RBC) in circulation. HbA1c values are free of day to day glucose fluctuations and are unaffected by exercise or recent food intake.

Dr. Gayatri M. Mehta

M. D. (Patho)

Reg. No. G-32215

DR GAYATRI MEHTA
MD(PATHOLOGY)

DR. ANAND D. PARIKH
MD(PATHOLOGY)

LAB USE ONLY (Entered by :GM Enter Date/Time:27/05/2023 4:09:00 PM) (Verify by :GM Verify Date/Time:27/05/2023 4:09:00 PM)

ISO 9001:2015 Certified Diagnostics Center

Vidhi Imaging Center | Pathology Department

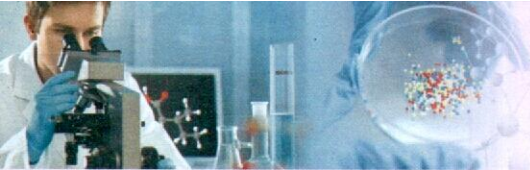L-86, Swatantra Senani Nagar, Opp. Akhbar Nagar Petrol Pump, Nr. Akhbar Nagar Circle, Nava-Vadaj, Ahmedabad - 380 013.

Ph. (Pathology) : 079-2762 1406, 8849893954 M. 98799 29406, 98250 09406, E-mail : vidhidiagnostics@gmail.com, Web. : www.vidhidiagnostics.com

Time (Pathology) : Mon. to Sat. 8.30 am to 8.00 pm, Sunday 9 am to 12 Noon

Pathology means science behind medicine

CT SCAN & CBCT FACILITY NOW AVAILABLE



Pathology Department

Patient's name : MEHA AGRAWAL
Age/Sex : 37 Years/Female
Referred by : Dr. MEDIWHEEL
Collection Time : 09:20

Reg. ID : P-1045-23
Accession : 6268
Order Dt/time : 27/05/2023 09:20

BIOCHEMISTRY

Sample type :Serum

Test Name	Result	Units	Biological Reference Interval
Urea, (Serum by GLDH method) :	15.4	mg/dl	10 - 50
S.Uric acid, (Serum by Uricase method) :	4.8	mg/dl	2.6-6.0
Bun :	7.2	mg/dl	6-20
Creatinine, (Serum by Enzymatic reaction) :	0.60	mg/dl	0.5-1.2
BUN/CREATRATIO	12		13 - 20
S.G.P.T (ALT) : (Serum by IFCC method)	10.8	U/L	0 - 40
S.G.O.T (AST) : (Serum by IFCC method)	11.5	U/L	0 - 37
ALK.PHOSPHATASE : (Serum by PNP method)	64	U/L	35-104
G.G.T :	21.4	U/L	8 - 78
<u>BILIRUBIN</u>			
Total :	0.34	mg/dl	Up to 1.2
Direct :	0.15	mg/dl	0-0.7
Indirect :	0.19	mg/dl	0 - 0.5
<u>SERUM PROTEINS</u>			
Total Protein (Serum by Biuret method) :	6.40	gms/dl	6.4 - 8.5
Albumin (Serum by BCG method) :	3.97	gms/dl	3.97-4.94
Globulins :	2.43	gms/dl	2.3 - 3.5
A/G Ratio :	1.634		0.9 - 2.9

Dr. Gayatri M. Mehta
M. D. (Patho)

Reg. No. G-32215

DR GAYATRI MEHTA
MD(PATHOLOGY)

DR. ANAND D. PARIKH
MD(PATHOLOGY)

LAB USE ONLY (Entered by :GM Enter Date/Time:27/05/2023 4:18:00 PM) (Verify by :GM Verify Date/Time:27/05/2023 5:02:00 PM)

ISO 9001:2015 Certified Diagnostics Center

Vidhi Imaging Center | Pathology Department

L-86, Swatantra Senani Nagar, Opp. Akhbarnagar Petrol Pump, Nr. Akhbarnagar Circle, Nava-Vadaj, Ahmedabad - 380 013.

Ph. (Pathology) : 079-2762 1406, 8849893954 M. 98799 29406, 98250 09406, E-mail : vidhidiagnostics@gmail.com, Web. : www.vidhidiagnostics.com

Time (Pathology) : Mon. to Sat. 8.30 am to 8.00 pm, Sunday 9 am to 12 Noon

Pathology means science behind medicine

CT SCAN & CBCT FACILITY NOW AVAILABLE

3717 Female

સાક્ષર સરકાર

ભેદ અટકાવેલ


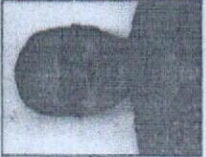

Meha Agrawal

જન્મ તારીખ/ DOB: 16/04/1986

સ્ત્રી / FEMALE

5659 3816 8573


આધાર-સામાન્ય માણસનો અધિકાર



stet

Dr. Vidhi D. Modh
MBBS
Reg. No. G-74540

Vidhi Diagnostics
L-86, Swatantra-Senani Nagar,
Opp. Akhbarnagar Bus Terminals,
Nr. Akhbarnagar Circle,
New Wadaj, Ahmedabad-13.



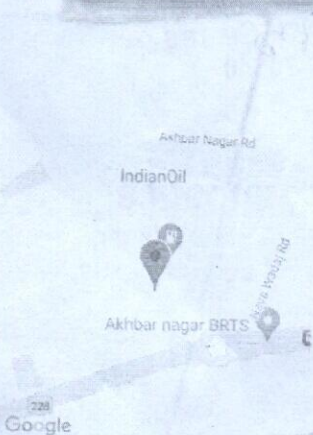Saturday, 27 May 2023 9:25 am

Nirnay Nagar
Ahmedabad

Gujarat

Altitude: 64.9ft

Index number: 258



Vidhi Diagnostics
L-86, Swatantra-Senani Nagar,
Opp. Akhbarnagar Bus Terminals,
Nr. Akhbarnagar Circle,
New Wadaj, Ahmedabad-13.

Dr. Vidhi D. Modh
MBBS
Reg. No. G-74540